

Peripheral artery disease: how much inter-leg symmetry? A contrast-enhanced magnetic resonance angiography study

Francesco Secchi, MD, PhD^{a,b}, Giovanni Di Leo, MSc^a, Alessandra Delnevo, MD^a, Marco Ali, MSc, PhD^{a,c,*}, Ida Daniela D'Angelo, MD^d, Veronica Gaia Nardella, MD^d, Francesco Sardanelli, MD^{a,b}

Abstract

The aim of this observational retrospective study was to qualitatively and quantitatively evaluate the symmetry of atherosclerotic plaques in patients with peripheral artery disease (PAD) undergoing contrast-enhanced magnetic resonance angiography of lower limbs. We retrospectively evaluated the peripheral magnetic resonance angiography of 82 patients considering the iliac, femoral and tibial arteries. Stenosis was scored 0 (none), 1 (<50%), 2 (50%–74%), 3 (75%–99%), and 4 (occluded). Symmetry was quantified as the percentage of bilaterally-diseased arteries and using the inter-leg absolute score difference (0–4). Signs test and Cohen κ were also calculated. Seventy-one (87%) patients had ≥ 1 bilaterally-diseased artery, and 168 (20%) of 820 artery pairs were bilaterally affected. At least 1 bilateral stenosis was observed from 11% (right internal iliac) to 73% (right superficial femoral). All 10 arteries showed symmetry, none of the inter-leg comparisons being significantly different ($P \geq .100$). Cohen κ ranged from 0.208 (common femoral) to 0.533 (internal iliac). This study showed that PAD was symmetrically distributed between the 2 legs, with the internal iliac artery being the most symmetric segment. Symmetry of PAD was quantified in 20%.

Abbreviations: ABI = ankle-brachial index, IQI = interquartile interval, MR = magnetic resonance, PAD = peripheral artery disease, TE = time of echo, TR = time of repetition.

Keywords: magnetic resonance, peripheral artery disease

Editor: Michael Albert Thomas.

The datasets generated during and/or analyzed during the current study are available from the corresponding author on reasonable request.

This study was supported by local research funds of the IRCCS Policlinico San Donato, a Clinical Research Hospital partially funded by the Italian Ministry of Health

Compliance with Ethical Standards.

Conflict of interest information:

F. Secchi and G. Di Leo have been sponsored to congresses by Bracco Imaging SpA (Milan, Italy)

F. Secchi has been sponsored to congresses by Bayer Healthcare (Berlin, Germany).

F. Sardanelli received research grants from Bayer Healthcare (Berlin, Germany) and Bracco Imaging SpA (Milan, Italy); moreover is member of advisory board for Bracco Imaging SpA (Milan, Italy) and General Electric Healthcare (Buc, France).

^a Unit Of Radiology, Irccs Policlinico San Donato, ^b Department of Biomedical Sciences for Health, Università degli Studi di Milano, Via Morandi 30, San Donato Milanese, ^c Unit of Diagnostic Imaging and Stereotactic Radiosurgery, CDI Centro Diagnostico Italiano, Via Saint Bon 20, Milan, ^d Postgraduate School in Radiodiagnosics, Università degli Studi di Milano, Via Festa del Perdono 7, Milan, Italy.

* Correspondence: Marco Ali, Unit of Diagnostic Imaging and Stereotactic Radiosurgery, CDI Centro Diagnostico Italiano, Via Saint Bon 20, 20147 Milan, Italy (e-mail: marco.ali90@gmail.com).

Copyright © 2020 the Author(s). Published by Wolters Kluwer Health, Inc. This is an open access article distributed under the terms of the Creative Commons Attribution-Non Commercial License 4.0 (CCBY-NC), where it is permissible to download, share, remix, transform, and buildup the work provided it is properly cited. The work cannot be used commercially without permission from the journal.

How to cite this article: Secchi F, Di Leo G, Delnevo A, Ali M, D'Angelo ID, Nardella VG, Sardanelli F. Peripheral artery disease: how much inter-leg symmetry? A contrast-enhanced magnetic resonance angiography study. *Medicine* 2020;99:16(e19637).

Received: 8 May 2019 / Received in final form: 21 February 2020 / Accepted: 25 February 2020

<http://dx.doi.org/10.1097/MD.00000000000019637>

1. Introduction

Peripheral arterial disease (PAD) consists of the presence of atherosclerotic plaques in the arteries of the extremities, with partial or complete obstruction of one or more peripheral arteries.^[1] It affects about 20% of people with more than 60 years of age, and nearly 50% of those with more than 85 years. Risk factors include cigarette smoking, impaired glucose tolerance, and hypertension.^[2] The resulting deficiency in oxygenated blood produces degeneration of the vasculature, nerves, and other tissues causing intermittent claudication, pain at rest, numbness and tingling of extremities, and progression to critical limb ischemia.^[3–5] Most patients affected with PAD are asymptomatic, but about 35% of them have symptoms such as intermittent claudication or critical limb ischemia.^[2]

Because of the limitations of clinical assessment of patient pain, a more objective measure is required to diagnose PAD. The measurement of blood pressure at the ankle was proposed as a test for PAD since 1950 and led to the development of the ankle-brachial index (ABI) defined as the ankle to arm systolic blood pressure ratio. An abnormally low value of ABI is indicative of atherosclerosis in the leg under evaluation and an ABI ≤ 0.90 is commonly used in clinical practice to diagnose PAD.^[6]

The distribution of artery stenosis in the lower extremities has been described. In a study of almost 14,000 patients with atherosclerotic arterial occlusive disease, DeBaakey and colleagues found that the most common disease pattern, occurring in over 40% of cases, involved the terminal aorta and its major branches, the distal portion of the femoral artery and the popliteal artery.^[7] Aortic bifurcation and femoral artery, particularly the superficial femoral artery lying within the adductor canal, are more frequently affected due to the vessel morphology and hemodynamics.^[8]

The symmetry of the distribution of PAD lesions in the lower extremities was initially reported in few papers.^[9,10] Due to the tendency to anatomical symmetry of the human body,^[11] in our study we have hypothesized a symmetrical distribution of atherosclerotic plaques in the 2 legs, with potential consequences in terms of PAD prognosis and prevention of bilateral disease progression.

The aim of our study was to qualitatively and quantitatively evaluate the symmetry of atherosclerotic plaques in patients with PAD undergoing contrast-enhanced magnetic resonance (MR) angiography of lower limbs.

2. Methods

2.1. Study population

The local Ethics Committee approved this retrospective study (Ethics Committee of San Raffaele University Hospital; protocol code CardioRetro; approved on Sep 14th, 2017). This study was supported by local research funds of San Donato Hospital, a Clinical Research Hospital partially funded by the Italian Ministry of Health. Due to the retrospective nature of this study, no specific informed consent was necessary.

We evaluated a consecutive series of patients who underwent a contrast-enhanced MR angiography at our institution for known or suspect PAD. The population was composed of 82 patients with a mean age of 69 ± 9 years (mean \pm SD), of which 60 males (age 69 ± 8 years) and 22 females (age 70 ± 11 years). Patients who had undergone lower extremity amputation as well as those with bilaterally normal vessels were excluded.

2.2. Image acquisition

All examinations were performed with a 1.5-T unit (Magnetom Sonata Maestro Class, Siemens Medical Solution, Erlangen, Germany). For each patient, we performed a three-step MR angiography from aortic bifurcation to tibial arteries using a three-dimensional gradient-echo fast low-angle shot sequence after injection of 0.1 mmol/kg of gadobenate dimeglumine (MultiHance, Bracco Imaging SpA, Milan, Italy) at the rate of 2 ml/s, followed by a 20-ml bolus of saline solution at the same injection rate. This sequence was repeated for each of the 3 steps, with the following technical parameters: iliac-femoral (time of repetition [TR] = 3.7 ms; time of echo [TE] = 1.3 ms; flip angle 30°; partition thickness = 1.8 mm; acquisition time from 13 s to 20 s, field of view 360 \times 400 mm), femoral-popliteus (TR = 3.32 ms; TE = 1.21 ms; flip angle 30°; partition thickness = 1.7 mm; acquisition time from 13 s to 20 s; field of view 280 \times 400 mm); and popliteus-tibial (TR = 3.32 ms; TE = 1.21 ms; flip angle 30°; partition thickness = 1 mm, acquisition time from 13 s to 20 s; field of view 233 \times 400 mm). Maximum intensity projection reconstructions were obtained.

2.3. Image analysis

For each patient, we analyzed the following 10 pairs of arteries: common iliac, external iliac, internal iliac, common femoral, profunda femoris, superficial femoral, popliteal, anterior tibial, posterior tibial, and peroneal. For each artery, the stenosis degree of both sides was estimated on post-contrast maximum intensity projection reconstructions. In case of multiple stenosis within an individual artery segment, the highest along with its extension was considered. Referring to the percentage of occlusion, the

following 4-point score was used: 0 for normal; 1 when $<50\%$; 2 when $\geq 50\%$ but $<75\%$; 3 when $\geq 75\%$ but $<100\%$; 4 when occluded. This occlusion percentage was visually estimated by one reader with an 8-year experience in reporting MR angiography.

2.4. Statistical analysis

Upon the exclusion of bilaterally normal artery segments, the symmetry of the disease per each artery was graded as the absolute difference in stenosis score between the left and right side (0 = maximal symmetry; 4 = no symmetry at all). Moreover, the stenosis degree was modeled using the generalized linear model for categorical variables, where the gender and the laterality were considered as fixed factors, while the artery segment as random factor. Finally, we estimated the “inter-leg” agreement between these 2 distributions using the Cohen κ statistics. Moreover, the symmetry of disease was quantified by calculating the percentage of artery segments with bilateral disease, regardless the stenosis score, as well as the percentage of patients with at least 1 artery segment with bilateral disease.

The distribution of the stenosis score as well as the distribution of the disease symmetry were calculated and presented as pie charts. Moreover, a pie chart was also obtained to show the distribution of artery segments with a paired stenosis score, that is, those with the same stenosis score in both legs. To verify whether the disease symmetry applies to all arteries, we compared all arteries using the Kruskal-Wallis test.

As a secondary endpoint, we compared the total stenosis score (calculated adding the scores of the 2 legs) among arteries using the Kruskal-Wallis test. Finally, considering that the superficial femoral artery is known to be more affected than other segments, its total stenosis score was compared to that of the remaining arteries using the Mann-Whitney U test. For that, median and interquartile interval (IQI) were calculated.

3. Results

The distribution of the stenosis score per artery and per each side is shown in Figure 1. A total of 1640 artery segments (82 patients \times 10 artery segment \times 2 sides) were evaluated, with the percentage of normal arteries ranging from 27%, for the right superficial femoral, to 89% for the right internal iliac. Thus, the percentage of arteries with a stenosis score equal or higher than 1 ranged from 11%, for the right internal iliac, to 73% for the right superficial femoral.

Symmetry of disease was quantified in 20% (168/820), being this the percentage of bilaterally diseased pairs of artery segments, regardless the stenosis score. Specifically, the number of patients with an artery segment with bilateral disease ranged from 5/82 (6%) for the common femoral artery to 45/82 (55%) for the superficial femoral artery. Out of 82 patients, 71 (87%) had at least 1 artery segment with bilateral disease, regardless the stenosis score.

The generalized linear model provided no significant association to stenosis of both sex ($P = .145$) and laterality ($P = .311$). The Cohen κ ranged from 0.208 (common femoral) to 0.533 (internal iliac), corresponding to an “inter-leg” agreement from fair to moderate.

Figure 1 also shows the distribution of disease symmetry (third column), where bilaterally normal arteries were excluded. In this regard, the same stenosis score in the two legs (corresponding to

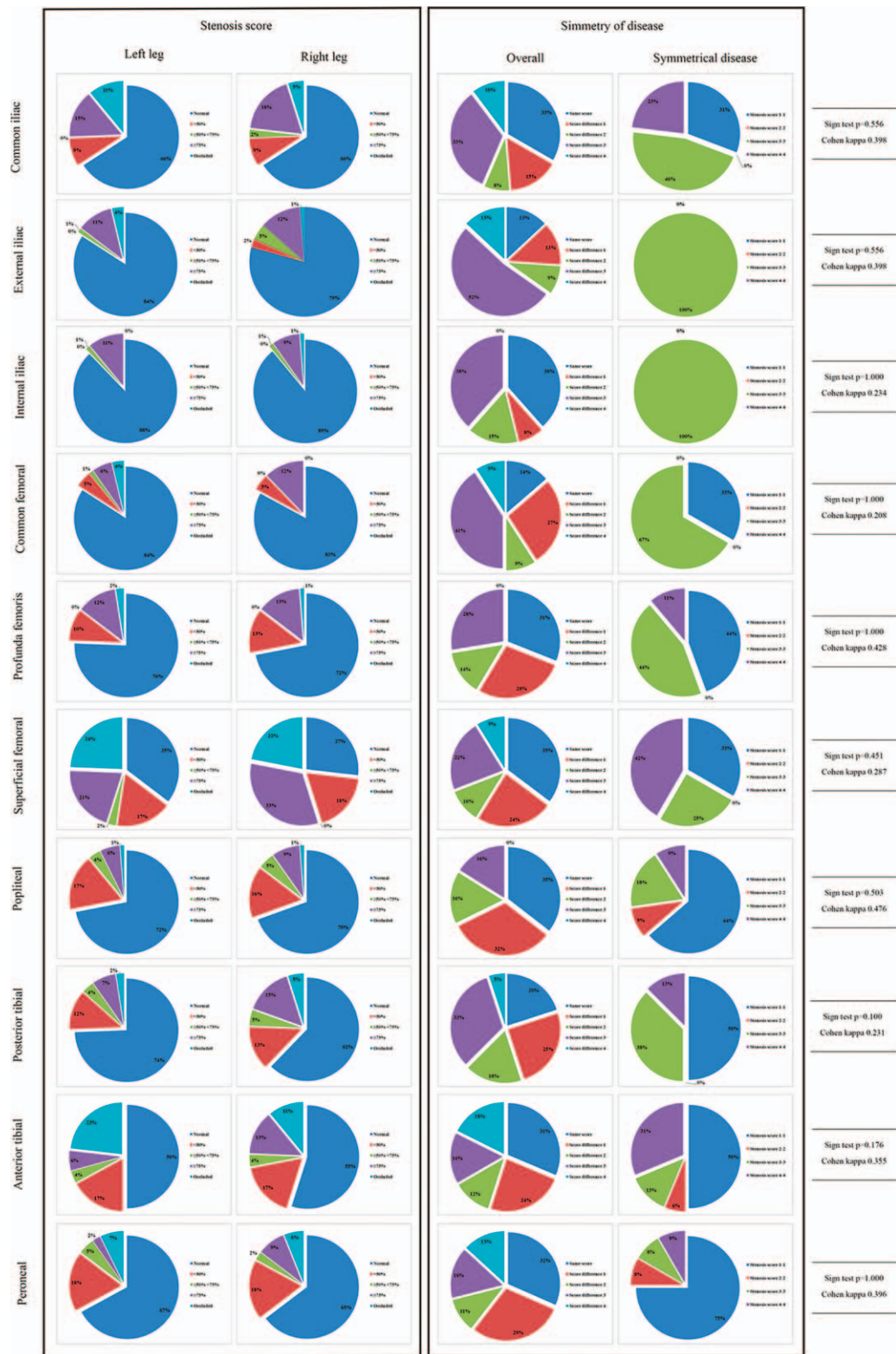


Figure 1. Distribution of the stenosis score per artery for the left leg and the right leg (first and second columns). The third and fourth columns show the distribution of the symmetry of disease. The results of the comparison between left and right legs (test of signs) as well as the calculation of the “inter-leg” agreement (Cohen’s κ statistics) are also shown.

maximal symmetry regardless the absolute stenosis score) ranged from 13% for the external iliac to 38% for the internal iliac. The fourth column of Figure 1 shows the distribution of artery

segments with the same stenosis score. In particular, the percentage of artery segments with the same stenosis score of 3 or 4 in both legs (ie, 3 and 3, or 4 and 4) ranged from 16%, for

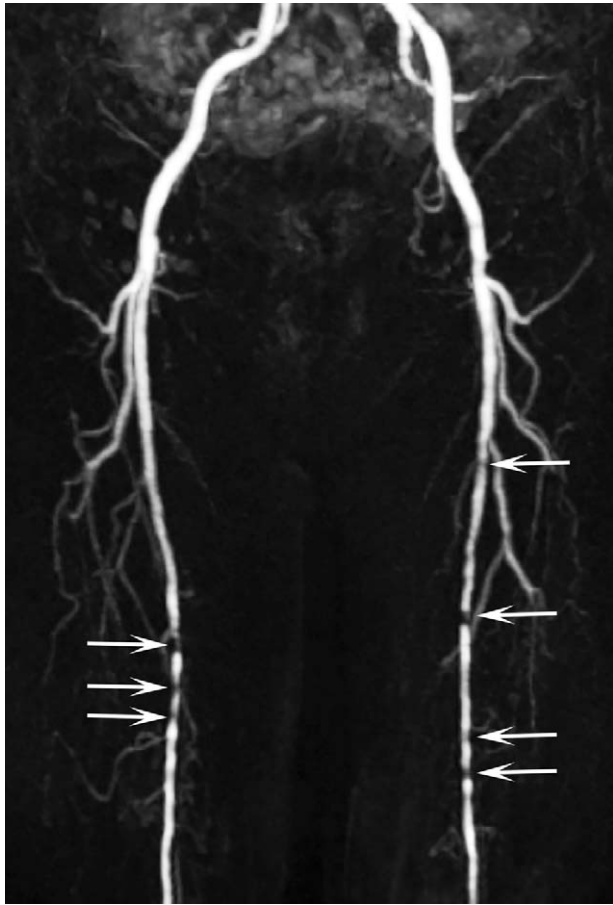


Figure 2. Example of maximum intensity projection reconstruction of the lower extremities studied with contrast-enhanced magnetic resonance angiography. A bilateral stenosis of the superficial femoral artery, scored as 3, can be appreciated (arrows).

the peroneal artery, to 100% for both external and internal iliac artery. The distribution of disease symmetry was similar for all 10 arteries, with the comparison being not significant ($P=.070$).

The total stenosis score per artery segment calculated on all patients was not equally distributed along the legs, with the comparison being statistically significant ($P<.001$). Moreover, the total stenosis score of the superficial femoral artery (median 4, IQI 3–7) was significantly higher than that of the remaining arteries (median 3, IQI 2–4) ($P<.001$).

Examples of symmetrical lesions are shown in Figures 2 and 3.

4. Discussion

In this study, we have shown that there is a trend for PAD to be symmetrically distributed between the 2 legs, but not uniformly distributed along the arterial segments. The study population resulted with a disease prevalence (the percentage of patients with a stenosis score equal or larger than 1 at least in 1 artery segment) from low to high, which can be considered a representative unselected population of patients with already known or suspected PAD undergoing MR angiography. Although a stenosis score of 1 is not clinically relevant, we have considered such a small stenosis (<50%) as the initial phase of a progressing

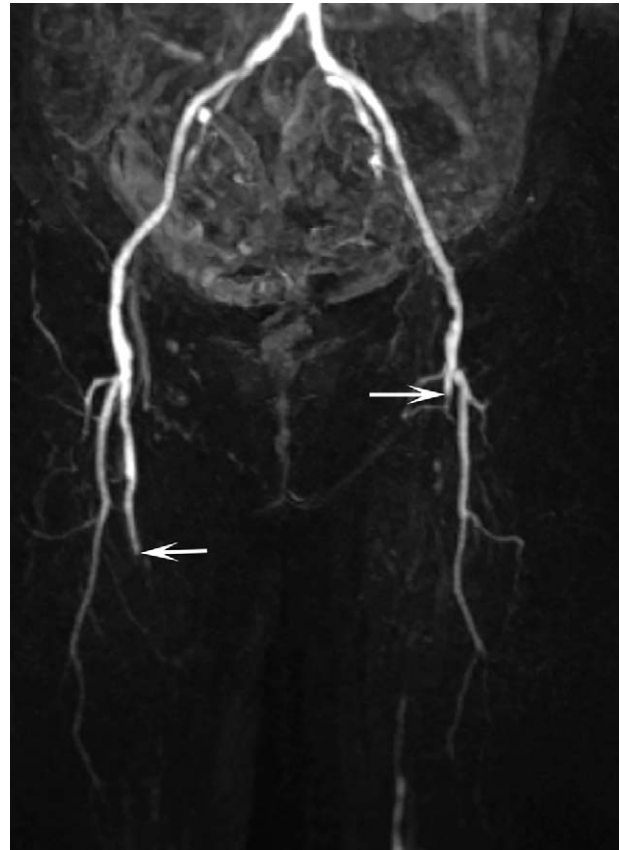


Figure 3. Example of maximum intensity projection reconstruction of the lower extremities obtained with contrast-enhanced magnetic resonance angiography. A bilateral occlusion of the superficial femoral artery, scored as 4, can be appreciated. Arrows show the level of the occlusion.

disease. In this regard, those presenting with a bilaterally normal artery segment were excluded from analysis of symmetry of that specific segment. This is because symmetry of normal condition is expected, while we wanted to demonstrate a certain degree of symmetry in disease condition, that is, that PAD tends to be symmetrically distributed between the two legs.

Several explanations were proposed for PAD localization. Previous studies investigated the relationship between anatomic and hemodynamic factors and plaque formation supporting a physiopathological substrate of symmetrical artery involvement. In fact, vascular inflammation and plaques are known to be mainly distributed at near side branches, where blood flow is non-uniform. Friedman et al^[12] have suggested the existence of “geometric risk factors” for atherosclerosis in the aortic bifurcation. According to the physiological symmetry of human vessels, this geometric and hemodynamics factors may also explain the symmetric distribution of PAD. On a physiopathological ground, plaque formation may be consequence of shear stress on endothelial function and proliferation of smooth muscle cells.^[13]

Considering the large number of variables involved in this study, the PAD symmetry could be quantified in several ways. The PAD symmetry for a given artery segment – strictly intended as the same stenosis score in the 2 legs – ranged from 13% for the external iliac to 38% for the internal iliac. Interestingly, all patients with the same stenosis score of the external iliac artery

had an advanced disease, with a score of 3 in both legs. Considering all artery segments, patients showing the same stenosis score in both legs mainly had a stenosis score of 3 or 4, suggesting not only a general symmetry but also a symmetry in an advanced stage of disease.

Widening the definition of symmetry to cases of bilaterally diseased artery segments regardless the stenosis score (even if it was not the same in the 2 legs), symmetry was quantified in 20% (168/820). To our opinion, this result allows to hypothesize a trend for symmetry in PAD development over time. In fact, we may argue that a patient showing a stenosis score of 1 (in one leg) and 2 (in the other leg) may have a disease progression over time leading to complete symmetry (2 and 2) or to worsening toward 2 and 3 or all other combinations. Of course, this hypothesis should be verified through cohort studies with longitudinal design, taking into account the potential influence of the therapies and the compliance to them. At any rate, the Cohen κ analysis assigned a higher statistical weight to larger discrepancies between stenosis scores.

From a physiopathological point of view, discrepancies in stenosis score between the 2 legs may have a different weight. Indeed, a discrepancy of 2 with a stenosis score of 1 in one artery segment and 3 in the contralateral segment is more relevant than the same discrepancy but with a stenosis score of 0 in one artery segment and 2 in the contralateral segment. Although both cases have the same discrepancy in the stenosis score, in the first case the artery segment is bilaterally diseased, meaning that PAD has started to develop in both legs. Somehow, we can say that PAD is “more symmetrical” in the first case than the second case.

As expected, the superficial femoral artery was the most affected segment, also showing a high degree of symmetry. Specifically, this artery showed a stenosis in 65% of the left leg and in 73% of the right leg (regardless the stenosis score) and, importantly, the stenosis score (≥ 1) was the same in the 2 legs in 35% of patients, with 67% of this 35% having a stenosis score of 3 or 4 in both legs.

In a previous arteriography study that investigated 100 candidates for vascular surgery, a marked symmetry was found in stenosis location, with a perfect agreement between the legs in 53% to 76% of contralateral vessels.^[14] Although using a different method to evaluate the symmetry, our results are in line with that study. Conversely, our results are not in line with those reported by Wilkström et al. They concluded that the atherosclerotic process is to a large degree a random event.^[15] However, they evaluated a selected population of patients affected with claudicatio expected to have unilateral plaque location while our population was not selected for such a symptom.

Our study has limitations. First, it is a retrospective study, implying the lack of important clinical variables such as systemic factors causing atherosclerosis (eg, diabetes mellitus, hypertension, dyslipidemia, tobacco smoking etc). However, our population presented a wide degree of PAD, thus permitting to evaluate different disease degrees. Second, the stenosis degree was evaluated visually by only one reader. However, this reader had an 8-year experience in reporting peripheral MR angiography. Finally, patients were studied once and were not followed up. Thus, we only have a cross-sectional evaluation of the disease and no conclusion may be drawn on the disease progression.

In conclusion, this study showed that PAD was symmetrically distributed between the 2 legs, with the internal iliac artery being

the most symmetric segment. Symmetry of PAD was quantified in 20%. For a given PAD patient, radiologists and clinicians should expect a symmetrical distribution of atherosclerotic lesions between the 2 legs. Longitudinal cohort studies are warranted to verify this hypothesis for the disease development over time and to verify the symmetry of the lesions extension for each vessel.

Author contributions

Conceptualization: Francesco Secchi, Alessandra Delnevo, Francesco Sardanelli.

Data curation: Giovanni Di Leo, Alessandra Delnevo.

Project administration: Francesco Secchi, Francesco Sardanelli.

Resources: Francesco Secchi.

Supervision: Francesco Secchi.

Validation: Ida Daniela D'Angelo, Francesco Sardanelli.

Visualization: Francesco Sardanelli.

Writing – original draft: Francesco Secchi, Marco Ali, Veronica Gaia Nardella, Francesco Sardanelli.

Writing – review & editing: Francesco Secchi, Marco Ali, Francesco Sardanelli.

Marco Ali orcid: 0000-0001-8156-7743.

References

- [1] Criqui MH, Aboyans V. Epidemiology of peripheral artery disease. *Circ Res* 2015;116:1509–26.
- [2] Kannel WB, McGee DL. Update on some epidemiologic features of intermittent claudication: the Framingham Study. *J Am Geriatr Soc* 1985;33:13–8.
- [3] Nehler MR, McDermott MM, Treat-Jacobson D, et al. Functional outcomes and quality of life in peripheral arterial disease: current status. *Vasc Med* 2003;8:115–26.
- [4] Sieminski DJ, Gardner AW. The relationship between free-living daily physical activity and the severity of peripheral arterial occlusive disease. *Vasc Med* 1997;2:286–91.
- [5] Walker C, Bunch FT, Cavros NG, et al. Multidisciplinary approach to the diagnosis and management of patients with peripheral arterial disease. *Clin Interv Aging* 2015;10:1147.
- [6] Winsor T. Influence of arterial disease on the systolic blood pressure gradients of the extremity. *Am J Med Sci* 1950;220:117–26.
- [7] Vogt MT, Wolfson SK, Kuller LH. Lower extremity arterial disease and the aging process: a review. *J Clin Epidemiol* 1992;45:529–42.
- [8] Cecchi E, Giglioli C, Valente S, et al. Role of hemodynamic shear stress in cardiovascular disease. *Atherosclerosis* 2011;214:249–56.
- [9] Suttmeier B, Teichgräber U, Rathke H, et al. Initial experience with imaging of the lower extremity arteries in an open 1.0 Tesla MRI system using the triggered angiography non-contrast-enhanced sequence (TRANSE) compared to digital subtraction angiography (DSA). *Biomed Tech (Berl)* 2016;61:383–92.
- [10] Savel'ev VS, Koshkin VM, Nosenko EM, et al. Peripheral macro-hemodynamics in patients with lower limb arteriosclerosis obliterans and type II diabetes mellitus. *Angiol Sosud Khir* 2003;9:9–20.
- [11] Adams GJ, Simoni DM, Bordelon CB, et al. Bilateral symmetry of human carotid artery atherosclerosis. *Stroke* 2002;33:2575–80.
- [12] Friedman MH, Hutchins GM, Barger CB, et al. Correlation between intimal thickness and fluid shear in human arteries. *Atherosclerosis* 1981;39:425–36.
- [13] Wood NB, Zhao SZ, Zambanini A, et al. Curvature and tortuosity of the superficial femoral artery: a possible risk factor for peripheral arterial disease. *J Appl Physiol* 2006;101:1412–8.
- [14] Walden R, Adar R, Rubinstein ZJ, et al. Distribution and symmetry of arteriosclerotic lesions of the lower extremities: an arteriographic study of 200 limbs. *Cardiovasc Intervent Radiol* 1985;8:180–2.
- [15] Wikström J, Hansen T, Johansson L, et al. Lower extremity artery stenosis distribution in an unselected elderly population and its relation to a reduced ankle-brachial index. *J Vasc Surg* 2009;50:330–4.