



King Saud University  
Saudi Dental Journal

www.ksu.edu.sa  
www.sciencedirect.com



## ORIGINAL ARTICLE

# Correlation between facial growth patterns and cortical bone thickness assessed with cone-beam computed tomography in young adult untreated patients

Francesca Gaffuri <sup>a,\*</sup>, Gianguido Cossellu <sup>a</sup>, Cinzia Maspero <sup>a</sup>, Valentina Lanteri <sup>a</sup>,  
Alessandro Ugolini <sup>b</sup>, Giulio Rasperini <sup>a</sup>, Iury O. Castro <sup>c</sup>, Marco Farronato <sup>a</sup>

<sup>a</sup> Fondazione IRCCS Cà Granda Ospedale Maggiore Policlinico, Department of Biomedical, Surgical and Dental Sciences, School of Dentistry, University of Milan, Milan, Italy

<sup>b</sup> Orthodontic Section, Department of Sciences Integrated Surgical and Diagnostic, University of Genova, Genova, Italy

<sup>c</sup> Department Orthodontics, School of Dentistry, Universidade Federal de Goiás, Goiania, Brazil

Received 17 December 2019; revised 22 January 2020; accepted 30 January 2020

## KEYWORDS

Alveolar bone;  
Cone beam computed  
tomography;  
Facial growth pattern

**Abstract** *Background:* The vertical facial growth pattern is one of the most important issue in the orthodontic diagnosis and treatment. Previous studies investigated the association between interdental bone thickness and facial divergence using mainly bidimensional analysis. When two-dimensional dental radiographic views are not sufficient for diagnosis and measurements, cone-beam computed tomography (CBCT) images should be used to assess the alveolar bone structure three-dimensionally and with high accuracy and reliability.

The aim of the present study was to evaluate the correlation between alveolar bone thickness and facial divergence in young adults untreated patients using a three-dimensional method analysis with CBCT images.

*Methods:* Records of 30 untreated patients (mean age  $16 \pm 2$  years) with Angle Class I and mild to moderate crowding were analyzed. Subjects were classified as hypodivergent ( $< 39^\circ$ ), normodivergent ( $41 \pm 2$ ), and hyperdivergent ( $> 43^\circ$ ). according to the inter-maxillary angle between the sagittal maxillary plane (ANS-PNS) and the mandibular plane (GN-ME). The alveolar bone thickness measurements were taken for the buccal and palatal/lingual surfaces of maxillary and mandibular

\* Corresponding author.

E-mail addresses: francesca.gaffuri@unimi.it (F. Gaffuri), gianguido.cossellu@unimi.it (G. Cossellu), cinzia.maspero@unimi.it (C. Maspero), valentina.lanteri@unimi.it (V. Lanteri), alexugolini@yahoo.it (A. Ugolini), giulio.rasperini@unimi.it (G. Rasperini), iurygo@hotmail.com (I.O. Castro), marco.farronato@unimi.it (M. Farronato).

Peer review under responsibility of King Saud University.



Production and hosting by Elsevier

<https://doi.org/10.1016/j.sdentj.2020.01.009>

1013-9052 © 2020 The Authors. Production and hosting by Elsevier B.V. on behalf of King Saud University.

This is an open access article under the CC BY-NC-ND license (<http://creativecommons.org/licenses/by-nc-nd/4.0/>).

Please cite this article in press as: Gaffuri, F. et al., Correlation between facial growth patterns and cortical bone thickness assessed with cone-beam computed tomography in young adult untreated patients. Saudi Dental Journal (2020), <https://doi.org/10.1016/j.sdentj.2020.01.009>

anterior teeth. Axial-guided navigation (AGN) was used to locate all landmarks using a specific software (Horos 3.0).

**Results:** The statistical analysis showed a significant difference between the hypodivergent and hyperdivergent group regarding buccal bone height ( $P = 0.005$ ), buccal apical bone thickness ( $P = 0.003$ ) and palatal mid-root bone thickness ( $P = 0.006$ ). Moreover, buccal bone height ( $P = 0.006$ ) was found to be statistically significant different in normodivergent compared with hypodivergent individuals.

**Conclusions:** Facial types were found to be correlated with alveolar bone thickness. The hyperdivergent subjects presented thinner alveolus bone in the anterior maxilla and at almost all sites in the mandible. Clinicians should be aware of the possibility of thin cortical bone plates in hyperdivergent patients, reducing antero-posterior movements to avoid fenestration and dehiscence.

© 2020 The Authors. Production and hosting by Elsevier B.V. on behalf of King Saud University. This is an open access article under the CC BY-NC-ND license (<http://creativecommons.org/licenses/by-nc-nd/4.0/>).

## 1. Introduction

The craniofacial morphology is a complex system with inter-individual phenotypic variations determined by genetics, environmental factors and functional demands. The growth of the maxillo-mandibular region is closely related to the surrounding muscular system: the craniofacial structures, including oral soft tissues and hard tissues, are strongly influenced by the strains of masticatory forces (Weinmann, 1955; Ichim et al., 2007).

According to the mechanostat hypothesis proposed by Frost (1987, 1994), and the researches made by Currey (Currey, 1968), a range of strain values are responsible for determining the nature of bone adaptation: strains exceeding this range induce bone production, whereas strains below those values, lead to bone loss (Jee, 2000). Several animal and human studies have investigated the relationship between masticatory muscles force and craniofacial growth pattern (Fields et al., 1984), showing associations between increased facial divergence, with a hyper-divergent growth pattern, and muscular hypofunction (Proffit and Fields, 1983; Garcia-Morales et al., 2003); whereas individuals with strong muscles are characterized by short face (Satiroglu et al., 2005).

Vertical facial morphology is important for the orthodontist, influencing growth prediction, anchorage system, bite force and functions. Since the vertical facial dimensions are related to morphological bone changes controlled by genetics and functions during childhood (Bresin, 2001, Mavropoulos), it is reasonable to believe that maxillary and mandibular cortical bone thicknesses might diverge too in patients with different facial growth pattern (Tsunori et al., 1998; Chan et al., 2008).

Several studies based on bidimensional analysis provided evidence of a significant relationship between facial type and the alveolar bone morphology. Dento-alveolar compensation occurred in subjects with hyper- and hypo- divergent facial growth mainly by adaptations in the alveolar thicknesses and bone heights of the anterior sites (Janson et al., 2003). However, these data are based on two-dimensional (2D) imaging whose limits have been widely demonstrated (van Vlijmen et al., 2009; Farronato et al., 2010).

In recent years, cone beam computed tomography (CBCT) has been specifically introduced and successfully used to evaluate 3D structures, volumes and the bony architecture and the morphology of the cortical bone in the maxillary-mandibular

complex (Cossellu et al., 2015a, 2015b; Kapila and Nervina, 2015). Whereas muscle forces have been related to cortical thickness and facial divergence, limited research has been conducted correlating cortical bone thickness to facial divergence.

The purpose of this study is to investigate the correlation between facial divergence and cortical bone thicknesses of the maxillary and mandibular anterior tooth-bearing region using CBCT images of young untreated adults.

## 2. Materials and methods

### 2.1. Sample selection

This study included records selected from a retrospective screening of CBCT images archived at the Dental Clinic of the Federal University of Goiás, Brazil, acquired from January 2011 to March 2014.

The 3D images were obtained using an I-CAT CBCT (Imaging Sciences International, Hatfield, PA, USA) configured for 0.25 mm volumetric reconstruction, 12-bit grayscale, isometric voxel, 120kVp tube voltage, field of view (FOV) of 13 cm, 3.8 mA tube current and exposure time of 40 s. The high definition and sensitivity of CBCT scans ensures that the buccal and palatal/lingual cortical bone, together with teeth, is visualized without any overlapping. The use of 12-bit grayscale, as a standard parameter, strengthens the effectiveness and the accuracy in evaluating the alveolar bone structures.

From 220 patients, whose CBCT images were taken for diagnosis and treatment plan of craniofacial, skeletal or pathological abnormalities, 93 subjects (mean age of  $16 \pm 2$  years) meeting the following inclusion criteria were selected: no previous orthodontic treatment, Angle Class I malocclusion, permanent dentition and mild to moderate dental crowding.

Records showing decayed teeth, deciduous dentition, impacted molars, periodontal disease with alveolar bone loss, missing lower anterior teeth, traumatic dental injury and metal restorations were excluded.

The resulting sample of 48 CBCT images was analyzed at the Department of Biomedical, Surgical and Dental Sciences (University of Milan, Fondazione IRCCS Ca' Granda, Ospedale Maggiore Policlinico) and classified in three groups according to the facial growth pattern: hypodivergent ( $< 39^\circ$ ), normodivergent ( $41 \pm 2^\circ$ ), and hyperdivergent ( $> 43^\circ$ ).

Categories were determined measuring the bi-dimensional and the 3D inter-maxillary angle between the sagittal maxillary plane (ANS-PNS) and right and left mandibular plane (GoDx-Me and GoSx-Me), using the software Mimics Materialise (Materialise HQ, Leuven, Belgium) as defined in Fig. 1. Patients had to fit into a single category for the two different resulting measurements, to be included in the study. 18 subjects who fell into mixed groups were excluded from the groups. The remaining selected CBCT images were 10 hypodivergent subjects, 10 normodivergent and 10 hyperdivergent ones.

Patients data were handled in accordance with the World Medical Association Declaration of Helsinki of 1975, revised in Tokyo 2004. This study was approved by the Research Ethics Committee of the institution where CBCT scans were performed (Brazil Platform, Federal University of Goiás, Brazil #024439/2014).

## 2.2. Alveolar bone measurements

Vertical alveolar bone distances and horizontal thicknesses around the maxillary and mandibular central and lateral incisors and canines were measured by a single examiner (F.G.) who had been trained. The images were analyzed using Horos 3.0 software (Horos Project, Annapolis, Maryland USA).

Axial-guided navigation (AGN) was used to locate the reference points (Castro et al., 2016) moving the axial cursor on the sagittal or coronal multiplane reconstructions guided by the axial plane along the axis of the dental root to achieve an optimal visualization of the marginal bone in the chosen view. Reference points, lines, and dimension variables are described in Fig. 2.

Buccal Bone Height (BHb) and palatal/lingual Bone Height (BHp), indicating the distances between the cement-enamel junction (CEJ) and the alveolar bone crest (AC), were measured parallel to the long axis of the 12 teeth selected for the research (the anterior region comprehending upper and lower incisors and canines), on the sagittal reconstructed slice. These measurements represent the amount of vertical alveolar bone loss (Sharpe et al., 1987).

The buccal (aBTb, mBTb) and palatal/lingual (aBTp, mBTp) bone thicknesses were measured at mid-root and root apex level, perpendicularly to the long axis of the teeth. In order to have a more accurate evaluation of the thickness values, we controlled each measure of anterior teeth both in the coronal and in the sagittal slices.

Measurements	Definition
BHv	Buccal bone height
BHp	Palatal bone height
aBTv	Apical buccal bone thickness
aBTp	Apical palatal bone thickness
mBTv	Mid-root buccal bone thickness
mBTp	Mid-root palatal bone thickness

## 2.3. Error method

All CBCT were randomly ordered by one operator and the identification was masked by a second operator before being evaluated. The examiners who analyzed the records were blind with regard to the divergence classification of patients. Alveolar bone measurements were traced by a single principal investigator (F.G.) and checked by a senior orthodontist (G.C.) in order to verify skeletal and dental landmarks location. Any disagreements were resolved to the satisfaction of both observers (F.G., G.C.).

To ensure intra-examiner reliability, 5 CBCTs from each group were randomly selected and all variables (both vertical and horizontal bone distances) were recalculated two weeks after the first data collection.

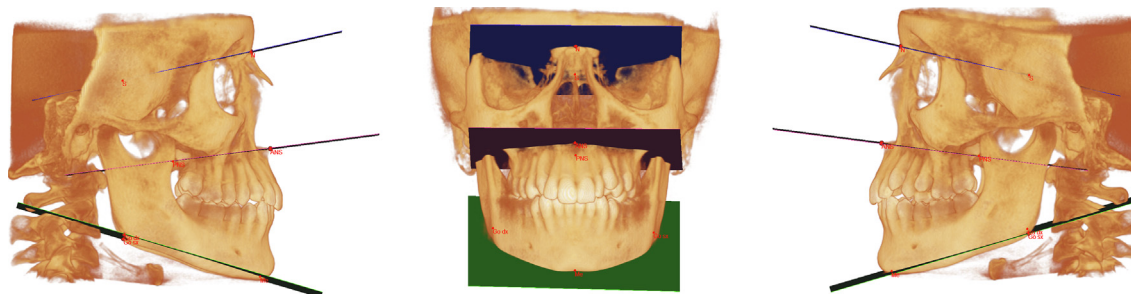
The Dahlberg's values method error and the intra-class correlation coefficients (ICC) were performed.

## 3. Statistical analysis

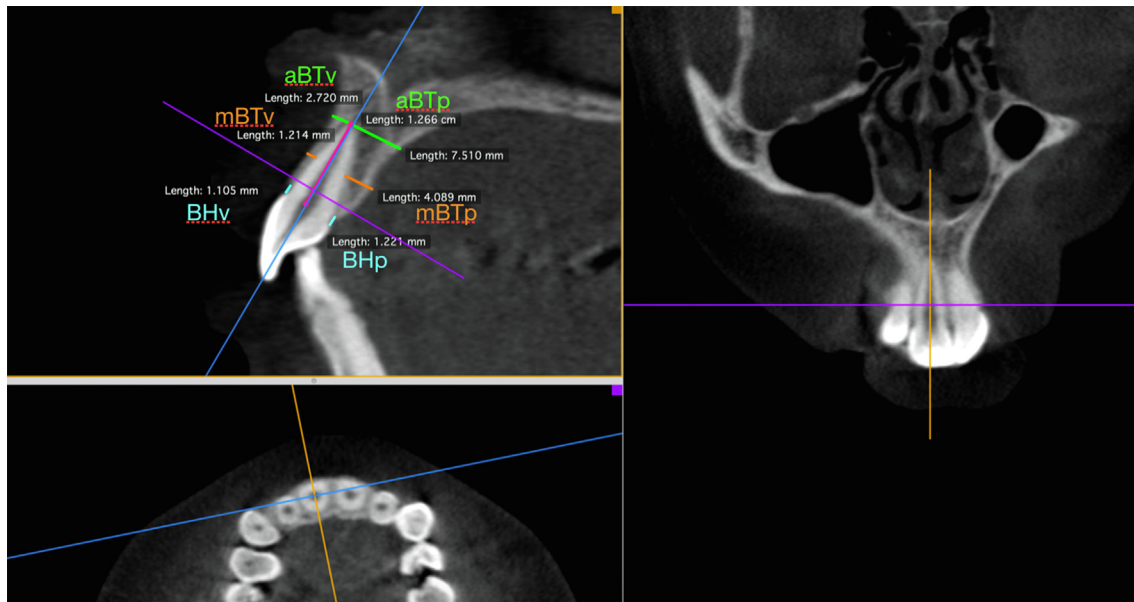
Statistical calculations were carried out using the Rstudio software (Rstudio Version 1.1.383, Rstudio, Inc., Massachusetts, USA). Descriptive statistics (mean and standard deviation) were calculated for each variable. Subjects data were compared using non-parametric tests for three independent samples (Kruskal-Wallis test). Level of significance was set at 5% for all statistical analyses; significance of post-hoc tests was corrected after Bonferroni ( $p = 0.017$ ).

## 4. Results

Horizontal and vertical alveolar bone thicknesses were assessed in all patients according to their growth pattern. Statistical analysis is presented in Table 1. The Kruskal-Wallis Test showed statistically significant differences among the



**Fig. 1** 3D analysis to classify the different growth pattern using the 3D inter-maxillary angle between the sagittal maxillary plane (ANS-PNS) and right and left mandibular plane (GoDx-Me and GoSx-Me), by means of the software Mimics Materialise (Materialise HQ, Leuven, Belgium).



**Fig. 2** Reference lines and measurements for an upper central incisor using the Horos 3.0 software (Horos Project, Annapolis, Maryland USA) DICOM images viewer. aBTb = buccal apical bone thickness; aBTp = palatal apical bone thickness; BHb = buccal bone height; BHp = palatal bone height; mBTb = buccal mid-root bone thickness; mBTp = palatal mid-root bone thickness.

**Table 1** Descriptive statistics and statistical comparison of Bone Thicknesses in Iperdivergent, Ipodivergent and Normodivergent subjects.

Bone Values	IPER		IPO		NORMO		KW Test		BONFERRONI POST HOC		
	Mean	SD	Mean	SD	Mean	SD	hyper vs hypo	vs Normo	hyper vs Normo	hyper vs hypo	Normo vs Ipo
BHv	2.65	1.81	1.34	0.56	1.77	0.66	0.001		0.041	0.005	0.006
BHp	2.09	1.48	1.18	0.54	1.52	0.63	0.060		0.135	0.024	0.034
aBTv	3.20	1.14	4.74	1.75	3.86	1.50	0.006		0.046	0.003	0.057
aBTp	4.54	1.68	5.71	2.10	5.37	2.02	0.054		0.067	0.025	0.339
mBTv	0.79	0.38	1.49	0.90	1.03	0.60	0.027		0.141	0.030	0.14
mBTp	1.42	0.86	2.31	0.89	1.90	0.83	0.029		0.101	0.006	0.091

groups for buccal bone height, buccal apical bone thickness and buccal/palatal mid-root bone thickness measurements ( $P < 0.05$ ).

The Post-hoc analysis results showed a significant correlation between growth patterns and the mean alveolar bone values considering the maxillary and the mandibular anterior region.

Buccal bone height ( $P = 0.005$ ), buccal apical bone thickness ( $P = 0.003$ ) and palatal mid-root bone thickness ( $P = 0.006$ ) showed statistically significant differences in hyperdivergent vs hypodivergent subjects, indicating that cortical bone was thicker in the hypodivergent group.

Furthermore, buccal bone height (0.006) was found to be statistically significant different in normodivergent vs hypodivergent individuals, showing a shorter alveolar ridge vertical thickness for the hypodivergent pattern.

## 5. Discussion

Previous researches, evaluating the association between facial type and the morphological features, were based on bidimensional analysis. Only few studies used CBCT images, but the

authors focused the investigation on different variables such as the interdental alveolar ridge (Kuitert et al., 2006; Gracco et al., 2010; Horner et al., 2012; Ozdemir et al., 2013; Sadek et al., 2015), sites for the placement of mini-screws and the presence of periodontal defects such as bone fenestration or dehiscences (Farronato et al., 2013).

The novelty of our study was to evaluate the alveolar bone thicknesses around anterior teeth by means of CBCT images, in different vertical facial pattern.

The results demonstrated that the mean of the buccal and lingual/palatal alveolar height of hypodivergent subjects was lower than those with an hyperdivergent facial type. Concerning the buccal and lingual/palatal bone thicknesses at mid-root and root apex level, the hyperdivergent facial type was found to be thinner than the hypodivergent facial type. Hyperdivergent facial pattern group had buccal apical bone thickness and lingual/palatal mid-root level significantly thinner than hypodivergent facial pattern. The bone height, indicating the vertical dimension deprived of alveolar bone between the CEJ and marginal crest, in buccal side was significantly greater in hyperdivergent than hypodivergent facial pattern.

The present study agrees with [Sadek et al. \(2015\)](#) that investigated differences in alveolar and skeletal dimensions among subjects with different vertical facial dimensions using CBCT. The authors concluded that high-angle group presented thinner alveolus anteriorly in the maxilla and at almost all sites in the mandible. Similarly, [Kuitert et al. \(2006\)](#) found that the cortical bone height was statistically significant longer in hyperdivergent faces than hypodivergent ones because of the increased dento-alveolar compensation mechanism occurred in long-face patients ([Klinge et al., 2017](#)).

[Horner et al. \(2012\)](#) assessed inter-radicular cortical bone thicknesses and alveolar ridge thicknesses of young adults to provide reference data for miniscrew placement and concluded that cortical bone tends to be thicker in hypodivergent than in hyperdivergent subjects.

On the other hand, studies have reported contradictory results for alveolar features when comparing patients with different facial growth patterns. [Gracco et al. \(2010\)](#) demonstrated that no differences, considering alveolar bone, between the facial types were found. However, the authors used only one criteria to classify the facial types identified by the 2D cephalometric radiographs.

Bidimensional analysis based on the Frankfort-mandibular plane can provide bias. The deflection of cranial base modifies the real vector of facial growth patterns. Thus, it is required the use of other reference plans to evaluate the facial type.

Although some researchers use CBCT to define the characteristics of alveolar bone height and thickness, different methods have been used. Most of these are taken in slices obtained by the CBCT, which might lead to measurement errors. Static images on the CBCT reveal the thickness and height only in that specific slice that are usually separated by at least 2 mm. Real measurements have to be achieved directly on the 3D reconstruction, with a dynamic process that requires specific examiner skills.

The present study used the Axial Guided Navigation (AGN) method ([Castro et al., 2013](#)). The measurements are made by moving the axial cursor on the sagittal or coronal view reconstructions guided by the axial one, with the goal to find the exact confine of the structures. This strategy and the software measuring tool ensured precise measurements from crest edge to the root apex without the limiting factors of two-dimensional radiographs and single slices. Despite the differences in the previous studies, there is a general consensus that among normo-, hypo- and hyper-divergent subjects the alveolar height of the posterior area of the mandible became greater toward the symphysis as well as the thickness of the lingual side and in maxillary buccal side the thickness became thinner from posterior to anterior ([Swasty et al., 2011](#)).

The present study evaluated the correlation between alveolar bone thickness and facial divergence in untreated young adult patients. [Swasty et al. \(2011\)](#) studied the cross-sectional human mandibular morphology in subjects with different vertical facial dimensions using CBCT and no significantly statistically differences were found between genders although the mandible was wider and taller in males than females ([Foosiri et al., 2018](#)). [Farnsworth et al. \(2011\)](#) did not find differences between males and females' cortical thickness in both maxilla and mandible. Studies related to the use of mini-implants, mini-plates, screws and temporary anchorage devices (TAD's) showed that the bone support, the quality and thickness of bone are important factors for the TAD's installation and

treatment success ([Fayed et al., 2010](#); [Martinelli et al., 2010](#); [Farnsworth et al., 2011](#)).

[Martinelli et al. \(2010\)](#) concluded that anterior sites require even more careful planning to placing anchorage, including the use of computed tomography records.

Furthermore, periodontal defects might be identified without distortions in CBCT in contrast with 2D radiologic exams like panoramic radiograph ([Mengel et al., 2005](#)).

[Enhos et al. \(2012\)](#) assessed dehiscence and fenestration in patients with different vertical growth patterns with CBCT and concluded that the prevalence of dehiscence was found in all different vertical growth patterns. Hypo-divergent subjects had less dehiscences than did the hyper-divergent and normodivergent groups.

Inherent limitations of CBCT scanning as related to physical spatial resolution of the image and limitations posed by the study sample size should be considered. In using digital radiography such as CBCT, the resolution of the voxel and the grayscale are important to determining the accuracy of measuring the anatomic structures. The present study used voxel size 0.25 mm and 12-bit grayscale. The differences in the density of cortical bone were not evaluated in this study. Further studies with higher resolution voxels can improve the accuracy of the measurements.

According with [Ozdemir et al. \(2013\)](#), the hyperdivergent facial pattern group presented slightly narrower cortical bone than the hypodivergent one, suggesting that subjects with this facial type tend to have less-dense buccal cortical bone in the maxillary and mandibular alveolar processes. Therefore, it is recommended that the antero-posterior movements in hyperdivergent patients should be reduced to avoid fenestration and dehiscence.

## 6. Conclusions

This research showed a statistically significant relationship between facial growth pattern and alveolar bone height and thickness. Hyper-divergent subjects presented thinner cortical bone anteriorly in the maxilla and at almost all sites in the mandible.

The present study brings an important knowledge about the characteristic of the anterior cortical bone suggesting new reference data for clinicians. These results provide information that could be useful for the clinicians to prevent iatrogenic risk of moving incisors beyond alveolar bone limits and preview the ideal direction and position of orthodontic tooth movements.

## Ethics approval and consent to participate

This study was approved by the Research Ethics Committee of the institution where CBCT scans were performed (Brazil Platform, Federal University of Goiás, Brazil #024439/2014).

Informed consent was obtained from all the patients included in the study. The ethical guidance for the study was in accordance with the World Medical Association Declaration of Helsinki of 1975, revised in Tokyo 2004.

## Acknowledgement

The authors do not have any financial interests, either directly or indirectly, in the products or information listed in the paper.

### Copyright releases

The undersigned author transfers all copyright ownership of the manuscript “Correlation between facial growth patterns and cortical bone thickness assessed with cone-beam computed tomography in young adult untreated patients” to the *Saudi Journal* in the event the work is published. The undersigned author warrants that the article is original, is not under consideration for publication by another journal and has not been previously published. I sign for and accept responsibility for releasing this material on behalf of *any* and all coauthors.”

### Declaration of Competing Interest

The authors declare that they have no competing interests.

### Funding

The authors received no financial support for the research, authorship, and/or publication of this article.

### Authors' contributions

FG performed the examinations, analyzed and interpreted the patient data and was a major contributor in writing the manuscript.

GC performed the examinations, participated in drafting the paper and revised the manuscript for submission JC has undertaken the clinical part of the study and participated in the acquisition of the data.

AU participated in the analysis and interpretation of data and revised the manuscript for submission MF contributed to the design of the study and revised the manuscript for submission.

CM contributed to the design of the study and revised the manuscript for submission All authors read and approved the final manuscript.

### References

- Bresin, A., 2001. Effects of masticatory muscle function and bite-raising on mandibular morphology in the growing rat. *Swed. Dent. J. Suppl.* 150, 1–49.
- Castro, I.O., Alencar, A.H., Valladares-Neto, J., Estrela, C., 2013. Apical root resorption due to orthodontic treatment detected by cone beam computed tomography. *Angle Orthod.* 83 (2), 196–203.
- Castro, L.O., Castro, I.O., de Alencar, A.H., Valladares-Neto, J., Estrela, C., 2016. Cone beam computed tomography evaluation of distance from cemento-enamel junction to alveolar crest before and after nonextraction orthodontic treatment. *Angle Orthod.* 86 (4), 543–549.
- Chan, H.J., Woods, M., Stella, D., 2008. Mandibular muscle morphology in children with different vertical facial patterns: A 3-dimensional computed tomography study. *Am. J. Orthod. Dentofacial Orthop.* 133 (1), 10.e11–13.
- Cossellu, G., Biagi, R., Sarcina, M., Mortellaro, C., Farronato, G., 2015a. Three-dimensional evaluation of upper airway in patients with obstructive sleep apnea syndrome during oral appliance therapy. *J. Craniofac. Surg.* 26 (3), 745–748.
- Cossellu, G., De Luca, S., Biagi, R., Farronato, G., Cingolani, M., Ferrante, L., Cameriere, R., 2015b. Reliability of frontal sinus by cone beam-computed tomography (CBCT) for individual identification. *Radiol. Med.* 120 (12), 1130–1136.
- Currey, J.D., 1968. The adaptation of bones to stress. *J. Theor. Biol.* 20 (1), 91–106.
- Enhos, S., Uysal, T., Yagci, A., Veli, I., Ucar, F.I., Ozer, T., 2012. Dehiscence and fenestration in patients with different vertical growth patterns assessed with cone-beam computed tomography. *Angle Orthod.* 82 (5), 868–874.
- Farnsworth, D., Rossouw, P.E., Ceen, R.F., Buschang, P.H., 2011. Cortical bone thickness at common miniscrew implant placement sites. *Am. J. Orthod. Dentofacial Orthop.* 139 (4), 495–503.
- Farronato, G., Garagiola, U., Dominici, A., Periti, G., de Nardi, S., Carletti, V., Farronato, D., 2010. “Ten-point” 3D cephalometric analysis using low-dosage cone beam computed tomography. *Prog. Orthod.* 11 (1), 2–12.
- Farronato, G., Giannini, L., Galbiati, G., Cannalire, P., Martinelli, G., Tubertini, I., Maspero, C., 2013. Oral tissues and orthodontic treatment: common side effects. *Minerva Stomatol.* 62 (11–12), 431–446.
- Fayed, M.M., Pazera, P., Katsaros, C., 2010. Optimal sites for orthodontic mini-implant placement assessed by cone beam computed tomography. *Angle Orthod.* 80 (5), 939–951.
- Fields, H.W., Proffit, W.R., Nixon, W.L., Phillips, C., Stanek, E., 1984. Facial pattern differences in long-faced children and adults. *Am. J. Orthod.* 85 (3), 217–223.
- Foosiri, P., Mahatumarat, K., Panmekiate, S., 2018. Relationship between mandibular symphysis dimensions and mandibular anterior alveolar bone thickness as assessed with cone-beam computed tomography. *Dental Press J. Orthod.* 23 (1), 54–62.
- Frost, H.M., 1987. The mechanostat: a proposed pathogenic mechanism of osteoporoses and the bone mass effects of mechanical and nonmechanical agents. *Bone Miner.* 2 (2), 73–85.
- Frost, H.M., 1994. Wolff's Law and bone's structural adaptations to mechanical usage: an overview for clinicians. *Angle Orthod.* 64 (3), 175–188.
- García-Morales, P., Buschang, P.H., Throckmorton, G.S., English, J. D., 2003. Maximum bite force, muscle efficiency and mechanical advantage in children with vertical growth patterns. *Eur. J. Orthod.* 25 (3), 265–272.
- Gracco, A., Luca, L., Bongiorno, M.C., Siciliani, G., 2010. Computed tomography evaluation of mandibular incisor bony support in untreated patients. *Am. J. Orthod. Dentofacial Orthop.* 138 (2), 179–187.
- Horner, K.A., Behrents, R.G., Kim, K.B., Buschang, P.H., 2012. Cortical bone and ridge thickness of hyperdivergent and hypodivergent adults. *Am. J. Orthod. Dentofacial Orthop.* 142 (2), 170–178.
- Ichim, I., Kieser, J.A., Swain, M.V., 2007. Functional significance of strain distribution in the human mandible under masticatory load: numerical predictions. *Arch. Oral Biol.* 52 (5), 465–473.
- Janson, G., Bombonatti, R., Brandao, A.G., Henriques, J.F., de Freitas, M.R., 2003. Comparative radiographic evaluation of the alveolar bone crest after orthodontic treatment. *Am. J. Orthod. Dentofacial Orthop.* 124 (2), 157–164.
- Jee, W.S., 2000. Principles in bone physiology. *J. Musculoskelet. Neuronal Interact.* 1 (1), 11–13.
- Kapila, S.D., Nervina, J.M., 2015. CBCT in orthodontics: assessment of treatment outcomes and indications for its use. *Dentomaxillofac. Radiol.* 44 (1), 20140282.
- Klinge, A., Becktor, K., Lindh, C., Becktor, J.P., 2017. Craniofacial height in relation to cross-sectional maxillary and mandibular morphology. *Prog. Orthod.* 18 (1), 32.
- Kuitert, R., Beckmann, S., van Loenen, M., Tuinzing, B., Zentner, A., 2006. Dentoalveolar compensation in subjects with vertical skeletal dysplasia. *Am. J. Orthod. Dentofacial Orthop.* 129 (5), 649–657.
- Martinelli, F.L., Luiz, R.R., Faria, M., Nojima, L.I., 2010. Anatomic variability in alveolar sites for skeletal anchorage. *Am. J. Orthod. Dentofacial Orthop.* 138 (3), 252.e251–259; discussion 252–253.

- Mengel, R., Candir, M., Shiratori, K., Flores-de-Jacoby, L., 2005. Digital volume tomography in the diagnosis of periodontal defects: an in vitro study on native pig and human mandibles. *J. Periodontol.* 76 (5), 665–673.
- Ozdemir, F., Tozlu, M., Germec-Cakan, D., 2013. Cortical bone thickness of the alveolar process measured with cone-beam computed tomography in patients with different facial types. *Am. J. Orthod. Dentofacial Orthop.* 143 (2), 190–196.
- Proffit, W.R., Fields, H.W., 1983. Occlusal forces in normal- and long-face children. *J. Dent. Res.* 62 (5), 571–574.
- Sadek, M.M., Sabet, N.E., Hassan, I.T., 2015. Alveolar bone mapping in subjects with different vertical facial dimensions. *Eur. J. Orthod.* 37 (2), 194–201.
- Satiroglu, F., Arun, T., Isik, F., 2005. Comparative data on facial morphology and muscle thickness using ultrasonography. *Eur. J. Orthod.* 27 (6), 562–567.
- Sharpe, W., Reed, B., Subtelny, J.D., Polson, A., 1987. Orthodontic relapse, apical root resorption, and crestal alveolar bone levels. *Am. J. Orthod. Dentofacial Orthop.* 91 (3), 252–258.
- Swasty, D., Lee, J., Huang, J.C., Maki, K., Gansky, S.A., Hatcher, D., Miller, A.J., 2011. Cross-sectional human mandibular morphology as assessed in vivo by cone-beam computed tomography in patients with different vertical facial dimensions. *Am. J. Orthod. Dentofacial Orthop.* 139 (4 Suppl), e377–e389.
- Tsunori, M., Mashita, M., Kasai, K., 1998. Relationship between facial types and tooth and bone characteristics of the mandible obtained by CT scanning. *Angle Orthod.* 68 (6), 557–562.
- van Vlijmen, O.J., Maal, T.J., Berge, S.J., Bronkhorst, E.M., Katsaros, C., Kuijpers-Jagtman, A.M., 2009. A comparison between two-dimensional and three-dimensional cephalometry on frontal radiographs and on cone beam computed tomography scans of human skulls. *Eur. J. Oral Sci.* 117 (3), 300–305.
- Weinmann, J.P., 1955. Variations in the structures of bone and bones and their significance in radiology. *Oral Surg. Oral Med. Oral Pathol.* 8 (9), 988–992.