

Role of Axial Split Osteotomy of Free Fibula Flap in Mandibular Reconstruction and Dental Rehabilitation

Alessandro Remigio Bolzoni, MD,
PhD*†
Alessandro Baj, MD*†
Ahmed Hassan Sweed, MD‡
Aldo Bruno Gianni, MD*†
Edoardo Francesco Montrasio,
MD*†
Giada Anna Beltramini, MD*

Summary: The fibula free flap (FFF) is regarded as the gold standard in mandibular reconstruction. Dental rehabilitation is important to improve the health-related quality of life of patients undergoing mandibular reconstruction. FFF provides adequate cortical bone osseous tissue for use in dental implantation. The application of “axial split osteotomy” via a double-barrel fibula graft may enable discrepancies between the native mandible and FFF to be avoided, thereby improving the likelihood of early and successful dental rehabilitation. (*Plast Reconstr Surg Glob Open* 2020;8:e2546; doi: [10.1097/GOX.0000000000002546](https://doi.org/10.1097/GOX.0000000000002546); Published online 20 January 2020.)

INTRODUCTION

The fibula free flap (FFF) is commonly used for mandibular reconstruction due to its ergonomic benefits. A dual-team approach is used that lowers the total operation time, furthermore, dissection is relatively easy, the pedicle length and caliber are suitable, and the morbidity rate is lower. The fibula depends on the periosteal blood supply for nourishment; it offers a considerable quantity of bicortical bone for dental rehabilitation, thus allowing multiple osteotomies to be performed at the recipient site. Moreover, it has separate septocutaneous perforators that allow a skin paddle (osteoseptocutaneous flap) to be used for soft tissue reconstruction, either externally (overlying skin) or internally (within the oral cavity), or both.¹

Dental rehabilitation after mandibular reconstruction is challenging, regardless of the use of temporary dentures or dental implantation. Moreover, there is no consensus regarding the optimal timing of dental implantation, which can be performed 6 weeks before reconstructive surgery (prefabricated fibula with split-thickness skin graft and dental implant),² immediately (during reconstructive surgery), or following a delay (after bone healing or radiotherapy).³ Successful dental implantation requires adequate bone tissue, a physiological maxillomandibular

relationship (occlusion), and immobile soft tissue surrounding the implants. These factors must be considered during reconstructive surgery to maximize patient satisfaction.

In this article, we describe a new technique for 1-step reconstruction of the anterior mandible. We used “axial split osteotomy” in a double-barrel fibula for excellent height matching between the native mandible and neomandible (double-barrel fibula) under the guidance of computer-aided design–computer-aided manufacturing (CAD-CAM) technology.

PATIENTS AND METHODS

A 56-year-old woman was referred to the Maxillofacial Surgery Unit of Fondazione IRCCS Ospedale Maggiore Ca' Granda Policlinico (Milan, Italy) because of ameloblastoma relapse. Diagnosis was performed via computed tomography and biopsy of a radiolucent lesion in the mandibular symphysis and left parasymphysis. With the aid of CAD-CAM technology, preoperative virtual planning for mandibular reconstruction was performed using the FFF–double-barrel technique; this revealed a discrepancy in height between the native mandible and neomandible (Figs. 1–3). We applied axial split osteotomy in the lower part of the upper segments to remove excess bone and ensure alveolar crest alignment. Two teams performed the operation simultaneously under general anesthesia and a bony FFF was harvested. Through intraoral access and 3-cm submandibular skin access, symphysis and left parasymphysis resection were performed, followed by inset of the planned reconstruction and microanastomosis

From the *Maxillofacial and Dental Unit of Fondazione IRCCS Ca' Granda Ospedale Maggiore Policlinico di Milano, Milan, Italy; †Department of Biomedical, Surgical and Dental Sciences, Università degli Studi di Milano, Milan, Italy; and ‡HNS Zagazig University, Zagazig, Egypt.

Received for publication March 6, 2019; accepted October 4, 2019.

Copyright © 2020 The Authors. Published by Wolters Kluwer Health, Inc. on behalf of The American Society of Plastic Surgeons. This is an open-access article distributed under the terms of the [Creative Commons Attribution-Non Commercial-No Derivatives License 4.0 \(CCBY-NC-ND\)](https://creativecommons.org/licenses/by-nc-nd/4.0/), where it is permissible to download and share the work provided it is properly cited. The work cannot be changed in any way or used commercially without permission from the journal.

DOI: [10.1097/GOX.0000000000002546](https://doi.org/10.1097/GOX.0000000000002546)

Disclosure: The authors have no financial interest to declare in relation to the content of this article.

Related Digital Media are available in the full-text version of the article on www.PRSGlobalOpen.com.

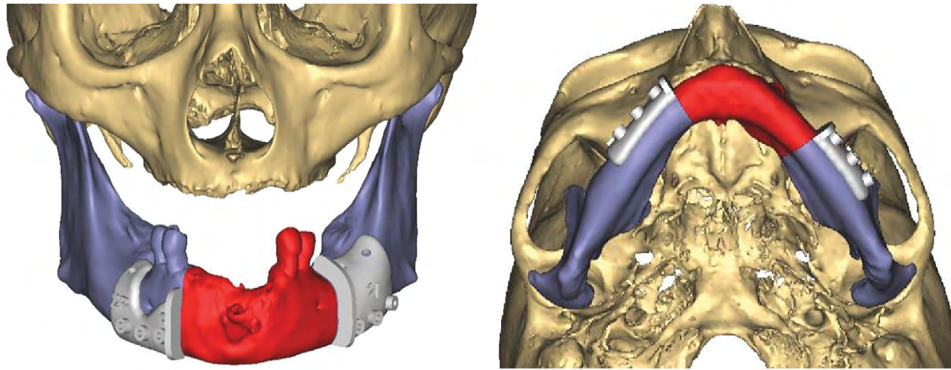


Fig. 1. CAD-CAM virtual planning performed using ProPlan CMF software (Materialise, Belgium)—Mandible resection guides.

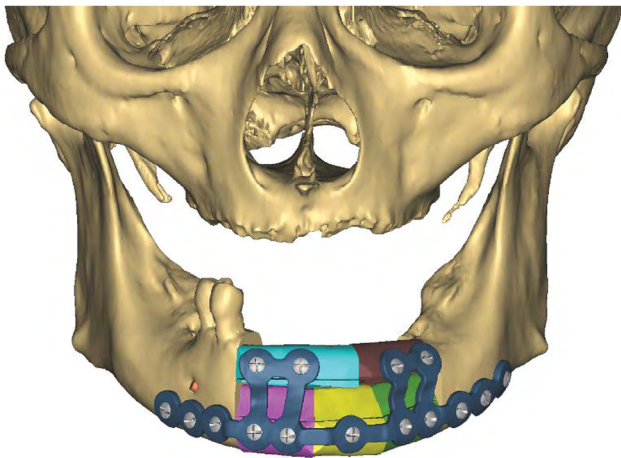


Fig. 2. Reconstruction plan and implant design (3-dimensional-printed 1.5-mm titanium plate): adjustment of vertical height, with application of axial split osteotomy to the upper segment to remove excess osseous bone in double-barrel 5-segmented FFF.

of the left facial vessels. Linear osteotomies and wedge osteotomies (mandibular resection and fibular segmentation) were performed using a piezoelectric device. No microvascular complications were observed, and there were no signs of partial or total flap loss (Fig. 4). Clinical and radiological stability was observed at both 6 and 12 months postoperatively. At 6 months postoperatively, 4 dental fixtures were positioned within the reconstructed jaw (See Video [online], which displays fibular bone tailoring based on planned cutting guides and flap inseting. Care must be taken to retain the periosteal attachments for all segments. In all types of fibula free flap (FFF) segmentation, maintenance of periosteal vascularization is necessary for reconstruction success. The pedicle must be loose to avoid kinking. Close attention is needed to prevent pedicle twisting).

In addition, we conducted a search of PubMed in September 2018 using the key words “split osteotomy” AND “fibula” AND “mandible” AND “reconstruction.” We found only 2 articles describing the application of sagittal

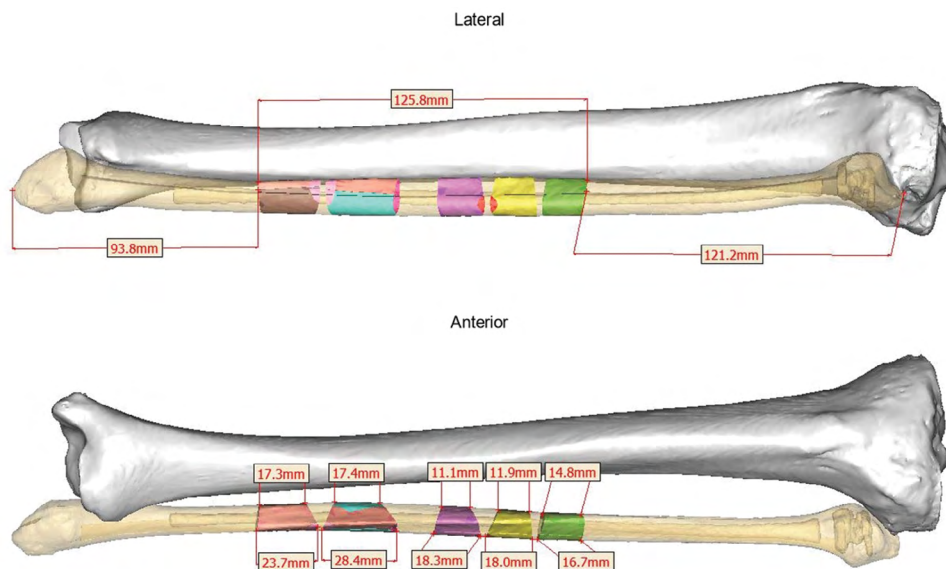


Fig. 3. Patient-specific left fibula graft (5 segments).

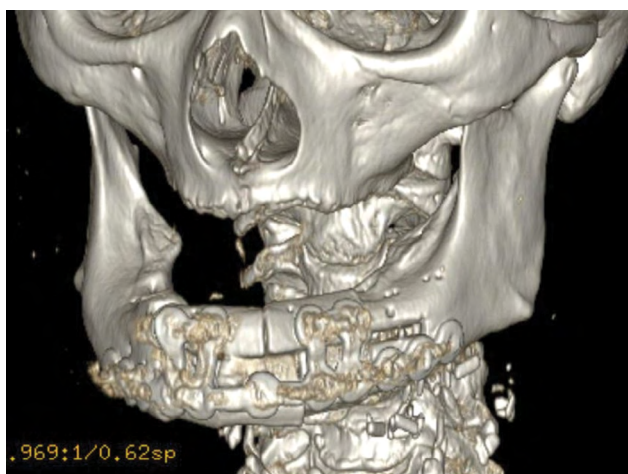


Fig. 4. Postoperative computed tomography (day 10).

split osteotomy and harvested fibula for mandibular angle reconstruction.

DISCUSSION

Dental rehabilitation following mandibular reconstruction improves mastication, speech, esthetics, and quality of life. The placement and osteointegration of dental implants require adequate bone quantity and quality.⁴ Although FFFs provide adequate cortical bone osseous tissue for dental implantation, the bony dimensions may be different from the native mandible, potentially resulting in failure of dental rehabilitation. Multiple methods can be used to achieve mandibular arch alignment, such as vertical osteodistraction,⁵ addition of a bone graft onlay with FFF,⁶ alignment of FFF to the upper (rather than lower) mandibular buttress (ie, alignment with the alveolar crest),⁷ and application of the double-barrel fibula technique.⁸ If the single-barrel fibula technique cannot obtain the necessary vertical dimension of bone, the double-barrel fibula technique is regarded as the best option.³ Alignment of the fibula with the alveolar crest may close the bony gap between the mandible and fibula but can also lead to unsatisfactory esthetic outcomes; in addition, augmentation of the single-barrel fibula technique with a nonvascularized onlay bone graft may lead to long-term bone resorption, causing implant failure.

When a single-barrel fibula is below the required vertical height of the native mandible, and the double-barrel fibula exceeds the required vertical height, we advocate vertical osteodistraction via either technique, with removal of excess osseous tissue from the lower portion of the upper segment to manage the discrepancy in bony dimensions between the native mandibular bone and the FFF. We prefer to use axial split osteotomy with the double-barrel fibula technique to obtain proper alignment; this technique provides immediate results when performed during primary surgery and thus does not delay long-term osteodistraction follow-up using serial radiological films; such a delay can be costly and may lower patient compliance. Notably, the axial split osteotomy provides 3 vascular cortical surfaces, thus ensuring stable dental

implantation. Axial split osteotomy can be performed with precision with the aid of CAD-CAM technology and a cutting guide.

Split osteotomy in the fibula was first described by Guyot et al,⁹ who applied sagittal osteotomy in the fibula (similar to Obwegeser-Dal Pont sagittal split osteotomy of the mandible) to remodel its shape during mandibular angle reconstruction in 4 patients. In a series of 10 patients, Longo et al¹⁰ successfully reconstructed the mandibular angle; 6-month follow-up assessments revealed normal relationships between the gonial angle and both the new fibular angle and the contralateral angle.

To the best of our knowledge, this is the first report of axial split osteotomy in harvested fibula during mandibular reconstruction, and further studies are needed to verify its stability. Axial split osteotomy and the removal of excess osseous tissue from the lower portion of the upper segment using the double-barrel fibula technique may represent an alternative immediate approach to avoid dimensional discrepancies between the native mandible and FFF, thus ensuring successful dental rehabilitation.

SUMMARY

FFF is considered the gold standard in mandibular reconstruction, and dental rehabilitation is a matter of concern among reconstructive surgeons seeking to improve health-related quality of life in these patients. FFF provides osseous tissue of cortical bone sufficient for dental implantation with relative bony dimensions discrepancy between the native mandible and neomandible. Axial split osteotomy is the best solution; either delayed axial split osteotomy with vertical distraction in single fibula, or axial split osteotomy with removal of excess bone from the lower portion of the upper segment in double-barrel fibula. Axial split osteotomy application in double-barrel fibula may be an alternative, immediate solution to avoid discrepancy in dimensions between the native mandible and free fibula flap, thus ensuring successful dental rehabilitation.

Giada Anna Beltramini, MD

Maxillofacial and Dental Unit of Fondazione IRCCS Ca' Granda Ospedale Maggiore Policlinico di Milano
35 via Francesco Sforza
20122 Milan, Italy
E-mail: giada.beltramini@hotmail.it

ACKNOWLEDGMENTS

The English in this document has been checked by at least 2 professional editors, both native speakers of English. For a certificate, please see <http://www.textcheck.com/certificate/Ofy6U2>.

REFERENCES

1. Shroff SS, Nair SC, Shah A, et al. Versatility of fibula free flap in reconstruction of facial defects: a center study. *J Maxillofac Oral Surg.* 2017;16:101–107.
2. Rohner D, Bucher P, Hammer B. Prefabricated fibular flaps for reconstruction of defects of the maxillofacial skeleton: planning, technique, and long-term experience. *Int J Oral Maxillofac Implants.* 2013;28:e221–e229.

3. Sozzi D, Novelli G, Silva R, et al. Implant rehabilitation in fibula-free flap reconstruction: a retrospective study of cases at 1-18 years following surgery. *J Craniomaxillofac Surg.* 2017;45:1655–1661.
4. Sumi Y, Hasegawa T, Miyaishi O, et al. Interface analysis of titanium implants in a human vascularized fibula bone graft. *J Oral Maxillofac Surg.* 2001;59:213–216.
5. Chiapasco M, Biglioli F, Autelitano L, et al. Clinical outcome of dental implants placed in fibula-free flaps used for the reconstruction of maxillo-mandibular defects following ablation for tumors or osteoradionecrosis. *Clin Oral Implants Res.* 2006;17:220–228.
6. Hayter JP, Cawood JI. Oral rehabilitation with endosteal implants and free flaps. *Int J Oral Maxillofac Surg.* 1996;25:3–12.
7. Smolka K, Kraehenbuehl M, Eggenesperger N, et al. Fibula free flap reconstruction of the mandible in cancer patients: evaluation of a combined surgical and prosthodontic treatment concept. *Oral Oncol.* 2008;44:571–581.
8. Bähr W, Stoll P, Wächter R. Use of the “double barrel” free vascularized fibula in mandibular reconstruction. *J Oral Maxillofac Surg.* 1998;56:38–44.
9. Guyot L, Richard O, Cheynet F, et al. “Axial split osteotomy” of free fibular flaps for mandible reconstruction: preliminary results. *Plast Reconstr Surg.* 2001;108:332–335.
10. Longo B, Nicolotti M, Ferri G, et al. Sagittal split osteotomy of the fibula for modeling the new mandibular angle. *J Craniofac Surg.* 2013;24:71–74.