original article

Annals of Oncology 21: 1173–1178, 2010
doi:10.1093/annonc/mdp455
Published online 27 October 2009

MACOP-B regimen in the treatment of adult Langerhans cell histiocytosis: experience on seven patients

E. Derenzini[1]*, M. P. Fina[1], V. Stefoni[1], C. Pellegrini[1], F. Venturini[1], A. Broccoli[1], L. Gandolfi[1], S. Pileri[2], S. Fanti[3], E. Lopci[3], P. Castellucci[3], C. Agostinelli[2], M. Baccarani[1] & P. L. Zinzani[1]

[1]*Department of Haematology and Medical Oncology 'L. & A. Seràgnoli'*; [2]*Unit of Haematopathology, Department of Haematology and Medical Oncology 'L. & A. Seràgnoli', University of Bologna and* [3]*Department of Nuclear Medicine, Sant'Orsola-Malpighi Hospital, Bologna, Italy*

Received 13 April 2009; revised 22 July 2009; accepted 11 August 2009

Background: Adult Langerhans cell histiocytosis (LCH) is a rare disease. The combination of vinblastine and prednisone, given in a 6-month course, is the standard of care but prospective randomized trials are lacking.
Patients and methods: We report our monocentric experience in the treatment of seven adult patients with multisystem (MS) LCH (n = 3) or single-system multifocal (SS-m) LCH (n = 4) with the short-course intensive chemotherapy regimen methotrexate, doxorubicin, cyclophosphamide, vincristine, prednisone and bleomicin (MACOP-B).
Results: The overall response rate was 100% [five complete response (CR), two partial response (PR)]. After a median follow-up of 6.5 years, four patients are in first continuous CR and three patients relapsed after 5, 8 and 62 months, respectively. Four patients were evaluated with positron emission tomography (PET) scan: all three PET-negative patients at the end of treatment had a long-lasting response with only one patient relapsing after 5 years. PET scan detected additional bone lesions at diagnosis in two of four patients, changing the treatment program in one of them.
Conclusions: MACOP-B regimen seems to be very active in the treatment of adult MS or SS-m LCH, with long-lasting responses in five of seven patients. PET scan merits further evaluation in the initial staging and in the evaluation of the response to chemotherapy.
Key words: chemotherapy, Langerhans cell histiocytosis, MACOP-B

introduction

Langerhans cell histiocytosis (LCH), formerly known as histiocytosis-X, is a rare disease, characterized by the infiltration of one or more organs by large, mononuclear, clonal CD1a-positive dendritic cells. All ages are affected, from birth to over 80 years of age. The incidence of adult LCH is lower than in children reaching one to two cases per million with a median age at presentation of 33 years [1].

The clinical presentation may vary from a localized and indolent disease to a disseminated disease involving various organs or systems with aggressive clinical course. The symptoms at diagnosis in adult LCH are related to the target organs affected: the main organs involved are lung, bone, skin and lymph nodes [2].

LCH is categorized into a single-system disease (localized or multifocal) and into a multisystem (MS) disease (involving various organs and systems). The MS disease is subdivided in two risk groups depending on the involvement of 'risk organs' such as hematopoietic system, lung, liver and spleen [3–5].

The prognosis of LCH depends on the extent of the disease, the type of organ involved and on the timing and quality of response to therapy.

Treatment strategies for LCH are related to the extent of the disease, with patients with limited stage disease having a good prognosis without systemic therapy (wait and see approach) and patients with single-system multifocal (SS-m) or MS disease usually requiring systemic therapy. To date, there is no optimal therapy for this rare disease, and the results particularly for multifocal or MS disease with risk organ involvement are suboptimal with a high rate of recurrences. The current therapeutical approach in adult LCH is drawn from the results of pediatric trials. As known, the Histiocyte Society established the combination of vinblastine and steroids as the standard therapy for children LCH, with an overall survival (OS) rate of 76% and 5-year event-free survival rate of 40% [6]. Based on the prognostic factors described in children with LCH, the main prognostic factors in adult LCH are considered to be risk organ involvement and lack of response after initial 6-week treatment.

A prospective International Clinical Trial, testing the therapeutic potential of the pediatric approach with vinblastine and steroids in adults with LCH, is currently under way.

*Correspondence to: Dr E. Derenzini, Department of Haematology and Medical Oncology 'L. & A. Seràgnoli', University of Bologna, Via Massarenti 9, 40138 Bologna, Italy. Tel: +39-0516363680; Fax: +39-0516364037; E-mail: enrico.derenzini@libero.it

Recently, Gadner et al. [7] reported the results of the LCH-II trial, showing that the intensification of standard vinblastine-based chemotherapy regimen with the addition of continuous prednisone and etoposide significantly improved OS and rapid responses in high-risk children with risk organ involvement.

So far, there are no published prospective trials about combination chemotherapy in adult LCH. Here we report our monocentric experience with the third-generation methotrexate, doxorubicin, cyclophosphamide, vincristine, prednisone and bleomicin (MACOP-B) regimen in the treatment of adult patients with multifocal/MS-LCH.

patients and methods

We retrospectively reviewed data of 10 consecutive and unselected adult patients affected by LCH, treated at our institution from 1995 to 2007. In absence of conclusive data coming from large randomized studies, from 1995 all adult patients affected by SS-m or MS-LCH were treated with the MACOP-B regimen for an institutional policy, and the protocol was approved by our institutional review board. Three patients with monofocal LCH underwent local treatment strategies (surgery in two patients and radiotherapy in one patient) and were not considered in this analysis. The other seven patients, affected by SS-m or MS-LCH, were treated with short-course intensive chemotherapy according to the MACOP-B protocol [8–10]. Median age at diagnosis was 27 years (range 18–62). Three patients were male and four were female. Four patients had SS-m LCH and three patients had MS-LCH with risk organ involvement. Characteristics of patients are showed in Table 1.

All patients were chemotherapy naive and had histologically proven SS-m or MS-LCH and age >18 years. All histological materials were reviewed by a pathologist (SP) from our institution. Diagnosis required demonstration of CD1a antigenic determinants on surface of the lesional cells and S-100 positivity, which was present in all patients [11].

staging and restaging procedures

All patients were initially evaluated with physical examination, complete endocrinological assessment, total-body computed tomography (CT) scan, complete skeletal X-ray, bone marrow biopsy and bone scan. All patients diagnosed after the year 2002 ($n = 4$) underwent also to positron emission tomography (PET) scan. Patients with bone lesions were also evaluated with magnetic resonance imaging (MRI). Restaging was done after 6 weeks of the 12-week chemotherapy and at least 4 weeks after the completion of the last chemotherapy course with total-body CT scan, skeletal X-ray, MRI and bone scan in case of bone lesions and PET scan when feasible (four patients).

Follow-up assessments were repeated every 3 months during the first year and every 6 months starting from the third to the fifth year and every 12–18 months for the further follow-up.

treatment protocol

All patients were treated with the MACOP-B regimen: cyclophosphamide 350 mg/mq and doxorubicin 50 mg/mq given i.v. on days 1, 15, 29, 43, 57 and 71; methotrexate 400 mg/mq on days 8, 36 and 64 followed by leucovorin rescue; vincristine 1.4 mg/mq on days 8, 22, 36, 50 and 64; bleomycin 10 mg/mq on days 22, 50 and 78 and prednisone 40 mg/mq on days 1–84.

All therapies were given in outpatient basis. All patients signed a written informed consent and the study was carried out according to the principles of the Declaration of Helsinki.

Adequate blood cell count (white blood cell >3000/μl, hemoglobin >10 g/dl, platelets >100 000/μl), renal and hepatic functions were required before every chemotherapy cycle. After the end of the chemotherapy courses, no maintenance therapy was given.

Table 1. Patients' characteristics

Patient No.	Age/sex	Pathological diagnosis	Prior therapy	Sites of disease at diagnosis	Symptoms at diagnosis	MS/SS-m	Risk organ involvement	Imaging techniques
1	23/female	Confirmed	–	Lymph nodes (inguinal and laterocervical)	Lymph node swelling; fever	SS-m	–	Skeletal X-ray; CT scan; bone scan; FDG–PET
2	62/male	Confirmed	–	Lymph nodes (submandibular) lung; tonsillar	Lymph node swelling; fever	MS	+	Skeletal X-ray; CT scan; bone scan
3	40/female	Confirmed	Radiotherapy	Bone (skull), diabetes insipidus	Diabetes insipidus; hypoacusia; fever	SS-m	–	MRI, CT scan, bone scan, skeletal X-ray; FDG–PET
4	27/male	Confirmed	–	Lymph nodes (abdominal), liver, spleen	Abdominal pain	MS	+	Skeletal X-ray; CT scan
5	18/female	Confirmed	–	Bone (skull, ribs)	Parietal bone pain and swelling	SS-m	–	Skeletal X-ray; CT scan; bone scan
6	23/male	Confirmed	Topical steroids	Bone (ribs, hip, femur, shoulder), lung (Figures 1 and 2)	Bone pain	MS	+	MRI, CT scan, bone scan, skeletal X-ray; FDG–PET
7	31/female	Confirmed	–	Bone (vertebrae: D4, D10) (Figure 3)	Bone pain	SS-m	–	MRI, CT scan, bone scan, skeletal X-ray; FDG–PET

MS, multisystem; SS-m, single-system multifocal; CT, computed tomography; FDG–PET, 2-[fluorine-18]fluoro-2-deoxy-D-glucose–positron emission tomography; MRI, magnetic resonance imaging.

response criteria

A complete response (CR) was defined as no evidence of active disease together with regression of signs and symptoms at physical examination and imaging studies (except for bone lesions since the complete reconstruction of the bone can take as long as 2 years, see next paragraph). Disease activity was defined as the presence of new symptomatic organ manifestations or local disease recurrence after initially successful therapy. A partial response (PR) was defined as a reduction of >50% of all measurable and active disease. Responses less than partial were considered as no response [6, 12, 13].

bone lesion criteria

Given the difficulty to evaluate the short-term response, in our clinical practice the response after 6 and 12 weeks of chemotherapy was assessed from a radiological, functional and clinical point of view. We considered the CR as the disappearance of contrast enhancement at CT scan, MRI and/or 2-[fluorine-18]fluoro-2-deoxy-D-glucose (FDG–PET), together with the disappearance of all symptoms related to bone lesions. Patients having a decrease in contrast enhancement at CT scan and/or MRI and/or a decrease >50% of standard uptake value or a decrease of the number of lesions >50% at FDG–PET scan, together with the disappearance of all symptoms related to bone lesions, were considered as partial responders [14, 15].

results

All patients completed the 12 planned cycles and were assessable for response after 6 weeks and at the end of the 12 weeks of chemotherapy. Individual responses and duration are shown in Table 2.

Response after 6 weeks of treatment were as follows: five CR (71%) (patients 1, 3, 4, 6 and 7: four of them confirmed also with PET scan) and two PR (29%) (patients 2 and 5); one patient with multiple bone lesions of the skull (patient 5) was considered as a partial responder, with a stability in the diameters of the lesions with no residual contrast enhancement at CT scan, together with the disappearance of bone pain and no further evidence of disease activity. This patient obtained a confirmed radiological CR after 12 weeks of therapy.

After the 12 weeks of therapy, five patients obtained a CR (71%) (patients 1, 3, 4, 5 and 7); two patients had a PR (patients 2 and 6): for patient 6, the PET scan carried out after the 12 weeks showed asymptomatic residual disease activity which was subsequently treated with local radiotherapy. This patient was scored as a partial responder (Figures 1 and 2).

Three patients [patient 2 (previous PR), patient 3 (previous CR) and patient 6 (previous PR)] relapsed after 8, 62 and 5 months, respectively. After a median follow-up of 6.5 years, five patients (71%) are alive and disease free without permanent consequences, two patients (29%) (patients 2 and 3) died after disease relapse despite salvage therapy. Patient 3 died of MS (bone and central nervous system) disease progression after second-line radiotherapy and patient 2 died of liver and pulmonary progression after failure of second-line chemotherapy including vinblastine and prednisone, respectively, 9.7 and 3.2 years after the initial diagnosis. Among the CR patients, four are in first continuous CR (+24, +72, +144 and +156 months, respectively).

Patient 6 underwent two courses of second-line ifosfamide, epirubicin, etoposide chemotherapy [16] and peripheral blood stem-cell mobilization and collection, obtaining a second CR;

Table 2. Rapid 6-week response, final response, FDG–PET evaluation and final outcome

Patient No.	6-Week evaluation	Interim PET	Time to symptoms disappearance (months)	Final post-therapy evaluation	Final post-therapy FDG–PET	Response duration (months)	Involved sites at disease relapse	Second-line therapy	Response to second-line therapy	Status
1	CR	CR	1.5	CR	CR	72+		–		Alive (CR)
2	PR	–	1.5	PR	–	8	Lung, liver	Vinblastine plus prednisone	PD	Dead (PD)
3	CR	CR	3	CR	CR	62	Femur, mastoid, CNS, ribs	Radiotherapy	Transient PR	Dead (PD)
4	CR	–	1.5	CR	–	144+		–		Alive (CR)
5	PR	–	3	CR	–	156+		–		Alive (CR)
6	CR	CR	1.5	PR	PR	5	Hip, ribs	IEV X 2 + ASCT (BEAM)	CR	Alive (II CR)
7	CR	CR	1.5	CR	CR	24+		–		Alive (CR)

FDG–PET, 2-[fluorine-18]fluoro-2-deoxy-D-glucose–positron emission tomography; CR, complete response, PR, partial response; PD, progressive disease; CNS, central nervous system, IEV, ifosfamide, epirubicin, etoposide; ASCT, autologous stem-cell transplantation; BEAM, BCNU, etoposide, cytarabine and melphalan.

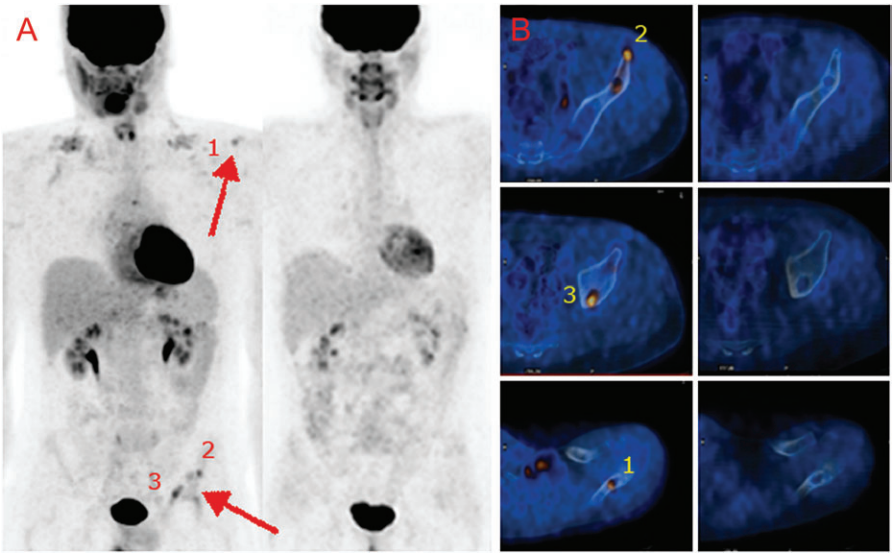

Figure 1. (A) 2-[Fluorine-18]fluoro-2-deoxy-D-glucose (FDG)–positron emission tomography (PET) scan of the patient 6 at initial staging (left), showing pathological hypermetabolic lesions of the left acromion (1), iliac bone (2) and acetabulum (3), and after six cycles of MACOP-B chemotherapy (right), showing a complete metabolic response with the disappearance of all lesions. (B) PET/computed tomography scan fusion images of the bone lesions of the same patient at baseline (left) and after six cycles of MACOP-B chemotherapy (right).

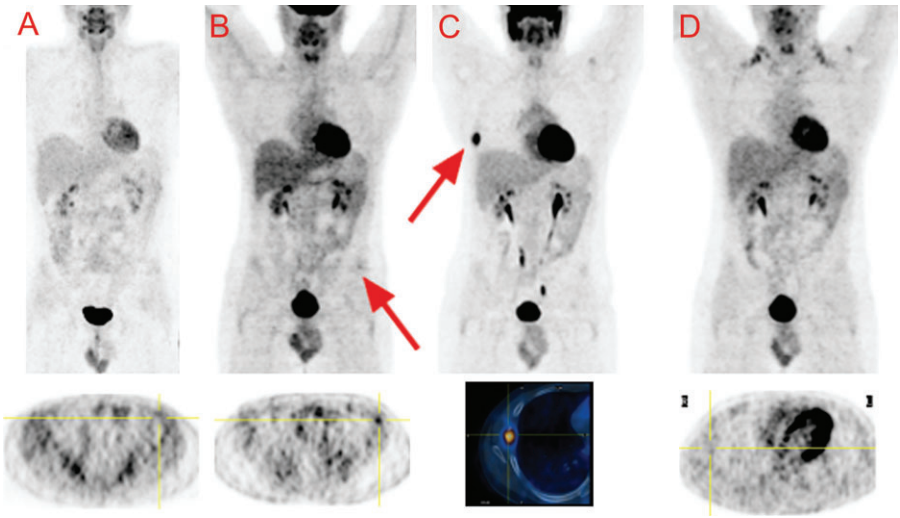

Figure 2. (A) 2-[Fluorine-18]fluoro-2-deoxy-D-glucose–positron emission tomography (FDG–PET) scan of the patient 6 after six cycles of MACOP-B chemotherapy. (B) FDG–PET scan after 12 cycles of MACOP-B chemotherapy showing residual disease at the iliac bone (red arrow). (C) Restaging FDG–PET scan showing relapse after radiotherapy with a right rib bone lesion (red arrow). (D) FDG–PET carried out after ASCT showing a complete metabolic response.

subsequently, autologous stem-cell transplantation (ASCT) according to the BEAM regimen (BCNU, etoposide, cytarabine and melphalan) [17, 18] was carried out, and now the patient is still in continuous second CR (Figure 2).

Toxic effects were mild and no patient developed any severe toxicity that required discontinuation of the treatment; only two patients had a treatment delay due to grade three neutropenia.

FDG–PET scan and outcome

Four (patients 1, 3, 6 and 7) of seven patients were assessed by PET scan at diagnosis, at week 6 (interim PET) and 1 month after the completion of the 12 planned chemotherapy cycles.

All four patients had a negative interim PET scan after 6 weeks of chemotherapy. One of these patients (patient 6) had a positive PET scan at the end of the treatment and then relapsed after 5 months but achieved a second CR after second-line chemotherapy and ASCT (Figures 1 and 2). Another patient (patient 3) with a negative PET at the end of the treatment relapsed after 5 years and died following recurrence. The other two patients are in continuous CR.

A negative interim PET was predictive of a long-lasting CR in three of four patients, with one of them who relapsed and died after >5 years (patient 3); the other patient (patient 6), who had a positive post-therapy PET, suffered from early relapse (5 months) (Figure 2). Considering the post-therapy PET

evaluation, all the three PET-negative patients maintained a long-lasting CR, with only one patient who relapsed and died after 5 years (patient 3).

PET scan allowed to detect additional bone lesions at diagnosis in two of four patients (patients 6 and 7). In patient 7, in whom a single lytic vertebral lesion was detected with CT scan and MRI, the detection of an additional vertebral lesion significantly changed the treatment approach, confirming the diagnosis of multifocal bone LCH and then making the patient eligible for systemic chemotherapy (Figure 3).

discussion

The MACOP-B regimen is a third-generation chemotherapy regimen conceived and employed for the treatment of aggressive non-Hodgkin's lymphomas [8–10]. This is an intensified weekly regimen, which is more intense but shorter (3 versus 6 months) than classical cyclophosphamide, doxorubicin, vincristine, prednisone (CHOP) regimen, which is still considered as the standard of care [19]. To date, the superiority of the MACOP-B regimen over standard CHOP regimen has not been demonstrated, but recent data show that there is a trend toward a survival and event-free survival advantage with the employ of dose-dense regimens in young patients (<60 years) with limited stage aggressive non-Hodgkin's lymphomas [20, 21].

LCH is a rare and heterogeneous disease entity, which may vary from an indolent long-lasting disease to a disseminated disease with aggressive clinical course and fatal outcome, mimicking an aggressive lymphoma. The current standard therapy for children with MS-LCH is a combination of steroids and vinblastine, according to the LCH-I trial [6], in which after an initial dose of corticosteroids and 24 weeks of vinblastine (6 mg/m^2 every week) were given. Therapy intensification with the addition of continuous corticosteroids and etoposide has been recently demonstrated to significantly improve the outcome of high-risk children with risk organ involvement (LCH-II trial) [7]. Whether longer treatment duration (12 months) can further improve these results is a matter of debate and it is currently being investigated in the LCH-III trial. In the evaluation of the results of the LCH trials [6, 7], the lack of rapid response after 6 weeks and the involvement of risk organs can be considered as the main adverse prognostic predictors [7, 22]. Thus, efforts have been made to intensify the induction phase to improve the outcome by increasing the rapid response rate.

Considering the LCH-I trial [6], the Dutch-German-Austrian Langerhans Histiocytosis study group (DAL-HX) studies [5, 23] and the LCH-II trial (arm B) [7], we can trace a trend toward an increased induction therapy intensification in the last two studies, with a corresponding increased rapid response rate (<60% in the LCH-I trial versus 79% in the DAL-HX trials versus 71% in the LCH-II trial). Despite the increased rapid response rates, the OS rates were similar, ranging from 76% to 80%. An improved outcome was thus observed only for patients with risk organ involvement in the LCH-II trial. To date, there are no published studies on adult patients with multifocal/MS-LCH, thus whether these findings can be translated to adult patients remains to be demonstrated.

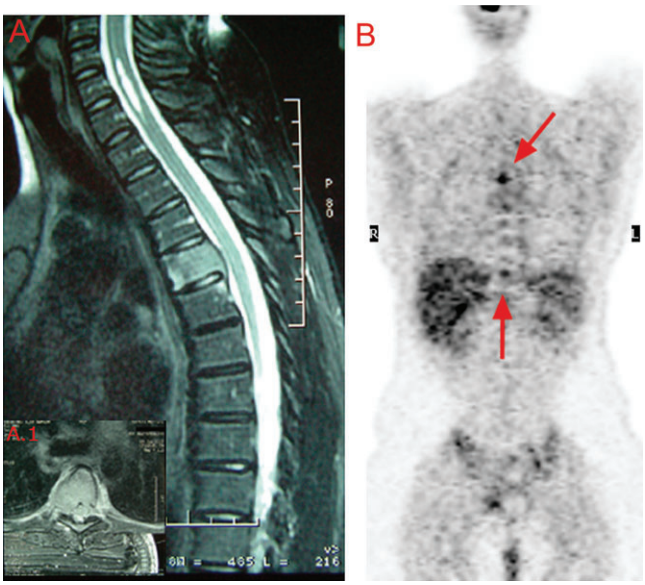

Figure 3. (A) Staging sagittal thoracic spine magnetic resonance imaging (MRI) of patient 7 showing a unique lesion with pathological contrast enhancement involving T 4 vertebral body, with initial posterior bulging and narrowing of the spinal canal. (A1) Axial MRI of the T 4 vertebral body lesion. (B) Staging 2-[fluorine-18]fluoro-2-deoxy-D-glucose–positron emission tomography of the same patient confirming the presence of the T 4 lesion and showing an additional bone lesion of the T 10 vertebral body (red arrows).

All adult patients treated with the MACOP-B regimen in the present study responded to chemotherapy at some time in the disease course (five CR and two PR), giving a CR rate of 71% and an overall response rate of 100%. The rapid response rate at 6 weeks was again 100% (five CR and two PR). Overall there were three recurrences (43%), with two patients who died of disease progression after recurrence, respectively, at 3.2 and 9.7 years after diagnosis; the other patient obtained a continuous second CR after second-line chemotherapy and ASCT. The other four patients are in first continuous CR after 24, 72, 144 and 156 months, respectively. In five patients, the symptoms of disease disappeared at the sixth week evaluation.

We obtained these promising results with a regimen which is very different from classical LCH chemotherapy protocols. First, the intensity of the MACOP-B induction therapy is greater than all previously investigated regimens for LCH: MACOP-B is more intense because of the weekly administration, and it is a polychemotherapy protocol containing five different drugs given together with the continuous administration of corticosteroids. Notably, neither vinblastine nor etoposide are included in the MACOP-B regimen, raising the question whether adding different drugs in the induction phase can improve the quality of the initial response.

Promising results were obtained with such approach by the Japan Histiocytosis Study Group [13], in which a combination of vincristine, doxorubicin and ara-C or cyclophosphamide was given as induction therapy. The results of this study confirm the relationship between rapid response rate and therapy intensification.

Second, no maintenance therapy was given after the end of the 12th week, whereas all the aforementioned LCH protocols had a maintenance phase after induction, for an overall duration ranging from 6 to 12 months. In our study, only one patient with a confirmed CR after the 12 cycles relapsed after 5 years. Thus, the quality of the CR would not have been improved by maintenance therapy in four of five patients.

Interestingly, the use of PET scan was able to detect additional bone lesions in two patients, modifying the therapeutic approach in one of them, according to the observations made by Phillips et al. [15]. A negative interim PET predicted a long-lasting response in three of four patients, whereas the only patient with a positive PET after the planned 12 cycles suffered from early relapse. These results support the extensive use of the PET scan at diagnosis, at week 6 and at the end of treatment. If the continuous steroid administration during chemotherapy could have affected the results of interim PET (four CR in four patients) is questionable, but in three of four cases, the CR at week 6 combined with the result of post-therapy PET.

In conclusion, in our study the MACOP-B polychemotherapy regimen showed a promising activity in adult LCH with manageable toxicity, confirming the relationship between the intensity of the induction phase and the rapid response rate. The quality of initial CR seems to be a crucial point determining the final prognosis, whereas the role of maintenance therapy is less clear, with only one of five patients relapsing after initial CR, despite no maintenance therapy, in the present study. Future efforts should be directed toward the enhancement of the induction phase by adding new drugs and increasing the dose intensity.

PET scan can be a very useful tool in the initial adult LCH evaluation, showing a high sensitivity particularly for bone lesions and sometimes determining a change in the therapeutic approach.

Finally, second-line chemotherapy and ASCT should be considered as salvage therapy for relapsed/refractory patients.

funding

BolognAIL.

references

1. Stockschlaeder M, Sucker C. Adult Langerhans cell histiocytosis. Eur J Haematol 2006; 76: 363–368.
2. Arico M, Girchikofsky M, Genereau T et al. Langerhans cell histiocytosis in adults. Report from the International Registry of the Histiocyte Society. Eur J Cancer 2003; 39: 2341–2348.
3. Chu T, D'Angio GJ, Favara BE et al. Histiocytosis syndromes in children. Writing Group of the Histiocyte Society. Lancet 1987; 2(8549): 41–42.
4. Howarth DM, Gilchrist GS, Mullan BP et al. Langerhans cell histiocytosis: diagnosis, natural history, management, and outcome. Cancer 1999; 85: 2278–2290.
5. Gadner H, Heitger A, Grois N et al. Treatment strategy for disseminated Langerhans cell histiocytosis. DAL-HX 83 Study Group. Med Pediatr Oncol 1994; 23: 72–80.
6. Gadner H, Grois N, Arico M et al. A randomized trial of treatment for multisystem Langerhans cell histiocytosis. J Pediatr 2001; 138: 728–734.
7. Gadner H, Grois N, Potscher U et al. Improved outcome in multisystem Langerhans cell histiocytosis is associated with therapy intensification. Blood 2008; 111(5): 2556–2562.
8. Klimo P, Connors JM. MACOP-B chemotherapy for the treatment of diffuse large-cell lymphoma. Ann Intern Med 1985; 102: 596–602.
9. Zinzani PL, Stefoni V, Tani M et al. MACOP-B regimen followed by involved-field radiation therapy in early-stage aggressive non-Hodgkin's lymphoma patients: 14-year update results. Leuk Lymphoma 2001; 42(5): 989–995.
10. Zinzani PL, Martelli M, De Renzo A et al. Primary mediastinal large B-cell lymphoma with sclerosis: a clinical study of 89 patients treated with MACOP-B chemotherapy and radiation therapy. Haematologica 2001; 86: 187–191.
11. Favara BE, Feller AC, Pauli M et al. Contemporary classification of histiocytic disorders. The WHO Committee on Histiocytic/Reticulum Cell Proliferations. Reclassification Working Group of the Histiocyte Society. Med Pediatr Oncol 1997; 29: 157–166.
12. Baumgartner I, von Hochstetter A, Baumert B et al. Langerhans'-cell histiocytosis in adults. Med Pediatr Oncol 1997; 28: 9–14.
13. Morimoto A, Ikushima S, Kinugawa N et al. Improved outcome in the treatment of pediatric multifocal Langerhans cell histiocytosis. Results from the Japan Langerhans Cell Histiocytosis Study Group-96 protocol study. Cancer 2006; 107: 613–619.
14. Goo HW, Yang DH, Ra YS et al. Whole-body MRI of Langerhans cell histiocytosis: comparison with radiography and bone scintigraphy. Pediatr Radiol 2006; 36: 1019–1031.
15. Phillips M, Allen C, Gerson P, McKlain K. Comparison of FDG-PET scans to conventional radiography and bone scans in management of Langerhans cell histiocytosis. Pediatr Blood Cancer 2009; 52: 97–101.
16. Zinzani PL, Tani M, Molinari AL et al. Ifosfamide, epirubicin, and etoposide regimen as salvage and mobilizing therapy for relapsed/refractory lymphoma patients. Haematologica 2002; 87: 816–821.
17. Philip T, Armitage JO, Spitzer G et al. High-dose therapy and autologous bone marrow transplantation after failure of conventional chemotherapy in adults with intermediate and high-grade non-Hodgkin lymphoma. N Engl J Med 1987; 316: 1493–1498.
18. Ichikawa K, Nomura S, Ishii K et al. Autologous stem cell transplantation for refractory Langerhans' cell histiocytosis. Bone Marrow Transplant 2007; 40: 807–808.
19. Fisher RI, Gaynor ER, Dahlberg S et al. Comparison of a Standard Regimen (CHOP) with three intensive chemotherapy regimens for advanced non-Hodgkin's lymphoma. N Engl J Med 1993; 328: 1002–1006.
20. Pfreundschuh M, Trumper L, Kloess M et al. Two-weekly or 3-weekly CHOP chemotherapy with or without etoposide for the treatment of young patients with good-prognosis (normal LDH) aggressive lymphomas: results of the NHL-B1 trial of the DSHNHL. Blood 2004; 104: 626–633.
21. Verdonck LF, Notenboom A, De Jong DD et al. Intensified 12-week CHOP (I-CHOP) plus G-CSF compared with standard 24-week CHOP (CHOP-21) for patients with intermediate-risk aggressive non-Hodgkin lymphoma: a phase 3 trial of the Dutch-Belgian Hemato-Oncology Cooperative Group (HOVON). Blood 2007; 109(7): 2759–2766.
22. Minkov M, Grois N, Heitger A et al. Response to initial treatment of multisystem Langerhans cell histiocytosis: an important prognostic indicator. Med Pediatr Oncol 2002; 39: 581–585.
23. Minkov M, Grois N, Heitger A et al. Treatment of multisystem Langerhans cell histiocytosis. Results of the DAL-HX 83 and DAL-HX 90 studies. DAL HX Study Group. Klin Padiatr 2000; 212: 139–144.