

Journal Pre-proof

MANAGEMENT OF PERSISTENT PNEUMOTHORAX WITH THORACOSCOPY AND BLEBS RESECTION IN COVID-19 PATIENTS

Alberto Aiolfi, MD, Tullio Biraghi, MD, Andrea Montisci, MD, Gianluca Bonitta, MSc, Giancarlo Micheletto, MD, Francesco Donatelli, MD, Silvia Cirri, MD, Davide Bona, MD

PII: S0003-4975(20)30604-4

DOI: <https://doi.org/10.1016/j.athoracsur.2020.04.011>

Reference: ATS 33730

To appear in: *The Annals of Thoracic Surgery*

Received Date: 15 April 2020


Revised Date: 21 April 2020

Accepted Date: 21 April 2020

Please cite this article as: Aiolfi A, Biraghi T, Montisci A, Bonitta G, Micheletto G, Donatelli F, Cirri S, Bona D, MANAGEMENT OF PERSISTENT PNEUMOTHORAX WITH THORACOSCOPY AND BLEBS RESECTION IN COVID-19 PATIENTS, *The Annals of Thoracic Surgery* (2020), doi: <https://doi.org/10.1016/j.athoracsur.2020.04.011>.

This is a PDF file of an article that has undergone enhancements after acceptance, such as the addition of a cover page and metadata, and formatting for readability, but it is not yet the definitive version of record. This version will undergo additional copyediting, typesetting and review before it is published in its final form, but we are providing this version to give early visibility of the article. Please note that, during the production process, errors may be discovered which could affect the content, and all legal disclaimers that apply to the journal pertain.

© 2020 by The Society of Thoracic Surgeons



**MANAGEMENT OF PERSISTENT PNEUMOTHORAX WITH THORACOSCOPY AND
BLEBS RESECTION IN COVID-19 PATIENTS**

Running head: Thoracoscopy in COVID-19 patients

Alberto Aiolfi MD, Tullio Biraghi MD, Andrea Montisci MD, Gianluca Bonitta MSc, Giancarlo Micheletto MD, Francesco Donatelli MD, Silvia Cirri MD, Davide Bona MD

1. Department of Biomedical Science for Health, Division of General Surgery, Istituto Clinico Sant' Ambrogio, University of Milan, Italy
2. Department of Anaesthesia and Intensive Care, Cardiothoracic Center, Istituto Clinico Sant' Ambrogio, University of Milan, Italy.
3. Chair of Cardiac Surgery, Department of Cardiothoracic Center, Istituto Clinico Sant' Ambrogio; University of Milan, Milano, Italy.

Corresponding Author

Alberto Aiolfi, MD

Via Luigi Giuseppe Faravelli, 16, 20149 Milan, Italy

E-mail: alberto.aiolfi86@gmail.com

Word count: 1452

Abstract

Several studies have been published describing the clinical and radiographic findings on the novel coronavirus (COVID-19) pneumonia. Therefore, there is currently a lack of pathologic data about its effects in intubated patients. Pneumothorax may occur rarely and results from a combination of fibrotic parenchyma with prolonged high-pressure ventilation. Chest drain represent the first line treatment. However, in case of persistent pneumothorax, thoracoscopy and bleb resection may be a feasible option to reduce air leak and improve ventilation. We report the cases of two COVID-19 patients successfully treated with thoracoscopy, bleb resection, and pleurectomy for persistent pneumothorax.

Keywords: COVID-19, Iatrogenic pneumothorax, Thoracoscopy

LIST OF ABBREVIATIONS

ARDS: Acute respiratory distress syndrome

COPD: Chronic obstructive pulmonary disease

COVID-19: Novel coronavirus

CRP: C-Reactive Protein

CT: Computed Tomography

GGO: ground-glass opacities

ICU: Intensive Care Unit

PEEP: Positive End-Expiratory Pressure

POD: Postoperative Day

WBC: White Blood Cells

Histologic data describing the pathologic changes of lung parenchyma caused by the COVID-19 are scarce [1]. A recent report showed edema, proteinaceous exudate, focal reactive hyperplasia of pneumocytes with patchy inflammatory cellular infiltration, and multinucleated giant cells [2]. This thickened, stiff tissue makes difficult for lungs to work properly and sustained-pressure ventilation may be necessary to obtain acceptable gas exchanges. In this setting, fibrotic parenchyma and pre-existing emphysematous blebs are prone to rupture with consequent risk of pneumothorax. Chest drains may be required however, in case of persistent air leak minimally invasive thoracoscopy with blebs resection may be indicated.

Case Reports

Patient 1

A 56-year old active smoker man was admitted to our hospital for fever, cough, and respiratory distress. Laboratory values were as follows: WBC: 18.200/mm³; neutrophils: 54%; CRP: 21.3 mg/dl. The nasopharyngeal swab was positive for COVID-19. The chest CT scan showed the presence of bilateral, peripheral GGO (**Figure 1**). Because the worsening dyspnea he was transferred to the ICU and intubated for acute respiratory insufficiency. Ventilator settings were: tidal volume 6 ml/kg, respiratory rate 20/min, and PEEP 10 cmH₂O. Five days after the intubation the chest X-Ray showed the presence of a left-side pneumothorax that was managed with 28 Fr pleural drain (**Figure 2**). Because the persistence of significant air-leak seven days after drainage, a left-side 3-ports thoracoscopy in the right lateral decubitus was planned. The inspection of the lung surface showed antracotic pigmentation with significant air-leak coming from small superficial blebs tears (**Supplementary Video**). Blebs were grasped and resected using Endo GIA™ 60mm Black (4.0-5.0mm) Tri-Staple™ Technology (Medtronic ®). The suture line was checked and reinforced with Human Fibrin Glue (TISSEEL – Baxter ®). No residual air leak was noticed and electrocautery scratch was performed for pleurodesis.

Patient 2

A 70-year old man, positive for COVID-19 and without comorbidities was transferred to our hospital for fatigue, fever, and respiratory distress. Laboratory values were WBC: 14.700/mm³; neutrophils: 48%; CRP: 16.1 mg/dl. The chest CT scan confirmed the presence of bilateral, sub pleural GGO. He was admitted to the ICU department and intubated for desaturation. Ventilator settings were: tidal volume 6 ml/kg, respiratory rate 20/min, and PEEP 8 cmH₂O. Two days after the intubation the chest X-Ray showed the presence of a left-side pneumothorax and a 28 Fr chest tube was placed. Three days after drainage the pneumothorax was persistent with substantial air leak. Three-ports left-side thoracoscopy in the right lateral decubitus was performed. The inspection of the left lung showed lingular blebs with air leak. Blebs resection with Endo GIA™ 60mm Purple (3.0-4.0 mm) Tri-Staple™ Technology (Medtronic ®) (**Figure 3**), suture line Fibrin Glue reinforcement (TISSEEL – Baxter ®), and pleural scratch were performed.

Both procedures were performed bed-side in the ICU department with non-selective low tidal volume ventilation. A 28 Fr chest tube was placed at the end of the procedure. On POD 1 there was no residual air leak and the chest X-ray did not show evidence of residual pneumothorax in both cases. Drains were removed on POD 2.

Comment

Reports on imaging findings of COVID-19 patients are now emerging [3]. The largest case series described multilobar involvement and rounded peripheral GGO while pneumothorax is rarely described as presentation sign (1%) [4]. Iatrogenic pneumothorax related to mechanical ventilation is a potentially lethal complication reported in up to 15% of ventilated patients [5]. It has been shown that iatrogenic pneumothorax occurs mostly in patients with an underlying lung diseases (i.e. COPD, ARDS, etc.) during the early phase of intubation [6]. As described for ARDS, lungs of

COVID-19 patients with significant interstitial involvement, seem physiologically small with low compliance and reduced elastance. This seems to be supported by recent pathologic findings showing edema, proteinaceous exudates, vascular congestion, and inflammatory changes [1]. Therefore, overinflation and high PEEP in such fibrotic and hypoelastic lungs may cause alveolar or pre-existing blebs rupture.

Iatrogenic pneumothorax in intubated COVID-19 patients is uncommon but may be seen with the progression of disease [3]. While chest tube placement should be considered as first line treatment, the persistence of air leak may constitute indication for low tidal volume two-lung ventilation thoracoscopy [7-8]. The procedure timing is unclear and was discussed multidisciplinary. In the first case, after chest tube placement, a wait-and-see strategy was preferred because doubts about the real effectiveness of the procedure. In the second case, a more aggressive and earlier operative attempt was planned. Although the procedure was successful in both, because the feeling of a stiffer parenchyma black cartridges were used for resection in the first case. Hence, we believe that early indication for thoracoscopy may be presumably better because the less traumatized, fibrotic, and inflamed interstitial tissues.

To the best of our knowledge, this is the first report that describes two COVID-19 patients treated with thoracoscopy and blebs resection for persistent pneumothorax. Treatment of pneumothorax in these patients is uncertain. While chest tube drainage seems indicated as first step treatment, thoracoscopy may be warranted in case of persistent or recurrent pneumothoraces. Timing of minimally invasive treatment is unclear, therefore early indication may presumably result in better outcomes and more effective air leak control.

References

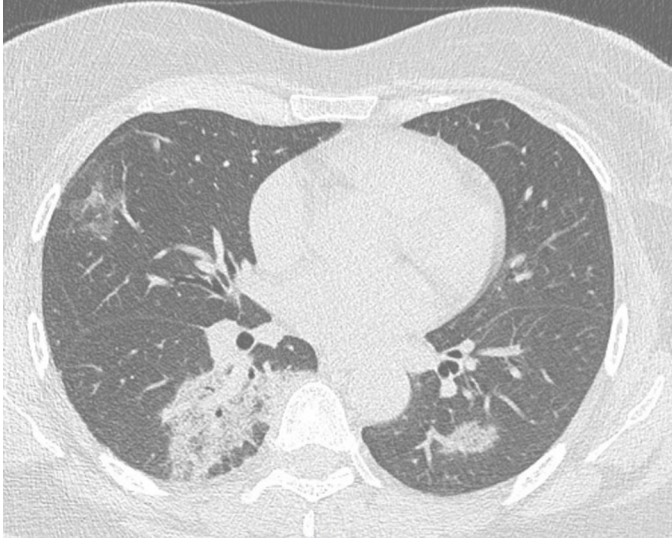1. Guan WJ, Ni ZY, Hu Y, Liang WH, Ou CQ, He JX, et al. Clinical Characteristics of Coronavirus Disease 2019 in China. *N Engl J Med*. 2020 Feb 28. doi: 10.1056/NEJMoa2002032.
2. Tian S, Hu W, Niu L, Liu H, Xu H, Xiao SY. Pulmonary Pathology of Early-Phase 2019 Novel Coronavirus (COVID-19) Pneumonia in Two Patients with Lung Cancer. *J Thorac Oncol*. 2020 Feb 28. pii: S1556-0864(20)30132-5.
3. Salehi S, Abedi A, Balakrishnan S, Gholamrezanezhad A. Coronavirus Disease 2019 (COVID-19): A Systematic Review of Imaging Findings in 919 Patients. *AJR Am J Roentgenol*. 2020 Mar 14:1-7.
4. Chen N, Zhou M, Dong X, Qu J, Gong F, Han Y, et al. Epidemiological and clinical characteristics of 99 cases of 2019 novel coronavirus pneumonia in Wuhan, China: a descriptive study. *Lancet*. 2020 Feb 15;395(10223):507-513. doi: 10.1016/S0140-6736(20)30211-7. Epub 2020 Jan 30.
5. Sassoon CS, Light RW, O'Hara VS, Moritz TE. Iatrogenic pneumothorax: etiology and morbidity. Results of a Department of Veterans Affairs Cooperative Study. *Respiration*. 1992;59(4):215-20.
6. Hsu CW, Sun SF. Iatrogenic pneumothorax related to mechanical ventilation. *World J Crit Care Med*. 2014 Feb 4;3(1):8-14.
7. Cerfolio RJ. Advances in thoracostomy tube management. *Surg Clin N Am* 2002;82:833-48.
8. Kim H, Kim HK, Choi YH, Lim SH. Thoracoscopic bleb resection using two-lung ventilation anesthesia with low tidal volume for primary spontaneous pneumothorax. *Ann Thorac Surg*. 2009 Mar;87(3):880-5.

FIGURE LEGENDS

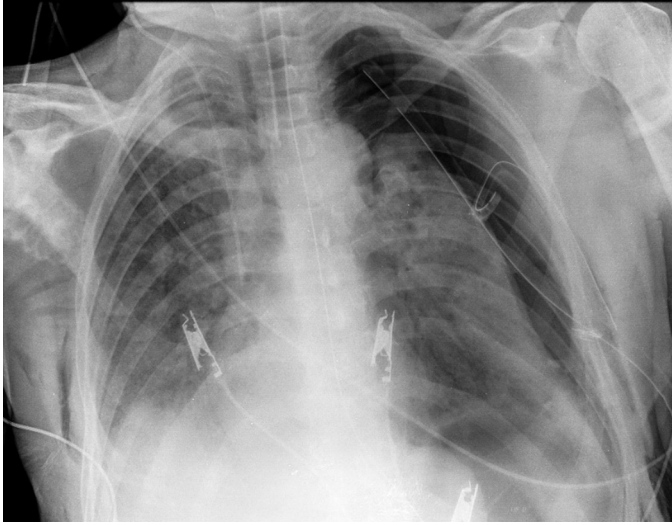
Figure 1. The chest Computed Tomography (CT) scan showed the presence of bilateral, peripheral ground-glass opacities (GGO).

Figure 2. The chest X-Ray showed the persistent left-side pneumothorax despite the presence of 28 Fr chest tube.

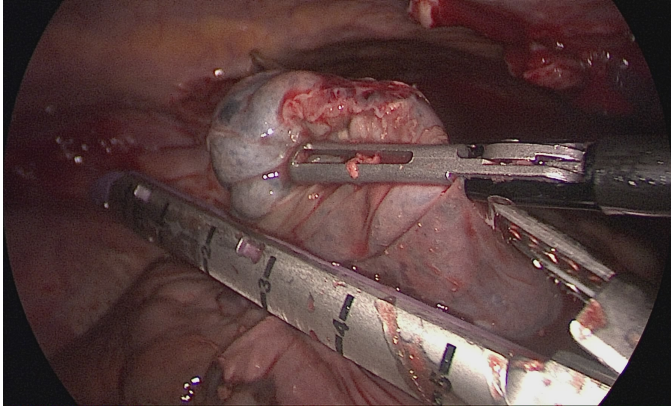
Figure 3. Blebs were grasped and resected using an Endo GIA™ Tri-Staple™ Technology (Medtronic ®). Suture line was reinforced with Fibrin Glue.



Journal Pre-proof



Journal Pre-proof



Journal Pre-proof