

THERAPY OF ENDOCRINE DISEASE

Endocrine dilemma: management of Graves' orbitopathy

Irene Campi*, Guia Vannucchi* and Mario Salvi

Graves' Orbitopathy Center, Endocrinology, Fondazione IRCCS Cà Granda, Milan, Italy
*(I Campi and G Vannucchi contributed equally to this work)

Correspondence
should be addressed
to M Salvi
Email
mario@mariosalvinet.it

Abstract

Management of Graves' orbitopathy (GO) must be based on the correct assessment of activity and severity of the disease. Activity is usually assessed with the Clinical Activity Score, whereas severity is classified according to a European Group On Graves' Orbitopathy (EUGOGO) consensus statement as mild, moderate-to-severe, and sight-threatening. Myopathic and chronic congestive forms are uncommon clinical presentations of GO. Restoration and maintenance of stable euthyroidism are recommended in the presence of GO.

In moderate-to-severe disease, steroids have been widely employed and have shown to possess an anti-inflammatory activity, but about 20–30% of patients are not responsive and present recurrence. Some novel immunosuppressors have already been employed in clinical studies and have shown interesting results, although the lack of randomized and controlled trials suggests caution for their use in clinical practice. Potential targets for therapy in GO are the thyroid-stimulating hormone and the insulin-like growth factor 1 receptor on the fibroblasts, inflammatory cytokines, B and T cells, and the PIK3/mTORC1 signaling cascades for adipogenesis. A recent open study has shown that tocilizumab, an anti-sIL-6R antibody, inactivates GO. Consistent reports on the efficacy of rituximab have recently been challenged by randomized controlled trials.

As the main goal of treatment is the well-being of the patient, the therapeutic strategy should be addressed to better suit the patient needs, more than improving one or more biological parameters. The increasing availability of new therapies will expand the therapeutic options for GO patients and allow the clinician to really personalize the treatment to better suit the patients' personal needs.

*European Journal of
Endocrinology*
(2016) **175**, R117–R133


Introduction

Graves' orbitopathy (GO) is an autoimmune inflammatory disorder involving the orbital tissues. It is the most common extrathyroidal manifestation of Graves'

disease (GD) (1). Although the pathogenesis of GO is not yet clarified, immunological cross-reactivity of thyroid and orbital antigens in muscular, connective,

Invited Author's profile

Dr Mario Salvi was trained initially in Italy. He carried out post-doctoral research at McGill University, where he began working in the field of thyroid autoimmunity with specific focus on the pathogenesis of Graves' disease and orbitopathy. He has been at the University of Milan since 2012. His center is a member of the European Group of Graves' Orbitopathy (EUGOGO) consortium, of which he was the Secretary from 2009 to 2015. Over the last 10 years he has developed an interest in immunotherapy for Graves' orbitopathy and has been carrying out clinical studies with rituximab and other immunosuppressors, in addition to multicenter trials of EUGOGO. He has published more than 140 papers and has more than 180 scientific communications at international meetings.



and adipose tissues is thought to play a key role (2). Different longitudinal studies confirm that spontaneous improvement or stabilization of eye symptoms and signs may occur when GO is mild (3, 4, 5, 6, 7, 8, 9). It is well known that GO has a self-limiting natural course, characterized by a phase of active inflammation of the orbital tissues, in which disease severity generally progresses, followed by a phase of stabilization and improvement of inflammation, as described by the 'Rundle curve' (10, 11) (Fig. 1A). Regression of the inflammatory process may lead to fibrosis, preventing affected tissues from returning to their previous healthy, functional state. Anti-inflammatory therapy is indicated in the first phase, whereas rehabilitative surgery may be indicated in the second one (12) (Fig. 1B). Thus, management of GO must be based on the correct assessment of activity and severity of the disease. In most European clinical centers, the activity is usually assessed with the Clinical Activity Score (CAS) (13) (Table 1), whereas severity is classified according to a recent consensus statement by EUGOGO as mild, moderate-to-severe, and sight-threatening (14).

Controversies in the diagnosis of GO

A CAS score $\geq 3/7$ at first examination or $4/10$ on follow-up visits (Table 1) qualifies the patients for a diagnosis of active GO. If the disease is of moderate-to-severe grade, the patient may benefit from the treatment with immunosuppressive therapies. There are, however, two clinical presentations of GO: a predominantly myopathic form, in which actual disease progression may not be correctly assessed with the CAS in the absence of soft tissue inflammation, and a chronic congestive form, in which soft tissue changes due to orbital congestion may be equivocally assessed as signs of active inflammation.

Myopathic GO

This form is characterized by prevalent muscle involvement resulting in motility impairment with few or absent soft tissue inflammatory signs. In patients affected with myopathic GO, diplopia often represents the first manifestation of ocular involvement and causes remarkable disability (15). To date, diplopia is qualitatively classified as absent, intermittent, inconstant or constant according to the Gorman Score (16), whereas a quantification of muscle defect may be studied by the field of binocular single vision, according to the Goldman or arc perimeter (17). A reduction of motility in any direction greater than

8° , in two subsequent ophthalmological examinations (1–3 months), is indicative of disease progression and accounts for one point of the CAS. This implies that the

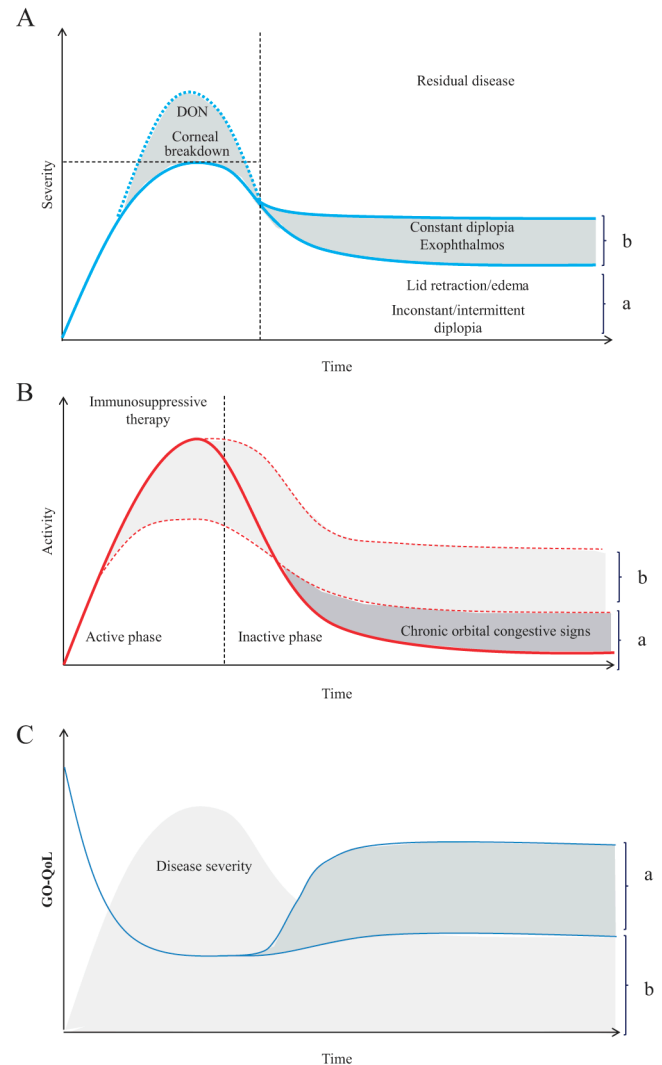


Figure 1

(A) The byphasic course of the severity of GO according to the model of Rundle (10). Dotted line shows the most severe forms of disease, generally responsive to urgent surgical decompression of the orbit. The degree of residual disease is related to successful (a) or unsuccessful (b) immunosuppression. (B) Proposed curve of the changes of activity in relation to the efficacy of immunosuppression. Shaded areas show successful (a) or unsuccessful (b) response to therapy. Persistence of chronic congestive signs may be observed even after disease inactivation. (C) Changes of quality of life (QoL) in relation to disease severity and successful (a) or unsuccessful (b) immunosuppressive therapy, based on the hypothesis that the QoL is inversely related to the degree of residual disease, as in (A).

Table 1 Inflammatory signs of active GO. The CAS is the sum of all items present. A CAS >3/7 or >4/10 indicates active GO.

Painful, oppressive feeling on or behind the globe, during the past 4 weeks	
Pain on attempted up, side, or down gaze, during the past 4 weeks	
Redness of the eyelid(s)	
Diffuse redness of the conjunctiva, covering at least one quadrant	
Swelling of the eyelid(s)	
Chemosis	
Swollen caruncle	
Increase of proptosis of ≥ 2 mm during a period of 1–3 months	
Decrease of eye movements in any direction $\geq 8^\circ$ during a period of 1–3 months	
Decrease of visual acuity of ≥ 1 line(s) on the Snellen chart (using a pinhole) during a period of 1–3 months	
Total	3/7 first visit 4/10 second visit

recent onset myopathic GO can be progressive, although inactive according to the CAS. This clinical situation is distinct from the change (usually worsening) of muscle ductions observed later during the scarring phase of GO, likely reflecting fatty degeneration and fibrosis typical of 'inactive' disease. In order to early identify progression in these patients with the myopathic form of GO, some authors have recently suggested to use quantitative MRI parameters, which have been shown to correlate with the changes of the CAS (18). This interesting approach, nevertheless, needs further validation before using it in daily clinical practice.

Chronic congestive GO

Congestion of the superior orbital vein plays an important role in the inflammatory phase, as demonstrated by computed tomography (19, 20, 21) and color Doppler imaging studies (22, 23, 24, 25). It has been suggested that in GO the success of the immunosuppressive treatment is the result of the effect not only on the autoimmune process but also on the reduction of orbital venous congestion. The impairment of superior orbital vein flow during the inflammatory phase of GO may otherwise persist, despite an effective outcome of immunosuppressive treatment (26). In these patients, ophthalmological signs of the persistent orbital vascular congestion may show similarities with some of those observed in active GO. Characteristic diagnostic criteria for the chronic congestive form may be eyelid edema, eyelid and conjunctival redness,

chemosis, and caruncle edema associated with disease duration >12 months, orbital CT scan evidence of increased muscle and adipose tissue volume, and unresponsiveness to immunosuppressive therapy (26).

If not properly recognized, the myopathic and chronic congestive forms of GO may bring about inadequate treatments, from either a too long 'wait-and-see' approach in the former group of patients or an unnecessary therapy in the latter. Disease duration is perhaps the most useful parameter for the differential diagnosis of these two particular subgroups of GO patients; as previously reported by Terwee and colleagues, GO duration >16 months was a significant predictor of no change and no response to therapy (27). A very recent study has shown that the increase of fibroadipose tissue is observed in untreated patients with a longer duration of disease (28), resulting in increasing proptosis and orbital fat volume mimicking disease progression. At the first clinical examination of a patient, it is very important to precisely assess the onset of the first symptoms and the diagnosis of disease, as this can provide essential contribution to the classification of GO. Indeed, the recent onset of diplopia in a purely myopathic form allows to hypothesize progressive GO. However, the presence of signs of orbital vascular congestion in a disease of long duration, perhaps in patients with previous immunosuppressive treatment, would be suggestive of chronic congestive disease. Once the diagnosis of inactive disease is made, surgery, orbital decompression and squint surgery are the only effective treatments to improve both congestive signs, by increasing the venous outflow of the orbit, and orthotropic vision (29).

Current guidelines for treatment of thyroid dysfunction in patients with GO

Prompt restoration and maintenance of stable euthyroidism are recommended in the presence of GO, because both hyperthyroidism and hypothyroidism have a negative impact on GO (30, 31). The optimal treatment of hyperthyroidism when GO is present is, however, a challenging dilemma (32). Table 2 summarizes the current evidence from the literature. Antithyroid drugs per se do not appear to negatively affect GO once euthyroidism has been restored. This is suggested by two prospective studies in which most patients during antithyroid drug treatment had stable GO (9, 33), with only a few cases of progression or improvement compatible with the natural history of the disease. GO may improve with

Table 2 Effect of treatments for Graves' hyperthyroidism on GO.

Finding	References
No impact on natural history of GO of antithyroid drugs	(30, 31, 32, 33, 34, 35)
Uncertain effect of thyroidectomy on progression of GO	(34, 35, 36)
<i>De novo</i> occurrence or progression of GO after RAI treatment with or without steroid prophylaxis	(39, 40, 41, 42, 43)
Postablation hypothyroidism induces progression of GO	(44, 45)
Stabilization of GO after total thyroid ablation (thyroidectomy followed by RAI treatment)	(46, 47, 48, 49, 50)

thyonamides only as a consequence of the restoration of euthyroidism (31) and the reduction of serum levels of thyroid-stimulating hormone (TSH) receptor (TSHR) antibodies (34). In addition, whichever regimen of antithyroid drug administration (titration vs block and replace) is employed, no difference on the GO outcome is observed.

Thyroidectomy, in particular near-total thyroidectomy, has been reported to be an effective treatment for hyperthyroidism (35). Scant literature exists on the effects of surgery on the course of GO, due to the difficulty in enrolling patients in studies in which surgery is planned to be the first-line therapy. One randomized clinical trial showed that the rate of *de novo* occurrence or progression of GO among patients submitted to thyroidectomy or medical therapy was similar but significantly lower than that observed after radioiodine (RAI) treatment (36).

RAI is an effective treatment for hyperthyroidism and represents the first-line treatment of hyperthyroidism in North America (35, 37). The majority of patients develop hypothyroidism within 1 year from RAI administration (38), although hypothyroidism may occur earlier, in some patients even 1 month after treatment. Although antithyroid drugs and thyroidectomy do not seem to affect the natural course of GO (36, 39), RAI treatment has been shown to be associated with worsening, or *de novo* occurrence, of GO in 5–15% of patients, mostly smokers (39, 40, 41). As 1989, it has been proposed that a short course of systemic corticosteroid treatment may prevent RAI-induced exacerbation of GO. Steroid prophylaxis has been carried out using very low doses of prednisone (0.2 mg/kg body weight), given 1 day after RAI therapy, and gradually tapered down and withdrawn after 6 weeks, which has been shown to be effective in a study in Italy (42) but not in a recent study on Japanese patients (43). Alternatively, methylprednisolone can be administered intravenously at the dose of 500 mg

weekly for 2 weeks followed by another two weekly infusions of 250 mg (cumulative dose of 1.5 g) (40). The onset of hypothyroidism should be promptly assessed and corrected, because late correction of post-RAI hypothyroidism has been shown to represent a relevant risk factor for reactivation or *de novo* occurrence of GO (44, 45). Finally, RAI can also be administered after surgery to attain total ablation of thyroid tissue, which might be beneficial for its complete removing of thyroid antigen(s) and autoreactive T lymphocytes likely involved in the pathogenesis of GO (1). Indeed, few studies have suggested that total thyroid ablation is more frequently associated with GO improvement than surgery alone (46, 47, 48, 49, 50). According to the recently published Italian guidelines on the treatment of hyperthyroidism in patients affected with GD and GO (51), total thyroid ablation may be suggested when trying to achieve earlier inactivation of GO that can be followed, when needed, by prompt rehabilitative surgery.

The optimal therapeutical approach for thyroid dysfunction in patients with GO remains a dilemma, and decisions in most cases still rely on expert endocrinologists' opinion, based on the age of patient, the degree of eye involvement, and, last but not least, the patients' expectations.

Treatment of moderate-to-severe orbitopathy

Immunosuppressive therapies exert their beneficial effects only in the active phase of GO, but not in the burnout disease where only rehabilitative surgery may improve the patient's eye appearance and function. In active progressive disease, medical treatment (immunosuppressive and/or anti-inflammatory) has the objective to reduce inflammation of eye muscles and orbital fibroadipose tissue, which may eventually reduce the need for significant subsequent rehabilitative surgery (52). According to a EUGOGO consensus paper, patients classified with moderate-to-severe GO usually have one or more of the following clinical signs: lid retraction ≥ 2 mm, moderate or severe soft tissue involvement, exophthalmos ≥ 3 mm above normal for race and gender, or inconstant or constant diplopia (52).

Glucocorticoids

High-dose systemic glucocorticoids (GCs) are currently the first-line treatment of active moderate-to-severe GO (3, 52, 53). Several randomized clinical trials found a

response rate of approximately 70–80% in patients treated intravenously and approximately 50–60% in those treated orally (53, 54). *In vitro* studies have shown that GCs decrease the production of glycosaminoglycans by orbital fibroblasts, downregulate some cytokine and antibody secretion, modulate T- and B-cell functions, and decrease trafficking of neutrophils and macrophages at the inflammation sites (14, 55) (Fig. 2). Treatment effectiveness much depends on interindividual variability, but this does not seem to be related to polymorphisms of the GC receptor (56).

Intravenous pulsed methylprednisolone is more effective (14, 46, 57, 61) and has a better safety profile compared with oral prednisone (60, 61, 62, 63, 64, 65). Different treatment schedules have been used, with cumulative doses ranging from 4.5 to 12 g and occasionally associated with oral GC interpulse or at the end of the protocol (3, 14, 54, 55, 56, 57, 58, 59). A recent multicenter randomized EUGOGO study has shown that a cumulative dose of 7.5 g of methylprednisolone is more effective than intermediate or lower doses (5 or 2.25 g respectively), although it is associated with more frequent adverse events (65). In particular, the high-dose regimen has a more significant and positive impact on eye muscle motility compared with lower doses. Therefore, a high-dose regimen may be used in more severe cases of GO, whereas an intermediate dose (5 g) regimen is recommended when patients have more moderate disease. In a recent paper, Vannucchi *et al.* (56) observed that in up to 70% of patients, GO becomes inactive after the first 6–8 weeks of intravenous GC treatment, without subsequent disease relapse. These findings suggest that in

these patients, steroids may be tapered off more rapidly with equal efficacy and better tolerability, compared with a full course of therapy. When deciding for therapy with intravenous methylprednisolone, a total cumulative dose of 8 g should not be exceeded. Morbidity and mortality of GC therapy in GO patients have been estimated to 6.5 and 0.6% respectively (63). Acute liver failure and cardiovascular events associated with GC administration may be fatal (56, 66, 67, 68, 69, 70). A marked increase of liver enzymes, often asymptomatic, is the most common adverse observed (71) and may be caused by a direct, dose-related toxic effect of intravenous methylprednisolone (IVMP) on hepatocytes. Preexistent viral hepatitis may be a risk factor for liver damage, whereas data on coexistent liver steatosis or diabetes are conflicting (67, 68). Autoimmune hepatitis may also occur during IVMP treatment (67, 68). Screening for virus markers and autoantibodies and clinical monitoring is suggested when deciding for high-dose IVMP therapy, in order to prevent complications (64). The concurrent use of statins has been shown to potentially induce liver damage in patients undergoing intravenous GC therapy for GO (72). Therefore, we suggest to consider temporary withdrawal of these medications at the time of steroid therapy, if the patient's clinical situation allows.

The major limitation of GC therapy is that 20–30% of patients are poorly responsive or unresponsive at all and that approximately 10–20% of patients present with disease relapse after drug withdrawal (65). A recent retrospective study has shown that responsive patients usually have inactivation of GO as early as 6–8 weeks from the beginning of GC therapy, whereas those who

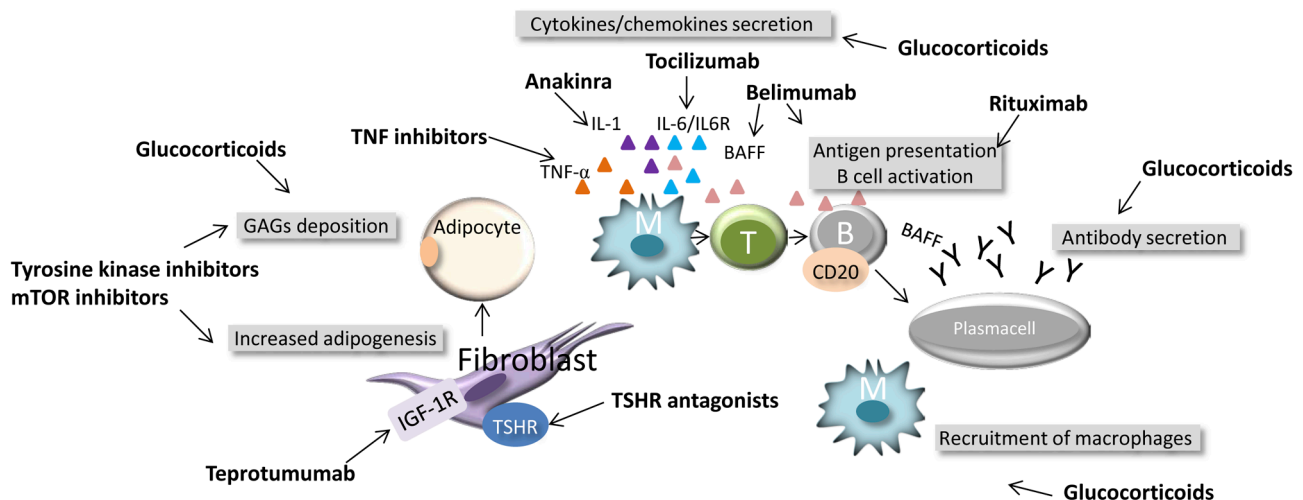


Figure 2

Potential targets for immunomodulatory treatments in active moderate-to-severe GO.

do not respond may be otherwise switched to other immunosuppressive treatments, alone or in combination with steroids (56).

What to do if GCs fail and moderate-to-severe GO is still active?

The management of patients in whom intravenous GC therapy gives only partial or inadequate response or of those with disease recurrence is a major challenge (57). There is no definitive agreement on how to treat these patients and the decision about a second-line treatment of active moderate-to-severe GO is based more on experts' opinion than on clinical evidence, due to the limited studies in the literature. First, such patients ought to be referred to specialized centers, because they are more prone to develop complications. Secondly, steroids may be administered in combination with other therapies, subsequently to their initial failure as monotherapy.

Combination therapy of oral GC and orbital radiotherapy could be considered an alternative, especially in the presence of muscle involvement and diplopia, and the two therapies have been shown to have synergistic effects (73, 74). Orbital radiotherapy has been shown in randomized clinical trials to be effective in improving diplopia (75, 76), with the exception of one randomized trial that has questioned its efficacy (77). In general, the administered dose is 20 Gray (Gy) per orbit fractionated in 10 daily doses over 2 weeks (78), but also 1 Gy per week over a 20-week period was shown to be equally effective and better tolerated (79). Irradiation therapy may induce mild and transient exacerbation of ocular inflammation that can be controlled by the concomitant administration of low-dose GCs (3, 80), whereas reports on long-term safety have been reassuring (81, 82). To date, there has been no evidence that intravenous GCs associated with orbital radiotherapy is more effective than steroids alone, but this interesting hypothesis will be challenged in a randomized multicenter clinical trial conducted among EUGOGO centers.

Oral GCs (starting dose, 0.5 mg/kg body weight of prednisone) have also been administered in combination with cyclosporine (5 mg/kg body weight) for 3 months (83, 84) to follow the initial intravenous GC treatment. Combined treatment with cyclosporine has been shown to allow reduction of GC doses and improvement of efficacy by maintaining therapy for a longer time.

These combined modalities of treatment imply retreatment with GC, a solution that may be proposed to patients with disease relapse, but hardly to nonresponders

to initial GC therapy. Furthermore, in patients with more severe GO undergoing a high-dose intravenous GC regimen with a total cumulative dose of GC of 7.5 g, safety concerns would prevent the clinician to plan for more steroids even if the patient had disease relapse after a significant therapeutic response to the initial GC treatment. It is also worth considering that some patients may elect not to repeat a GC-based regimen if they experienced a poor outcome with the first one. Are there real alternatives to immunosuppression with steroids in GO?

Novel targeted therapeutic modalities

Over the past decade, a series of studies have partly uncovered the mechanisms involved in GO pathogenesis, in particular those leading to cytokine-driven inflammation and increased retro-orbital adipogenesis. Based on these findings, evidence has emerged for treating progressive GO by directly targeting the specific reactions of immune and inflammatory processes that result in orbital tissue expansion and remodeling occurring in GO.

The potential property of novel immunomodulating agents is a disease-modifying and not just an anti-inflammatory effect (85). Figure 2 shows the antigens that may be specifically targeted in GO, the TSHR, the insulin-like growth factor 1 (IGF-1) receptor (IGF-1R), and the platelet-derived growth factor (PDGF) receptor, expressed on the fibroblasts, several cytokines that have been shown to be involved in disease progression and molecules regulating the immune function of antigen presentation, such as B and T cells (Fig. 2).

Most of these compounds are not yet available for clinical use in GO, and only a few of those have been employed in human studies and have shown to be potentially useful for treating patients. We will mainly focus on findings from clinical studies, which in most cases are open label studies with only few randomized controlled studies.

Low-molecular-weight TSHR ligands

Interestingly, low-molecular-weight TSHR ligands have been synthesized over the past few years. They interact with the TSHR as (i) TSHR agonists (that activate receptors), (ii) neutral antagonists (that inhibit receptor activation by agonists), and (iii) inverse agonists (that inhibit receptor activation by agonists and possess constitutive signaling). These molecules are studied for potential treatment of both GD and GO but have been

tested so far only *in vitro* on thyrocytes (86) and orbital fibroblasts (87) (Fig. 2).

Targeting the IGF-1R

The IGF-1R was shown to be coexpressed with the TSHR on orbital fibroblasts and fibrocytes (88), and *in vitro* blocking of the IGF-1R attenuates TSH-dependent signaling (89). Serum IGF-1R autoantibodies have been detected only in subgroups of patients with GO (90) and do not seem to occur with significant prevalence in active GO. A phase-II multicenter, placebo-controlled randomized clinical trial, conducted in the US and in Europe (91), is currently investigating a specific human monoclonal antibody that binds to the extracellular subunit domain of IGF-1R (Teprotumumab, RV 001, R1507). Binding of Teprotumumab to IGF-1R on fibrocytes was shown to attenuate TSH-dependent interleukin (IL)-6 and IL-8 expression and Akt phosphorylation (89) (Fig. 2). The ongoing study will hopefully provide the background for potential use in current clinical practice.

Modifiers of orbital tissue remodeling

Inhibitors of PIK3/mTORC1 cascades have been shown in an *in vitro* model of GO to reduce hyaluronan accumulation and adipogenesis (92). Although trials with first-generation inhibitors, such as wortmannin, LY294002, or rapamycin and its derivatives, have been stopped because of significant untoward effects, second-generation inhibitors are currently being used in clinical trials on patients with refractory cancers (93), but to date, no trials have been planned in autoimmune thyroid disease.

A PDGF-BB isoform of the PDGF receptor has recently been found expressed and increased in the orbital tissue of GO patients (94, 95, 96, 97). Its signaling on orbital fibroblast can be blocked by tyrosine kinase inhibitors, such as imatinib mesylate, nilotinib, and dasatinib, which has been shown to decrease *in vitro* the mRNA expression of hyaluronic synthetase 2 and IL-6 and IL-8 cytokines in orbital tissue from active GO (96) (Fig. 2). These compounds are invariably associated with serious side effects, and this may impact on their further development as effectively available therapeutic agents for GO.

Targeting cytokines/chemokines with monoclonal antibodies

The active phase of GO is driven by proinflammatory and Th1-derived cytokines, such as IL-6 and IL-1, and

IFN-gamma-induced chemokines, such as CXCL10, whereas Th2-derived cytokines, including IL-4, IL-5, and IL-10, prevail in the disease inactive phase (98).

TSHR antibodies have been shown to increase the expression of IL-1 receptor on orbital fibroblasts (99) synergistically with a smoke extract (100). Anakinra, an IL-1 receptor antagonist, may antagonize this mechanism, although this hypothesis has not been challenged in a clinical trial.

Most TNF inhibitors (etanercept, infliximab, adalimumab) have been widely and successfully used in autoimmune rheumatic diseases. Etanercept, a recombinant fusion protein of extracellular ligand-binding portion of the human TNF receptor, binds TNF and blocks the interaction with its receptors, thus preventing inflammatory responses. A small trial with etanercept was conducted on ten patients with active moderate-to-severe GO in 2005 by Paridaens *et al.* (101) resulting in improvement of soft tissue inflammatory signs in six patients, but no advantage over therapy with GC, in terms of overall efficacy and side effects.

Activation of the IL-6/sIL-6R system has been shown in active GO by Salvi and colleagues (102). An IL-6 receptor antagonist, tocilizumab has been successfully employed in rheumatic disease (103) and recently in an open clinical trial on 18 patients with GO refractory to GC treatment (104). Disease activity improved in all patients, proptosis values decreased in 72%, and ocular motility improved in 83%. One patient who had acute optic neuropathy was able to avoid orbital decompression. Currently, a placebo-controlled trial is testing the efficacy and safety of tocilizumab in patients with moderate-to-severe or sight-threatening GO, who did not respond to treatment with pulse steroids (phase III clinical trial, randomized, placebo-controlled, double-blind, parallel groups and multicenter study, EUDRACT 2010-023841-31). The results of this study are expected in the Spring of 2016.

The detection of increased serum BAFF concentrations in patients with either Hashimoto's thyroiditis (105) or GD, with and without orbitopathy (106), suggests that targeting BAFF may be an option in the management of GD. The therapeutic efficacy of belimumab, a monoclonal antibody against BAFF, has been challenged so far in patients with rheumatoid arthritis (RA) and systemic lupus erythematosus (SLE) with moderate clinical benefits, mostly in SLE. A randomized controlled trial of belimumab compared with intravenous steroids in active GO will start at the beginning of 2016 (EUDRACT 2015-002127-26). This treatment might affect the secretion of

TSHR autoantibodies as well as the B-cell-driven immune mechanisms involved with GO (Fig. 2).

Rituximab

Following the first report on a successful treatment of one patient with moderate-to-severe GO (107), several noncontrolled studies on the effects of rituximab (RTX) in GO have appeared in the literature (108). More recently, two randomized controlled trials in moderate-to-severe GO comparing RTX with placebo (109) and to steroids (110), respectively, have just been published. Although these trials provide conflicting results, most nonrandomized studies suggested that RTX might be beneficial for moderate-to-severe and active GO (110).

RTX is a mouse–human monoclonal antibody that targets CD20. This is a human B-lymphocyte-specific antigen is expressed on B cells in the various stages of maturation, but not on plasma cells (111). To date, it has been approved for clinical use in rheumatoid arthritis and antineutrophil cytoplasmic antibody-associated vasculitis. The rationale for using RTX in GO is the potential blockade of the generation of TSHR antibodies and of inflammatory cytokines. RTX may also block B-cell antigen presentation fairly rapidly upon depletion (112), but not the interaction between B and T cells, without therefore producing an effect on specific pathogenic autoantibodies (113) (Fig. 2).

To date, clinical studies have shown that RTX can be employed in patients with active moderate-to-severe GO either as first-line treatment or when IVMP therapy fails (114, 115, 116, 117, 118, 119).

Efficacy and dosing of RTX in GO

In earlier reports (107, 114), RTX has been employed in patients with active steroid-resistant GO. In an open study, RTX has subsequently been used as a first-line therapy in previously untreated patients (115). Disease inactivation at 24 weeks and lack of disease relapse up to 18 months of follow-up were observed, whereas GO is generally reported to relapse in 10–20% of patients after IVMP (65).

More recently, two randomized clinical trials have studied the efficacy of RTX in patients with active moderate-to-severe GO. Salvi *et al.* (110) have randomized 32 patients with either RTX or IVMP and studied the decrease of the CAS as a primary end point at 24 weeks. The CAS improved in 100% of patients after RTX compared with 69% after IVMP ($P < 0.001$). Disease never relapsed in patients treated with RTX,

but in five after IVMP. Neither treatment was effective on proptosis, palpebral aperture, and the total eye score for severity, but RTX proved to be more effective than steroids on motility and quality of life (QoL). The results of this work seem to suggest that RTX may act as a disease-modifying therapy, compared with steroids. Stan *et al.* (109) were not able to find RTX effective in treating active GO, compared with placebo. The study included 21 patients, of whom two developed optic neuropathy. Reasons for the conflicting results of these two studies are unknown, but differences in the patients' population included may have had an important impact on the treatment outcomes. A much longer GO duration (11.2 vs 4.5 months) in the trial of Stan *et al.* (109) may have resulted in treating patients with more congestive than active, inflammatory disease. A greater number of patients previously treated with steroids (40 vs 19%) and a lesser degree of motility involvement (mean diplopia score 2 vs 3.5) was infact included in their study. Failure of RTX treatment and subsequent progression to acute DON, similarly to the two patients herein described, was previously reported (120). One possible explanation is that subclinical DON was already present in these patients at the time of therapy and that the release of cytokines induced by RTX might have resulted in increased intraorbital edema with optic nerve compression. To date, RTX has been employed in another ten patients with dysthyroid optic neuropathy (DON) (116, 118, 121) and has induced significant improvement of vision. We therefore suggest caution in employing RTX in very severe GO, particularly if subclinical DON is suspected, until randomized controlled trials will provide evidence of its superiority over standard treatment with high-dose IVMP.

Optimal dosing schedules of RTX in GO are undetermined due to the lack of randomized trials. The infusion of 1000 mg twice, with a 2-week interval, has been employed as the standard treatment of RA and other autoimmune diseases. This dose has been initially used in most open studies (115, 118) and in case reports (107, 114) in patients with GO. Rapid and complete peripheral B-cell depletion following very low-dose (100 mg) RTX was shown in a study by Salvi *et al.* (112). These patients presented a rapidly occurring orbital tissue edema that spontaneously resolved within 60–90 min. Interestingly, these patients had complete GO inactivation within a few weeks, and therefore were cured with an RTX dose about 20 times lower than the standard dose suggested in systemic autoimmune disease. In addition, a dose finding analysis in the

clinical trial of Salvi *et al.* (110) has shown the efficacy of a single 500 mg RTX dose compared with two doses of 1000 mg.

Side effects of RTX

Studies addressing dose–response relationship in relation to its potential impact on the safety of RTX therapy are lacking. A recent meta-analysis of randomized studies has shown no significant differences in the primary clinical outcomes in RA when 1000 mg twice were compared with 500 mg twice, 2 weeks apart (122). Lower RTX doses also imply a significant reduction of treatment costs in chronic disease and the incidence of the initial infusion reactions, commonly described due to the chimeric nature of RTX. These reactions may be present in 10–30% of patients at first infusion and can be severe, but reversible (123). The underlying mechanism is the release of proinflammatory cytokines from macrophages, monocytes, lymphocytes, and NK cells. Infections have been reported as a major side effect mostly due to the hypogammaglobulinemia resulting from repeated RTX doses, although in recent large retrospective studies in patients with multiple autoimmunity severe infections were more frequently associated with treatment with steroids and other immunosuppressive agents than to hypogammaglobulinemia (124). The rare occurrence of progressive multifocal leukoencephalopathy has been reported in patients after RTX, although all of these patients had previously been treated with other immunosuppressive therapies, including cyclophosphamide, azathioprine, and even steroids, oral prednisone, or intravenous steroids (125).

Treatment of sight-threatening ophthalmopathy

Sight-threatening GO, known also as DON, is due to either compressive optic neuropathy, caused by severe hypertrophy of eye muscles at the orbital apex, or severe corneal damage resulting from severe corneal exposure, caused by excessive proptosis of the ocular globe and severe orbital congestion. In general, DON accounts for about 3–5% of all cases of GO and cigarette smoking, the male gender, restrictive strabismus, and rapidly progressive GO are considered risk factors for its development (73, 126). The diagnosis of DON is often challenging, in particular in more subclinical forms in which the progression to overt forms is not always straightforward. A survey among EUGOGO members in 2007 found that optic disc swelling,

impaired color vision, and CT scan evidence of apical crowding, with potential compression optic nerve, are the most useful predictive features (126). When present, optic disc swelling is very specific for DON, but patients may also have normal appearance of optic nerve due to the combination of edema and optic nerve atrophy.

The standard therapy for DON is urgent surgical orbital decompression, although a few studies have shown that as many as 40% of patients may respond to a course of high-dose IVMP within 1–2 weeks from the initial signs of visual deterioration (127, 128). The first-line treatment of DON should be a cycle of high-dose IVMP, either 500 or 1000 mg daily for three consecutive days, repeated 1 week later. An accurate clinical ophthalmological examination at 2 weeks is required to assess response and recovery of normal vision. At that point, this therapy may be continued with weekly IVMP pulses, up to a cumulative dose of 8 g, if GO is still in the active phase (127, 128). Some patients improve slowly, and the extent to which a full recovery of optic nerve function is attained is currently not known. Urgent orbital decompression is mandatory if patients do not respond to IVMP or when such treatment is contraindicated (125, 126).

Outcome of treatment and patient's satisfaction

GO has great influence on the QoL of affected patients, especially those with some degree of functional impairment such as diplopia or oppressive pain due to chronic orbital congestion. In particular, double vision severely affects the patients' QoL, as they experience difficulties in reading, driving, and daily working activities.

Medical treatments (immunosuppressive/anti-inflammatory) are beneficial only in the active phase of the disease with the objective to decrease inflammation and reduce progression of disease severity and, consequently, the need for subsequent rehabilitative surgery. The main goal of corrective surgery is to improve visual function, preserve the cornea, and reduce the eyelid retraction and the orbital congestion resulting from the expansion of the orbital content associated with GO. The optimal surgical treatment should be tailored to the patient-specific needs, in particular to the reduction of the degree of residual disease, to the anatomical characteristics of the orbit, and to the impact of GO on the patients' QoL.

De novo occurrence or worsening of diplopia is the most frequent complication of orbital decompression, particularly when the orbital floor is removed

(129, 130). The overall prevalence of postoperative diplopia in primary gaze is around 20% (131, 132) and may require additional surgery for strabismus. The aim of eye muscle surgery is to align the eyes and to restore single binocular vision in primary and reading positions. In order to achieve this goal, multiple operations may be necessary. However, the persistence of diplopia in extreme upgaze is common, but it is usually well tolerated with a negligible effect on overall visual function (133). Eyelid surgery is generally the last step of rehabilitation, and its aim is the correction of residual eyelid malpositions after medical treatment or orbital decompression (133).

According to a recent survey, the satisfaction of GO patients with therapy is often insufficient. It has been estimated that about 30% of patients attending a thyroid–eye clinic and nearly the half of those attending a nonspecialist clinic, are not fully satisfied with the treatments they have received. This suggests first that the late referral of patients to a joint thyroid–eye clinic may positively affect the final outcome of the disease (134), and secondly, that although medical and surgical techniques have improved over time, GO still has a marked negative effect on the patients' QoL even many years after treatment and that should be considered a chronic disease (135). This is probably due to the fact that the face is the seat of recognition for a human being, and living with a change in the appearance, as a result of any pathological condition, is always a challenging task (136).

Measurement of QoL in GO

The concept of QoL encompasses different aspects of physical and mental health, including health risks, functional status, social support, and socioeconomic status (137, 138, 139). For this reason, the quantification of QoL has become increasingly important in health care. The most common strategy for measuring the QoL consists in the administration of questionnaires or interviews, which investigate the patient's personal feeling about the disease or the therapy (140). A disease-specific questionnaire (GO-QoL) was developed by Terwee *et al.* in 1998 (141) and was the first instrument designed specifically to measure health related (HR)-QoL in patients with GO. It consists of 16 questions focusing on two specific subscales: 8 questions explore the visual impairment due to decreased visual acuity and/or diplopia; the remaining 8 questions describe the psychosocial effects of facial disfigurement. The use of GO-QoL has several advantages: first, it is simple, as

the score is easy to calculate, self-administered, and reproducible (142); secondly, the GO-QoL strongly correlates with the severity of GO manifestations, and, to a lesser extent, with disease activity (140) (Fig. 1C). Thirdly, the score is a reliable measure of the disease changes over time (142) or as a consequence of a medical (143) or surgical (144) treatment. In this context, a mean change of at least 6 points on one or both subscales suggests a significant change in daily functioning. For more aggressive therapies, a change of at least 10 points is usually considered as the minimal clinically relevant difference (143). The GO-QoL has been validated in different populations (145, 146, 147, 148) and translated into 15 different languages. For these reasons, QoL has become also suitable as an outcome measure of therapeutic response in RTC trials, and an improvement of GO-QoL has been shown in patients responsive to therapy.

In patients undergoing surgical treatments, the GO-QoL score increases significantly for both visual functioning and appearance after the first strabismus surgery in GO patients, showing the highest improvement for visual functioning-related questions. No differences were found in the QoL in patients previously submitted to orbital decompression compared with those who only underwent squint surgery (144). Medical treatment yields more conflicting results. Compared with oral steroids, IVMP has been associated with a significantly higher improvement either in the visual or in psychosocial functioning (5) (Fig. 1C). Conversely, in a recent study comparing IVMP and RTC, the analysis of the GO-QoL has shown significant improvement in IVMP patients for the appearance scale, but not for the visual functioning scale, whereas RTX was associated with an improvement in both scales (110).

These conflicting results may be addressed by studying the degree of the improvement of GO-QoL also considering the different therapeutic protocols and the different degrees of orbital involvement before therapy. In addition, a statistical correction for age, gender, and sociopsychological background must also be considered. Despite these limitations, it has been suggested that the routine administration of the GO-QoL in daily clinical practice is likely to improve the quality of care and to identify patients who need further psychological support (149).

These psychological implications of GO may also be further studied by means of a more specific questionnaire. In 2005, Yeatts *et al.* (140) developed a questionnaire of 105 questions investigating four areas (general and mental health, self-perception and social functioning,

general visual function, specific visual function) in relation to GO. They found that GO patients had a lower score for all measures of QoL compared with a control group. In particular, GO patients experience difficulties in the physical and mental components, the self-perception, and social desirability. Although the results were not age or gender specific, women appeared to have a stronger decline in self-perception compared with men. Compared with other visually impaired groups, GO patients had a score similar to those of patients with diabetic retinopathy or macular degeneration.

When measured with a questionnaire assessing general moods, such as the Medical Outcomes Study-24 (MOS-24), GO patients scored worse than controls or other groups of patients with chronic diseases as heart failure, diabetes, and emphysema (150). As depression and anxiety have been associated with GO (151), it has been suggested that psychological counseling or, when necessary, referral to a psychiatric service should be offered to GO patients (152) in order to improve the patients' QoL. Consistently with this hypothesis, in a study on 25 GO patients (153), Estcourt *et al.* showed an alteration of personality as a direct consequence of the physical changes associated with GO. In particular, the occurrence of frustration and depression, the concern on the potential effects of GO on job security and career progression, and anxiety have a great impact on the patients' coping strategies and even on the interactions with health-care professionals. Referral to a psychologist may be beneficial in selected patients, similar to what reported for other diseases causing physical disfigurement (154). However, it has been estimated that about 75% of patients with GO felt that they did not receive significant professional support for their psychological problems (153), suggesting that this issue is often overlooked by clinicians.

Patients with GO are also often involved with an important and life-affecting occupational impairment. In a survey on 192 workers affected with GO, nearly 20% of patients were unfit to work for a 1 month, whereas 3% were unfit for 4–6 months (155). The main determinants of working disability and the consequent impaired earning capacity are eye muscle motility disorders, whereas proptosis does not seem to influence the occupational status. This suggests that functional impairment plays a greater role in disability than in cosmetic implications (156). The occupational impairment has significant economic consequences of public health relevance, and for this reason, preventive care and rapid rehabilitation should be offered to GO patients (155).

Measurement of GO patient satisfaction

Rumsey *et al.* (154) observed that patients with a high level of frustration and depression were often disappointed with the final outcome of GO therapy, especially because they seemed to have unrealistic expectations of the outcome of surgery, with the desire to go back to the life they had before GO.

Patient satisfaction may be defined as the degree to which a patient feels to have received high-quality health care, and it is certainly a subjective measurement (157). This concept is complex as it is composed of satisfaction determinants, which are patient-dependent variables (such as background expectations, interaction expectations, action expectations, and finally outcome expectations), and satisfaction components, which are the actual kind of care that the patients received (158). Understanding the elements of patient satisfaction is important on many levels. As the main goal of a medical procedure is to provide high-quality of care that satisfies the needs of the patients, the measure of satisfaction allows to change the practice in order to improve the quality of care (157). This observation is especially relevant if we consider that nowadays patients have free access to medical information from the Internet, which influences the patients' expectations and desires. The improvement of the quality of care may increase the level of patients' expectation, causing a paradoxical decrease in the level of satisfaction (159).

For this reason, the idea that engaging patients and patient associations in decisions about the priority of interventions is a relevant factor in improving the quality of health service has grown importance in several fields of the medicine. The patient's perspective is multidimensional and has been measured through the use of patient-reported outcomes (PROs). A great amount of work using PROs has been performed in areas such as cancer care, where clinicians should balance the available treatments against their side effects and morbidity especially in patients in which long-term survival is not achievable. Important PROs that have been proposed in the field of oncology include the analyses of three main areas: QoL, current health state, and satisfaction with care (160).

The GO-QoL was specifically designed for patients with GO and has been validated as a PRO in measuring the benefits of the current approach to GO management. There are still several critical points, from the patients' point of view, along the way of improving disease care. A first attempt to engage patients and public in a discussion on GO unmet needs has been recently performed by

Perros and coworkers in a 2-day event, planned by a committee of professional and patient-led organizations; the patients disclosed that psychological elements should be one of the priorities for future research (161).

Conclusions

In patients, the improvement of satisfaction is associated with an improvement of the QoL. In addition, the incorporation of patient satisfaction as a part of the evaluation of treatment quality may also influence the population's health and the health-care policies. In fact, progress in patient satisfaction is associated with cost saving as a result of fewer complaints, second opinions, and repeated investigations (157).

As the main goal of treatment is the well-being of the patient, the therapeutic strategy should be addressed to better suit the patient needs, more than improving one or more biological parameters.

Therefore, the measurement of QoL and patient satisfaction is mandatory. In our experience, these topics have been partially overlooked by clinical researchers in the field of GO, also probably in relation to the persistently unsatisfactory outcome of medical treatment modalities in this disease. It is predictable that in the near future, the increasing availability of new therapies will expand the therapeutic options for GO patients and allow clinician to really personalize the treatment protocols to better suit the patients' personal needs. In this context, the engagement of the patient association and patients in such decisions will be an invaluable opportunity for improving the quality of care in GO.

Declaration of interest

The authors declare that there is no conflict of interest that could be perceived as prejudicing the impartiality of the research reported.

Funding

This work was supported in part by MIUR, Roma, and by Fondazione Cà Granda, IRCCS, Milano, Italy.

References

- Bartalena L, Pinchera A & Marcocci C. Management of Graves' ophthalmopathy: reality and perspective. *Endocrine Review* 2000 **21** 168–199. (doi:10.1210/edrv.21.2.0393)
- Bahn RS. Graves' ophthalmopathy. *New England Journal of Medicine* 2010 **25** 726–738. (doi:10.1056/NEJMra0905750)
- Menconi F, Profilo MA, Leo M, Sisti E, Altea MA, Rocchi R, Latrofa F, Nardi M, Vitti P, Marcocci C *et al.* Spontaneous improvement of untreated mild Graves' ophthalmopathy: Rundle's curve revisited. *Thyroid* 2014 **24** 60–66. (doi:10.1089/thy.2013.0240)
- Marcocci C & Marinò M. Treatment of mild, moderate-to-severe and very severe Graves' orbitopathy. *Best Practice and Research Clinical Endocrinology and Metabolism* 2012 **26** 325–337. (doi:10.1016/j.beem.2011.11.005)
- Perros P, Crombie AL & Kendall-Taylor P. Natural history of thyroid associated ophthalmopathy. *Clinical Endocrinology* 1995 **42** 45–50. (doi:10.1111/j.1365-2265.1995.tb02597.x)
- Streeten DH, Anderson GH Jr, Reed GF & Woo P. Prevalence, natural history and surgical treatment of exophthalmos. *Clinical Endocrinology* 1987 **27** 125–133. (doi:10.1111/j.1365-2265.1987.tb00848.x)
- Noth D, Gebauer M, Muller B, Burgi U & Diem P. Graves' ophthalmopathy: natural history and treatment outcomes. *Swiss Medical Weekly* 2001 **131** 603–609.
- Marcocci C, Kahaly GJ, Krassas GE, Bartalena L, Prummel M, Stahl M, Altea MA, Nardi M, Pitz S, Boboridis K *et al.* European Group on Graves' orbitopathy selenium and the course of mild Graves' orbitopathy. *New England Journal of Medicine* 2011 **364** 1920–1931. (doi:10.1056/NEJMoa1012985)
- Tanda ML, Piantanida E, Liparulo L, Veronesi G, Lai A, Sassi L, Pariani N, Gallo D, Azzolini C, Ferrario M *et al.* Prevalence and natural history of Graves' orbitopathy in a large series of patients with newly diagnosed Graves' hyperthyroidism seen at a single center. *Journal of Clinical Endocrinology and Metabolism* 2013 **98** 1443–1449. (doi:10.1210/jc.2012.3873)
- Rundle FF & Wilson CW. Development and course of exophthalmos and ophthalmoplegia in Graves' disease with special reference to the effect of thyroidectomy. *Clinical Science* 1945 **5** 177–194.
- Dolman PJ. Evaluating Graves' orbitopathy. *Best Practice and Research Clinical Endocrinology and Metabolism* 2012 **26** 229–248. (doi:10.1016/j.beem.2011.11.007)
- Wiersinga WM. Advances in medical therapy of thyroid-associated ophthalmopathy. *Orbit* 1996 **15** 177–186. (doi:10.3109/01676839609150235)
- Mourits MP, Prummel MF, Wiersinga WM & Koorneef L. Clinical activity score as a guide in the management of patients with Graves' ophthalmopathy. *Clinical Endocrinology* 1997 **47** 9–14. (doi:10.1046/j.1365-2265.1997.2331047.x)
- Bartalena L, Baldeschi L, Dickinson A, Eckstein A, Kendall-Taylor P, Marcocci C, Mourits M, Perros P, Boboridis K, Boschi A *et al.* Consensus statement of the European Group on Graves' Orbitopathy (EUGOGO) on management of GO. *European Journal of Endocrinology* 2008 **158** 273–285. (doi:10.1530/EJE-07-0666)
- Nunery WR, Martin RT, Heinz GW & Gavin TJ. The association of cigarette smoking with clinical subtypes of ophthalmic Graves' disease. *Ophthalmic Plastic and Reconstructive Surgery* 1993 **9** 77–82. (doi:10.1097/00002341-199306000-00001)
- Bahn RS & Gorman CA. Choice of therapy and criteria for assessing treatment outcome in thyroid-associated ophthalmopathy. *Endocrinology Metabolism Clinics of North America* 1987 **16** 397–407.
- Sullivan TJ, Kraft SP, Burack C & O'Reilly C. A functional scoring method for the field of binocular single vision. *Ophthalmology* 1992 **99** 575–581. (doi:10.1016/S0161-64209231931-1)
- Politi LS, Godi C, Cammarata G, Ambrosi A, Iadanza A, Lanzi R, Falini A & Bianchi Marzoli S. Magnetic resonance imaging with diffusion-weighted imaging in the evaluation of thyroid-associated orbitopathy: getting below the tip of the iceberg. *European Radiology* 2014 **24** 1118–1126. (doi:10.1007/s00330-014-3103-3)
- Monteiro ML, Goncalves AC, Silva CT, Moura JP, Ribeiro CS & Gebrim EM. Diagnostic ability of Barrett's index to detect dysthyroid optic neuropathy using multidetector computed tomography. *Clinics* 2008 **63** 301–306. (doi:10.1590/S1807-59322008000300003)
- Hudson HL, Levin L & Feldon SE. Graves exophthalmos unrelated to extraocular muscle enlargement. Superior rectus muscle

- inflammation may induce venous obstruction. *Ophthalmology* 1991 **98** 1495–1499. (doi:10.1016/S0161-64209132099-2)
- 21 Nugent RA, Belkin RI, Neigel JM, Rootman J, Robertson WD, Spinelli J & Graeb DA. Graves orbitopathy: correlation of CT and clinical findings. *Radiology* 1990 **177** 675–682. (doi:10.1148/radiology.177.3.2243967)
 - 22 Nakase Y, Osanai T, Yoshikawa K & Inoue Y. Color Doppler imaging of orbital venous flow in dysthyroid optic neuropathy. *Japanese Journal of Ophthalmology* 1994 **38** 80–86.
 - 23 Alp MN, Ozgen A, Can I, Cakar P & Gunalp I. Colour Doppler imaging of the orbital vasculature in Graves' disease with computed tomographic correlation. *British Journal of Ophthalmology* 2000 **84** 1027–1030. (doi:10.1136/bjo.84.9.1027)
 - 24 Somer D, Ozkan SB, Ozdemir H, Atilla S, Soylev MF & Duman S. Colour Doppler imaging of superior ophthalmic vein in thyroid-associated eye disease. *Japanese Journal of Ophthalmology* 2002 **46** 341–345. (doi:10.1016/S0021-5155(02)00485-9)
 - 25 Monteiro ML, Angotti-Neto H, Benabou JE & Betinjane AJ. Color Doppler imaging of the superior ophthalmic vein in different clinical forms of Graves' orbitopathy. *Japanese Journal of Ophthalmology* 2008 **52** 483–488. (doi:10.1007/s10384-008-0594-y)
 - 26 Verity DH & Rose GE. Acute thyroid eye disease (TED): principles of medical and surgical management. *Eye* 2013 **27** 308–319. (doi:10.1038/eye.2012.284)
 - 27 Terwee CB, Prummel MF, Gerding MN, Kahaly GJ, Dekker FW & Wiersinga WM. Measuring disease activity to predict therapeutic outcome in Graves' ophthalmopathy. *Clinical Endocrinology* 2005 **62** 145–155. (doi:10.1111/cen.2005.62.issue-2)
 - 28 Potgieser PW, Wiersinga WM, Regensburg NI & Mourits MP. Some studies on the natural history of Graves' orbitopathy: increase in orbital fat is a rather late phenomenon. *European Journal of Endocrinology* 2015 **173** 149–153. (doi:10.1530/EJE-14-1140)
 - 29 Onaran Z, Konuk O, Oktar SO, Yucel C & Unal M. Intraocular pressure lowering effect of orbital decompression is related to increased venous outflow in Graves' orbitopathy. *Current Eye Research* 2014 **39** 666–672. (doi:10.3109/02713683.2013.867355)
 - 30 Karlsson FA, Dahlberg PA, Jansson R, Westermark K & Enoksson P. Importance of TSH receptor activation in the development of severe endocrine ophthalmopathy. *Acta Endocrinologica* 1989 **121** 132–141.
 - 31 Prummel MF, Wiersinga W, Mourits M, Koornneef M, Berghout A & van der Gaag R. Amelioration of eye changes of Graves' ophthalmopathy by achieving euthyroidism. *Acta Endocrinologica* 1989 **121** 185–189.
 - 32 Bartalena L. The dilemma of how to manage Graves' hyperthyroidism in patients with associated orbitopathy. *Journal of Clinical Endocrinology and Metabolism* 2011 **96** 592–599. (doi:10.1210/jc.2010-2329)
 - 33 Bartalena L, Marcocci C, Bogazzi F, Manetti L, Tanda ML, Dell'Unto E, Bruno-Bossio G, Nardi M, Bartolomei MP, Lepri A *et al.* Relation between therapy for hyperthyroidism and the course of Graves' ophthalmopathy. *New England Journal of Medicine* 1998 **338** 73–78. (doi:10.1056/NEJM199801083380201)
 - 34 Laurberg P, Wallin G, Tallstedt L, Abraham-Nordling M, Lundell G & Topping O. TSH-receptor autoimmunity in Graves' disease after therapy with anti-thyroid drugs, surgery, or radioiodine: a 5-year prospective randomized study. *European Journal of Endocrinology* 2008 **158** 69–75. (doi:10.1530/EJE-07-0450)
 - 35 Bartalena L. Diagnosis and management of Graves disease: a global overview. *Nature Reviews Endocrinology* 2013 **9** 724–734. (doi:10.1038/nrendo.2013.193)
 - 36 Tallstedt L, Lundell G, Topping O, Wallin G, Ljunggren JG, Blomgren H & Taube A. The Thyroid Study Group Occurrence of ophthalmopathy after treatment for Graves' hyperthyroidism. *New England Journal of Medicine* 1992 **326** 1733–1738.
 - 37 Burch HB, Burman KD & Cooper DS. A survey of clinical practice patterns in the management of Graves' disease. *Journal of Clinical Endocrinology and Metabolism* 2012 **97** 4549–4558. (doi:10.1210/jc.2012-2802)
 - 38 Bogazzi F, Giovannetti C, Fessehatsion R, Tanda ML, Campomori A, Compri E, Rossi G, Ceccarelli C, Vitti P, Pinchera A *et al.* Impact of lithium on efficacy of radioactive iodine therapy for Graves' disease: a cohort study on cure rate, time to cure, and frequency of increase in serum thyroxine after antithyroid drug withdrawal. *Journal of Clinical Endocrinology and Metabolism* 2010 **95** 201–208. (doi:10.1210/jc.2009-1655)
 - 39 Bartalena L, Marcocci C, Bogazzi F, Panicucci M, Lepri A & Pinchera A. Use of corticosteroids to prevent progression of Graves' ophthalmopathy after radioiodine therapy for hyperthyroidism. *New England Journal of Medicine* 1989 **321** 1349–1352.
 - 40 Vannucchi G, Campi I, Covelli D, Dazzi D, Currò N, Simonetta S, Ratiglia R, Beck-Peccoz P & Salvi M. Graves' orbitopathy activation after radioactive iodine therapy with and without steroid prophylaxis. *Journal of Clinical Endocrinology and Metabolism* 2009 **94** 3381–3386.
 - 41 Bartalena L & Tanda ML. Clinical practice – Graves' ophthalmopathy. *New England Journal of Medicine* 2009 **360** 994–1001. (doi:10.1056/NEJMc0806317)
 - 42 Lai A, Sassi L, Compri E, Marino F, Sivelli P, Piantanida E, Tanda ML & Bartalena L. Lower dose prednisone prevents radioiodine-associated exacerbation of initially mild or absent Graves' orbitopathy: a retrospective cohort study. *Journal of Clinical Endocrinology and Metabolism* 2010 **95** 1333–1337. (doi:10.1210/jc.2009-2130)
 - 43 Watanabe N, Noh JY, Kozaki A, Iwaku K, Sekiya K, Kosuga Y, Matsumoto M, Suzuki M, Yoshihara A, Ohye H *et al.* Radioiodine-associated exacerbation of Graves' orbitopathy in the Japanese population: randomized prospective study. *Journal of Clinical Endocrinology and Metabolism* 2015 **100** 2700–2708. (doi:10.1210/jc.2014-4542)
 - 44 Tallstedt L, Lundell G, Blomgren H & Bring J. Does early administration of thyroxine reduce the development of Graves' ophthalmopathy after radioiodine treatment? *European Journal of Endocrinology* 1994 **130** 494–497. (doi:10.1530/eje.0.1300494)
 - 45 Perros P, Kendall-Taylor P, Neoh C, Frewin S & Dickinson J. A prospective study of the effects of radioiodine therapy for hyperthyroidism in patients with minimally active Graves' ophthalmopathy. *Journal of Clinical Endocrinology and Metabolism* 2005 **90** 5321–5323.
 - 46 Menconi F, Marinò M, Pinchera A, Rocchi R, Mazzi B, Nardi M, Bartalena L & Marcocci C. Effects of total thyroid ablation versus near-total thyroidectomy alone on mild to moderate Graves' orbitopathy treated with intravenous glucocorticoids. *Journal of Clinical Endocrinology and Metabolism* 2007 **92** 1653–1658.
 - 47 Leo M, Marcocci C, Pinchera A, Nardi M, Megna L, Rocchi R, Latrofa F, Altea MA, Mazzi B, Sisti E *et al.* Outcome of Graves' orbitopathy after total thyroid ablation and glucocorticoid treatment: follow-up of a randomized clinical trial. *Journal of Clinical Endocrinology and Metabolism* 2012 **97** E44–E48. (doi:10.1210/jc.2011-2077)
 - 48 Moleti M, Violi MA, Montanini D, Trombetta C, Di Bella B, Sturniolo G, Presti S, Alibrandi A, Campenni A, Baldari S *et al.* Radioiodine ablation of postsurgical thyroid remnants with recombinant human TSH (rhTSH) in patients with moderate-to-severe Graves' orbitopathy (GO): a prospective, randomized, single-blind clinical trial. *Journal of Clinical Endocrinology and Metabolism* 2014 **99** 1783–1789. (doi:10.1210/jc.2013-3093)
 - 49 Moleti M, Mattina F, Salamone I, Violi MA, Nucera C, Baldari S, Lo Schiavo MG, Regalbuto C, Trimarchi F & Vermiglio F. Effects of thyroidectomy alone or followed by radioiodine ablation of thyroid remnants on the outcome of Graves' ophthalmopathy. *Thyroid* 2003 **13** 653–658. (doi:10.1089/10507250332240004)
 - 50 De Bellis A, Conzo G, Cennamo G, Pane E, Bellastella G, Colella C, Iacovo AD, Paglionico VA, Siniis AA, Wall JR *et al.* A time course of

- Graves' ophthalmopathy after total thyroidectomy alone or followed by radioiodine therapy: a 2-year longitudinal study. *Endocrine* 2012 **41** 320–326. (doi:10.1007/s12020-011-9559-x)
- 51 Bartalena L, Macchia PE, Marcocci C, Salvi M & Vermiglio F. Effects of treatment modalities for Graves' hyperthyroidism on Graves' orbitopathy: a 2015 Italian Society of Endocrinology Consensus Statement. *Journal of Endocrinological Investigation* 2015 **38** 481–487. (doi:10.1007/s40618-015-0257-z)
- 52 Prummel MF, Bakker A, Wiersinga WM, Baldeschi L, Mourits MP, Kendall-Taylor P, Perros P, Neoh C, Dickinson AJ, Lazarus JH *et al.* Multi-center study on the characteristics and treatment strategies of patients with Graves' orbitopathy: the first European Group on Graves' Orbitopathy experience. *European Journal of Endocrinology* 2003 **148** 491–495. (doi:10.1530/eje.0.1480491)
- 53 Kahaly G, Pitz S, Müller-Forell W & Hommel G. Randomized trial of intravenous immunoglobulins versus prednisolone in Graves' ophthalmopathy. *Clinical Experimental Immunology* 1996 **106** 197–202. (doi:10.1046/j.1365-2249.1996.d01-854.x)
- 54 Matejka G, Vergès B, Vaillant G, Petit JM, Brun-Pacaud A, Rudoni S & Brun JM. Intravenous methylprednisolone pulse therapy in the treatment of Graves' ophthalmopathy. *Hormones Metabolic Research* 1998 **30** 93–98. (doi:10.1055/s-2007-978843)
- 55 Heufelder AE, Wenzel BE & Bahn RS. Glucocorticoids modulate the synthesis and expression of a 72 kDa heat shock protein in cultured Graves' retroocular fibroblasts. *Acta Endocrinologica* 1993 **128** 41–50.
- 56 Vannucchi G, Covelli D, Campi I, Origo D, Currò N, Cirello V, Dazzi D, Beck-Peccoz P & Salvi M. The therapeutic outcome to intravenous steroid therapy for active Graves' orbitopathy is influenced by the time of response but not polymorphisms of the glucocorticoid receptor. *European Journal of Endocrinology* 2013 **170** 55–61. (doi:10.1530/EJE-13-0611)
- 57 Kahaly GJ, Eds WM Wiersinga & GJ Kahaly GJ Management of moderately severe Graves' orbitopathy. In *Graves' Orbitopathy. A Multidisciplinary Approach: Questions and Answers*. 2nd revised version, 2nd eds, pp 120–158. Basel, Switzerland: Karger, 2010.
- 58 Kendall-Taylor P, Crombie AL, Stephenson AM, Hardwick M & Hall K. Intravenous methylprednisolone in the treatment of Graves' ophthalmopathy. *BMJ* 1988 **297** 1574–1578.
- 59 Aktaran S, Akarsu E, Erbağcı I, Araz M, Okumuş S & Kartal M. Comparison of intravenous methylprednisolone therapy vs. oral methylprednisolone therapy in patients with Graves' ophthalmopathy. *International Journal of Clinical Practice* 2007 **61** 45–51.
- 60 Kahaly GJ, Pitz S, Hommel G & Dittmar M. Randomized, single blind trial of intravenous versus oral steroid monotherapy in Graves' orbitopathy. *Journal of Clinical Endocrinology and Metabolism* 2005 **90** 5234–5240.
- 61 Kauppinen-Mäkelin R, Karma A, Leinonen E, Löytyniemi E, Salonen O, Sane T, Setälä K, Viikari J, Heufelder A & Välimäki M. High dose intravenous methylprednisolone pulse therapy versus oral prednisone for thyroid-associated ophthalmopathy. *Acta Ophthalmologica Scandinava* 2002 **80** 316–321. (doi:10.1034/j.1600-0420.2002.800316.x)
- 62 Macchia PE, Bagattini M, Lupoli G, Vitale M, Vitale G & Fenzi G. High-dose intravenous corticosteroid therapy for Graves' ophthalmopathy. *Journal of Endocrinological Investigation* 2001 **24** 152–158. (doi:10.1007/BF03343835)
- 63 Zang S, Ponto KA & Kahaly GJ. Intravenous glucocorticoids for Graves' orbitopathy: efficacy and morbidity. *Journal of Clinical Endocrinology and Metabolism* 2011 **96** 320–332. (doi:10.1210/jc.2010-1962)
- 64 Gao G, Dai J, Qian Y & Ma F. Meta-analysis of methylprednisolone pulse therapy for Graves' ophthalmopathy. *Clinical Experimental Ophthalmology* 2014 **42** 769–777. (doi:10.1111/ceo.2014.42.issue-8)
- 65 Bartalena L, Krassas GE, Wiersinga W, Marcocci C, Salvi M, Daumerie C, Bornaud C, Stahl M, Sassi L, Veronesi G *et al.* and the European Group on Graves' Orbitopathy. Efficacy and safety of three different cumulative doses of intravenous methylprednisolone for moderate to severe and active Graves' orbitopathy. *Journal of Clinical Endocrinology and Metabolism* 2012 **97** 4454–4463. (doi:10.1210/jc.2012-2389)
- 66 Marcocci C, Watt T, Altea MA, Rasmussen AK, Feldt-Rasmussen U, Orgiazzi J & Bartalena L; European Group of Graves' Orbitopathy. Fatal and non-fatal adverse events of glucocorticoid therapy for Graves' orbitopathy: a questionnaire survey among members of the European Thyroid Association. *European Journal of Endocrinology* 2011 **166** 247–253. (doi:10.1530/EJE-11-0779)
- 67 Le Moli R, Baldeschi L, Saeed P, Regenburg N, Mourits MP & Wiersinga WM. Determinants of liver damage associated with intravenous methylprednisolone pulse therapy in Graves' ophthalmopathy. *Thyroid* 2007 **17** 357–362. (doi:10.1089/thy.2006.0267)
- 68 Marinò M, Morabito E, Brunetto MR, Bartalena L, Pinchera A & Marcocci C. Acute and severe liver damage associated with intravenous glucocorticoid pulse therapy in patients with Graves' ophthalmopathy. *Thyroid* 2004 **14** 403–406. (doi:10.1089/10507250474193276)
- 69 Lendorf ME, Rasmussen AK, Fledelius HC & Feldt-Rasmussen U. Cardiovascular and cerebrovascular events in temporal relationship to intravenous glucocorticoid pulse therapy in patients with severe endocrine ophthalmopathy. *Thyroid* 2009 **19** 1431–1432.
- 70 Gursoy A, Cesur M, Erdogan MF, Corapcioglu D & Kamel N. New-onset acute heart failure after intravenous glucocorticoid pulse therapy in a patient with Graves' ophthalmopathy. *Endocrine* 2006 **29** 513–516. (doi:10.1385/ENDO:29:3)
- 71 Sisti E, Menconi F, Leo M, Profilo MA, Mautone T, Mazzi B, Rocchi R, Latrofa F, Nardi M, Vitti P *et al.* Long-term outcome of Graves' orbitopathy following high-dose intravenous glucocorticoids and orbital radiotherapy. *Journal of Endocrinological Investigation* 2015 **38** 661–668. (doi:10.1007/s40618-015-0241-7)
- 72 Covelli D, Vannucchi G, Campi I, Currò N, D'Ambrosio R, Maggioni M, Gianelli U, Beck-Peccoz P & Salvi M. Statins may increase the risk of liver dysfunction in patients treated with steroids for active Graves' orbitopathy. *Journal of Clinical Endocrinology and Metabolism* 2015 **100** 1731–1737. (doi:10.1210/jc.2014-4463)
- 73 Bartalena L, Marcocci C, Chiovato L, Laddaga M, Lepri A, Andreani D, Cavallacci G, Baschieri L & Pinchera A. Orbital cobalt irradiation combined with systemic corticosteroids for Graves' ophthalmopathy: comparison with systemic corticosteroids alone. *Journal of Clinical Endocrinology and Metabolism* 1983 **56** 1139–1144.
- 74 Marcocci C, Bartalena L, Bogazzi F, Bruno-Bossio G, Lepri A & Pinchera A. Orbital radiotherapy combined with high-dose systemic glucocorticoids for Graves' ophthalmopathy is more effective than orbital radiotherapy alone: results of a prospective study. *Journal of Endocrinological Investigation* 1991 **14** 853–860. (doi:10.1007/BF03347943)
- 75 Mourits MP, van Kempen-Harteveld ML, Garcia MB, Koppeschaar HP, Tick L & Terwee CB. Radiotherapy for Graves' orbitopathy: randomised placebo-controlled study. *Lancet* 2000 **355** 1505–1509.
- 76 Prummel MF, Terwee CB, Gerding MN, Baldeschi L, Mourits MP, Blank L, Dekker FW & Wiersinga WM. A randomized controlled trial of orbital radiotherapy versus sham irradiation in patients with mild Graves' ophthalmopathy. *Journal of Clinical Endocrinology and Metabolism* 2004 **89** 15–20. (doi:10.1210/jc.2003-030809)
- 77 Gorman CA, Garrity JA, Fatourehchi V, Bahn RS, Petersen IA, Stafford SL, Earle JD, Forbes GS, Kline RW, Bergstrahl EJ *et al.* A prospective, randomized, double-blind, placebo-controlled study of orbital radiotherapy for Graves' orbitopathy. *Ophthalmology* 2001 **108** 1523–1534.
- 78 Bartalena L, Marcocci C, Tanda ML, Rocchi R, Mazzi B, Barbesino G & Pinchera A. Orbital radiotherapy for Graves' ophthalmopathy. *Thyroid* 2002 **12** 245–250. (doi:10.1089/105072502753600223)

- 79 Kahaly GJ, Rosler HP, Pitz S & Hommel G. Low- versus high-dose radiotherapy for Graves' ophthalmopathy: a randomized, single blind trial. *Journal of Clinical Endocrinology and Metabolism* 2000 **85** 102–108.
- 80 Wiersinga WM & Prummel MF. Graves' ophthalmopathy: a rational approach to treatment. *Trends in Endocrinology and Metabolism* 2002 **13** 280–287. (doi:10.1016/S1043-2760(02)00622-7)
- 81 Marcocci C, Bartalena L, Rocchi R, Marinò M, Menconi F, Morabito E, Mazzi B, Mazzeo S, Sartini MS, Nardi M *et al.* Long-term safety of orbital radiotherapy for Graves' ophthalmopathy. *Journal of Clinical Endocrinology and Metabolism* 2003 **88** 3561–3566.
- 82 Wakelkamp IM, Tan H, Saeed P, Schlingemann RO, Verbraak FD, Blank LE, Prummel MF & Wiersinga WM. Orbital irradiation for Graves' ophthalmopathy: is it safe? A long-term follow-up study. *Ophthalmology* 2004 **111** 1557–1562.
- 83 Kahaly G, Schrezenmeier J, Krause U, Schwikert B, Meuer S, Muller W, Dennebaum R & Beyer J. Cyclosporin and prednisone vs. prednisone in treatment of Graves' ophthalmopathy: a controlled, randomized and prospective study. *European Journal of Clinical Investigation* 1986 **16** 415–422. (doi:10.1111/j.1365-2362.1986.tb01016.x)
- 84 Prummel MF, Mourits MP, Berghout A, Krenning EP, van der Gaag R, Koornneef L & Wiersinga WM. Prednisone and cyclosporine in the treatment of severe Graves' ophthalmopathy. *New England Journal of Medicine* 1989 **321** 1353–1359.
- 85 Salvi M. Immunotherapy for Graves' ophthalmopathy. *Current Opinion in Endocrinology Diabetes and Obesity* 2014 **21** 409–414. (doi:10.1097/MED.0000000000000097)
- 86 Neumann S1, Raaka BM & Gershengorn MC. Human TSH receptor ligands as pharmacological probes with potential clinical application. *Expert Reviews of Endocrinology and Metabolism* 2009 **4** 669.
- 87 Gershengorn MC & Neumann S. Update in TSH receptor agonists and antagonists. *Journal of Clinical Endocrinology and Metabolism* 2012 **97** 4287–4292. (doi:10.1210/jc.2012-3080)
- 88 Douglas RS, Afifyan NF, Hwang CJ, Chong K, Haider U, Richards P, Gianoukakis AG & Smith TJ. Increased generation of fibrocytes in thyroid-associated ophthalmopathy. *Journal of Clinical Endocrinology and Metabolism* 2010 **95** 430–438. (doi:10.1210/jc.2009-1614)
- 89 Chen H, Mester T, Raychaudhuri N, Kauh CY, Gupta S, Smith TJ & Douglas RS. Teprotumumab, an IGF-1R blocking monoclonal antibody inhibits TSH and IGF-1 action in fibrocytes. *Journal of Clinical Endocrinology and Metabolism* 2014 **99** E1635–E1640. (doi:10.1210/jc.2014-1580)
- 90 Minich WB, Dehina N, Welsink T, Schwiebert C, Morgenthaler NG, Köhrle J, Eckstein A & Schomburg L. Autoantibodies to the IGF1 receptor in Graves' orbitopathy. *Journal of Clinical Endocrinology and Metabolism* 2013 **98** 752–760. (doi:10.1210/jc.2012-1771)
- 91 Zhang L, Grennan-Jones F, Draman MS, Lane C, Morris D, Dayan CM, Tee AR & Ludgate M. Possible targets for nonimmunosuppressive therapy of Graves' orbitopathy. *Journal of Clinical Endocrinology and Metabolism* 2014 **99** E1183–E1190. (doi:10.1210/jc.2013-4182)
- 92 Kurtz J-E & Ray-Coquard I. PI3 kinase inhibitors in the clinic: an update. *Anticancer Research* 2012 **32** 2463–2470.
- 93 Jerusalem G, Rorive A & Collignon J. Use of mTOR inhibitors in the treatment of breast cancer: an evaluation of factors that influence patient outcomes. *Breast Cancer* 2014 **17** 43–57. (doi:10.2147/BCTT.S38679)
- 94 van Steensel L, Paridaens D, van Meurs M, van Hagen PM, van den Bosch WA, Kuijpers RW, Drexhage HA, Hooijkaas H & Dik WA. Orbit-infiltrating mast cells, monocytes, and macrophages produce PDGF isoforms that orchestrate orbital fibroblast activation in Graves' ophthalmopathy. *Journal of Clinical Endocrinology and Metabolism* 2012 **97** E400–E408. (doi:10.1210/jc.2011-2697)
- 95 van Steensel L, van Hagen PM, Paridaens D, Kuijpers RW, van den Bosch WA, Drexhage HA, Hooijkaas H & Dik WA. Whole orbital tissue culture identifies imatinib mesylate and adalimumab as potential therapeutics for Graves' ophthalmopathy. *British Journal of Ophthalmology* 2011 **95** 735–738. (doi:10.1136/bjo.2010.192302)
- 96 Virakul S, Dalm VA, Paridaens D, van den Bosch WA, Hirankarn N, van Hagen PM & Dik WA. The tyrosine kinase inhibitor dasatinib effectively blocks PDGF-induced orbital fibroblast activation. *Graefes' Archive for Clinical and Experimental Ophthalmology* 2014 **252** 1101–1109. (doi:10.1007/s00417-014-2674-7)
- 97 Distler JH & Distler O. Intracellular tyrosine kinases as novel targets for anti-fibrotic therapy in systemic sclerosis. *Rheumatology* 2008 **47** v10–v11.
- 98 Wakelkamp IM, Bakker O, Baldeschi L, Wiersinga WM & Prummel MF. TSH-R expression and cytokine profile in orbital tissue of active vs. inactive Graves' ophthalmopathy patients. *Clinical Endocrinology* 2003 **58** 280–287. (doi:10.1046/j.1365-2265.2003.01708.x)
- 99 Li B & Smith TJ. Regulation of IL-1 receptor antagonist by TSH in fibrocytes and orbital fibroblasts. *Journal of Clinical Endocrinology and Metabolism* 2014 **99** 625–633. (doi:10.1210/jc.2013-3222)
- 100 Cawood TJ, Moriarty P, O'Farrelly C & O'Shea D. Smoking and thyroid-associated ophthalmopathy: a novel explanation of the biological link. *Journal of Clinical Endocrinology and Metabolism* 2007 **92** 59–64. (doi:10.1210/jc.2006-1824)
- 101 Paridaens D, van den Bosch WA, van der Loos TL, Krenning EP & van Hagen PM. The effect of etanercept on Graves' ophthalmopathy: a pilot study. *Eye* 2005 **19** 1286–1289.
- 102 Salvi M, Girasole G, Pedrazzoni M, Passeri M, Giuliani N, Minelli R, Braverman LE & Roti E. Increased serum concentrations of interleukin-6 (IL-6) and soluble IL-6 receptor in patients with Graves' disease. *Journal of Clinical Endocrinology and Metabolism* 1996 **81** 2976–2979.
- 103 Maini RN, Taylor PC, Szechinski J, Pavelka K, Bröll J, Balint G, Emery P, Raemen F, Petersen J, Smolen J *et al.* CHARISMA Study Group. Double-blind randomized controlled clinical trial of the interleukin-6 receptor antagonist, tocilizumab, in European patients with rheumatoid arthritis who had an incomplete response to methotrexate. *Arthritis and Rheumatology* 2006 **54** 2817–2829. (doi:10.1002/(ISSN)1529-0131)
- 104 Pérez-Moreiras JV, Alvarez-López A & Gómez EC. Treatment of active corticosteroid-resistant Graves' orbitopathy. *Ophthalmic Plastic and Reconstructive Surgery* 2014 **30** 162–167. (doi:10.1097/IOP.0000000000000037)
- 105 Fabris M, Grimaldi F, Villalta D, Picerno A, Fabro C, Bolzan M, De Vita S & Tonutti E. BlyS and April serum levels in patients with autoimmune thyroid diseases. *Autoimmunity Reviews* 2010 **9** 165–169. (doi:10.1016/j.autrev.2009.07.005)
- 106 Vannucchi G, Covelli D, Currò N, Dazzi D, Maffini A, Campi I, Bonara P, Guastella C, Pignataro L, Ratiglia R *et al.* Serum BAFF concentrations in patients with Graves' disease and orbitopathy before and after immunosuppressive therapy. *Journal of Clinical Endocrinology and Metabolism* 2012 **97** 755–759. (doi:10.1210/jc.2011-2614)
- 107 Salvi M, Vannucchi G, Campi I, Rossi S, Bonara P, Sbrozzi F, Guastella C, Avignone S, Pirola G, Ratiglia R *et al.* Efficacy of rituximab treatment for thyroid-associated ophthalmopathy as a result of intraorbital B-cell depletion in one patient unresponsive to steroid immunosuppression. *European Journal of Endocrinology* 2006 **154** 511–517. (doi:10.1530/eje.1.02119)
- 108 Salvi M, Vannucchi G & Beck-Peccoz P. Potential utility of rituximab for Graves' orbitopathy. *Journal of Clinical Endocrinology and Metabolism* 2013 **98** 4291–4299. (doi:10.1210/jc.2013-1804)
- 109 Stan MN, Garrity JA, Carranza Leon BG, Prabin T, Bradley EA & Bahn RS. Randomized controlled trial of rituximab in patients with Graves' orbitopathy. *Journal of Clinical Endocrinology and Metabolism* 2014 **100** 432–441. (doi:10.1210/jc.2014-2572)
- 110 Salvi M, Vannucchi G, Currò N, Campi I, Covelli D, Dazzi D, Simonetta S, Guastella C, Pignataro L, Avignone S *et al.* Efficacy of B-cell targeted therapy with rituximab in patients

- with active moderate to severe Graves' orbitopathy: a randomized controlled study. *Journal of Clinical Endocrinology and Metabolism* 2015 **100** 422–431. (doi:10.1210/jc.2014-3014)
- 111 Engel P, Gómez-Puerta JA, Ramos-Casals M, Lozano F & Bosch X. Therapeutic targeting of B cells for rheumatic autoimmune diseases. *Pharmacological Reviews* 2011 **63** 127–156. (doi:10.1124/pr.109.002006)
- 112 Salvi M, Vannucchi G, Currò N, Introna M, Rossi S, Bonara P, Covelli D, Dazzi D, Guastella C, Pignataro L *et al.* Small dose of rituximab for Graves orbitopathy: new insights into the mechanism of action. *Archives of Ophthalmology* 2012 **130** 122–124. (doi:10.1001/archophthalmol.2011.1215)
- 113 Mackay F, Groom JR & Tangye SG. An important role for B-cell activation factor and B cells in the pathogenesis of Sjogren's syndrome. *Current Opinion in Rheumatology* 2007 **19** 406–413. (doi:10.1097/BOR.0b013e328277ef4c)
- 114 El Fassi D, Nielsen CH, Hasselbalch HC & Hegedüs L. Treatment-resistant severe, active Graves' ophthalmopathy successfully treated with B lymphocyte depletion. *Thyroid* 2006 **16** 709–710. (doi:10.1089/thy.2006.16.709)
- 115 Salvi M, Vannucchi G, Campi I, Currò N, Dazzi D, Simonetta S, Bonara P, Rossi S, Sina C, Guastella C *et al.* Treatment of Graves' disease and associated ophthalmopathy with the anti-CD20 monoclonal antibody rituximab: an open study. *European Journal of Endocrinology* 2007 **156** 33–40. (doi:10.1530/eje.1.02325)
- 116 Erdei A, Paragh G, Kovacs P, Karanyi Z, Berenyi E, Galuska L, Lenkey A, Szabados L, Gyory F, Ujhelyi B *et al.* Rapid response to and long-term effectiveness of anti-CD20 antibody in conventional therapy resistant Graves' orbitopathy: a five-year follow-up study. *Autoimmunity* 2014 **47** 548–555. (doi:10.3109/08916934.2014.939266)
- 117 Mitchell AL, Gan EH, Morris M, Johnson K, Neoh C, Dickinson AJ, Perros P & Pearce SH. The effect of B cell depletion therapy on anti-TSH receptor antibodies and clinical outcome in glucocorticoid-refractory Graves' orbitopathy. *Clinical Endocrinology* 2013 **79** 437–442. (doi:10.1111/cen.2013.79.issue-3)
- 118 Khanna D, Chong KK, Afifiyan NF, Hwang CJ, Lee DK, Garneau HC, Goldberg RA, Darwin CH, Smith TJ & Douglas RS. Rituximab treatment of patients with severe, corticosteroid-resistant thyroid-associated ophthalmopathy. *Ophthalmology* 2010 **117** 133–139. (doi:10.1016/j.ophtha.2009.05.029)
- 119 El Fassi D, Banga JP, Gilbert JA, Padoa C, Hegedüs L & Nielsen CH. Treatment of Graves' disease with rituximab specifically reduces the production of thyroid stimulating autoantibodies. *Clinical Immunology* 2009 **130** 252–258. (doi:10.1016/j.clim.2008.09.007)
- 120 Krassas GE, Stafilidou A & Boboridis KG. Failure of rituximab treatment in a case of severe thyroid ophthalmopathy unresponsive to steroids. *Clinical Endocrinology* 2010 **72** 853–855. (doi:10.1111/j.1365-2265.2009.03762.x)
- 121 Salvi M, Vannucchi G, Campi I, Currò N, Simonetta S, Covelli D, Pignataro L, Guastella C, Rossi S, Bonara P *et al.* Rituximab treatment in a patient with severe thyroid-associated ophthalmopathy: effects on orbital lymphocytic infiltrates. *Clinical Immunology* 2009 **131** 360–365. (doi:10.1016/j.clim.2008.12.005)
- 122 Bredemeier M, de Oliveira FK & Rocha CM. Low- versus high dose rituximab for rheumatoid arthritis: a systematic review and meta-analysis. *Arthritis Care and Research* 2014 **66** 228–235. (doi:10.1002/acr.v66.2)
- 123 Descotes J. Immunotoxicity of monoclonal antibodies. *mAbs Journal* 2009 **1** 104–111. (doi:10.4161/mabs.1.2.7909)
- 124 van Vollenhoven RF, Emery P, Bingham CO III, Keystone EC, Fleischmann RM, Furst DE, Tyson N, Collinson N & Lehane PB. Long-term safety of rituximab in rheumatoid arthritis: 9.5-year follow-up of the global clinical trial programme with a focus on adverse events of interest in RA patients. *Annals of the Rheumatic Diseases* 2013 **72** 1496–1502. (doi:10.1136/annrheumdis-2012-201956)
- 125 Food and Drug Administration 2006 FDA Public Health Advisory: life-threatening brain infection in patients with systemic lupus erythematosus after Rituxan (rituximab) treatment. Rockville, MD, USA: U.S. Department of Health and Human Services, Food and Drug Administration. (available at: <http://www.fda.gov/cder/drug/>)
- 126 McKeag D, Lane C, Lazarus JH, Baldeschi L, Boboridis K, Dickinson AJ, Hullo AI, Kahaly G, Krassas G, Marcocci C *et al.* European Group on Graves' Orbitopathy (EUGOGO) Clinical features of dysthyroid optic neuropathy: a European Group on Graves' Orbitopathy (EUGOGO) survey. *British Journal of Ophthalmology* 2007 **91** 455–458. (doi:10.1136/bjo.2006.094607)
- 127 Wakelkamp IM, Baldeschi L, Saeed P, Mourits MP, Prummel MF & Wiersinga WM. Surgical or medical decompression as a first-line treatment of optic neuropathy in Graves' ophthalmopathy? A randomized controlled trial. *Clinical Endocrinology* 2005 **63** 323–328. (doi:10.1111/cen.2005.63.issue-3)
- 128 Currò N, Covelli D, Vannucchi G, Campi I, Pirola G, Simonetta S, Dazzi D, Guastella C, Pignataro L, Beck-Peccoz P *et al.* Therapeutic outcomes of high-dose intravenous steroids in the treatment of dysthyroid optic neuropathy. *Thyroid* 2014 **24** 897–905. (doi:10.1089/thy.2013.0445)
- 129 Mourits MP, Bijl H, Altea MA, Baldeschi L, Boboridis K, Currò N, Dickinson AJ, Eckstein A, Freidel M, Guastella C *et al.* Outcome of orbital decompression for disfiguring proptosis in patients with Graves' orbitopathy using various surgical procedures. *British Journal of Ophthalmology* 2009 **93** 1518–1523.
- 130 Garrity JA, Fatourehchi V, Bartley GB, Bergstrahl EJ, DeSanto LW, Gorman CA. Graves' ophthalmopathy. Results of transantral orbital decompression in 428 patients with severe Graves' ophthalmopathy. *American Journal of Ophthalmology* 1994 **116** 533–547.
- 131 Rocchi R, Lenzi R, Marinò M, Latrofa F, Nardi M, Piaggi P, Mazzi B, Altea MA, Pinchera A, Vitti P *et al.* Rehabilitative orbital decompression for Graves' orbitopathy: risk factors influencing the new onset of diplopia in primary gaze, outcome and patients' satisfaction. A large retrospective study. *Thyroid* 2012 **22** 1170–1175. (doi:10.1089/thy.2012.0272)
- 132 Paridaens D, Hans K, van Buitenen S & Mourits MP. The incidence of diplopia following coronal and translid orbital decompression in Graves' orbitopathy. *Eye* 1998 **12** 80.
- 133 Eckstein A, Schittkowski M & Esser J. Surgical treatment of Graves' ophthalmopathy. *Best Practice and Research Clinical Endocrinology and Metabolism* 2012 **26** 339–358. (doi:10.1016/j.beem.2011.11.002)
- 134 Estcourt S, Hickey J, Perros P, Dayan C & Vaidya B. The patient experience of services for thyroid eye disease in the United Kingdom: results of a nationwide survey. *European Journal of Endocrinology* 2009 **161** 483–484. (doi:10.1530/EJE-09-0383)
- 135 Terwee C, Wakelkamp I, Tan S, Dekker F, Prummel MF & Wiersinga W. Long-term effects of Graves' ophthalmopathy on health-related quality of life. *European Journal of Endocrinology* 2002 **146** 751–757. (doi:10.1530/eje.0.1460751)
- 136 De Sousa A. Psychological issues in acquired facial trauma. *Indian Journal of Plastic Surgery* 2010 **43** 200–205. (doi:10.4103/0970-0358.73452)
- 137 Parrish RK II. Visual impairment, visual functioning, and quality of life assessments in patients with glaucoma. *Transactions of the American Ophthalmological Society* 1996 **94** 919–1028.
- 138 The WHOQOL Group. The World Health Organization Quality of Life Assessment (WHOQOL). Development and psychometric properties. *Social Science and Medicine* 1998 **46** 1569–1585.
- 139 Wiersinga WM, Prummel MF & Terwee CB. Effects of Graves' ophthalmopathy on quality of life. *Journal of Endocrinological Investigation* 2004 **27** 259–264. (doi:10.1007/BF03345275)
- 140 Yeatts RP. Quality of life in patients with Graves ophthalmopathy. *Transactions of the American Ophthalmological Society* 2005 **103** 368–411.

- 141 Terwee CB, Gerding MN, Dekker FW, Prummel MF & Wiersinga WM. Development of a disease specific quality of life questionnaire for patients with Graves' ophthalmopathy: the GO-QOL. *British Journal of Ophthalmology* 1998 **82** 773–779. (doi:10.1136/bjo.82.7.773)
- 142 Terwee CB, Gerding MN, Dekker FW, Prummel MF, van der Pol JP & Wiersinga WM. Test-retest reliability of the GO-QOL: a disease-specific quality of life questionnaire for patients with Graves' ophthalmopathy. *Journal of Clinical Epidemiology* 1999 **52** 875–884. (doi:10.1016/S0895-43569900069-4)
- 143 Terwee CB, Dekker FW, Mourits MP, Gerding MN, Baldeschi L, Kalmann R, Prummel MF & Wiersinga WM. Interpretation and validity of changes in scores on the Graves' ophthalmopathy quality of life questionnaire (GO-QOL) after different treatments. *Clinical Endocrinology* 2001 **54** 391–398. (doi:10.1046/j.1365-2265.2001.01241.x)
- 144 Jellema HM, Merckel-Timmer E, Kloos R, Saeed P & Mourits MP. Quality of life improves after strabismus surgery in patients with Graves' orbitopathy. *European Journal of Endocrinology* 2014 **10** 785–789. (doi:10.1530/EJE-13-0973)
- 145 Choi YJ, Lim HT, Lee SJ, Lee SY & Yoon JS. Assessing Graves' ophthalmopathy-specific quality of life in Korean patients. *Eye* 2012 **26** 544–551. (doi:10.1038/eye.2011.359)
- 146 Park JJ, Sullivan TJ, Mortimer RH, Wagenaar M & Perry-Keene DA. Assessing quality of life in Australian patients with Graves' ophthalmopathy. *British Journal of Ophthalmology* 2004 **88** 75–78. (doi:10.1136/bjo.88.1.75)
- 147 Ponto KA, Hommel G, Pitz S, Elflein H, Pfeiffer N & Kahaly GJ. Quality of life in a German Graves orbitopathy population. *American Journal of Ophthalmology* 2011 **152** 483–490. (doi:10.1016/j.ajo.2011.02.018)
- 148 Lin IC, Lee CC & Liao SL. Assessing quality of life in Taiwanese patients with Graves' ophthalmopathy. *Journal of the Formosan Medical Association* 2014 **114** 1047–1054.
- 149 Wiersinga WM. Quality of life in Graves' ophthalmopathy. *Best Practice and Research Clinical Endocrinology and Metabolism* 2012 **26** 359–370. (doi:10.1016/j.beem.2011.11.001)
- 150 Gerding MN, Terwee CB, Dekker FW, Koorneef L, Prummel MF & Wiersinga WM. Quality of life in patients with Graves' ophthalmopathy is markedly decreased: measurement by the Medical Outcomes Study instrument. *Thyroid* 1997 **7** 885–889. (doi:10.1089/thy.1997.7.885)
- 151 Frewin SE, Dickinson AJ, Kendall-Taylor P & Perros P. Psychosocial morbidity in patients with thyroid-associated ophthalmopathy. *Journal of Endocrinology* 1999 **160** (Supplement) 241.
- 152 Coulter I, Frewin S, Krassas GE & Perros P. Psychological implications of Graves' orbitopathy. *European Journal of Endocrinology* 2007 **157** 127–131. (doi:10.1530/EJE-07-0205)
- 153 Estcourt S, Vaidya B, Quinn A & Shepherd M. The impact of thyroid eye disease upon patients' wellbeing: a qualitative analysis. *Clinical Endocrinology* 2008 **68** 635–639. (doi:10.1111/j.1365-2265.2007.03087.x)
- 154 Rumsey N, Clarke A, White P, Wyn-Williams M & Garlick W. Altered body image: appearance related concerns of people with visible disfigurement. *Journal of Advanced Nursing* 2004 **48** 443–453. (doi:10.1111/jan.2004.48.issue-5)
- 155 Ponto KA, Merkesdal S, Hommel G, Pitz S, Pfeiffer N & Kahaly GJ. Public health relevance of Graves' orbitopathy. *Journal of Clinical Endocrinology and Metabolism* 2013 **98** 145–152. (doi:10.1210/jc.2012-3119)
- 156 Ponto KA, Pitz S, Pfeiffer N, Hommel G, Weber M & Kahaly GJ. Quality of life and occupational disability in endocrine orbitopathy. *Deutsches Ärzteblatt International* 2009 **106** 283–289.
- 157 Chow A, Mayer EK, Darzi AW & Athanasiou T. Patient-reported outcome measures: the importance of patient satisfaction in surgery. *Surgery* 2009 **146** 435–443. (doi:10.1016/j.surg.2009.03.019)
- 158 Ware JE Jr, Snyder MK, Wright WR & Davies AR. Defining and measuring patient satisfaction with medical care. *Evaluation and Program Planning* 1983 **6** 247–263. (doi:10.1016/0149-71898390005-8)
- 159 Stimson GWB & Webb B. *Going to See the Doctor: The Consultation Process in General Practice*, pp 321–321. London, UK: Routledge & Kegan Paul, 1975.
- 160 George AK & Sanda MG. Measuring patient satisfaction. In *Clinical Research for Surgeons*, edn 1, ch 14, pp 253–265. Ed D Penson. New York, NY, USA: Humana Press, 2006.
- 161 Perros P, Dayan CM, Dickinson AJ, Ezra DG, Hickey JL, Hintschisch C, Kahaly G, Lazarus JH, Ludgate M, Bartès B *et al*. Future research in Graves' orbitopathy: from priority setting to trial design through patient and public involvement. *Thyroid* 2015 **25** 1181–1184. (doi:10.1089/thy.2015.0222)

Received 30 November 2015

Revised version received 15 March 2016

Accepted 31 March 2016