

Enrico Sertoli and the supporting cells of the testis

“Morphology is function”

C. Patriarca¹, M. Colecchia², C.A. Clerici³

¹ Pathology Unit, St Anna Hospital (ASST Lariana), Como, Italy; ² Pathology Department, SSD Uropathology, Fondazione IRCCS Istituto Nazionale dei Tumori, Milan, Italy;

³ Department of Oncology and Hemato-oncology, University of Milan, and SSD Clinical Psychology, Fondazione IRCCS Istituto Nazionale dei Tumori, Milan, Italy

Summary

In 1865, Enrico Sertoli, at the age of 23, published an article in his own name entitled: “About the existence of special branched cells in the seminiferous tubules of the human testis.” These were Sertoli’s ideal cells; in this paper he arrived at a perspicacious description of the morphology and function of these cells and in the subsequent articles he investigated the topic of spermatogenesis. Despite the importance of Sertoli’s discovery, the attention of the scientific literature remained very limited after Sertoli’s death for half a century and the partial eclipse finished only in the 1970s of the twentieth century.

“Il testicolo dell’uomo è costituito, come ognuno sa, nella sua parte più essenziale, da un numero stragrande di piccoli canaletti, tortuosi e tra loro aggomitati, che terminando nella loro estremità a fondo cieco oppure ad anse, a due e tre superiormente si uniscono in unici canaletti non tortuosi”

Enrico Sertoli, 1865

Morphology is function

Before an audience of students at the *Scuola Superiore di Medicina Veterinaria* during the opening ceremony for the academic year 1872-73, Enrico Sertoli concluded his talk by exhorting his listeners to study histology. In somewhat bombastic tones, typical of the rhetoric of his time, he said: “Take courage, young scholars! Don’t be deterred by the difficulties you will encounter in studying such an important part of medical knowledge.” After giving the students a good scolding (*“Le forme microscopiche, che voi forse non sapete ancora abbastanza apprezzare, almeno se arguir debbo dalla riluttanza che molti di voi mostrarono nel sottoporsi a prove concernenti questa parte tanto essenziale dello scibile medico”*), he dedicated a part of his talk to emphasizing the close relationship between form and function ¹. He judged that the most effective models to use to persuade his audience could

be drawn *“by taking for example the nerve cell, with its multiple branches”*. Although the central nervous system was not his field of study, while working and studying in the laboratories at the Botanical Gardens in Pavia, he had happened to come into close contact with a student a year younger than him, Camillo Golgi. This was the man who, in 1873, was adding the final touches to his “black reaction” technique for staining neurons that – many years later – earned him a Nobel Prize that he shared with Ramon J Cajal. *“Form acquires its real importance when it is acknowledged as a function”*, Sertoli said, and again: *“the functional manifestations are closely related to the morphological composition”*. (*“La vita inchiude il concetto della forma (...) e la conoscenza della forma (...) ci rappresenta graficamente le leggi secondo le quali i processi della vita si compiono (...). Dice il prof. Oehl che la forma (...) determina la direzione, come un filo telegrafico la direzione del movimento”*).

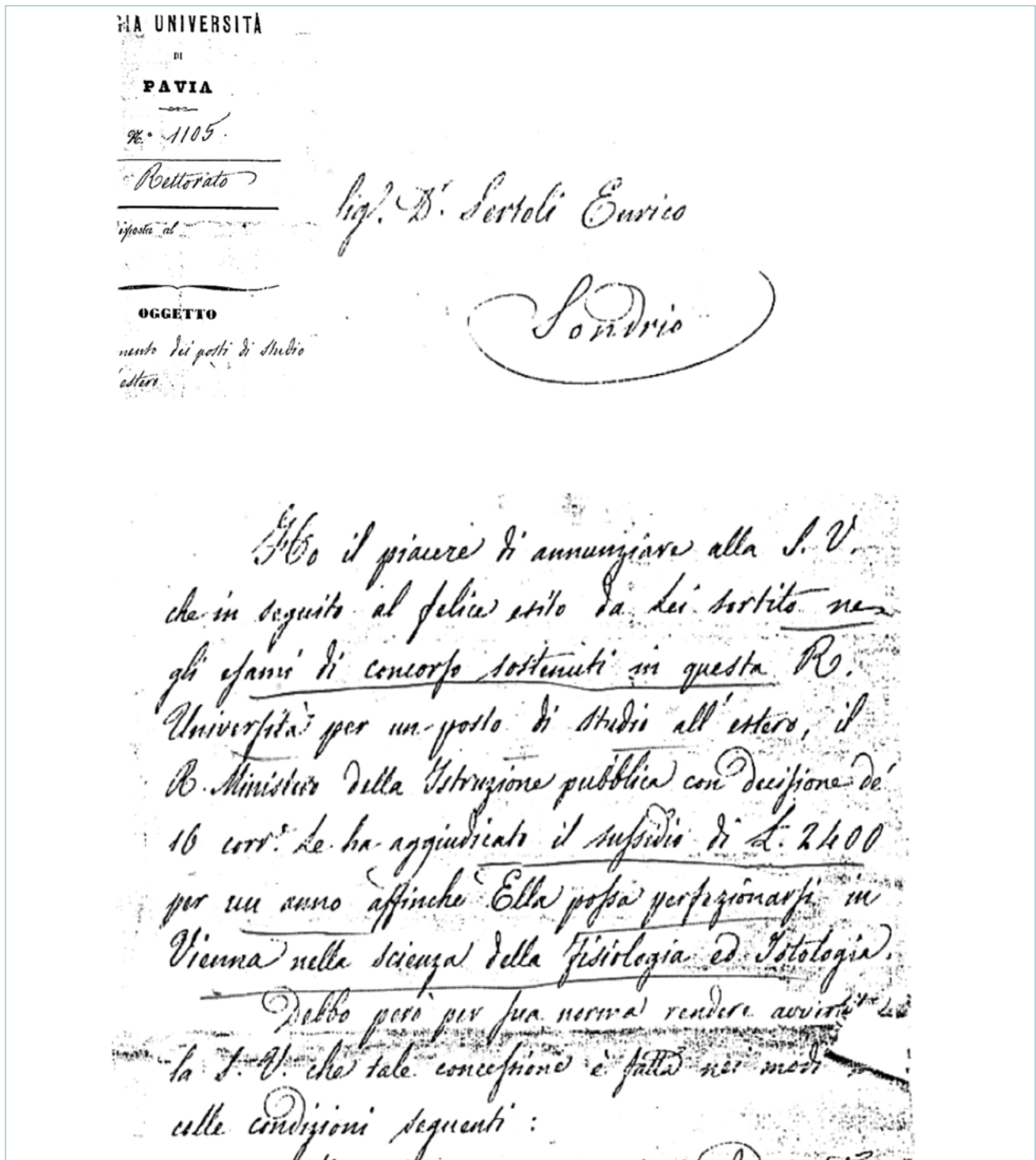
How to cite this article: Patriarca C, Colecchia M, Clerici CA. Enrico Sertoli and the supporting cells of the testis. “Morphology is function”. Pathologica 2019;111:375-81. <https://doi.org/10.32074/1591-951X-32-19>.

Correspondence: Carlo Patriarca, Servizio di Anatomia Patologica, Ospedale Sant’Anna di Como, via Ravona, 22020 San Fermo della Battaglia (CO), Italy - E-mail: carlo.patriarca@asst-lariana.it

It was under the guidance of the histologist and physiologist Eugenio Oehl that Enrico Sertoli graduated in 1865². His virtual peers Camillo Golgi and Giulio Bizzozzero were also attending Oehl's laboratory during the same period. Still in 1865, Sertoli published an article in his own name in the journal *il Morgagni* en-

titled: "Dell'esistenza di particolari cellule ramificate nei canalicoli seminiferi del testicolo umano"³. These were Sertoli's ideal cells, one of the most beautiful examples of the relationship between form and function to be found in nature.

Enrico Sertoli (Sondrio 1842-1910) was the sec-



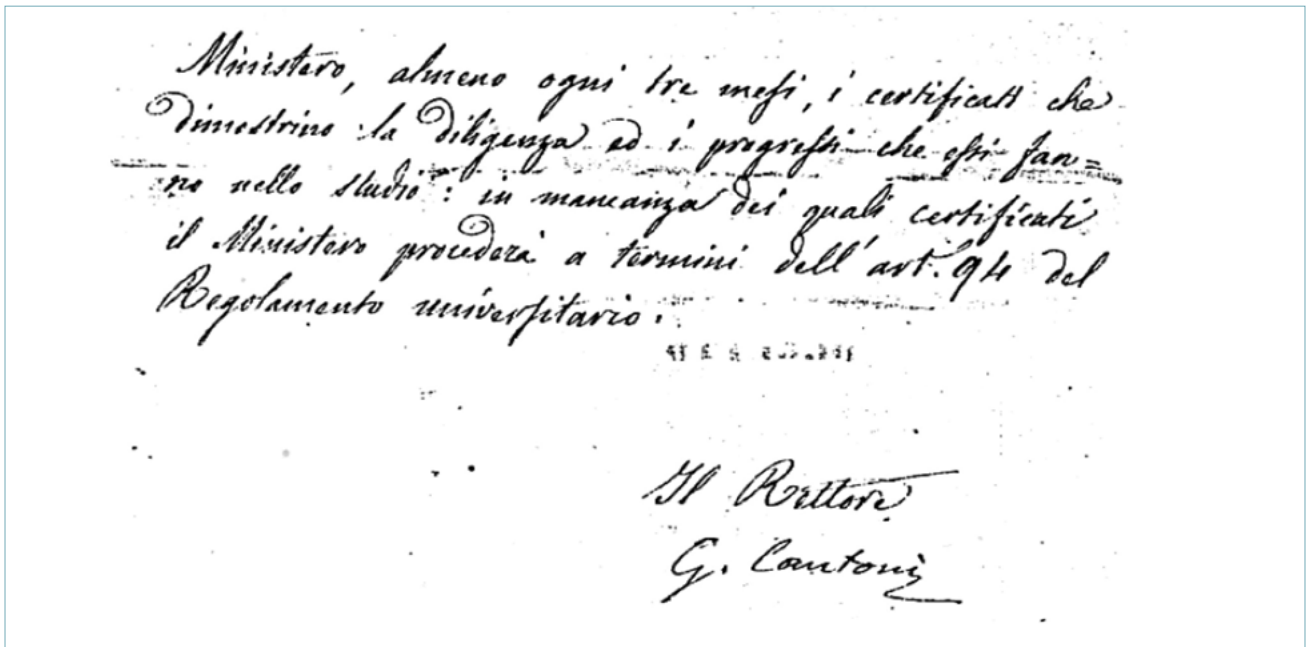


Fig. 1. Excerpt from a letter written by the Rector G. Cantoni, dated 18 October 1865: *in seguito al felice esito da lei sortito negli esami (...) per un posto di studio all'estero, il Regio Ministero dell'Istruzione pubblica (...) le ha aggiudicato un sussidio di lire 2400 per un anno, affinché ella possa perfezionarsi in Vienna nella scienza della Fisiologia e Istologia. (...) I sussidi saranno pagati in dodici rate mensili eguali posticipate (...)* (by kind concession of the Sertoli family).

ond-born son of a noble family. He had already graduated in medicine in 1865, at the age of 23, when he departed for Vienna to further his studies at the laboratories of Ernst Brücke, one of the most famous physiologists at the time.

Enrico probably received only a part of the 2400 lire bursary he had been awarded (Fig. 1), because he hastily returned to Italy the next year, when he had the chance to join the Lombard patriots and fight beneath the Stelvio pass against the Austrians⁴. These were the early days of June 1866, at the time of the first military operations in the Third Italian War of Independence. With the 68th Infantry Regiment, Enrico was then sent to Palermo, where the army was engaged in quelling a revolt. When an outbreak of cholera spread from Naples to Sicily, he was finally able to return to being a doctor, albeit in uniform.

After his time in the army, Sertoli returned to his studies, heading this time to Tübingen and the physiology laboratory directed by Hoppe-Seyler, where he obtained a post as assistant and focused his interest on blood proteins². In 1870, at just 28 years old, he was called to teach anatomy and physiology at the *Scuola Superiore di Medicina Veterinaria* in Milan and, once there, he did not forget *his* cells.

The institute had been established by Eugenio Beauharnais in 1805, growing from what was originally the *Scuola Minore di Anatomia Veterinaria e Mascalcia* created by the previous Austrian government. Sertoli was appointed director of physiology and kept occupied full time in running the laboratory⁵, but this did not prevent him from returning to debating the function of the supporting cells in the seminiferous tubules. He reiterated their trophic and supporting role, but rejected the idea that these cells might “*take part directly in the formation of the sperm cells*”⁶. There was a widespread conviction among histologists of the 19th century that, in addition to the known germ cells, there were epitheliomorphic elements that the famous Swiss histologist Kolliker erroneously defined as polygonal^{2,7}. It was believed that these elements originated from germ cells, or else that part of them gave rise to germ cells. But Sertoli had never seen spermatozoa inside such cells, which also had a shape too dissimilar from that of the seminiferous cells. He argued thus in his article of 1865, concluding that he was not convinced that the branched cells produced spermatids.

One wonders what means Sertoli had used to arrive at such a perspicacious description of the morphology and function of these cells. As was common practice

in his time, at 20 years old, Sertoli had bought himself a Belthle microscope (a German instrument that was then top of the range, with 10x and 20x lenses) - and he must have been very fond of it because it was recently still in an excellent state of repair and in the hands of his family ².

Sertoli was in the habit of fixing tissue samples in a solution of mercury salts (mercuric chloride, which went by the name of 'corrosive sublimate') and ammonia. After three or five days, he would then proceed as follows: "From it I remove a piece of tubule that I tear with the aid of fine needles over a glass dish, adding a drop of distilled water; I cover the preparation with a glass lid and then submit it to observation" ³. That was it - no formalin (which was still not commercially available), and no modern microtome sectioning; and, as for hematoxylin, Waldeyer was still fine-adjusting it around the time, and Sertoli was not using it yet.

This is how Sertoli described the 'branched cells' in his article of 1865: "These cells are irregularly cylindrical or conical with delicate borders and with nuclei that invariably contain a nucleolus. The cytoplasm is transparent, homogeneous, and always contains fine fat droplets. These cells are almost always furnished with very transparent fine processes in which fat droplets are also found (...). In some of these cells one sees a bifurcation or other secondary processes. Other cells of this type send out more processes that branch and sometimes envelop other cells" (...).

The description goes on in great detail ("Ho inoltre osservato che questi prolungamenti discostandosi dalla cellula formano delle curve, le quali corrispondendo ad altre formate o ad altri prolungamenti o da incurva-

mento all'interno di un lato della cellula, costituiscono come delle nicchie semicircolari nelle quali vengono ricettate le cellule seminifere (...). Le cellule seminifere sono fortemente aderenti alle pareti dei rispettivi ricettacoli, giacchè per il rotolamento io non riuscii mai a distaccarle"), and Sertoli comments on how acetic acid and iodine tincture affect the visibility of the cell. Figure 2 shows Sertoli's original drawings, which perfectly illustrate the branched form of these cells and spermatogenesis-supporting function that he envisaged for them, based on a detailed description (here reported only in part) of how these cells cluster to form concave niches. Not only the fat content in the cytoplasm, but also the adhesion of spermatogons and spermatids (that we can now attribute to the role of the adhesion molecules) had already been clearly recognized.

Another significant passage, but an erroneous observation in this case, is documented in Figure 3, accompanied by Sertoli's comment that: "The processes have also a further function: they guarantee the communication among the branched cells (...) so that the content of the cells is fused" (...).

Although Sertoli never mentioned the word 'syncytial', and some deny that he would have defined these branched cells as such ⁷, it seems to us that his own hand drawing leave little space for doubt on the matter. After all, a precise definition of the boundaries of these branched cells must have sometimes been very hard to achieve using the microscopes of Sertoli's time. Even in 1902, von Ebner (a convinced supporter of their nature as precursors of spermatids) ⁸ agreed that Sertoli's cells were syncytial ²⁷. Whether they were

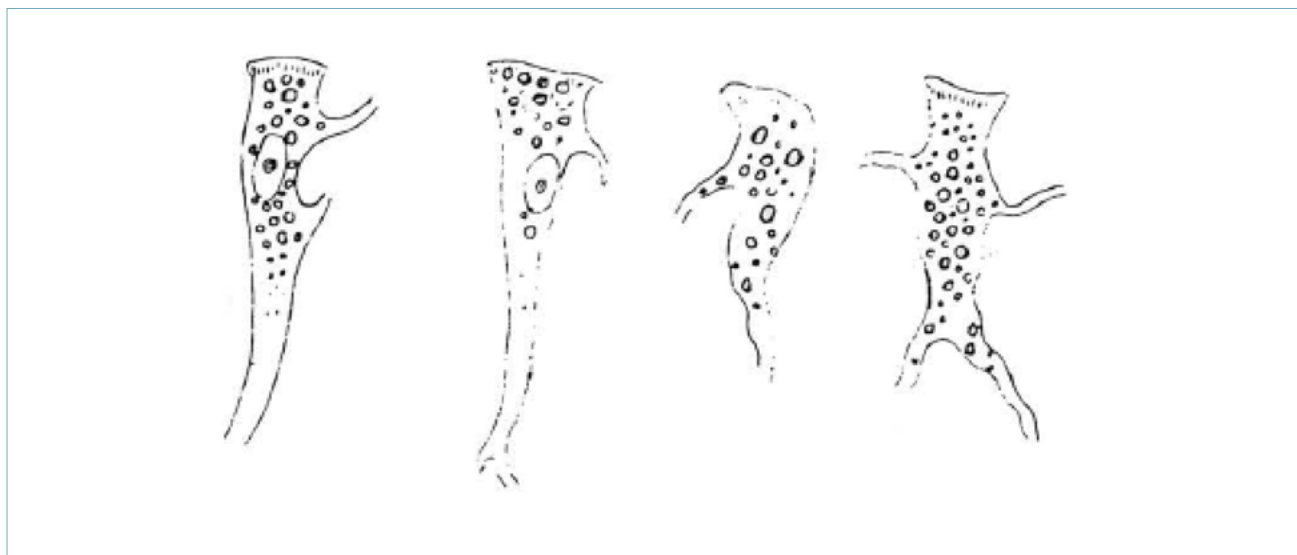

Fig. 2. (From Sertoli E. *Il Morgagni* 1865).

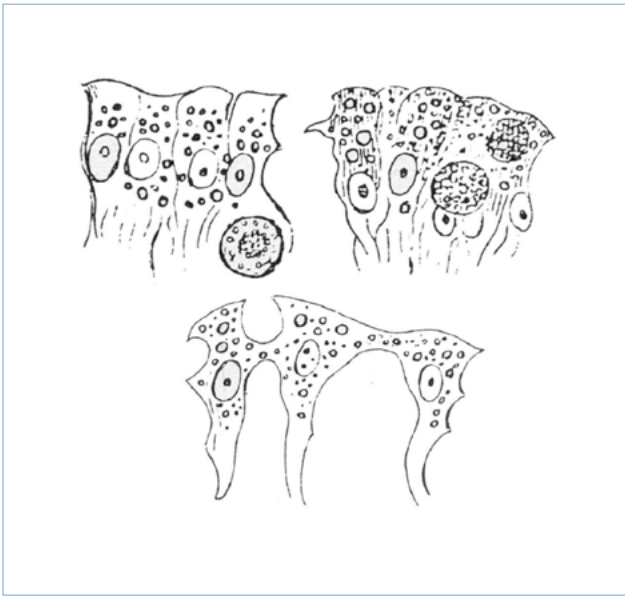

Fig. 3. (From Sertoli E. *Il Morgagni* 1865).

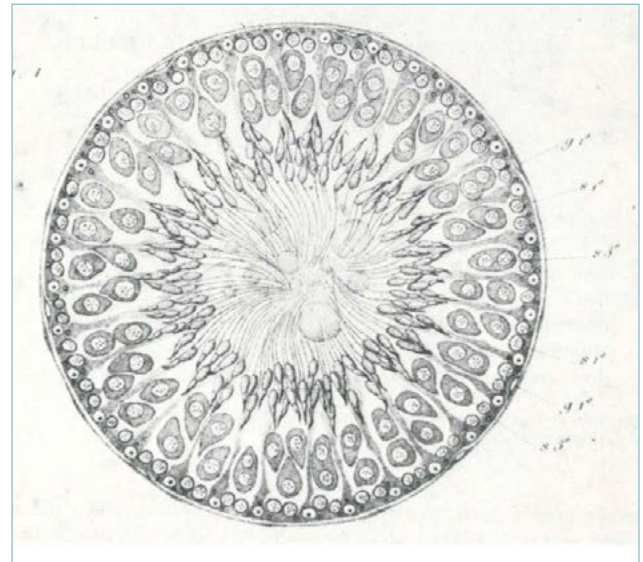


Fig. 4. Sertoli's idealized drawing of 1878 representing a cross section of a seminiferous tubule.

syncytial or not, according to Sertoli, the branched cells "are joined together in parallel": this finding was also a massive leap forward, and was only confirmed after 1960, in the modern anatomico-functional concept of the hemato-testicular barrier ^{7,8}.

Sertoli returned to the topic of branched cells in the 1870s ^{6,9,10}, when he clarified their post-mitotic nature, the so-called *fixed cells* (*Dans les cellules fixes (...) décrites sur le nom de cellules ramifiées, on n'observe pas le plus petit indice de caryokinèse, quel que soit le point du canalicule où on le examine* ¹⁰). This was when he started adding Muller fixative and silver nitrate, improving the quality of his lab technique. His work was so clear in its approach and scientific precocious, even on the topic of spermatogenesis (Sertoli provided an accurate description of its various stages) that what he wrote in 1878 ¹¹ was recently translated into English ⁸. These are writings in which, among other things, Sertoli quibbled with von Ebner, who called his cells 'spermatoblasts'. They also provide further topographical details of his studies, when he wrote that, adjacent to the *rete testis*, "I found that the cells in question little by little stopped presenting extensions. It is worth adding that, even today, pathologists daily engaging in diagnostics are still astounded by Sertoli's ability to describe the jagged contours of *his* cells using the means available to him in the 19th century.

For teaching purposes, Sertoli also tried to summarize his observations in the shape of a pattern, which became the forerunner of all subsequent schematic

representations in the histology manuals ¹² (Fig. 4). In later years Sertoli saw his name firmly attached to the branched cells (in 1888 von Ebner spoke of "Sertoli's cells"), and turned his keen gaze elsewhere. In



Fig. 5. Enrico Sertoli (photo from around 1900).

Number of publications with “Sertoli cell” in the title or abstract (NLM search).

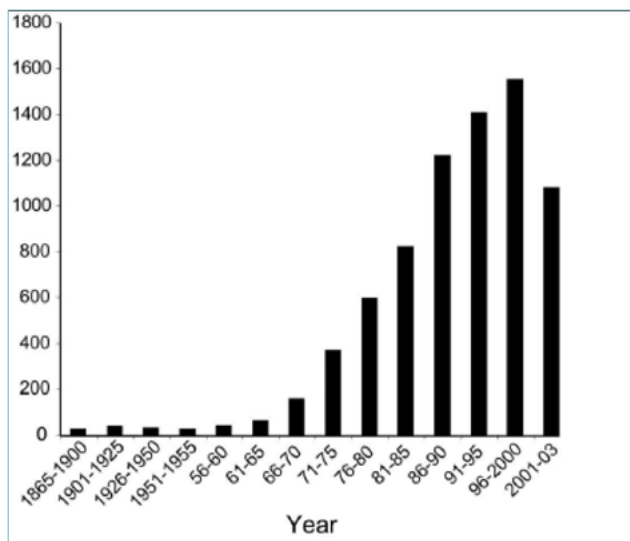


Fig. 6. (Modified from Rex A Hess 2005 Ref 2).

addition to running the institute of which he became director, his efforts became focused on new research fields (the lymphatic system, lung, muscle, kidney, etc.) that kept him busy for several years (Fig. 5)^{2 13 14}, until he decided to leave his university teaching post in 1907.

Despite the importance of Sertoli's discovery, the attention demonstrated by the scientific literature remained very limited for roughly half a century after Sertoli's death (in Sondrio in 1910). On average, Sertoli cells were only mentioned in about one publication a year (Fig. 6) up until the early 1950s, when Gunnar Teilum published his descriptions of Sertoli cell tumors^{15 16}.

Also in *Pathologica*, Sertoli's name almost eclipsed, surviving as a substantivized (*sertolization*) name in the descriptions of testicular atrophy¹⁷.

Some of the reasons for Sertoli's partial eclipse during the first half of the 20th century include: the introduction of electron microscopy only after the 1930s; the great interest in biology of germ cell maturation rather than of Sertoli cells; the lack of understanding in the field of endocrinology; the limited development of andrology and scarce interest in the topic of male infertility; and the rarity of tumors of the sexual cords. Today we know that Sertoli cell tumor (SCT) is a well characterized entity composed of cells resembling embryonal, prepubertal, and adult Sertoli cells. SCT accounts for < 1% of all testicular tumors, yet it is the second most common sex cord–stromal tumor.

SCT occurs in a wide range of age, most occurring in adults. Its rarity and some overlapping features with seminoma and other sex cord stromal tumors (Leydig, unclassified tumors) is a matter of difficult interpretation in the routine practice. Orchiectomy remains the only therapeutic option, because radiotherapy and chemotherapy have been unsuccessful to date. About 12% of SCTs are malignant¹⁸. Gynecomastia seems to be more frequent in malignant cases. Features predictive of aggressive behavior include extra-testicular spread, size > 5 cm, high-grade cytological atypia, > 5 mitoses per 10/HPFs, and necrosis and lymphovascular invasion. Recently the occurrence of *CTNNT1* gene mutations and nuclear displacement of β -catenin has been considered a driver mutation in the oncogenesis of this tumor in the majority of Sertoli cell tumors¹⁹.

In summary, what we label with Sertoli's name is a well known tumor. However, it has to be said that what happened to Sertoli is a far from an unusual case of posthumous acknowledgement of the value of a scientific discovery. Thinking of how a remarkable intuition can fade into oblivion brings to mind sadder cases, such as Ignac Semmelweis²⁰: the forerunner of anti-sepsis, he was rejected and forgotten by the scientific community of his time, only to gain his well-deserved place among the great names of medicine after his death.

References

- 1 *Discorso inaugurale dell'anno scolastico 1872-1873 della Reale Scuola Superiore di Veterinaria di Milano*. Milano: Tipografia L. Vietti, via Fiori Chiari 8.
- 2 Hess RA, Franca LSR. *History of the Sertoli cell discovery*. In: *Sertoli cell biology*. Chapt. 1. Griswold M, Skinner M, eds. Elsevier Inc. 2005, pp. 3-13. <https://doi.org/10.1016/B978-012647751-1/50002-7>
- 3 Sertoli E. *Dell'esistenza di particolari cellule ramificate nei canalicoli seminiferi del testicolo umano*. Il Morgagni 1865;7:31
- 4 Patriarca PL. *Storia della Medicina e della Sanità in Valtellina*. Sondrio: L'Officina del Libro 1998.
- 5 Uselli F. Enrico Sertoli. Estratto dall'“Annuario Veterinario Italiano” 1934-35. Roma.
- 6 Sertoli E. *Osservazioni sulla struttura dei canalicoli seminiferi del testicolo*. Gazzetta Medica Italiana. Lombardia 1871;52:413-5.
- 7 França LR, Hess RA, Dufour JM, et al. *The Sertoli cell: one hundred fifty years of beauty and plasticity*. Andrology 2016;4:189-212. <https://doi.org/10.1111/andr.12165>
- 8 Geyer CB. *A historical perspective on some “new” discoveries on spermatogenesis from the laboratory of Enrico Sertoli in 1878*. Biol Reprod 2018;99:671. <https://doi.org/10.1093/biolre/iox146>
- 9 Sertoli E. *Sulla struttura dei canalicoli seminiferi del testicolo studiata in rapporto allo sviluppo dei nemaspermi*. Gazzetta Medica Italiana. Lombardia 1875;2:401-3.
- 10 Sertoli E. *Sur la caryokinèse dans la spermatogénèse*. Archives Italiennes de Biologie. 1886;7:369-75.

- ¹¹ Sertoli E. *The structure of seminiferous tubules and the development of spermatids in rats*. Archivio per le scienze mediche. Turin: Vincenzo Bona 1878;1-76.
- ¹² Ober WB, Sciagura C. Leydig. *Sertoli and Reinke: three anatomists who were on the ball*. Pathology annual 1981;16:1-13.
- ¹³ Patriarca PL. *Enrico Sertoli: istologo e fisiologo*. Valtellina Med 1995;XI,2:47-50.
- ¹⁴ Baratelli G, Lanzani A, Sacco RN. *Biography of Enrico Sertoli*. Urology 2002;60:196-8.
- ¹⁵ Teilum G. *Estrogen-producing Sertoli cell tumors (Androblastoma tubular lipoides) of the human testis and ovary. Homologous ovarian and testicular tumors*. J Clin Endocrinol Metab 1949;9:301-18. <https://doi.org/10.1210/jcem-9-4-301>
- ¹⁶ Teilum G. *Classification of testicular and ovarian androblastoma and Sertoli cell tumors*. Cancer 1958;11:769-82. [https://doi.org/10.1002/1097-0142\(195807/08\)11:4<769::aid-cn-cr2820110415>3.0.co;2-y](https://doi.org/10.1002/1097-0142(195807/08)11:4<769::aid-cn-cr2820110415>3.0.co;2-y)
- ¹⁷ Badini A, Gambaro GC. *Considerazioni anatomo patologiche e cliniche sul cosiddetto pseudoseminoma del testicolo*. Pathologica 1968;LX:431-42.
- ¹⁸ Young RH, Koelliker DD, Scully RE. *Sertoli cell tumors of the testis, not otherwise specified: A clinicopathologic analysis of 60 cases*. Am J Surg Pathol 1998;22:709-21. <https://doi.org/10.1097/00000478-199806000-00008>
- ¹⁹ Perrone F, Bertolotti A, Montemurro G, et al. *Frequent mutation and nuclear localization of β -catenin in sertoli cell tumors of the testis*. Am J Surg Pathol 2014;38:66-71. <https://doi.org/10.1097/PAS.0b013e31829cdbc6>.
- ²⁰ Céline LF. *Il dottor Semmelweis*. Milano: Adelphi 1975.

Received and accepted: October 25, 2019