



Case Report

Thallium toxicity due to adulterated infusion with thallium sulfate in eight members belonging to the same family nucleus: Autopsy findings and ICP-MS analysis (inductively coupled plasma mass spectrometry) in a triple homicide

Domenico Di Candia¹, Enrico Muccino³, Alessio Battistini², Michele Boracchi⁴, Guendalina Gentile⁵, Riccardo Zoja^{6,*}

Laboratorio di Istopatologia Forense e Microbiologia Medico Legale, Sezione di Medicina Legale e delle Assicurazioni, Dipartimento di Scienze Biomediche per la Salute, Università degli Studi di Milano, Via Luigi Mangiagalli, 37, 20133 Milano, Italy

ARTICLE INFO

Keywords:

Acute thallium poisoning
Homicide
ICP-MS
forensic pathology

ABSTRACT

The banning of the heavy metal thallium (Tl) in many Countries, because of its toxicity, led to a remarkable reduction of the number of cases of poisoning both accidental and homicidal forcing us to better study the pharmacokinetics of this poison using new technologies. The Authors, in this work, are reporting the case of a collective thallium toxicosis caused by voluntary adulteration of an infusion with thallium sulfate, occurred in 8 members of the same familial nucleus; the administration of Prussian Blu resulted to be ineffective for 3 of these members that died at a later time.

The most peculiar aspects of this rare manner of poisoning are discussed; the analytical procedures used, Inductively Coupled Plasma Mass Spectrometry (ICP-MS) in particular, resulted to be fundamental in the forensic diagnosis process of acute poisoning cause by thallium.

1. Introduction

Among all the different intoxications caused by heavy metals, those caused by thallium (Tl) are still quite significant but can be usually enlisted as accidental or professional events [1], suicide attempts [2] and rare voluntary adulterations of food [3] with homicidal purposes [4–6]. The authors of these homicidal events take advantage of the high toxicity of this poison and its characteristics, being this substance colourless, tasteless, odourless and challenging both the clinician and the forensic pathologist in a difficult diagnosis that requires several investigations and a solid expertise.

The Authors, in the following manuscript, are reporting the data concerning an exceptional, unique case of homicidal thallium poisoning occurred in Italy and involving 8 members of the same family nucleus,

three of which deceased because of voluntary adulteration of a herbal infusion, poisoned with thallium sulphate by another member of the family, grandson of the victims. Single cases are discussed and the results of the toxicological-forensic analysis, fundamental in the outlining of the homicide event, assessed with ICP-MS, are reported (Table 1).

2. Case report

On October 2017, three members of a same family – an elderly couple and their oldest daughter – started to show symptoms of systemic malaise, dysentery, nausea, vomit, swelling, lack of energy, numbness, formication of the lower limbs, a sense of skin burning and fever and they were therefore carried to the closest A&E and hospitalized. The medical staff, detecting high concentration of thallium both

* Corresponding author.

E-mail address: riccardo.zoja@unimi.it (R. Zoja).

¹ ORCID: 0000-0003-1401-6815.

² ORCID: 0000-0001-6007-0658.

³ ORCID: 0000-0002-2217-9094.

⁴ ORCID: 0000-0002-4240-4121.

⁵ ORCID: 0000-0002-4407-9844.

⁶ ORCID: 0000-0003-3347-2541.

Table 1
Thallium concentrations detected in the victims during hospitalization and at toxicological-forensic exam.

| Victim | Matrix | Thallium dosing at hospital | Survival time | Post-mortem thallium dosing with ICP-MS |
|------------|-----------------|-----------------------------|---------------|---|
| Father | Blood | 3.40 mcg/mL | 2 days | 2.75 mcg/mL |
| | Urine | 22.00 mcg/mL | | 1.49 mcg/mL |
| | Gastric content | / | | 1.93 mcg/mL |
| | Hair | / | | 10.11 ng/mg |
| Daughter 1 | Blood | 10.00 mcg/mL | 2 days | 6.01 mcg/mL |
| | Urine | 42.00 mcg/mL | | / |
| | Gastric content | / | | 3.43 mcg/mL |
| | Hair | / | | 5.72 ng/mg |
| Mother | Blood | 5.70 mcg/mL | 14 days | 1.15 mcg/mL |
| | Urine | 16.30 mcg/mL | | / |
| | Gastric content | / | | 1.11 mcg/mL |
| | Hair | / | | 10.38 ng/mg |

plasmatic (father = 3.4 mcg/mL; mother = 5.7 mcg/mL; daughter = 10 mcg/mL) and urinary (father = 22.7 mg/L; mother = 16.3 mg/L; daughter = 42 mg/L), diagnosed a thallium toxicosis and administered a chelation therapy with Prussian Blu, reporting the fact to the law enforcement agency.

The following day five other members of the same family were brought to the same A&E – the two parents-in-law of the oldest daughter (daughter 1), the youngest daughter of the first couple of elderly people, the husband of the oldest daughter and the in-home nurse of the first couple (Fig. 1). These patients showed the same symptoms of the first three patients and the formulated diagnosis was identical.

Crime scene investigations were assessed on several houses belonging to the family and 70 specimens, environmental samples and food samples, among which an unlabeled infusion, were analyzed. According to the investigations carried out, a high dosage of thallium sulphate was detected in the same infusion that was regularly drunk by the whole family every afternoon. In fact, all the family members that drank the infusion had manifested the same symptoms and since the intoxication involved all the members of a specific family it was inferred that the poisoning was assessed with homicidal intentions.

The father and the oldest daughter, despite medical intervention, deceased 2 days after hospitalization, the mother after 14 days while the other 5 members of the family, even though seriously intoxicated, managed to survive.

3. Autopsy investigations

The Judicial Authority ordered the autopsy examination of the three corpses 3 days after the death of the patients. The examination was assessed at the Bureau of Legal Medicine of the University of Milan.

3.1. External examination

The corpses appeared to be in overall good conditions of preservation. A few signs of injections (forearm, latero-cervical region and wrists) were detected and traced back to the medical procedures administered during hospitalization.

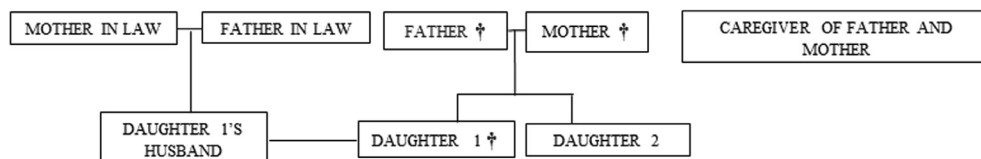


Fig. 1. Graphic representation of the parental relationship between the victims: the symbol † indicates the patients deceased.

3.2. Internal examination

1. Father: cadaver of male sex and Caucasian race, esteemed age between 90 and 95 years, average weight (length: 172 cm; weight 64 kg). At cadaveric dissection: cerebral hemorrhagic focus of a few millimeters of diameter; pleural petechiae; bilateral inflammation of the inferior pulmonary lobes; cardiomegaly; atherosclerosis and hepatic steatosis.
2. Daughter: cadaver of female sex and Caucasian race, esteemed age of 60–65 years, obese (length: 162 cm; weight: 94 kg). At cadaveric dissection it was possible to detect a thyroid gland of increased dimensions with fibrosis; bilateral pleural effusion; bilateral pleural petechiae, pulmonary edema; aortic valve disease and hepatic steatosis.
3. Mother: cadaver of female sex and Caucasian race, esteemed age between 85 and 90 years, average weight (length: 155 cm; weight 59 kg). At cadaveric dissection it was possible to notice the outcomes of a left temporal craniotomy, with related trans-dura mater surgical access; bilateral pleural effusion; bilateral posterior visceral-parietal pleural adhesions; bilateral pulmonary edema; inflammation of the middle and inferior pulmonary right lobes; mitral and aortic valve disease; tri-vascular coronary disease; sclerosis of the aorta and nephrosclerosis.

From all the corpses, during autopsy examination, an extensive sampling of all the biological matrices was assessed in order to carry out chemical-toxicological analysis. The samples collected were: femoral and cardiac blood, bile, urine and gastric content; fragments of brain, lungs, kidneys, liver and cholecystic mucosa, gastric mucosa, psoas muscle, adipose tissue, nail plates of all the fingers of both hands; nasal swabs and hair locks (6 proximal centimeters collected from the occipital area).

Moreover, in order to assess possible histological examinations, analysis that were not subsequently requested by the Judicial Authority, samples of brain, cerebellum, brainstem, thyroid, lungs, heart, stomach, liver, spleen, small intestine, kidneys, pancreas, adrenal glands and esophagus were collected.

At autopsy examination, for the three victims, no other lethal cause of death could be determined and the *exitus* could be ascribed to respiratory failure in a context of suspected intoxication for the father and for the oldest daughter and the mother, the cause of death was identified in multi-organ failure in a context of suspected acute intoxication from thallium.

4. Toxicological-forensic investigations

In order to confirm the episode of thallium poisoning, already detected with *intra-vitam* analysis assessed during hospitalization, we proceeded with toxicological post-mortem investigations on biological matrices sampled during the autopsy examination of the three corpses. Toxicological screening was assessed following the Bureau of Legal Medicine of the University of Milan's standard procedures and we assessed a targeted research of the most common substances of abuse.

Psychoactive drugs (cocaine, amphetamines, ecstasy, methadone, opioids and ketamine) were screened with immune-enzymatic analysis (ELISA) using a Dinex instrument and analyzing femoral blood, cardiac blood and a liver specimen. The three victims did not show positivity for these molecules. BAC (Blood Alcohol Content) assessed with gas

chromatography and HPB-Alc column with head-space technique in order to detect a qualitative-quantitative value of ethylic alcohol in femoral blood; all victims resulted to be negative. Organic volatile substances screened with gas chromatography with CP Sil 8MS/LB column. All victims resulted to be negative for these substances.

In order to better target the research for metals, since *intra-vitam* exams showed a severe thallium toxicosis, we proceeded with a quantitative evaluation of thallium via ICP-MS analysis on several biological matrices sampled during autopsy examination.

For the preparation of the samples in order to assess ICP-MS analysis, 0.5 mL of femoral blood, 0.5 mL urine and 0.5 mL of gastric content were digested according to EPA DG-CL-03 standard procedures. Nitric acid (HNO₃, 69% Hiperpur Solution) and hydrogen peroxide (H₂O₂, 30% Hiperpur Solution) were purchased from Panreac Quimica SLU (Castellar del Valles, Barcelona, Spain). Purified water was obtained through a Milli-Q system (Millipore, Merck KGaA, Darmstadt, Germany). Together with these samples, we proceeded with the digestion of the calibration points as well, prepared with appropriate dilutions of an Agilent standard thallium in an aqueous solution of 5% HNO₃. Each sample was mineralized according to the previously cited EPA digestion method.

For the preparation of the hair samples, a hair lock from each cadaver was segmented into three different sections each: a sample was composed by the proximal 2 cm of hair, the second sample was composed by the medial 2 cm of hair and the third sample was composed by the 2 distal centimeters of hair. 250 mg of each of the 9 hair samples was then digested according to EPA DG-CL-10 standard procedures. A calibration curve, specific for hair samples, was prepared and digested following the same EPA procedure used for the biological samples. The inductively coupled plasma mass spectrometer (Agilent 7500ce, Agilent Technologies, Santa Clara, CA, USA) used in our study was equipped with a Cetac ASX-510 auto-sampler (Thermo Fisher Scientific, San Jose, CA, USA). Argon and helium utilized were pure at 99.999%. Internal standard solution was prepared from a stock Agilent Yttrium standard solution of by appropriate diluting using 1% (v/v) nitric acid till a concentration of 1 mcg/mL and added by peristaltic pump.

The high concentrations of thallium detected in the biological matrices concerning the three victims (Table 1), much higher compared to doses already considered as lethal under a toxicological point of view, evaluated in a range between 0.5 and 11 mcg/mL, were considered as coherent with the clinical presentation of the intoxication and the diagnosis was evaluated to be of an acute intoxication of the metal, orally administered and responsible for their death.

The Judicial Authority did not allow the analysis on biological samples collected from the survived five members of the family nor the divulgation of the analytical results obtained during hospitalization of the patients.

5. Police investigations

After two months of investigations, Police agents found a non-deleted e-mail on the computer of a 27-year-old grandson of the elderly couple, son of the younger daughter. The e-mail concerned a solicit for the delivery of 6 flacons of thallium sulphate for a total weight of 60 g ordered in June. The Inquiring Authority detected, moreover, a series of phone calls in which the suspect contacted a Paduan industry specialized in the commerce of thallium. The man personally collected the poison – according to the analysis of the cell-phone calls used by his mobile phone – providing fake identification, cash paying the substance and justifying his trip to his relatives saying that he was traveling in order to sustain a job interview.

The unemployed accountant was enrolled in a Jews sect since 3 years before called Second Vatican Council and, following the *hikikomori* rules (a Japanese word meaning “being confined”), voluntarily lived isolated from the external world and social life, spending his days using his personal computer.

Interrogated by the law enforcement agents, he confessed he had attempted to adulterate several times the infusion his mother was used to prepare every afternoon and serve to her old parents and other family members, all reunited to drink it, with thallium sulphate in order to estimate the proper dose to cause the death of his relatives. According to his confession, the motivation for such an act was that he considered his family “guilty of being impure” and “too attached to material goods”.

The young man was therefore arrested and accused of triple first-degree murder and quintuple attempted murder but he was then found not guilty due to complete mental illness and sentenced to 10 years of judicial psychiatric hospital.

6. Discussions

We presented the exceptional and unique case of thallium-toxicosis that took place in Italy in 2017 due to voluntary adulteration of an infusion with thallium sulphate and occurred in eight members of the same family, three of which died because of the intoxication. According to the investigations assessed, the poison was placed in a herbal infusion that was consumed by the all family every afternoon and the perpetrator was identified in a grandson of the victims, later accused of triple homicide and attempted homicide of five other people.

Heavy metals' toxicity can be caused, apart from criminal actions, because of environmental exposure, professional poisoning or accidental events: in all these cases, the diagnosis achieved with general clinical practice is quite rare and is characterized by high mortality and morbidity if the cause is not promptly recognized and treated. When involved in crimes like those exposed in our work, thallium intoxication can be mis-detected due to the wide range of presentation symptoms of the intoxication, to the physical characteristics of the substance (colorless, tasteless and odorless) and to the symptoms that may vary from events that may be confused with other common diseases (chronic thallium-toxicosis) to more specific events (acute thallium-toxicosis). The first symptoms of poisoning, within the first 48 h from the intoxication, may include gastric-intestinal symptoms (abdominal pain, cramps, fever and constipation), acute cardiotoxic effects, hematic signs (anemia and thrombocytopenia), followed by neurotoxic symptoms (tremor, acute and progressive paralysis of the limbs, coma), mutagenic effects [7] and genotoxic events [8]. Within 3 weeks, usually, alopecia appears mainly to the eyebrows and the axillary area.

Acute intoxication from thallium (the lethal dose in men is estimated to be between 8 and 12 mg/kg; the lethal plasmatic concentration is considered to be between 0.5 and 11 mcg/mL) is an exceptional and often rare condition [9] and is one of the most rare and complex situations studied [10]: in the biological processes, thallium acts in a way similar to potassium but with an affinity 10 times higher, replacing this latter substance in a series of enzymatic complexes, especially mitochondrial, that need this substance as an activator and ending up being damaged [11]. In fact, the immediate administration of thallium, via any way of administration, generates lethal effects caused by a complete upsetting of important processes with a mechanism that has not yet been clarified [12]. Moreover, other mechanisms are suspected of having an important role in these processes as the already cited oxidative stress, the interruption of the potassium-regulated homeostasis and of the glutathione metabolism [13].

Therapy, in cases of thallium intoxications, consists in the administration of chelating agents able of binding the substance in order to facilitate renal metabolism and elimination from the blood stream. Prussian Blue is the substance commonly used with an extremely slow process – 78% of the dose is eliminated in a month, mostly, with feces – but the death can occur precociously due to cardiocirculatory failure or, belatedly, for multi-organ failure related to the global effects of the poison on the cellular metabolism [14].

Despite its terrible properties, thallium has been used in time with several medical purposes as in treating cutaneous mycosis, gonorrhoea,

syphilis and TBC [4] while its radioisotopes –thallium-201– are currently used in the diagnosis of melanomas and in cardiac scintigraphy [1].

Thallium is a toxic “heavy metal” [15] that can be found in low concentrations [16] in several minerals of the Earth crust [13] and used in many industries: bijoux [17], photography and optical lenses [18], dyeing and pigments [17], concrete industries [6], waxing products [19] and for green fireworks [20] that take advantage of the spectral emissions of this element [21].

It's in the form of salts and solutions –sulfate, acetate and carbonate, with a concentration of 2% as a rat poison [17]– that thallium exerts its lethal action: in particular, when sulfate, it's called the “poisoner's poison” [22] because, similarly to arsenic, it is tasteless [23], colorless [4] and odorless [23]. Thanks to its properties it rapidly disappears from biological fluids, causing a diagnostic delay [23] it is of difficult detection during standard toxicological analysis, even though it is rapidly distributed to several organs – brain, heart, liver, adrenal glands, cartilages, hair and nails [24].

In the cases treated in this work, the demonstration of high concentrations of thallium in biological matrices (cardiac blood, urine, gastric content and hair) sampled from the three victims during autopsy examination, was assessed with a very sensible analytical technique for detecting the presence of these trace elements and able of measuring ppq (part-per-quadrillion) quantities in solution: the ICP-MS [25]. Hair samples were taken from the occipital area of the scalp, according to the Italian Healthcare Minister's guidelines, since this region is richly vascularized granting a more reliable distribution of substances of toxicological interest in this matrix. The presence of thallium in the first 2 cm of hair analyzed with ICP-MS technique, and the absence of the element in the remaining 4 distal centimeters, was in accordance with the several attempted adulterations put in place by the indicted and confessed during interrogation by the police. The concentrations of thallium in the distal 4 cm of hair were lower than 0.02 ng/mg and so to be considered of no toxicological interest: the negativity of the distal end of the hair locks underlined that the homicide attempts had started no more than two months before the effective death of the three relatives of the murderer.

The evidence of autopsy investigations, together with toxicological analysis, thanks to the aid provided by this sensible and specific technique, demonstrated the presence of high concentrations of thallium in the biological material examined, and was of fundamental help in building up the accuse of lethal thallium-toxicity in the analyzed cases. In fact, this present work of forensic interest stands up as an example of assistance for those cases where clinical and pathological-forensic signs can mislead due to unclear signs of intoxication, acute neurological symptoms not otherwise specified and aspects similar to Guillain-Barré syndrome [4] and highlights how the ICP-MS is a fundamental analysis in similar cases where the perpetrators take advantage of the delayed diagnosis for destroying critical proofs.

Declaration of Competing Interest

The authors declare that they have no known competing financial

interests or personal relationships that could have appeared to influence the work reported in this paper.

References

- [1] D. Ibrahim, B. Froberg, A. Wolf, D.E. Rusyniak, Heavy metal poisoning: clinical presentations and pathophysiology, *Clin. Lab. Med.* 26 (2006) 67–97.
- [2] M. Sojáková, M. Žigrai, A. Karaman, S. Plačková, P. Klepančová, Š. Hrušovský, Thallium intoxication. Case Report, *Neuro Endocrinol. Lett.* 36 (2015) 311–315.
- [3] W.J. Meggs, R. Cahill-Morasco, R.D. Shih, L.R. Goldfrank, R.S. Hoffman, Effects of Prussian blue and N-acetylcysteine on thallium toxicity in mice, *J. Toxicol. Clin. Toxicol.* 35 (1997) 163–166.
- [4] Q. Wang, X. Huang, L. Liu, Analysis of nine cases of acute thallium poisoning, *J. Huazhong Univ. Sci. Technol. Med. Sci.* 27 (2007) 213–216.
- [5] J.O. Aasly, Thallium intoxication with metallic skin discoloration, *Neurology* 22 (68) (2007) 1869.
- [6] S. Hann, C. Latkoczy, T.L. Bereuter, T. Prohaska, G. Stinger, C. Reiter, Reconstruction of a case of thallium poisoning using LA-ICP-SFMS, *Int. J. Legal Med.* 119 (2005) 35–39.
- [7] Y. Jiang, W. Xia, B. Zhang, X. Pan, W. Liu, S. Jin, W. Huo, H. Liu, Y. Peng, X. Sun, H. Zhang, A. Zhou, S. Xu, Y. Li, Predictors of thallium exposure and its relation with preterm birth, *Environ. Pollut.* 12 (2017) S0269-7491(17)32797-5.
- [8] J.J. Rodriguez-Mercado, M.A. Altamirano-Lozano, Genetic toxicology of thallium: a review, *Drug Chem. Toxicol.* 36 (2013) 369–383.
- [9] H.T. Zhang, B.P. Qiao, B.P. Liu, X.G. Zhao, Study on the treatment of acute thallium poisoning, *Am. J. Med. Sci.* 347 (2014) 377–381.
- [10] R.S. Hoffman, Thallium toxicity and the role of Prussian blue in therapy, *Toxicol. Rev.* 22 (2003) 29–40.
- [11] L. Osorio-Rico, A. Santamaria, S. Galván-Arzate, Thallium toxicity: general issues, neurological symptoms, and neurotoxic mechanisms, *Adv. Neurobiol.* 18 (2017) 345–353.
- [12] A. Lennartson, Toxic thallium, *Nat. Chem.* 7 (2015) 610.
- [13] P. Cvjetko, I. Cvjetko, M. Pavlica, Thallium toxicity in humans, *Arh. Hig. Rada Toksikol.* 61 (2010) 111–119.
- [14] S. Salehi, A.S. Saljooghi, S. Badiie, M.M. Moqadam, Chelation of Thallium (III) in rats using combined deferasirox and deferiprone therapy, *Toxicol. Res.* 33 (2017) 299–304.
- [15] S. Li, W. Huang, Y. Duan, J. Xing, Y. Zhou, Human fatality due to thallium poisoning: autopsy, microscopy, and mass spectrometry assays, *J. Forensic Sci.* 60 (2015) 247–251.
- [16] C. Huang, X. Zhang, G. Li, Y. Jiang, Q. Wang, R. Tian, A case of severe thallium poisoning successfully treated with hemoperfusion and continuous veno-venous hemofiltration, *Hum. Exp. Toxicol.* 33 (2014) 554–558.
- [17] S. Galvan-Arzate, A. Santamaria, Thallium toxicity, *Toxicol. Lett.* 99 (1998) 1–13.
- [18] A. Ghaderi, N. Vahdati-Mashhadian, Z. Oghabian, V. Moradi, R. Afshari, O. Mehrpour, Thallium exists in opioid poisoned patients, *Daru* 1 (23) (2015) 39.
- [19] E. Marmo, M.G. Matera, R. Acampora, et al., Prenatal and postnatal metal exposure: effect on vasomotor reactivity development of pups: experimental research with antimony trichloride, thallium sulfate and sodium metavanadate, *Curr. Ther. Res.* 42 (1987) 823–838.
- [20] H.W. Ryu, D.H. Lee, H. Won, K.H. Kim, Y.J. Seong, S.H. Kwon, Influence of toxicologically relevant metals on human epigenetic regulation, *Toxicol. Res.* 31 (2015) 1–9.
- [21] M.E. Weeks, The discovery of the elements. XIII. Supplementary note on the discovery of thallium, *J. Chem. Educ.* 9 (1932) 2078.
- [22] H. Hasan, The Boron Elements: Boron, Aluminum, Gallium, Indium, Thallium, Rosen Publishing Group, 2009, p. 14 ISBN 978-1-4358-5333-1.
- [23] S. Senthilkumar, N. Balamurugan, N.N. Jena, R.G. Menezes, P. Thirumalaikolundusubramanian, Acute alopecia: evidence to thallium poisoning, *Int. J. Trichol.* 9 (2017) 30–32.
- [24] A.B. Fischer, T. Eikmann, Vorkommen und toxikologie von thallium, *Umweltmed. Forsch. Prax.* 7 (2002) 321–327.
- [25] A.K. Das, R. Chakraborty, M.L. Cervera, M. de la Guardia, Determination of thallium in biological samples, *Anal. Bioanal. Chem.* 385 (2006) 665–670.