

Non surgical treatment of Crouzon Syndrome

Cinzia Maspero, Lucia Giannini, Guido Galbiati, Laima Kairyte, Giampietro Farronato

SUMMARY

Crouzon syndrome is an autosomal dominant disorder with variable expressivity, characterized by skull and facial malformations. Such alterations vary from case to case. Management requires multidisciplinary approach. Two cases of two sisters affected by Crouzon syndrome are described. Treatment was performed by orthopedic and orthodontic devices without surgery. Good esthetics and functional results were obtained. Five-year follow-up records are presented.

Key words: Crouzon Syndrome; Craniosynostosis; FGFR 2.

INTRODUCTION

Craniofaciosynostosis represents one of the most common congenital malformations affecting human skull. Crouzon's syndrome is the most frequently occurring member of this group. The incidence of this disease is currently estimated to occur in 1 out of every 25,000 people out of the general population while its frequency ranges from 4.5 to 4.8% of all craniosynostosis (1).

Crouzon Syndrome is characterized by a premature fusion of superior and posterior sutures of the maxilla along the wall of the orbit. These early synostosis can involve cranial vault, cranial base, the orbital region and maxillary area (2). Crouzon disease, is much more variable in severity from patient to patient and the facial dysmorphology ranges from mild to severe.

The developmental arrest affects the maxilla, the orbit and the vault and the alterations mainly concern the sagittal dimensions of the face. The most notable characteristic is the underdevelopment of the midface and eyes that seem to bulge from their sockets (3). There may be a component of true extrusion of the eyes, however, because when cranial sutures became synostosed, intercranial pressure increases.

It has an autosomal dominant transmission caused by mutations in the FGFR-2 gene which is mapped on

the chromosome locus 10q25-10q26, with variable expressivity; 50% of incidence of Crouzon syndrome are not inherited and are the result of new mutation (1, 4). Some authors underline that this pathology involves male gender more frequently than females one with a preponderance of 3:1 (5) other ones find no differences between gender (1).

In order to permit brain development, a compensatory growth towards other non ossified sutures causes facial deformities (1). In fact, if the synostosis between the orbital region and maxillary bones precedes maxillary development downward and forward, an important underdevelopment of the midface occurs. An early diagnosis might guide craniofacial growth and development in order to minimize the consequences of this pathology and improve the success of therapy.

Oral common features manifestation are maxillary hypoplasia usually present and it leads to a skeletal class III malocclusion with upper incisors crowding, V-shaped upper arch, mandibular prognathism and sometimes cleft lip and palate and bifid ugula (1, 5).

Craniofacial dysostosis treatment is usually surgical and prognosis depends on the severity of the pathology. A multidisciplinary approach is surely the best treatment (1).

The aim of this work consists in presenting two cases report of two sisters affected by Crouzon Syndrome treated with a non-surgical approach. Orthopedic and orthodontic treatment is described and a five years follow up records are presented.

TWO CASE REPORTS

Two sisters, 5 and 6 years old, were referred to the Department of Pedodontics and Orthodontics of

*Maxillo-Facial and Odontostomatology Unit, Fondazione IRCCS Cà Granda – Ospedale Maggiore Policlinico, University of Milan, Milan, Italy

Cinzia Maspero* – M.D., D.D.S.

Lucia Giannini* – D.D.S.

Guido Galbiati* – D.D.S.

Laima Kairyte* – D.D.S.

Giampietro Farronato* – M.D., D.D.S.

Address correspondence to Prof. Giampietro Farronato, Via Comenda 10, 20122 Milan Italy.

E-mail address: giampietro.farronato@unimi.it

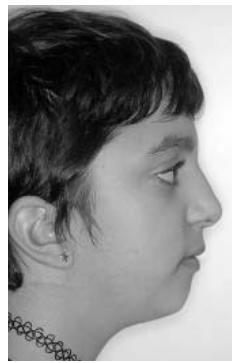
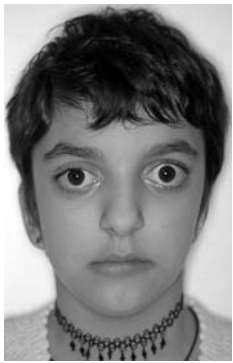
Fig. 1. Extraoral frontal view at treatment beginning

Fig. 2. Extraoral lateral view at treatment beginning

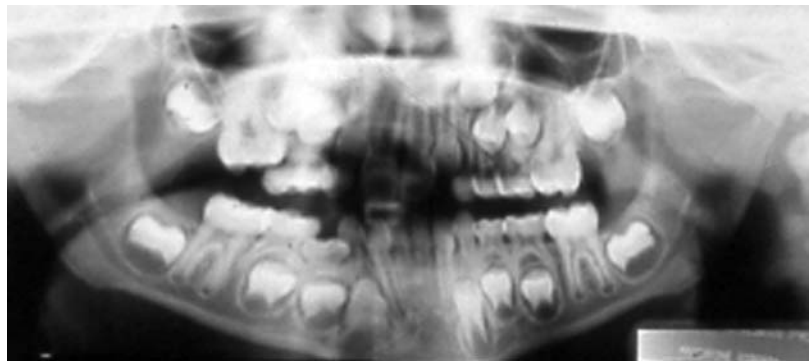


Fig. 4. Panoramic radiograph at treatment beginning

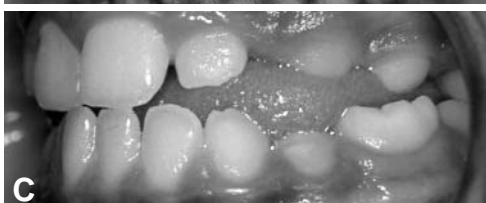
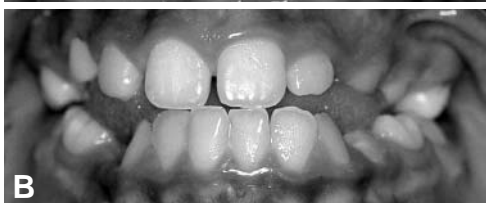
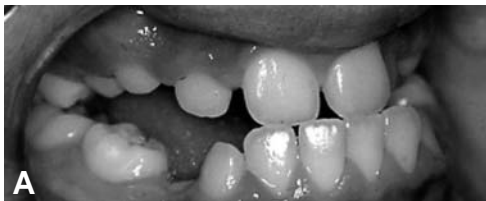Fig. 3. Intraoral frontal (B), and lateral (A, C) views at treatment beginning

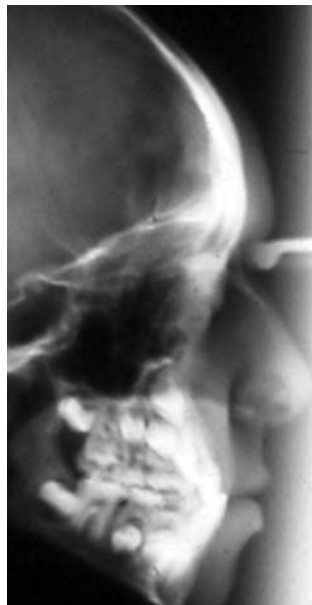

Fig. 5. Lateral radiograph at the beginning of the treatment

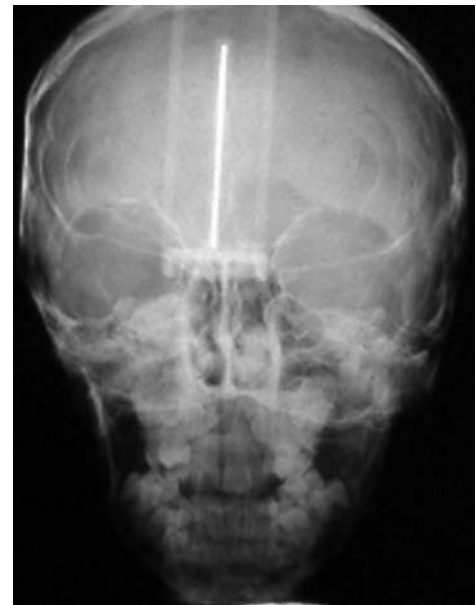

Fig. 6. Frontal radiograph at treatment beginning

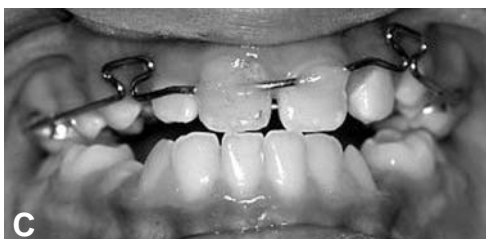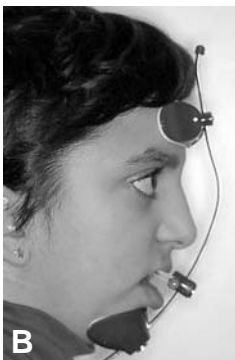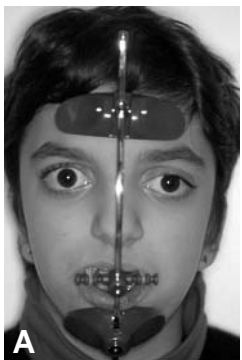


Fig. 7. Extraoral frontal (A), lateral (B) and intraoral (C) views with the facemask

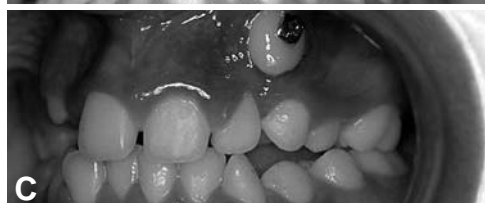
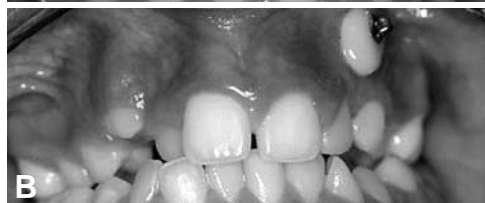
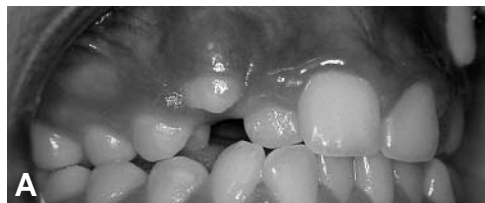Fig. 8. Intraoral frontal (B) and lateral (A, C) views at the removal of the facemask

tion by the Center of Craniofacial Disorders after a diagnosis of Crozon syndrome by the genetist. During the medical history the parents referred that the surgical treatment to relieve cranial sutures was not necessary because the intracranial pressure was under the limit requiring surgical decompression and it didn't cause compression of the optic nerve and hydrocephalus.

The parents described a normal intelligence with good study results. They were not

Milan University for dental and orthodontic consulta-

any medications and denied any medical history. The

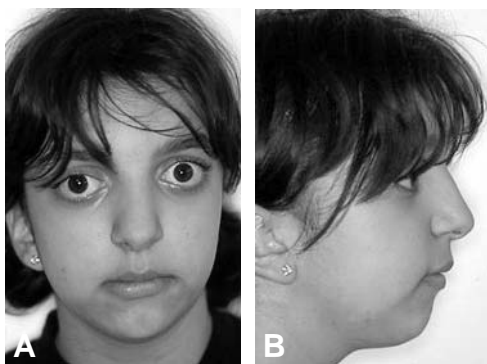


Fig. 9. Extraoral frontal (A) and lateral (B) views at the beginning of the orthodontic fixed therapy

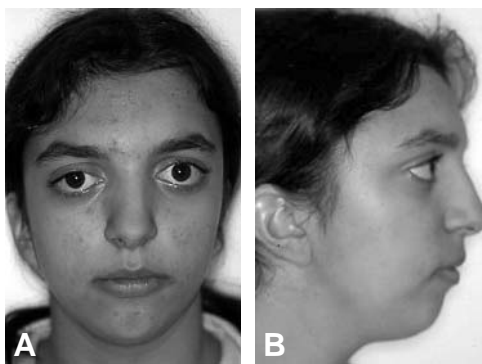

Fig. 12. Extraoral frontal (A) and lateral (B) views at the end of the orthodontic fixed therapy

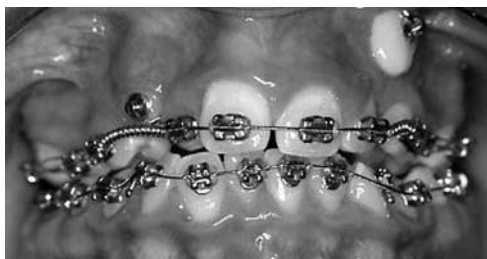

Fig. 10. Intraoral frontal view at the beginning of the fixed therapy

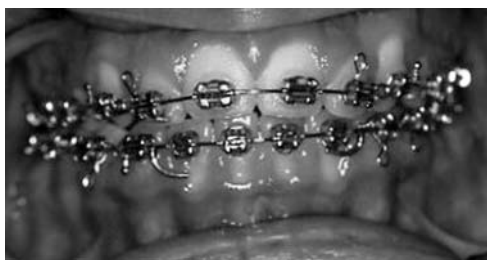

Fig. 11. Intraoral frontal view at the end of the fixed therapy

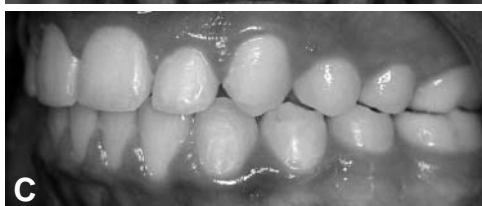
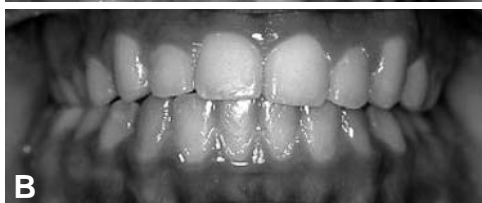
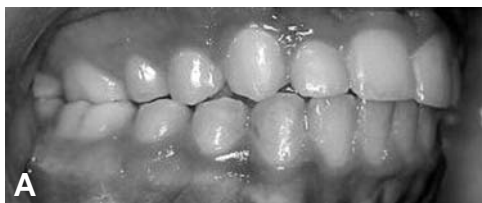Fig. 13. Intraoral frontal (B) and lateral (A, C) views at the end of the fixed therapy

ophthalmologic consultation revealed reduced vision and the audiology test was within normal limits in both sisters.

Case report 1

MR was 6-years old. Extraoral frontal examination showed exophthalmus, strabismus, gross proptosis, hypertelorism, midface hypoplasia, facial asymmetry (eyebrows, eyes, ears) and a laterodeviation of the mandible to the left side (Fig. 1). The profile view showed a mild parrot beak nose, everted lower lip, a concave-type soft tissue facial profile with a retrusive maxillary-type facial deformity due to the hypoplastic maxilla (Fig. 2).

The intraoral examination permitted us to observe a mixed dentition, a dental Class III on the right side (Fig. 3A) and a dental Class I on the left side (Fig. 3B). The lower midline was shifted on the left side while the upper one on the right side (Fig. 3C).

Maxillary hypoplasia was evident with a narrow deep upper arch and a posterior left cross bite. A retruded maxilla was also present showing an anterior cross

bite with posterior open bite on both sides from the lateral incisors to the first permanent molars. No digital abnormalities were seen. The parents reported reduced vision.

The panoramic radiograph (Fig. 4) showed the presence of all the permanent teeth buds. The lateral cephalometric examination indicated a skeletal maxillary and mandibular retrusion (SNA was 70° ; SNB was 73°) and a skeletal open bite. (Fig. 5) The ANB angle was -3° confirming the class III skeletal relationship (Table).

The frontal telera-diography confirmed the facial asymmetry with the right side of the face higher than the left side, the mandibular deviation on the left side and the narrow maxilla. The nasal septum and the nasal cavity were also asymmetric (Fig. 6). The assessment of the skeletal age accord-

ing to Bjork (6) and Grave et al. (7) with the evaluation of hand-wrist radiograph, confirmed a skeletal age of 6.

Treatment objectives:

- to correct the skeletal transverse and sagittal maxillary discrepancy to obtain a stable skeletal class I relationship to provide a more favorable environment for normal growth;
- to recover the integrity of the upper and lower arch;
- to solve dental crowding and level and align teeth to obtain a right and left class I occlusion with coincident midlines and ideal overbite and overjet.

After an explanation was given, informed consent was obtained from the parents of the patient.

Treatment plan and progress

The objectives were to correct the skeletal maxillary deficiency, the class III malocclusion and the retrusive maxillary-type facial deformity caused by maxillary hypoplasia. The treatment plan proposed was as follows:

- orthodontic treatment planning included a rapid palatal expansion with a Hyrax expander activated with a quarter turn twice per day for fifteen days. The expansion obtained was about 7.5 mm. The appliance was then blocked by using a metal ligature wire and was then kept passively in place for 4-6 months to wait for the drifting of the incisors into the space created by the expansion and to stabilize the results. After six months the palatal expander was removed and a

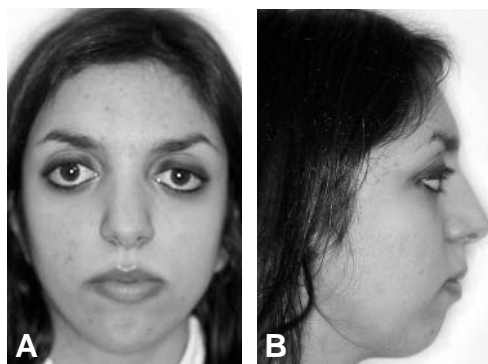


Fig. 15. Extraoral frontal (A) and lateral (B) views at the follow up controls

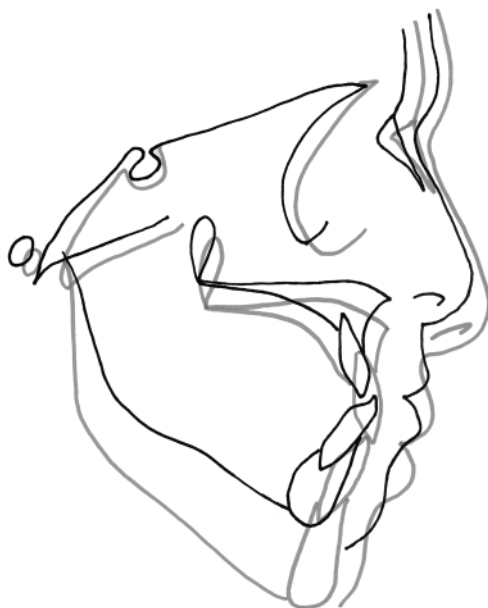

Fig. 14. Cephalometric superimpositions. In black the pretreatment tracing, in grey the posttreatment one.

postero-anterior facemask was applied in order to stimulate maxillary anterior growth and relieve maxillary sutures (Fig. 7). The patient was instructed to wear the facemask for protraction regularly for 12 hours a day. The amount of force used which was directed forward and downward to the occlusal plane, to avoid opening the bite was 400 g for each side. After 18 months the postero-anterior facemask was removed. Intraoral examination showed correct interarch relationships and dental class I with normal overjet and overbite. (Fig. 8) The facial examination showed better proportions of the third of the face (Fig. 9A). The profile was improved. (Figure 9B) Advancement of the maxillary segment was confirmed by the lateral cephalometric examination which indicated the presence of a skeletal class I with the following cephalometric measurements: SNA 74°, SNB 72°, ANB +2°. The SNA measurement indicates that the



Fig. 16. Smile of the patient at the follow up controls

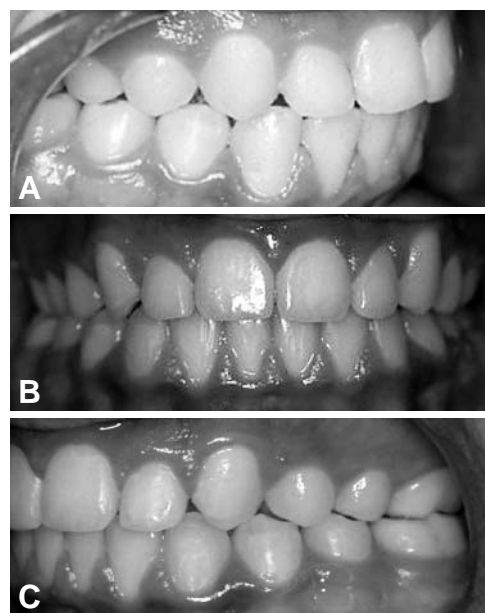


Fig. 17. Intraoral frontal (B) and lateral (A, C) views at the follow up controls

maxilla moved forward as a consequence of the RME-facemask therapy.

- When all permanent teeth, except the two maxillary canines, were erupted a fixed appliance therapy with a low friction technique was performed (Fig. 10). The vestibular erupting maxillary canines were then bonded in order to guide their correct eruption.
- After 24 months the appliance could be removed (Fig. 11).

Results

Facial examination showed a more symmetrical face, a natural lip posture. The maxillary retrusive facial profile improved showing an harmonic profile (Fig. 12).

The positions of the upper and lower lips relative to the esthetic line had improved. Intraoral examination showed a dental Class I on both side, normal interarch relationship and the coincidence of midlines (Fig. 13). The overjet and overbite were within the norm. A remarkable change in facial form from a maxillary



Fig. 18. Extraoral frontal view at treatment beginning



Fig. 19. Extraoral lateral view at treatment beginning

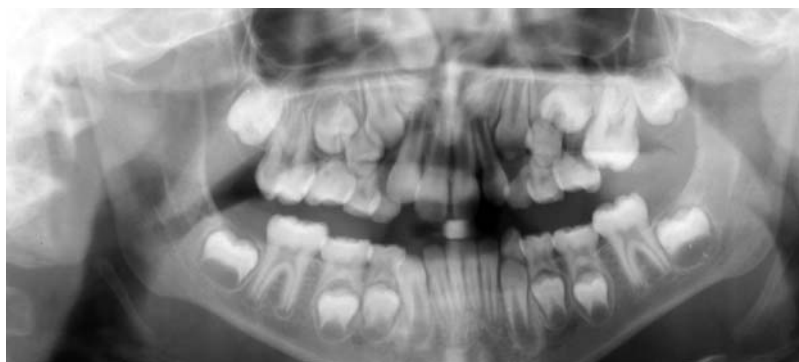

Fig. 21. Panoramic radiograph at treatment beginning

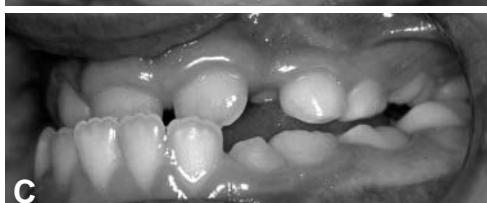
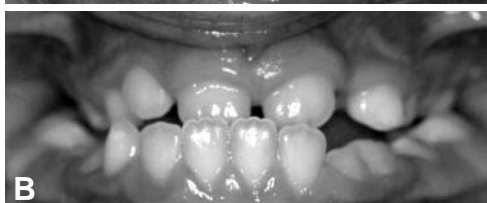
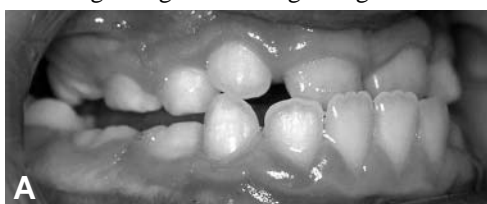Fig. 20. Intraoral frontal (B), and lateral (A, C) views at treatment beginning

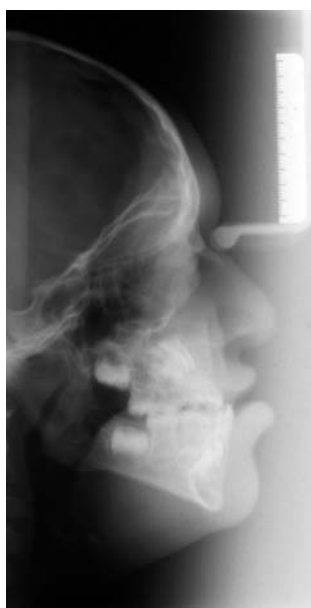

Fig. 22. Lateral radiograph at the beginning of the treatment

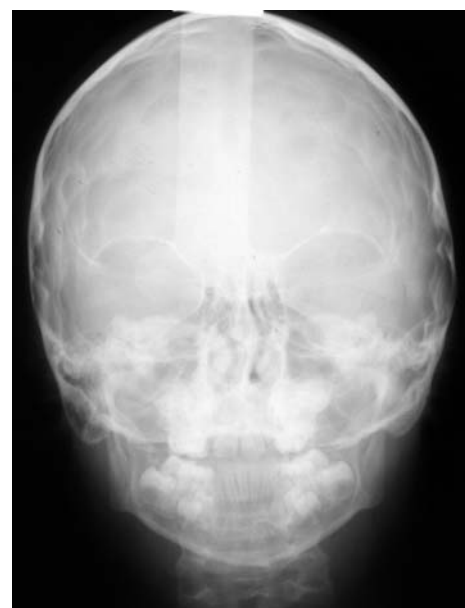

Fig. 23. Frontal radiograph at treatment beginning

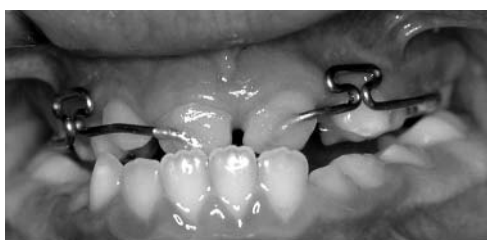

Fig. 24. Intraoral frontal view at the beginning of the Rapid Maxillary Expansion

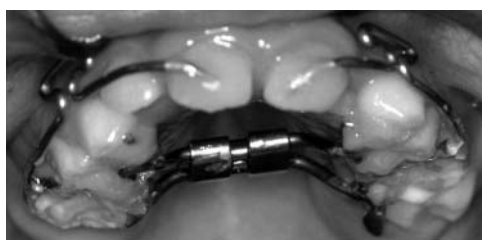

Fig. 25. Intraoral occlusal view at the beginning of the Rapid Maxillary Expansion

retrusive-type facial profile to an harmonic type profile was noted, the positions of the upper and lower lips relative to the esthetic line had improved.

The cephalometric measurements confirmed the presence of a skeletal class I with the maxilla in a stable position. The cephalometric superimposition showed that significant maxillary advancement had occurred. (Fig.14)

Point porion (P) and orbitale (Or) were drawn on the first cephalogram, transferred to the second cephalogram, and dotted by superimposition on the stable struc-

tures of the cranial base, as suggested by Bjork et al. (8-14). The coordinate analysis is based on a reference system consisting of horizontal (FH) and vertical (TFH) lines. Point T, the superior point of the anterior wall of the sella turcica at the junction

with tuberculum sellae, was used as the origin (9, 10). The Frankfort horizontal plane of the first radiogram was used as the best estimate for the FH, and the line perpendicular to this plane through point T was TFH.

After treatment, a significant increase in the SNA angle and A-TFH distance showed that the maxilla moved forward. The mean value of SNA increased 4.5° and A-TFH increased 2.34 mm. The correction of ANB was enhanced by a mild downward-backward rotation of the mandible. The retention appliance consisted of a positioner to be worn during the night. The patient and

the parents were satisfied with her facial and dental aesthetics.

An improvement of the eye proptosis and exorbitism was also obtained probably due to the action of the face-mask which stimulated the forward displacement of the maxillary bone. The patient referred also a constant improvement of the vision in age confirmed by the ophthalmologic examination. She was then scheduled in a maintenance program with periodical controls.

A 5 years follow up control showed a well proportioned soft tissue profile, the occlusion remained stable with normal overjet, overbite and dental alignment. Correct vertical dimension was maintained. (Figures 15-17).

Clinical case 2

MS was 5 years-old.

Facial frontal examination showed a mild exophthalmos and hypertelorism and midface's hypoplasia due to retruded maxilla, relatively large mandible with deviation on the left side resulting in a mild asymmetry (Fig. 18).

The profile showed a reduction of the lower facial third, everted lower lip and a mild parrot beak nose (Fig. 19). She was wearing glasses because her vision was reduced. No digital abnormalities were present.

The intraoral examination showed the presence of mixed dentition, dental class III on both side. The lower midline was shifted to the left side due to the mandibular deviation on the same side. The maxilla was hypoplastic and retruded showing anterior and posterior bilateral cross bite (Fig. 20).

The panoramic radiograph showed the presence of all permanent teeth buds (Fig. 21). The lateral radiograph showed a skeletal class III with a normal vertical dimension (Fig. 22).

Maxillary anterior-posterior length was short and the maxilla was located in a significantly retrognathic position. Mandibular body length and mandibular



Fig. 26. Extraoral lateral view at the beginning of the facemask therapy

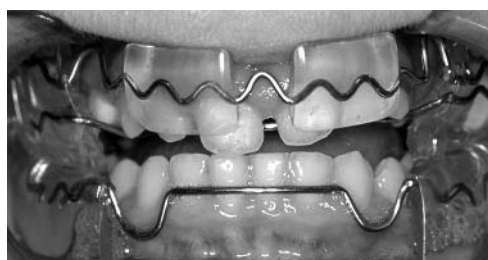

Fig. 27. Intraoral frontal view at the beginning of the therapy with Frankel III

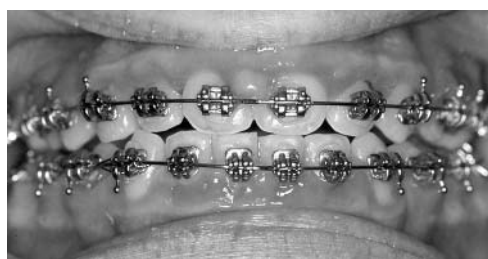

Fig. 28. Intraoral frontal view at the beginning of the fixed therapy

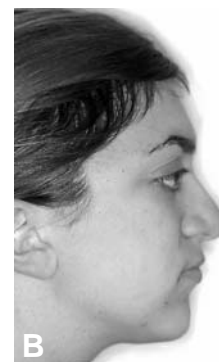

Fig. 29. Extraoral frontal (A) and lateral (B) view at the end of the orthodontic fixed therapy

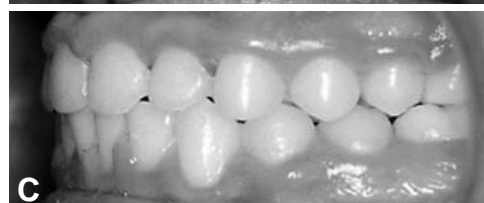
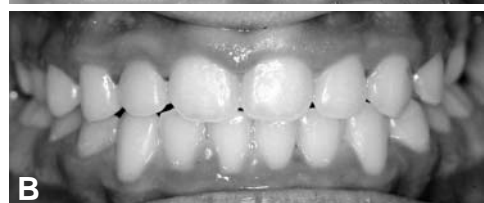
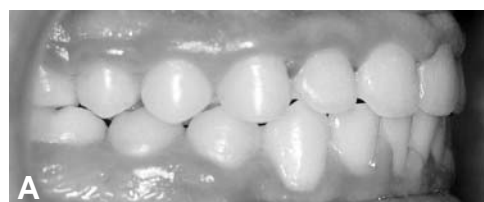Fig. 30. Intraoral frontal (B) and lateral (A, C) views at the the end of the orthodontic fixed therapy

plane angle were normal but mandible were relatively repositioned [SNA angle was 71° , SNB 72.5° and ANB -1.5°].

The upper incisors were lingually inclined, the lower incisors showed a lingual inclination. The frontal telerradiography (Fig. 23) showed a reduced lower third and the mandibular latero deviation on the left side. The nasal septum was also deviated. The assessment of the skeletal age according to Bjork (12) and Grave et al. (13) with the evaluation of hand-wrist radiograph, confirmed a skeletal age of 5.

Treatment objectives:

- To correct the skeletal transverse and sagittal maxillary discrepancy to obtain a stable skeletal class I relationship;
- To solve dental crowding and level and align teeth to obtain a right and left class I occlusion with coincident midlines and ideal overbite and overjet.

After the explanation was given, informed consent was obtained from the parents.

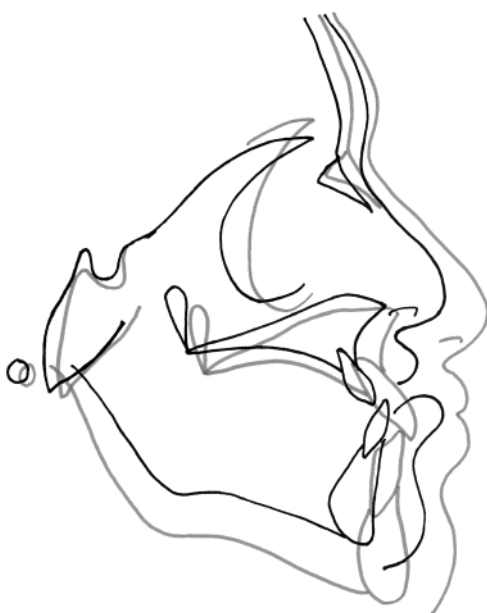


Fig. 31. Cephalometric superimpositions. In black the pretreatment tracing, in grey the posttreatment one

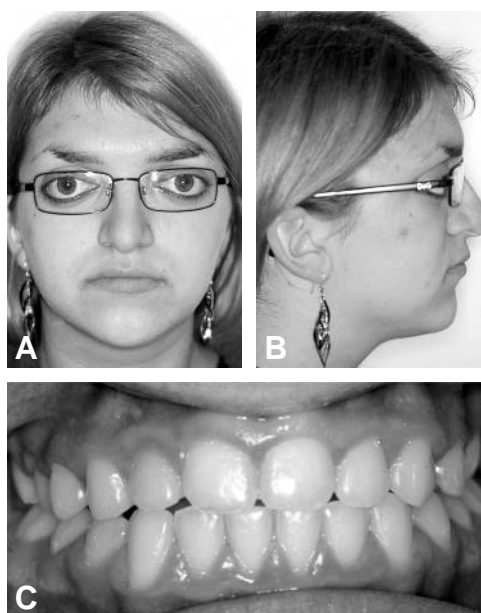


Fig. 32. Extraoral (A, B) and intraoral (C) views at follow up controls



Fig. 33. Smile of the patient at follow up controls

Treatment plan and progress

Treatment plan proposed was as follows:

- orthodontic treatment planning comprehend a rapid palatal expansion with a modified Hyrax expander activated with a quarter turn twice per day for fifteen days and then kept passively in place for 4-6 months to wait for the drifting of the incisors into the space created by the expansion and to stabilize the results (Figures 24, 25).

Table. Cephalometric values before and after therapy

Values	Clinical Case 1		Clinical Case 2	
Angular, degrees				
SNA	70	74	71	74
SNB	73	72	72,5	73
ANB	-3	2	-1.5	1
SN-MP	28	48	41	44
FH-MP	29	32	28	28
U1 to SN	92	90	92	104
U1 to FH	84	100	106	120
L1 to MP	92	80	96	90
L1 to FH	56	65	55	50
Linear, millimetres				
SN	66	70	66	69
GoMe	56	70	54	60
ArGo	40	45	36	42
ArMe	90	105	85	100
Nme	106	130	100	120
OJ	-3	1.5	-3	2
OB	-1	1.5	0	2
Gonial	140	132	140	131

After six months the palatal expander was removed and a postero-anterior facemask was applied in order to stimulate maxillary anterior growth and relieve the

maxillary sutures. (Fig. 26) The patient was instructed to wear the facemask for 12 hours a day. The amount of force used was 400 gr for each side, and it was directed forward and downward to the occlusal plane, to avoid opening the bite. The cephalometric measurements underlined the presence of a skeletal class I (ANB was 1°) due to a forward movement of the maxilla under the effect of the facemask (SNA was 74°). The ANB angle changed from -3° to +2°. The maxilla was advanced 4 mm horizontally. The upper incisors were tipped labially. A good intertincisal relationship was established. The cephalometric superimposition as described above showed a significant maxillary advancement. After treatment, a significant increase in the SNA angle and A-TFH distance showed that the maxilla moved forward. The mean value of SNA increased 2° and A-TFH increased 2.50 mm. The negative overjet was corrected. The correction of ANB was enhanced by a mild downward-backward rotation of the mandible.

- A functional appliance (Frankel III) was then applied in order to maintain normal skeletal relationships (Fig. 27).
- After 18 months, when all permanent teeth, were erupted a fixed appliance therapy with a low friction technique was performed (Fig. 28).
- After 18 months the appliance could be removed.

Results

Facial examination showed a symmetrical face, a natural lip posture and an harmonic profile (Fig. 29).

Intraoral examination showed a dental class I on both side and normal interarch relationship (Fig. 30). The overjet and overbite were within the norm. The retention appliance consisted of a positioner to be worn during the night and the patient was then scheduled in a maintenance program with periodical controls.

The patient was satisfied with her facial and dental aesthetics. There was also an improvement of the eye proptosis and exorbitism. These effects are probably consequences of the action of the orthopaedic therapy. On the other side, the patient described also an improvement of the vision confirmed by the ophthalmologic examination.

The cephalometric superimposition showed the significative maxillary advancement which has occurred. (Fig. 31) Stable occlusal relationship with dental alignment and correct vertical dimension were maintained in the follow up controls. (Figures 32, 33) She was then scheduled in a maintenance program with periodical recalls.

The 5 years follow-up examination showed well positioned soft tissue. The occlusion was stable with normal overjet and overbite.

DISCUSSION

Therapeutic procedures in Crouzon patients usually include surgical intervention in order to minimize facial and dental consequences. Management of symptoms and complications requires multidisciplinary approach by a team working together with the family. Prognosis depends on severity of malformations.

If the head circumference is within normal parameters, if intracranial pressure is within the limits which doesn't cause hydrocephalus and the patients show normal mental development an orthopedic approach with orthodontic devices can be adopted as the cases shown in this paper. The distraction approach to the midface deformity at an early age with orthopedic devices like RME and the face mask can accomplish horizontal advancement and vertical lengthening of the midface and the transverse maxillary increase.

These effects have been well described in many studies (8). According to these authors and their studies the transverse widening would stimulate remodel-

ing at lateral and posterior maxillary sutures and thus increase have favourable anteroposterior response (9).

The orthopedic force of the RME-facemask therapy stimulates cellular activity in circummaxillary sutures and maxillary tubercula, and this facilitates maxillary forward displacement (10). To obtain successful forward movement it is essential that the patient is before age 8 (9). The results obtained in these two cases report can confirm this theory. In fact with the devices used it was possible to obtain an advancement of the midface obtaining good esthetic results.

The reference system used in these cases report was appropriate for the evaluation of skeletal changes. The structures of the cranial base, such as the contour of the anterior wall of the sella turcica, the anterior contours of the middle cranial fossae, and the contour of the cribriform plate and the bilateral fronto-etmoidal, were proven to be stable by Bjork et al. (8). Point T was proven to be a stable point by Bjork et al. (8) and Viazis (11). Orthodontic treatment by fixed multibracket appliance was then performed to reach a functional occlusion. This study evidences that also a non surgical approach in patients with mild Crouzon syndrome allows obtaining a good facial and dental esthetics.

Early treatment allows to obtain higher possibilities to correct the facial asymmetry (12, 13).

CONCLUSIONS

- Crouzon syndrome generally requires Le Fort III advancement osteotomies followed by distraction (14). The cases report described in this paper permit to underline that if the patients present a moderate skull involvement and are still growing also with orthopedic treatment it is possible to obtain optimal results.

- The positive results of this study, consistent with long-term findings of other authors, confirm the success of nonsurgical-functional approach with RME-Facemask functional therapy in growing Crouzon patients (15-17).

- A combination of orthopedic and orthodontic treatment was found to be effective for improving the appearance and occlusion of patients with mild Crouzon syndrome, without surgery.

REFERENCES

1. Bowling EL, Burstein FD. Crouzon syndrome. *Optometry* 2006;77:217-22.
2. Posnick JC. The craniofacial dysostosis syndrome: current reconstructive strategies. *Clin Plast Surg* 1994;21:585-98.
3. Fries PD, Katowitz JA. Congenital craniofacial anomalies of ophthalmic importance. *Surv Ophthalmol* 1990;35:87-119.
4. Arnaud-Lopez L, Fragoso R, Mantilla-Capacho J, Barros-Núñez P. Crouzon with acanthosis nigricans. Further delineation of the syndrome. *Clin Genet* 2007;72:405-10.
5. Gorlin RJ, Cohen MM Jr, Levin LS. Syndromes of the head and neck. 3rd ed. New York: Oxford University Press; 1990. p.516-26.
6. Bjork A. Timing of interceptive orthodontic measures

- based on stages of maturation. *Trans Eur Orthod Soc* 1972;61-74.
7. Rakosi T, Jonas I, Graber TM. Orthodontic diagnosis. Thieme Med. Publ. Inc.; 1993.
 8. Bjork A, Skieller V. Normal and abnormal growth of the mandible: a synthesis of longitudinal cephalometric implant studies over a period of 25 years. *Eur J Orthod* 1983;5:1-46.
 9. Proffit WR, Fields HW Jr, Sarver DM. *Ortodonzia moderna*. 3rd ed. Elsevier Masson; 2008.
 10. Kambara T. Dentofacial changes produced by extra-oral forward force in the *Macaca irus*. *Am J Orthod* 1971;71:249-77.
 11. Viazis AD. The cranial base triangle. *J Clin Orthod* 1991;25:565-70.
 12. Elmi P, Reitsma JH, Buschang PH, Wolvius EB, Ongkosuwito EM. Mandibular asymmetry in patients with the crouzon or apert syndrome. *Cleft Palate Craniofac J* 2014 May 30. [Epub ahead of print].
 13. Gothwal S, Nayan S, Kumar J. Crouzon syndrome with bony upper airway obstruction: case report and review literature. *Fetal Pediatr Pathol* 2014;33:199-201.
 14. Mohadeb JV, Lu YQ, Aldowaji AK, Gu X, Zhang Q, Xu P, Yang C. Management of Crouzon syndrome in an adult patient. *J Clin Orthod* 2013;4:673-80.
 15. Farronato G, Cannalire P, Martinelli G, Tubertini I, Giannini L, Galbiati G, et al. Cleft lip and/or palate: review. *Minerva Stomatol* 2014;63:111-26.
 16. Farronato G, Giannini L, Galbiati G, Cannalire P, Martinelli G, Tubertini I, et al. Oral tissues and orthodontic treatment: common side effects. *Minerva Stomatol* 2013;62:431-46.
 17. Farronato G, Maspero C, Esposito L, Briguglio E, Farronato D, Giannini L. Rapid maxillary expansion in growing patients. Hyrax versus transverse sagittal maxillary expander: a cephalometric investigation. *Eur J Orthod* 2011;33:185-9.

Received: 14 01 2014

Accepted for publishing: 20 06 2014