

Rapid Maxillary Expander and Eruption Guidance Appliance therapy in skeletal Class II: cephalometric considerations



C. Maspero¹, G. Begnoni², A. Magnani³,
M. Farronato³, N. Khomchyna⁴,
C. Dellavia⁵

Department of Biomedical, Surgical and Oral Sciences,
University of Milan, Fondazione IRCCS Cà Granda, Milan, Italy

¹ Assistant Professor

² DDS, Ph.D.

³ DDS, Ph.D.

⁴ Student in Dentistry

⁵ Associate Professor of Human Anatomy

e-mail: giacomo.begnoni@unimi.it

DOI 10.23804/ejpd.2019.20.04.04

Abstract

Aim The use of rapid maxillary expander (RME) combined with eruption guidance appliances (EGA) represents a valid method in the treatment of skeletal Class II deep bite patients. In this paper a retrospective cephalometric study of the effects of RME and EGA therapy in Class II deep bite patients is described and compared with the treatment effects of patients with the same malocclusion treated only by RME.

Materials and methods Pre and post treatment cephalometric radiographs of 47 Class II division 1 deep bite growing patients treated with RME followed by EGA (mean age 9.65 years) (Group 1) were compared with those obtained from a control group (Group 2) of 44 patients (mean age 9.34 years) treated with RME only. The following cephalometric values were analyzed: SNA; SNB; ANB; SN-PNS.ANS; SN-Go. GN; N-Me; S-Go.

Results Improvement in maxillo-mandibular relationship was observed in both groups with significantly higher decrease of SNA and ANB in group 1. The cranio-maxillary relation shows a tendency to grow downward and backward in both groups. Both anterior and posterior total facial heights showed a significant increase in group 1.

Conclusions RME followed by EGA therapy in Class II skeletal deep bite patients has shown better results compared with RME therapy without functional appliance.

Introduction

Class II malocclusion is the most frequent skeletal sagittal disharmony in Caucasian populations [Proffit, 2001].

Mandibular growth can be influenced by a variety of functional orthopaedic appliances because of the skeletal and neuromuscular adaptations that occur as a response to therapy [Proffit, 2001; Koretsi et al., 2016; Burhan and Nawaya, 2015; Ehsani et al., 2015; D'Antò et al., 2015; Perillo et al., 2011]. In skeletal Class II malocclusion the correction of sagittal discrepancy can be complicated by maxillary transverse hypoplasia. In fact, in the literature many papers describe the orthopaedic corrective effects of the rapid maxillary expander (RME) both on the sagittal and vertical planes in skeletal Class II patients [Conroy-Piskai et al., 2016; Farronato et al., 2011a; Farronato et al., 2011b; Volk et al., 2010; McNamara et al., 2010].

According to some authors, the use of RME itself in growing patients permits the correction of mild Class II malocclusions [Farronato et al., 2011a; Farronato et al., 2011b]. The eruption guidance appliance (EAG) is a removable elastodontic device indicated in Class I and II mixed or permanent dentition; its main indication is to guide the eruption of posterior teeth in Class I relationship, while at the same time advancing the mandible, correcting the overbite and increasing the neuromuscular balance [Keski-Nisula et al., 2008; Janson et al., 2000; Nilsson et al., 2016; Janson et al., 2007; Myrlund et al., 2015; Migliaccio et al., 2014; Farronato et al., 2013].

RME, permits an easy management of Class II malocclusions by benefiting from the resolution of the maxillary contraction to improve the growth potential of the mandible [McNamara et al., 2010].

The aim of this study is to analyse the cephalometric effects of RME and EGA therapy in Class II growing patients.

Materials and methods

The present study was approved by a research project of Fondazione IRCCS Cà Granda Ospedale Maggiore Policlinico

KEYWORDS Occlus-o-Guide; Eruption guidance appliance; Rapid maxillary expander; Skeletal Class II; Functional therapy.

(n. 3 OU 420/425 - research year 2018) and all procedures and materials in the present study were approved by the ethics committee of "Fondazione IRCCS Cà Granda Ospedale Maggiore Policlinico" "B Area", number 421 of 09/03/2016.

The selection criteria for patient participation were:

- maxillary transverse hypoplasia;
- skeletal and dental Class II malocclusion;
- skeletal and dental deep bite;
- IV period of the carpal growth index (pubertal spurt);
- no temporomandibular joint disorders;
- absence of periodontal disease;
- no previous orthodontic treatment.

An informed consent was signed by all the parents of the patients.

Two cephalometric tracings were available for each patient. The first one was taken before diagnosis (T1) and the second one at the end of treatment (T2). Cephalometric analyses were performed by one trained investigator (GB).

Patients were divided into two groups.

Group 1

Group 1 consisted of 47 Caucasian patients (24 males and 23 females) with an initial mean age of 9.65 years treated with RME (Fig. 1) and EGA (Fig. 2). The rapid palatal expander was activated twice a day (0.5 mm expansion a day) for 14 consecutive days [Farronato et al., 2011a] until the desired expansion was achieved. Then an occlusal radiograph was taken to verify that the opening of the palatal suture had occurred, after which the expansion screw was "locked" by a metal ligature wire. The appliance was removed after 6 months after its last activation.

Phase 2 of the treatment involved the use of eruption guidance appliance 2 to 4 hours during the day and all night.

For all patients included in group 1 lateral radiographs were obtained before treatment (T1) with RME and after completion of functional therapy with EGA (T2).

Group 2

Group 2 consisted of 44 patients (20 males and 24 females) with an initial mean age of 9.34 years. All patients received only RME therapy to correct the maxillary hypoplasia.

Cephalometric analysis

All the lateral radiographies were taken at the same radiology department by the same technician.

The cephalometric analysis was based on the cephalometric tracing proposed by the Milan University [Farronato et al. 2011a]. The assessment of the skeletal relationships was based on the following cephalometric values: SNA, SNB and ANB angles. S.N-ANS.PNS, S.N-GO.GN, N-Me (anterior facial height-AFH), and S-GO (posterior facial height-PFH) (Fig. 3).

Measurement error

To evaluate the repeatability of the measurements, all measurements were taken twice by the same operator at both T1 and T2 in subsamples of both groups, and no significant differences were found with the Student t test for paired data ($p < .05$).

Statistical analysis

Descriptive statistics for each measurement were calculated to enable characterisation of both groups. At first, for each variable, the difference (variation) between the

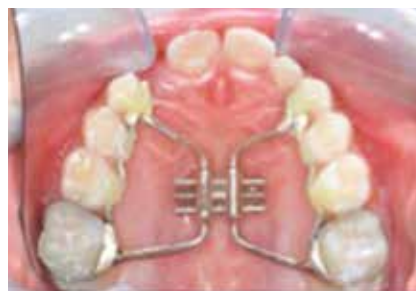

FIG. 1 Rapid maxillary expander (RME).

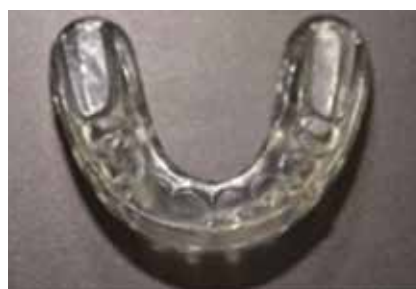

FIG. 2 Eruption guidance appliance (EGA).

values at T2 and T1 was calculated. Then, a Student t test for independent samples was performed to detect significant differences between the variations of each measurement between groups. The P value of < 0.05 was considered significant.

Results

Before treatment, patients of both groups showed similar cephalometric characteristics and were similar in age.

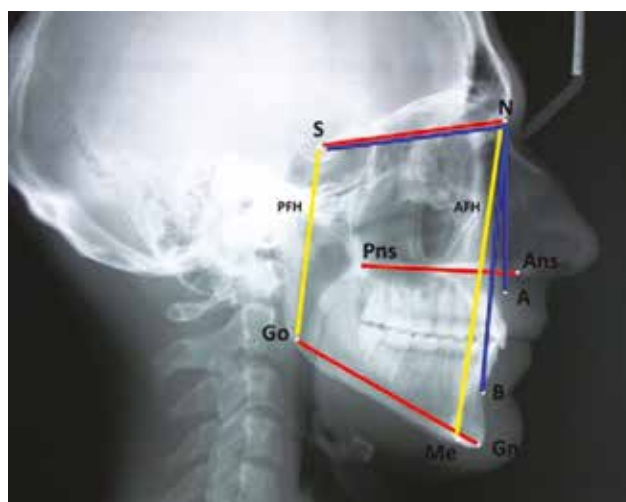


FIG. 3 Cephalometric landmarks, lines and planes: S, sella; N, Nasion; A, Subspinal; B, Supramental; Ans, Anterior nasal spine; Pns, Posterior nasal spine; Me, Menton; Go, Gonion; Gn, Gnathion. Angular Measurements (blue): SNA; SNB; ANB. Planes (red): Mandibular plane-MP (Go.Gn); Cranial plane-CP (S.N); Palatal plane-PP (Ans.Pns). Linear Measurements (yellow): AFH, Anterior Facial Height (N.Me); PFH, Posterior Facial Height (S.Go).

	Group-1 (T1)		Group-2 (T1)	
	Mean	SD	Mean	SD
Age (years)	9.65	1.35	9.34	1.03
Sagittal Relationship				
SNA (°)	82.87	2.61	81.8	1.68
SNB (°)	77.32	2.46	76	2
ANB (°)	5.55	1.01	5.8	1.1
S.N-Go.Gn (°) (CP-MP)	31.22	4.16	32.8	3.7
S.N-Ans.Pns (°) (CP-PP)	8.65	2.64	9.48	1.77
Vertical Relationship				
N-Me (AFH) (mm)	107.03	7.82	108.3	2.3
S-Go (PFH) (mm)	66.37	7.35	65.15	1.95

TABLE 1 Mean and standard deviations of age and cephalometric parameters (sagittal and vertical relationship) of both groups at T1.

	Variations (T2-T1) in Group-1		Variations (T2-T1) in Group 2		Student t test (Group-1 vs Group-2 variations)
	Mean	SD	Mean	SD	
Sagittal Relationship					
SNA (°)	-0.71	1.92	0.43	0.42	P<0.0001***
SNB (°)	1.72	1.78	2.29	0.85	NS
ANB (°)	-2.37	1.03	-1.85	0.69	P<0.01**
S.N-Go.Gn (°) (CP-MP)	0.77	2.69	0.78	0.68	NS
S.N-Ans.Pns (°) (CP-PP)	0.2	1.88	0.99	0.49	NS
Vertical Relationship					
N-Me (AFH) (mm)	7.95	5.87	-0.32	0.68	P<0.0001***
S-Go (PFH) (mm)	6.13	5.21	0.46	0.54	P<0.0001***

TABLE 2 Mean, standard deviations of the cephalometric variations (T2-T1) of each group, and Student t test for unpaired samples between groups (*: P<0.05; **: P<0.01; ***: P<0.001).

Descriptive statistics of both groups at T1 and T2 are presented in Table 1, whereas the variations of each measurement between T2 and T1 and statistical analysis are showed in Table 2. During the treatment period a reduction of SNA (-0.71°), an increase of SNB (+1.72°) with a final reduction of ANB (-2.37°) were observed in group 1. In group 2, during the treatment period an increase of both SNA (+0.43°) and SNB (+2.29°) with a final reduction of ANB (-1.85°) were found. Significant differences were observed in the variations between the groups considering SNA (p<.0001) and ANB (p<.01), with a greater reduction in group 1.

No statistical differences were observed between groups considering the relationship between the different facial planes: cranial plane (CP), palatal (PP) and mandibular (MP) plane. In both groups, a moderate increase in the relationship between CP and PP (+0.2° in group 1, +0.99° in group 2) and between CP and MP (+0.77° in group 1, +0.78° in group 2) were found.

Regarding the vertical effects, higher differences were obtained in group 1 compared to group 2 for both AFH (+7.95 mm vs -0.32 mm) and PFH (+6.13 mm vs +0.46 mm). Significant differences were observed in both vertical measurements between the two groups (p<.0001).

Discussion

In this paper a case-control study that analyses the advantages of a functional appliance therapy (EGA) after palatal expansion (RME) in skeletal Class II deep bite patients is described. The effects on the sagittal and vertical dimensions and between the facial planes are the following.

Sagittal effects

SNA tends to increase in the RME therapy group (+0.43°) and to decrease in the RME-EGA group (-0.7°) showing a high significant difference (<0.001) between groups. Before the puberal growth spurt, the maxilla grows more than the mandible, and this trend is amplified by the use of RME. Nevertheless, the use of the EGA restricts forward maxillary growth as confirmed by Janson et al. [2000], who observed a similar effect after 26 months of EGA therapy (-0.46°). According to recent systematic reviews about the effects of different functional treatments [Koretsi et al., 2016; Nucera et al., 2016] the inhibitory control of these appliances on the maxillary growth is about -0.10° per year. The data obtained in this study suggest that the functional treatment proposed immediately after maxillary expansion has a greater inhibitory effect on the A point's growth as compared to

functional treatments without maxillary expansion.

SNB increases in both groups, but without significant differences between the two groups, even if in group 2 a greater increase was found (+2.29° vs +1.78°).

The explanation for the increase of SNB in group 1 had already been suggested in another work [Farronato et al., 2011a]. According to the authors the “palatal expansion increases transverse maxillary diameter and releases the mandible, which gains a correct sagittal position which is impeded by the constricted maxillary bone”. However, the value of SNB obtained in group 1 is higher than that obtained by Janson et al. [2000] after 26 months of EGA treatment (1.07°). Hence, the effects on SNB obtained in group 1 could be attributed to the preliminary resolution of the maxillary contraction by RME with the use of the functional appliance. Moreover, our data are similar to those of a recent meta-analysis, according to which the mean predictable increase in SNB angle in puberty period by a functional appliance is 0.96° [Koretsi et al., 2016].

ANB angle decreases in both groups but with a significantly greater decrease in group 1 ($P < 0.001$).

The decrease of ANB angle in the test group and the consequent improvement of the skeletal relationship is the result of the relative restriction of the maxillary growth and the forward advancement of the mandible, as had already been observed in Class II division 1 malocclusions mainly characterised by a retruded mandible [McNamara, 2010].

The decrease in ANB angle (-2.37°) is higher than that obtained by Janson et al. [2000] with the same appliance during the pubertal peak of growth in a period of 26 months (-0.97°). However, our data confirms the mean additional decrease of 1.14° per year attributed to the use of functional appliances as reported in a recent meta-analysis [Koretsi et al., 2016].

As demonstrated previously [Farronato et al., 2011b; Volk et al., 2010], the decrease in ANB angle after therapy with RME in 9-year-old patients can vary between -0.9 [Volk et al., 2010] and -1.81 [Farronato et al., 2011b]; however, according to a recent review there is no agreement between the authors about the real effect on mandibular position after palatal expansion [Feres et al., 2015].

The data obtained in this study suggest that rapid palatal expansion followed by a second phase with a functional appliance permits a more effective forward mandibular repositioning in skeletal Class II malocclusions.

Facial plane effects

Analysing the mean variations between the facial planes (cranial, palatal and mandibular) after the two treatments it is possible to underline that the data were close to zero and thus the planes seem to have not been significantly affected by the therapy. These data confirm those obtained by Janson et al. [2007] and Myrlund et al. [2015] that reported a similar effect on the facial planes with the EGA appliance: Janson observed a low tendency of mandibular counterclockwise growth/rotation (-1.82°) as a long term treatment effect. Additionally, Myrlund observed a low tendency of mandibular and maxillary counterclockwise growth.

The changes in the relationship between cranial and mandibular planes observed in the two groups have similar values suggesting that the EGA appliance does not affect the cranio-mandibular relationship.

The delta values in the cranio-maxillary relationship

showed no significant changes between the two groups, suggesting also in this case that the EGA does not alter the facial plane after the RME therapy.

According to Chung et al. [2004] the short-term effects of RME on mandibular and palatal planes produce a downward and backward rotation. In our group 1 this effect is opposed by the subsequent therapy with EGA that allows intrusion of the front teeth and the counterclockwise rotation of mandibular and palatal planes, as already suggested by Janson et al. [2000; 2007].

Vertical effects

A significant difference between groups has been observed for both AFH ($P < 0.001$) and PFH ($P < 0.001$), with a greater effect in group 1 compared to group 2.

The vertical increase of the AFH data obtained in this study resulted higher than the ones observed by Janson et al. [2000] who obtained +6.05 mm for AFH and +4.87 mm for PFH in 24 months treatment with the same appliance.

Baysal and Uysal [2014] with twin-block and Herbst appliances as well as Karacay et al. [2006] with Jasper Jumper appliance obtained lower values for both AFH and PFH than this study for a similar treatment length, but similar to the ones obtained with Begg appliance [Nelson et al., 2007].

According to Chung et al. [2004] the short-term effect of RME on the vertical dimension is an increase of AFH equal to 3.34 mm. This finding could explain the higher increase in the vertical dimension obtained in group 1 as already described by previous studies thanks to the combination of RME and EGA [Farronato et al., 2011; Farronato et al., 2011a]. Apparently, the association of RME and EGA permits not only the resolution of maxillary hypoplasia but also a forward repositioning of the mandible that permits to correct the skeletal Class II.

In addition, EGA appliance seem to allow the correction of dental alignment by avoiding undesired dentoalveolar effects [Janson et al., 2000], such as the counterclockwise rotation of the mandible.

The appliance facilitates the correction of the relationship between the skeletal bases by encouraging eruptive guidance, facilitating the achievement of an ideal dental relationship and allowing the eruption of both anterior and posterior teeth so to increase both AFH and PFH without altering the mandibular rotation.

The initial treatment with RME seems to increase the skeletal effects obtained by the EGA appliance, achieving better results on both sagittal and vertical dimensions.

The orthopaedic treatment proposed in group 1 represents an efficient therapy for skeletal Class II deep bite malocclusion characterised by maxillary contraction and sagittal discrepancy with an ANB value between 4 and 7, with low or moderate crowding.

Conclusions

The therapeutic approaches presented in this study are useful for correction of skeletal Class II deep bite malocclusion characterised by maxillary hypoplasia, and permit to obtain consistent results with decrease of ANB and SNA angles and increase of SNB angle. Comparing the two approaches, the RME and EGA therapy seems to allow a greater improvement of the sagittal and vertical skeletal dimensions.

References

- » Ahmad S, Burhan, Fehmieh R, Nawayi; Dentoskeletal effects of the Bite-Jumping Appliance and the Twin-Block Appliance in the treatment of skeletal Class II malocclusion: a randomized controlled trial. *Eur J Orthod* 2015 37:330-7.
- » Baysal A, Uysal T. Dentoskeletal effects of Twin Block and Herbst appliances in patients with Class II division 1 mandibular retrognathia. *Eur J Orthod* 2014 36(2):164-72.
- » Burhan AS, Nawayi FR. Dentoskeletal effects of the Bite-Jumping Appliance and the Twin-Block Appliance in the treatment of skeletal Class II malocclusion: a randomized controlled trial. *Eur J Orthod* 2015 37(3):330-7.
- » Chung CH, Font B. Skeletal and dental changes in the sagittal, vertical, and transverse dimensions after rapid palatal expansion. *Am J Orthod Dentofacial Orthop* 2004 126(5):569-75.
- » Conroy-Piskai C, Galang-Boquiren MT, Obrez A, Viana MG, Oppermann N, Sanchez F, Edgren B, Kusnoto B. Assessment of vertical changes during maxillary expansion using quad helix or bonded rapid maxillary expander. *Angle Orthod* 2016 86(6):925-933.
- » D'Antò V, Bucci R, Franchi L, Rongo R, Michelotti A, Martina R. Class II functional orthopaedic treatment: a systematic review of systematic reviews. *J Oral Rehabil* 2015 42(8):624-42.
- » Ehsani S, Nebbe B, Normando D, Lagravere MO, Flores-Mir C. Short-term treatment effects produced by the Twin-block appliance: a systematic review and meta-analysis. *Eur J Orthod* 2015 37(2):170-6.
- » (a)Farronato G, Giannini L, Galbiati G, Maspero C. Sagittal and vertical effects of rapid maxillary expansion in Class I, II, and III occlusions. *Angle Orthod* 2011 81(2):298-303.
- » (b)Farronato G, Maspero C, Esposito L, Briguglio E, Farronato D, Giannini L. Rapid maxillary expansion in growing patients. Hyrax versus transverse sagittal maxillary expander: a cephalometric investigation. *Eur J Orthod* 2011 33(2):185-9.
- » Farronato G, Giannini L, Galbiati G, Grillo E, Maspero C. Occlus-o-Guide® versus Andresen activator appliance: neuromuscular evaluation. *Prog Orthod* 2013 20:14-4.
- » Feres MF, Raza H, Alhadlaq A, El-Bialy T. Rapid maxillary expansion effects in Class II malocclusion: A systematic review. *Angle Orthod* 2015 Feb 10.
- » Janson GR, da Silva CC, Bergersen EO, Henriques JF, Pinzan A. Eruption Guidance Appliance effects in the treatment of Class II, Division 1 malocclusions. *Am J Orthod Dentofacial Orthop* 2000 117(2):119-29.
- » Janson GR, Nakamura A, Chiqueto K, Castro R, de Freitas MR, Henriques JF. Treatment stability with the eruption guidance appliance. *Am J Orthod Dentofacial Orthop*. 2007 131(6):717-28.
- » Karacay S, Akin E, Olmez H, Gurton AU, Sagdic D. Forsus Nitinol Flat Spring and Jasper Jumper corrections of Class II division 1 malocclusions. *Angle Orthod* 2006 76(4):666-72.
- » Keski-Nisula K, Hernesniemi R, Heiskanen M, Keski-Nisula L, Varrela J. Orthodontic intervention in the early mixed dentition: a prospective, controlled study on the effects of the eruption guidance appliance. *Am J Orthod Dentofacial Orthop* 2008 133(2):254-60.
- » Koretsi V, Zymerdikas VF, Papageorgiou SN, Papadopoulos MA. Treatment effects of fixed functional appliances in patients with Class II malocclusion: a systematic review and meta-analysis. *Eur J Orthod* 2016 38(2):113-26.
- » McNamara JA Jr, Sigler LM, Franchi L, Guest SS, Baccetti T. Changes in occlusal relationships in mixed dentition patients treated with rapid maxillary expansion. A prospective clinical study. *Angle Orthod* 2010 80(2):230-8.
- » Migliaccio S, Aprile V, Zicari S, Greci A. Eruption guidance appliance: a review. *Eur J Paediatr Dent* 2014 15(2):163-6.
- » Myrlund R, Dubland M, Keski-Nisula K, Kerosuo H. One year treatment effects of the eruption guidance appliance in 7- to 8-year-old children: a randomized clinical trial. *Eur J Orthod* 2015 37(2):128-34.
- » Nelson B, Hägg U, Hansen K, Bendeus M. A long-term follow-up study of Class II malocclusion correction after treatment with Class II elastics or fixed functional appliances. *Am J Orthod Dentofacial Orthop* 2007 132(4):499-503.
- » Nilsson JJ, Shu X, Magnusson BH, Burt IA. Treatment of adolescent patients with class II division 1 malocclusion using Eruption guidance appliance: A comparative study with Twin-block and Activator-Headgear appliances. *Swed Dent J* 2016 40(1):79-89.
- » Nucera R, Lo Giudice A, Rustico L, Matarese G, Papadopoulos MA, Cordasco G. Effectiveness of orthodontic treatment with functional appliances on maxillary growth in the short term: A systematic review and meta-analysis. *Am J Orthod Dentofacial Orthop* 2016 149(5):600-611.
- » Perillo L, Cannavale R, Ferro F, Franchi L, Masucci C, Chiodini P, Baccetti T. Meta-analysis of skeletal mandibular changes during Frankel appliance treatment. *Eur J Orthod* 2011 33(1):84-92.
- » Proffit WR. *Ortodonzia moderna*. Seconda edizione. Milano: Elsevier Masson 2001.
- » Volk T, Sadowsky C, Begole EA, Boice P. Rapid palatal expansion for spontaneous Class II correction. *Am J Orthod Dentofacial Orthop* 2010 137(3):310-5.