



Gamma Knife Radiosurgery for Short Unilateral Neuralgiform Headache Attacks with Conjunctival Injection and Tearing (SUNCT) Syndrome: Targeting the Trigeminal Nerve and the Sphenopalatine Ganglion. Case Report and Literature Review

Ismail Zaed¹, Luca Attuati¹, Concezione Tommasino², Enrico Massimo Arosio³, Pierina Navarria⁴, Antonella Stravato⁵, Giovanni Colombo⁶, Piero Picozzi¹

Key words

- Gamma knife radiosurgery
- Short-lasting unilateral neuralgiform headache attacks with conjunctival injection and tearing
- Sphenopalatine ganglion
- Trigeminal nerve

Abbreviations and Acronyms

CT: Computed tomography

GKRS: Gamma knife radiosurgery

MRI: Magnetic resonance imaging

SPG: Sphenopalatine ganglion

SUNCT: Short-lasting unilateral neuralgiform headache attacks with conjunctival injection and tearing

TN: Trigeminal nerve

From the ¹Neurosurgery, Humanitas Clinical and Research Center — IRCCS, Rozzano - Milano; ²Department of Biomedical, Surgical and Odontoiatric Sciences, University of Milano, ASST Santi Paolo e Carlo University Hospital, Milano; ³Anesthesia, ⁴Radiation Oncology, ⁵Medical Physics and ⁶Otorhinolaryngology Unit, Humanitas Clinical and Research Center — IRCCS, Rozzano - Milano, Italy

To whom correspondence should be addressed:

Ismail Zaed, M.S.

[E-mail: ismailzaed1@gmail.com]

Citation: *World Neurosurg.* (2020) 133:167-171.

<https://doi.org/10.1016/j.wneu.2019.10.016>

Journal homepage: www.journals.elsevier.com/world-neurosurgery

Available online: www.sciencedirect.com

1878-8750/\$ - see front matter © 2019 Elsevier Inc. All rights reserved.

INTRODUCTION

Short-lasting unilateral neuralgiform headache attacks with conjunctival injection and tearing (SUNCT) syndrome is a rare pathology, defined as a primary headache syndrome.^{1,2} SUNCT diagnosis can be difficult because signs and symptoms overlap with other facial pain diseases, such as trigeminal neuralgia and cluster headache. This pathology is characterized by at least 20 pain attacks per day, with a wide range of duration (1–600 seconds). The SUNCT attacks usually start and cease abruptly and have an irregular temporal pattern. The

BACKGROUND: Short-lasting unilateral neuralgiform headache attacks with conjunctival injection and tearing (SUNCT) is a primary headache syndrome with an unclear pathogenesis, and only in very few cases, SUNCT is secondary to known lesions (secondary SUNCT). Several pharmacological as well as interventional and invasive treatments have been used to treat SUNCT cases, with no definitive results. We describe a patient with idiopathic SUNCT syndrome, successfully treated with gamma knife radiosurgery and we report a review of the cases of the literature treated with radiosurgery.

CASE REPORT: A 63-year-old woman complained of episodes of intense and regular paroxysmal facial pain in the territory of the maxillary branch of the trigeminal nerve accompanied by inflammation of conjunctiva and involuntary lacrimation from 2006. During the following years, she received several treatments: combination of drugs, acupuncture, and endonasal infiltration of the sphenopalatine ganglion. The frequency of the painful attacks increased progressively and it was impossible for her to have a normal active life. Combined gamma knife radiosurgery treatment, targeting the trigeminal nerve (80 Gy maximum dose) and the sphenopalatine ganglion (80 Gy maximum dose) was performed in April 2016 (visual analog score before treatment = 6). Pain gradually reduced in the following months, as well as frequency and severity of the attacks. No sensory deficit developed. The follow-up length of our patient is 37 months: she is nearly pain free (visual analog score = 2) and has resumed a normal life.

CONCLUSIONS: Patients with idiopathic SUNCT have few therapeutic options. Our case demonstrates that gamma knife radiosurgery is a feasible and effective noninvasive option to treat patients with medically refractory idiopathic SUNCT.

localization of such attacks is characteristic because they are mainly unilateral and affect the orbital/periorbital region. As the name of the syndrome indicates, these painful attacks, which can be moderate or severe, are followed by dramatic conjunctival injection and lacrimation.^{1,2} Signs and symptoms are not limited to those described here. During the attacks, rhinorrhea or nasal stuffiness, facial sweating, hyperventilation, and increased intraocular pressure on the symptomatic side, as well as vascular engorgement

and eyelid edema with pseudoptosis can also occur.^{2,3} Ictal changes in pupillary diameter are rare in SUNCT.

The pain has been described as burning, stabbing, or electric in character. Pain attacks start and cease abruptly, without any premonitory sign. In some cases, these attacks are triggered by external factors, such as a change of temperature. Postattack refractory periods may be completely absent.⁴ Solitary attacks usually have a “plateau-like” pattern, but other temporal patterns can be seen: repetitive (short-lasting attacks in rapid succession), sawtooth-like

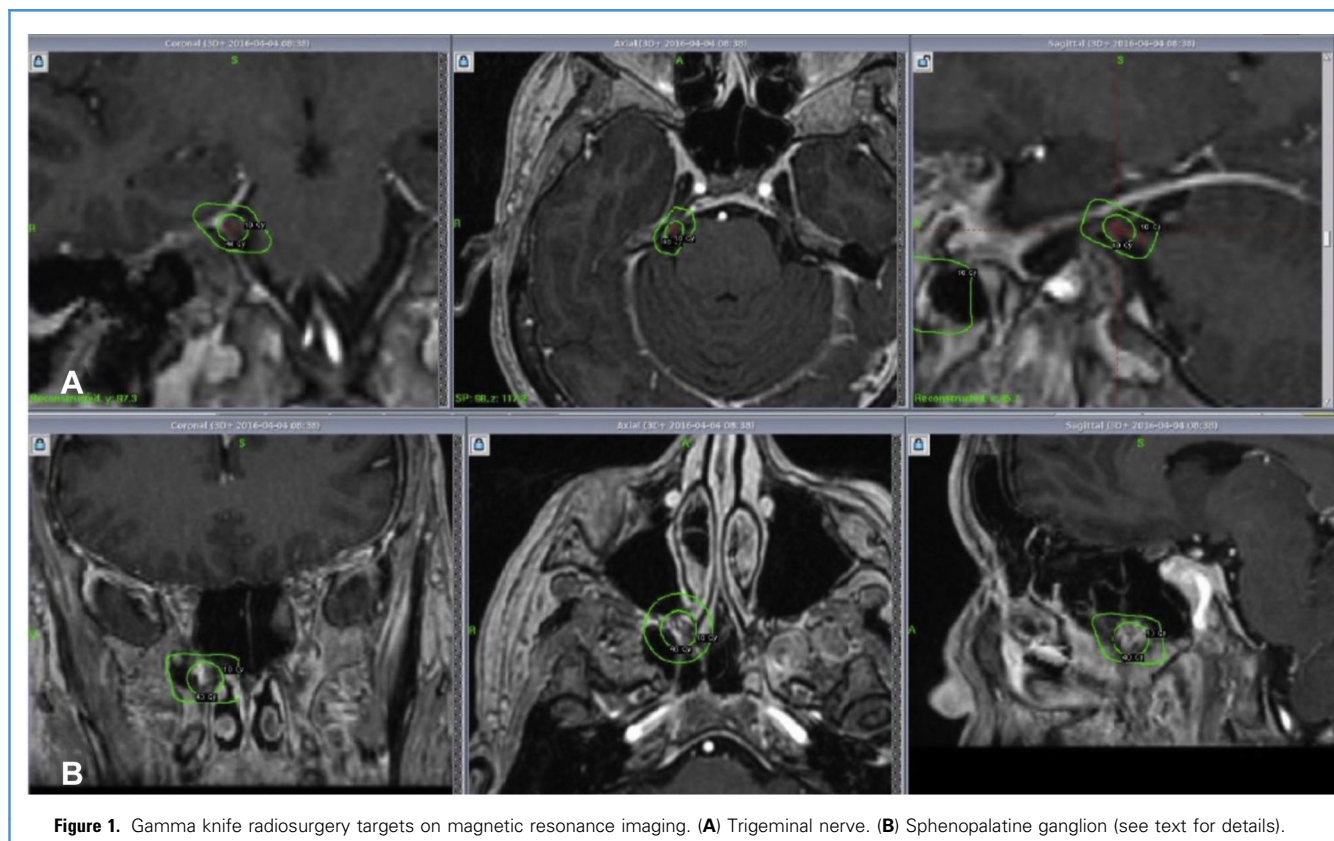


Figure 1. Gamma knife radiosurgery targets on magnetic resonance imaging. (A) Trigeminal nerve. (B) Sphenopalatine ganglion (see text for details).

(and its variant staccato-like, in which consecutive spike-like paroxysms occur without reaching the pain-free baseline), and plateau-like plus exacerbations (a mixture of 1- to 2-second jabs superimposed on top of the conventional plateau-like pattern).⁴

The etiology and pathogenesis of SUNCT is unknown. SUNCT syndrome is more frequently idiopathic, and in very few cases can be secondary to other pathologies.⁵ It has been hypothesized that SUNCT symptoms arise from the triggering of the trigeminally innervated areas, even though it has also been reported that extratrigeminal territory can be involved.⁶

The SUNCT syndrome is a lifelong condition, and patients can need treatment for an indefinite period. Until now, no consensus has emerged to define the effective treatment. Pharmacological as well as interventional and invasive treatments have been performed, with no definitive results.⁷

Here we describe a case of idiopathic SUNCT syndrome successfully treated

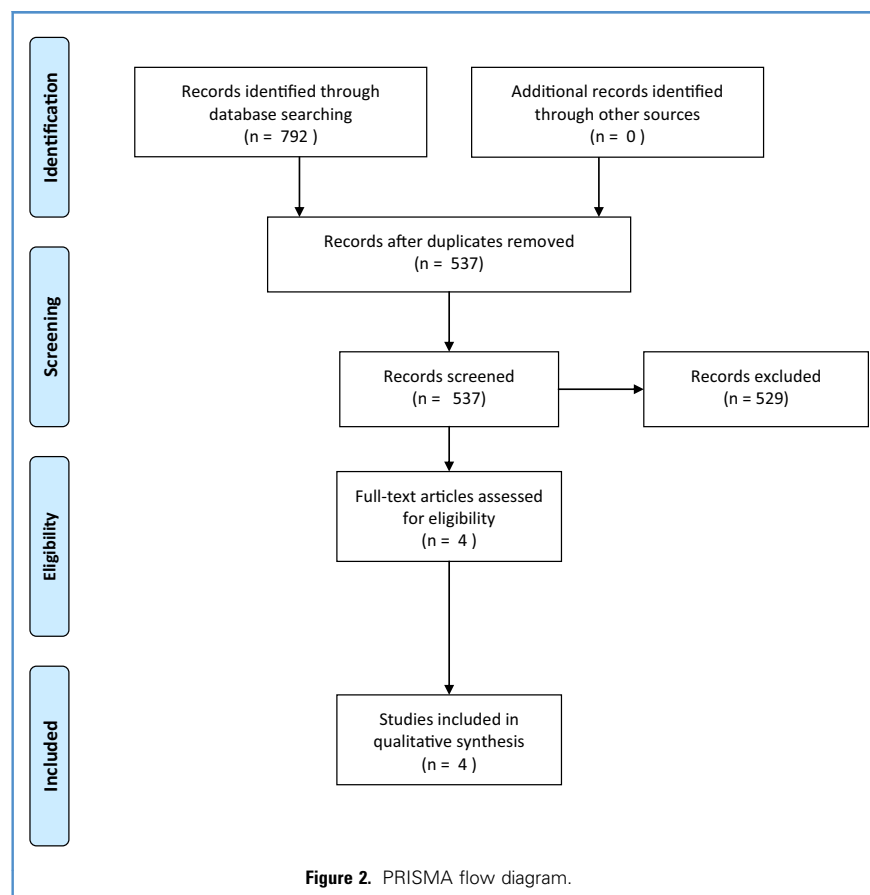
with gamma knife radiosurgery (GKRS) targeting the trigeminal nerve and sphenopalatine ganglion and review the cases of the literature reporting radiosurgical treatment for such a rare disease.

CASE REPORT

A 63-year-old woman, suffering from SUNCT dating from the age of 52 years, was referred to our University Hospital. Apart from the painful syndrome, the patient was healthy and had no significant medical history. The pain syndrome started in 2006 (winter) and was mainly localized in the territory innervated by the maxillary branch (V₂) of the right trigeminal nerve (TN). The patient reported that the pain attacks were often triggered by any kind of stimulation in the TN territory (tactile, motor, or gustative stimuli); however, on several occasions she could not individualize any apparent trigger. The pain attack was always accompanied by rapidly developing conjunctival injection and lacrimation in the right eye. The

patient underwent several odontology evaluations, which did not show any pathology in the upper right jaw (V₂ innervation area). She started to wear a dental mouthguard, which did not have any effect on the pain attacks. In July 2006, the patient started acupuncture treatment 2 times a week, with very little reduction in the pain attacks. In September 2006, she started medical treatment with progressive doses of amitriptyline (up to a maximal dosage of 100 mg/day) with a short-term benefit of the pain attacks, but long-term gain in aqueous humor control. Meanwhile, she also started steroids and vitamins (B₁₂, B₁, B₆, niacin, vitamin E), without evident benefits.

In the following years, she underwent cutaneous electrostimulation in 2010, and in the same year, the ear, nose, and throat surgeon applied a mixture of cocaine, menthol, and phenol together with ampicillin and steroids at the level of the right sphenopalatine ganglion (SPG), without pain relief. After an extremely distressing pain attack in May 2011, she started



hydromorphone, with poor pain control. After another worsening in 2013, hydromorphone was changed for oxycodone and naloxone, and the patient underwent lidocaine infiltrations of the right SPG. There was a further worsening in the next year; she was then suffering pain attacks almost every hour. In October 2014, gabapentin was introduced in the therapy with no pain improvement.

In 2016, she was referred to our University Hospital and underwent radiosurgery treatment that was performed using GKRS, with the help of both magnetic resonance imaging (MRI) and computed tomography (CT) targeting. Because of similarities between SUNCT and cluster headache, it was decided to treat both the trigeminal nerve and the sphenopalatine ganglion. A Leksell G stereotactic frame was attached to the patient's head under local anesthesia and conscious sedation (e.g., midazolam). Thereafter, a 1-mm-thick axial contrast-enhanced T1 volumetric MRI sequence, a

FIESTA T2 sequence and CT scan for bone imaging were obtained for trigeminal root and sphenopalatine ganglion localization, and treatment planning (Figure 1). Radiosurgery was performed with a Gamma Knife Perfexion (Elekta Instruments, Stockholm, Sweden). The TN was targeted at the level of the intracisternal segment using a single 4-mm isocenter delivering 80 Gy (maximum dose). Because of the small dimension of the cistern and the short length of the nerve in this particular patient, the 4-mm isocenter was plugged to keep the 15-Gy isodose out of the brainstem. The SPG was targeted with the assistance of a neuroradiologist and an ear, nose, and throat surgeon. Because the SPG is not directly visible on CT and MRI scans, the posterior part of the pterygopalatine fossa, where the vidian nerve terminates in the ganglion, was targeted. The V2 also passes through the pterygopalatine fossa and has multiple anastomoses with the SPG. This region was

targeted with a single 8-mm isocenter delivering a maximum dose of 80 Gy. The use of a wider isocenter for this target is related to the difficulty to precisely identify the sphenopalatine ganglion, as well as to the absence of other sensitive structures in this anatomical region.^{8,9}

At the first follow-up, 3 months after the radiosurgical procedure, the patient reported a significant reduction of the pain, which nearly completely disappeared 6 months after radiosurgery. There was no alteration in facial sensation. On the latest follow-up, 37 months after the procedure, the patient remains completely pain free (visual analog scale = 2), and she only uses amitriptyline 10 mg twice daily. She did not suffer from any side effect or complication from the procedure.

REVIEW OF THE LITERATURE

To assess the use of radiosurgery for the treatment of primary SUNCT syndrome, the authors performed a systematic review of the literature up to May 2019, using the MEDLINE and SCOPUS databases. The following keywords terms were used in a title and abstract screening: "Short-lasting Unilateral Neuralgiform Headache attacks with Conjunctival injection and Tearing," "SUNCT," "SUNCT and treatment," "SUNCT and radiosurgery." Relevant references of published articles were screened to increase the scientific quality of papers.

The selection of the papers has been summarized in the PRISMA flowchart (Figure 2). According to our review, only 5 patients with SUNCT treated with radiosurgery have been reported up to now.¹⁰⁻¹³ In 2002, Black and Dodick reported the first 2 SUNCT patients treated with radiosurgery.¹⁰ Both patients had failed medical therapies. The first patient underwent a glycerol rhizotomy, GKRS, and microvascular decompression of the TN. The second patient underwent GKRS of the trigeminal root exit zone and 2 microvascular decompression surgeries. Both patients received GKRS treatment targeting the trigeminal nerve only, and neither patient benefited from radiosurgery. Subsequent reports of idiopathic SUNCT cases documented that radiosurgery treatment was beneficial.¹¹⁻¹³ Effendi et al. reported a case in 2011 of SUNCT successfully treated by GKRS

Table 1. Cases of Idiopathic SUNCT Syndrome Treated With Radiosurgery

Author	Year	Sex	Age	Years From Presentation	Duration (s)	Frequency (Per d)	Trigger	Pain Side	Target	Dose (Gy)	Follow-Up (mo)	Success
Black et al.	2002	M	39	2	2–3	20–400	NA	R	TN	90 Gy	NA	No
		M	28	10	20–30	100–200	NA	R	TN	90 Gy	NA	No
Effendi et al.	2011	M	82	6	30–120	3–10	Yes	R	TN SPG	80 Gy 80 Gy	39	Yes
Mathew et al.	2012	M	50	1	10–30	100–200	NA	R	TN SPG	80 Gy 80 Gy	4	Yes
Tan et al.	2013	F	83	1	300–1800	6–10	Yes	R	TN SPG	90 Gy 80 Gy	16	Yes
Present study	2019	F	63	10	20–120	>100	Yes	R	TN SPG	80 Gy 80 Gy	37	Yes

NA, not available; R, right; SPG, Sphenopalatine ganglion; TN, Trigeminal nerve.

with irradiation of both the trigeminal nerve and sphenopalatine ganglion. A dose of 80 Gy was delivered to both structures. The patient did not have any side effects from the procedure, had complete pain cessation 2 weeks after the treatment, and remained pain-free with no medication at the latest follow-up (39 months after radiosurgery).¹¹ A similar case was reported in 2012. A 50-year-old man with SUNCT refractory to medications received GKRS treatment.¹² He was given 80 Gy both to the trigeminal nerve and the sphenopalatine ganglion. At 4 months' follow-up, he had no more spontaneous attacks and only very occasional brief episodes of pain, precipitated by touching. GKRS of both the trigeminal nerve and sphenopalatine ganglion yielded near-total relief to the patient. In 2013, Tan et al.¹³ treated a SUNCT case with frameless stereotactic radiosurgery targeting the trigeminal nerve and the sphenopalatine ganglion. A total dose of 90 Gy was prescribed to the isocenter for the trigeminal nerve and 80 Gy was prescribed to the isocenter for the sphenopalatine ganglion. At 1 week posttreatment, the 83-year-old patient reported a 60% reduction of pain. Her pain continued to improve and at her last follow-up (16 months), she was completely pain free without any medications.¹³

Table 1 illustrates the SUNCT cases treated with stereotactic radiosurgery. All but 2 patients were male, and the mean age was 57.5 years (range, 28–83). There

was a great range of variability both in the duration of the pain attacks (from 2 up to 1800 seconds), and in the frequency (from 3 to 400 attacks per day). In all cases, the pain was localized on the right side, and in 50% of the cases (3 of 6), the pain attacks were triggered. Radiosurgical treatment was effective in 4 of 6 patients (this study).^{11–13} The 2 cases reported by Black et al.¹⁰ did not show any significant improvement after radiosurgery treatment. The authors did not give any explanation for the failures; however, in both cases, only the entry root of the trigeminal nerve was irradiated, without targeting the sphenopalatine ganglion. In the cases in which both the TN and SPG were treated (4 of 6 patients), the same dosage (80 Gy) was used to treat the trigeminal nerve and the sphenopalatine ganglion and the radiosurgery treatment was effective (this study).^{11–13} These case reports also demonstrate that both targets can be treated safely with minimal side effects for the patient.

DISCUSSION

According to a recent classification of headache disorders, SUNCT syndrome is defined as a rare trigeminal autonomic cephalalgia, characterized by attacks of moderate or severe strictly unilateral neuralgiform paroxysmal orbital, supraorbital or temporal and/or other trigeminal distribution stabbing pain lasting for 1 to 600 seconds.¹ The pain symptoms are

accompanied by ipsilateral cranial autonomic features such as lacrimation and conjunctival injection.^{1–4,6} Although SUNCT is classified as a primary headache disorder, secondary causes have been increasingly reported, such as neoplastic lesions in the posterior fossa, pituitary gland, and also neurovascular conflicts and infections.⁵

The proposed pathophysiology of SUNCT is the activation of the trigeminal autonomic reflex and the trigeminal cervical complex, which are both responsible for the autonomic symptoms and the debilitating pain.^{1,14} Furthermore, SUNCT has similarities with cluster headache, and high-frequency stimulation of the sphenopalatine ganglion is an emerging abortive treatment for cluster headache attacks.¹⁵ These pathophysiological considerations constitute the scientific basis for the combined treatment of the trigeminal nerve and the sphenopalatine ganglion. For the treatment of trigeminal neuralgia, the TN has been frequently targeted with radiosurgery in its intracisternal component. In recent years, the technique has been refined and great care is taken to target the precise area to be treated to optimize pain control and minimize complications.¹⁶ It has been reported that a lesion close to the root exit zone of the TN is very effective on pain, although this type of lesion carries the possibility of unpleasant collateral symptoms (hypoesthesia). Therefore, when feasible and depending on intracisternal TN length, the isocenter

should be located distally from the brainstem¹⁶; doses generally used for these treatments range between 80 and 90 Gy (maximal dose).^{15,16}

The other target, the SPG, is a relay for the autonomic fibers toward the lacrimal and nasal mucosal glands. The pterygopalatine fossa, where the SPG is located, establishes connections with the maxillary branch of the TN. Thus, it makes sense to select this target for therapeutical procedures, such as local drug infiltration or stimulating electrode insertion or neurodestructive procedure in SUNCT cases.

According to our review, very few patients have been treated with radiosurgery for such rare syndrome with mixed results.¹⁰⁻¹³ The SUNCT patients who did benefit from radiosurgery received treatment targeting both the TN and the SPG, demonstrating that the irradiation of the SPG is fundamental for the control of pain in the SUNCT syndrome.¹¹⁻¹³ It has been postulated that the addition of the SPG in combination with the TN as a target might have been important for complete pain relief, because efferent parasympathetic outflow from it may be involved in further pain generation through the activation of trigeminovascular sensory afferents.¹⁵ Thus, by ablating both targets, one might achieve peripheral blockade of all possible pain pathways, providing effective pain relief for the patient. The case reports have also demonstrated that both targets can be treated safely with minimal side effects for the patient.¹¹⁻¹³

Our patient has been followed for more than 3 years; however, a longer follow-up will be necessary to evaluate the long-lasting effects of such an approach. If she remains pain free, GKRS targeting trigeminal nerve and sphenopalatine ganglion may provide a very attractive treatment option for the patient who suffers from medically refractory SUNCT.

CONCLUSIONS

SUNCT is a rare but debilitating cephalgia that is difficult to control. It can be idiopathic or secondary to other pathologies. After failed medical therapy, options include nerve blockades, sphenopalatine ganglion stimulation, microvascular surgery, or other neurosurgical procedures, depending on the secondary cause of the syndrome. Up to now, to the best of our knowledge, these options are all invasive to various degrees.

Here we present a case of idiopathic SUNCT syndrome, successfully treated using GKRS, a minimally invasive procedure. Initial response to treatment has been excellent, with no side effects. Longer follow-up and further experience with radiosurgery will determine the efficacy and safety of this treatment option for such a rare disease.

REFERENCES

- Headache Classification Committee of the International Headache Society (IHS). The international classification of headache disorders: 3rd edition beta version. *Cephalalgia*. 2013;33:629-808.
- Cao Y, Yang F, Dong Z, Huang X, Cao B, Yu S. Secondary short-lasting unilateral neuralgiform headache with conjunctival injection and tearing: a new case and a literature review. *J Clin Neurol*. 2018;14:433-443.
- Arca KN, Halker Singh RB. SUNCT and SUNA: an update and review. *Curr Pain Headache Rep*. 2018;22:56.
- Pareja JA, Caminero AB, Sjaastad O. SUNCT syndrome: diagnosis and treatment. *CNS Drugs*. 2002;16:373-383.
- Trucco M, Mainardi F, Maggioni F, Badino R, Zanchin G. Chronic paroxysmal hemicrania, hemicrania continua and SUNCT syndrome in association with other pathologies: a review. *Cephalalgia*. 2004;24:173-184.
- Pareja JA, Pareja J, Palomo T, Caballero V, Pamo M. SUNCT syndrome: repetitive and overlapping attacks. *Headache*. 1994;34:114-116.
- Pareja JA, Alvarez M, Montojo T. SUNCT and SUNA: recognition and treatment. *Curt Treat Options Neurol*. 2013;15:28-39.
- Massager N, Lorenzoni J, Devriendt D, Desmedt F, Brotschi J, Levivier M. Gamma knife surgery for idiopathic trigeminal neuralgia performed using a far-anterior cisternal target and a high dose of radiation. *J Neurosurg*. 2004;100:597-605.
- Xu Z, Schlesinger D, Moldovan K, et al. Impact of target location on the response of trigeminal neuralgia to stereotactic radiosurgery. *J Neurosurg*. 2014;120:716-724.
- Black DF, Dodick DW. Two cases of medically and surgically intractable SUNCT: a reason for caution and an argument for a central mechanism. *Cephalalgia*. 2002;22:201-204.
- Effendi K, Jarjoura S, Mathieu D. SUNCT syndrome successfully treated by gamma knife radiosurgery: case report. *Cephalalgia*. 2011;31:870-873.
- Mathew T, Srinivas D, Aroor S, et al. SUNCT syndrome treated with gamma knife targeting the trigeminal nerve and sphenopalatine ganglion. *J Headache Pain*. 2012;13:491-492.
- Tan DY, Chua ET, Ng KB, Chan KP, Thomas J. Frameless linac-based stereotactic radiosurgery treatment for SUNCT syndrome targeting the trigeminal nerve and sphenopalatine ganglion. *Cephalalgia*. 2013;33:1132-1136.
- Goadsby PJ. Trigeminal autonomic cephalalgias (TACs). *Acta Neurol Belg*. 2001;101:10-19.
- Schytz HW, Barløse M, Guo S, et al. Experimental activation of the sphenopalatine ganglion provokes clusterlike attacks in humans. *Cephalalgia*. 2013;33:831-841.
- Tuleasca C, Régis J, Sahgal A, et al. Stereotactic radiosurgery for trigeminal neuralgia: a systematic review. *J Neurosurg*. 2018;130:733-757.

Conflict of interest statement: The authors declare that the article content was composed in the absence of any commercial or financial relationships that could be construed as a potential conflict of interest.

Received 28 June 2019; accepted 3 October 2019

Citation: *World Neurosurg.* (2020) 133:167-171.
<https://doi.org/10.1016/j.wneu.2019.10.016>

Journal homepage: www.journals.elsevier.com/world-neurosurgery

Available online: www.sciencedirect.com

1878-8750/\$ - see front matter © 2019 Elsevier Inc. All rights reserved.