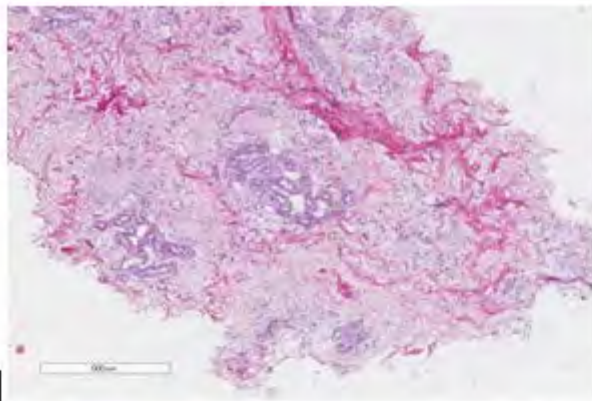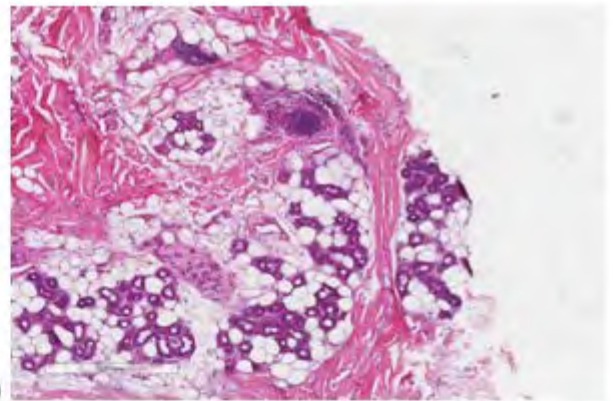
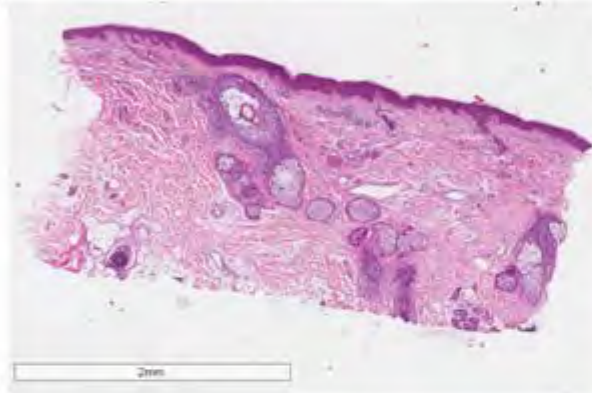



a)



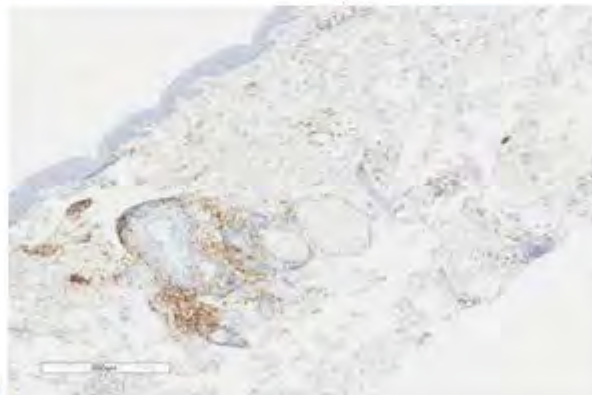
b)



c)



d)



e)

- a) Reticular derma, transverse section 4X, hematoxylin-eosin staining
- b) Hypoderma, transverse section 4X, hematoxylin-eosin staining
- c) Longitudinal section, 1.5X, hematoxylin-eosin staining
- d) Longitudinal section, 4X, staining for CD8⁺ lymphocytes
- e) Longitudinal section, 4X, staining for CD4⁺ lymphocytes