

Cone-Beam Computed Tomography accuracy in pulp chamber size evaluation: an *ex-vivo* study

Short Title: Three-dimensional pulp chamber evaluation

Marcello Maddalone, MD, DDS ¹, Claudio Citterio, MD, DDS ¹, Alberto Pellegatta, MD, DDS ¹, Massimo Gagliani, MD, DDS ², Lorena Karanxha DDS, PhD ², Massimo Del Fabbro, MSc, PhD ^{2,3}

1 Department of Translational Medicine and Surgery. University of Milano-Bicocca, Milan, Italy

2 Department of Biomedical, Surgical and Dental Sciences, Università degli Studi di Milano, Milan, Italy

3 Dental Clinic, IRCCS Orthopedic Institute Galeazzi, Milan, Italy

Authorship declaration:

We declare that all authors contributed significantly and have read and approved the manuscript.

Corresponding Author:

Marcello Maddalone, MD, DMD, Department of Medicine and Surgery, University of Milano Bicocca, Viale Lombardia 6, Milano, Italy

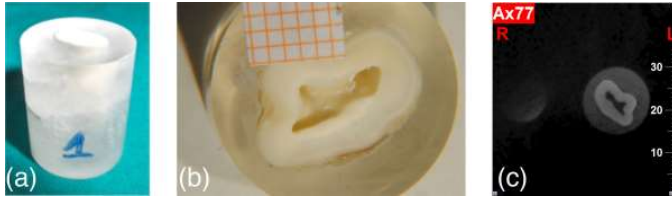
Tel. 00393356080227, e-mail: marcello.maddalone@unimib.it

Acknowledgements.

This study received no funding.

Disclosure statement.

The authors declare that they have no conflicts of interest.



Cone-Beam Computed Tomography

accuracy in pulp chamber size evaluation: an *ex-vivo* study

Abstract

This study aimed to assess *ex-vivo* the accuracy of Cone-Beam Computed Tomography (CBCT), as compared to operative microscope, for evaluating pulp chamber size. A total of forty teeth were extracted for periodontal reasons and a horizontal section was done at the most apical level of the cement-enamel junction. The pulp chamber was photographed using a digital camera connected to an optical microscope. Then, the tooth was scanned with CBCT and the horizontal slide matching the anatomical section of pulp chamber was digitally stored. The pulp chamber section area was measured through image analysis software. The two methods provided similar results, either for mono-radicular ($p=0.14$) and multi-radicular teeth ($p=0.93$). Correlation was statistically significant ($p<0.0001$), being the coefficient $r=0.89$ and 0.94 for mono-radicular and multi-radicular teeth, respectively. Conclusively, CBCT is suitable for pulp chamber morphology evaluation. However, it has limitations in detecting the anatomical variability of small branches in root canal system.

Key words: cone beam computed tomography; *ex-vivo* study; pulp chamber; root canal system; root canal treatment;

Introduction

Diagnosis and treatment of diseases of endodontic origin is among the most common procedures in daily dental practice. Obtaining detailed information on the tooth anatomy and root canal condition is essential in order to achieve a successful root canal treatment and to clearly identify pulp and periapical diseases. The most common tools for the examination of the root canal are the root apex locators, that essentially only allow to determine the working length, and intraoral periapical radiographs. The latter can only two-dimensionally represent the root canal system, which minimizes the diagnostic performance (1). Furthermore, since no bucco-lingual/palatal projections can be taken, intraoral radiographs do not guarantee identification of all of the anatomical and pathological features of the root canal system (2).

Cone-Beam Computed Tomography (CBCT) overcomes most of these limitations, by generating three-dimensional reconstructions. CBCT, also called digital volume tomography (DVT), uses an extra-oral imaging scanner, which was developed in the late 1990s to allow digital three-dimensional reconstruction of the maxillo-facial complex. The effective radiation dose of CBCT is approximately in the range of a standard digital panoramic radiograph (3), thus exposing the patient to a significantly lower radiation load than the conventional computed tomography (CT) for medical use (4). In addition, the use of scanners for Cone-Beam technology is less complex, and thus, the hardware (X-ray source and detectors) less expensive, than conventional CT scanners. As compared to panoramic radiographs, CBCT allows for a significant improvement in diagnostic imaging performance (5). Therefore, CBCT may be helpful, as an adjunct to standard intraoral techniques, for the management of various endodontic problems (6,7).

When comparing any radiographic imaging techniques used in the oral region, one should consider that all of them may carry some degree of inaccuracy when estimating the size of

anatomical structures (8,9). In the present study we aimed at assessing the reliability of CBCT for quantitative evaluation of the size of pulp chamber and related structures, by a comparison with direct microscopic evaluation of the same region.

Materials and Methods

The sample study was composed of 40 teeth, extracted for periodontal reasons from seven patients. All teeth were intact in morphology and structure. Fifteen teeth had multiple roots, and 25 were monoradicular. All patients provided their signed informed consent to use their extracted teeth for this study.

The analysis of the area of the pulp chamber of the extracted teeth, visible after horizontal section of the tooth, was chosen as a model. Each tooth was disinfected by immersion for thirty minutes in a 5.5% solution of sodium hypochlorite (NaOCl), rinsed and then stored in saline solution to prevent dehydration. Then, each tooth was placed in suitable cylindrical containers of 10 or 20 ml, according to tooth size, and poly(methyl methacrylate) resin (PMMA, Ivoclar Vivadent, Schaan, Liechtenstein) was applied through a machine for curing resin self-hardening heat (IVOMAT®, Ivoclar Vivadent, Schaan, Liechtenstein). Polymerization occurred within 15 minutes, at a temperature of 90°C and a pressure of 4 Atm. A cut perpendicular to the main tooth axis, at the most apical level of the cement-enamel junction was then made using a semi-automatic precision cutting machine with a diamond-coated saw blade (ISOMET 1000® Buehler, Lake Bluff, Illinois, USA). Then, the base resin of the sample was treated with a rotating disc microtome and ground with sandpaper abrasive sheet “P180” (3M Sandblaster, London, Ontario, Canada) to smoothen any surface irregularities that might affect inclination (Figure 1a).

Subsequently, an optical microscope at 10x magnification was used to take an image of the tooth section showing the pulp chamber area. A ruler with 5-mm ticks was placed close to

each sample and used as reference for calibrating the image analysis software prior to the measurement of the pulp chamber area (Figure 1b).

The CBCT evaluation of the same samples was performed in a radiology centre specialized in cranio-facial region assessment using a Cone-Beam NewTom VG ® (Quantitative Radiology srl, Verona, Italy). The technical specifications of the CBCT system are listed in Table 1. Each sample was placed on the chin support. After taking radiographic scans, volumetric data collected were processed using dedicated software (NNT NewTom®), which enabled to view in sequence the axial sections of each 3D model. The most coronal sectional image of the tooth, which corresponded with the photograph of the pulp chamber taken with the optical microscope, was chosen for measurement. On each image obtained by the processing software, a ruler with ticks each millimeter was added on the side as a reference, as for the photographs (Figure 1c).

A dedicated software for image analysis (Scion Image, Scion Corporation, National Institute of Health, Frederick, MD) was used to calculate the size of the area of interest (pulp chamber floor in a tooth horizontal section) in square millimetres (mm²). To benefit from the full potential of this program, a specific procedure was used for both methods: images loaded in the main screen resulting from the digital reflex camera, connected to the eyepiece of the microscope, and images derived from the elaboration of CBCT scans were stored in the digital “jpg” format. All images were coded and measurements were performed by the same trained operator, that loaded the images according to a random sequence, so as to minimizing evaluation bias. In order to evaluate the intra-operator reproducibility in performing measurements, before starting the study the operator evaluated the pulp chamber size of 5 monoradicated and 5 multiradicated teeth for 3 times each, with both techniques. The sequence of the teeth was changed each time. The measurements from the three sequences

were then compared with analysis of variance and Pearson's correlation test. In figure 2 are illustrated some steps of the procedure for measuring the area of the pulp chamber.

Statistical analysis

The normality of data distribution, considering separately the monoradicular and the multiradicular teeth, was evaluated with the D'Agostino and Pearson's omnibus normality test. The measurements on images obtained with the microscope and CBCT were compared using the two-tailed paired Student's t-test. The correlation between groups was evaluated with the Pearson r test. All analyses were carried out on the 2 separate sub-datasets of monoradicular and multiradicular teeth. A significance threshold of $P=0.05$ was considered. The statistical analysis was performed using GraphPad Prism software version 5.03 (GraphPad, La Jolla, CA, USA).

Results

Intra-operator agreement was very high, being correlations between consecutive measurements of the same samples between 97% and 99%. Table 2 summarizes the descriptive statistics of the pulp chamber floor area measurements performed by CBCT and microscopic techniques. No significant between-group difference was found in pulp chamber floor transversal area, neither for monoradicular teeth ($P=0.14$), nor for multiradicular teeth ($P=0.93$). The area measurement on images obtained with CBCT, however, were overestimated as compared to microscopic images. On the average the measurements with CBCT were 22.3% higher in monoradicular teeth and 31.5% higher in multiradicular teeth. The correlation analyses for single-rooted and multi-rooted teeth are shown in Fig. 3a,b. A fair correlation was found for both subsets of data, being r coefficient equal to 0.89 and 0.94 for mono- and multi-radicular teeth, respectively ($p<0.0001$ in both cases).

Discussion

The success of endodontic treatment depends on the identification of all root canals so that they can be accessed, cleaned, shaped, and obturated (10). Ramamurthy et al. found that investigators evaluating different two-dimensional film modalities were rarely able to detect the presence of the second mesiobuccal (MB2) canal in more than 50% of cases (11).

Matherne *et al.* (3) compared the ability of three board-certified endodontists to detect the number of root canals on intraoral digital (both charged-couple device and photostimulable phosphor) plate images with CBCT in 72 extracted teeth (3 equal groups of maxillary molars, mandibular premolars, and mandibular incisors). They found that on the average, the observers failed to detect at least one root canal in 40% of the teeth using intraoral radiographs (12). Abuabara *et al.* (13) in 2013 stated that the combined use of different methods increased the detection of the second canal in MB roots, but without a significant difference among CBCT, the operating microscope and clinical analysis. Baratto Filho *et al.* in 2009 demonstrated that operating microscope and CBCT are important tools for locating and identifying root canals, and CBCT represents a good method for the initial identification of maxillary first molar internal morphology (14).

Diagnostic information about the “third dimension” has particular importance in planning root-end surgery, in which the angle of the root respect to the cortical bone, the thickness of the latter and the relationship with adjacent anatomical structures such as the inferior alveolar nerve, the mental foramen, or the maxillary sinus, should be considered (15). The spatial relationship between the root (or roots) and surrounding anatomical structures or periradicular lesions cannot always be assessed with conventional intraoral radiographs (16). Also, the position and shape of anatomical structures inside the root to be tested (for example, isthmuses, lateral canals, and root resorption) may be difficult to assess. Furthermore, though the radiation dose of a single intraoral radiograph is very low, several intraoral projections taken at different angles may be necessary for the diagnosis of traumatic dental injuries such

as root fracture, luxation and avulsion (17). It has been reported that three or four intraoral radiographs of an area of interest taken with the parallel technique allowed for adequate depth perception and spatial relationships of periapical lesions (1). To be detectable radiographically, a periapical radiolucency should reach nearly 30%-50% of bone mineral loss (12). So, detection of early lesions may be challenging using two-dimensional radiographs. Also, the type of bone in which the lesion is located, with different thickness of the cortical layer, influences the radiographic visualization (18). A periapical lesion of a given size can be detected in a region covered by a thin cortex, whereas the same size lesion may not be observed in a region covered by a thicker cortex.

Stavropoulos and Wenzel compared CBCT (NewTom 3G) to digital- and film-based intraoral periapical radiography for the detection of periapical bone defects on 10 frozen pig mandibles by four calibrated examiners (19). They reported that CBCT provides greater diagnostic accuracy (61%) compared with digital (39%) and (44%) conventional radiographs. Özen *et al.* (20) performed a similar study comparing the detection of chemically induced periapical lesions by three observers using digital- and film-based conventional radiography to two CBCT systems (Iluma, Imtec Imaging, Ardmore, OK and iCAT, Imaging Sciences International, Hatfield, PA). They found that CBCT systems provided similar intra- and inter-observer agreement that was substantially higher than that of conventional radiography. Nevertheless, while detection rates for CBCT were higher, they did not advocate the replacement of intraoral radiography for detecting periapical lesions in routine clinical practice due to financial and radiation dose considerations. In a clinical study, Patel *et al.* found that the prevalence of periapical lesions in the paired roots of teeth with primary endodontic disease was detected with periapical radiographs and CBCT 20% and 48% of the time, respectively (21). In another study, periapical radiographs identified the presence of

periapical lesions in only 3% of the roots of endodontically treated molar teeth, whilst CBCT could demonstrate the presence of the lesion in 14% of the same roots (22).

Recent systematic reviews of the endodontic literature summarized the evidence on this topic, indicating that CBCT seems to offer the best performance among radiological methods for identifying periapical lesions and dental anatomy, as well as vertical root fractures (23-26).

Starting from these premises, the aim of this experimental study was to assess the accuracy of Cone-Beam technology to reproduce as closely as possible the true anatomy of the floor of the pulp chamber, by investigating the correlation between the results obtained using the microscope and those obtained with the CBCT.

We have chosen to include the extracted teeth in resin blocks of known size and shape, to ensure a solid medium to support and protect the sample under consideration, and to ensure standardization of measurements. A good correlation between the two methods was found, independent of the pulp chamber size. However, we found that CBCT tends to overestimate the actual size of the pulp chamber measured through the microscope. Such different outcomes in area estimation are usually of limited clinical relevance when the area of the pulp chamber is large, but may become relevant when the dimension of the pulp chamber is around or below 1.5 mm². This imprecision could derive from the fact that CBCT examines a calcified tissue, the dentin, which may have different degrees of calcification, and proximal dentin could be not completely calcified even if formed. Similarly, the light incidence on optical microscopic samples could determine little aberrations that can influence image border detection via software. It is likely that, when the two effects go towards different directions in the same sample, the discrepancy in size measurement between the two methods could be considerable, especially when the involved area is small.

Regarding this point, a recent paper by Brüllmann and Schulze (27) pointed out that using CBCT one cannot expect higher accuracy than in the range of half a millimetre at best, and

such error margins should be considered whenever treatment planning is based on CBCT images that require assessment or estimation of anatomical structures at the submillimeter dimension.

Conventional radiological examination, limited to two-dimensional periapical images, is still a valid tool in most endodontic cases, due to its accuracy and low exposure. However, CBCT may overcome many limitations of the periapical radiography as it provides diagnostic information on the three-dimensional anatomy of the tooth and adjacent structures, that can be essential for a careful treatment planning in specific situations. Nevertheless, it is important to determine the accuracy and the limits of CBCT when precision is needed in assessing the size of anatomical structures in the range or below one millimetre. Considering the higher radiation exposure when using CBCT, as compared to conventional radiographic techniques, its use should be considered only if its benefits prevail over any potential risks (28).

Conclusions

CBCT can be an excellent tool for estimating pulp chamber size and morphology. Though, its use should only be reserved to situations where conventional imaging systems do not provide adequate information to allow for proper management of the endodontic condition.

References

References

1. Brynolf I. A histological and roentgenological study of the periapical region of human upper incisors. *Odontol Rev* 1967;18:1-176.
2. Matherne RP, Angelopoulos C, Kulilid JC, et al. Use of cone-beam computed tomography to identify root canal systems in vitro. *J Endod* 2008;34:87-9.
3. Iwai K, Arai K, Hashimoto K, et al. Estimation of effective dose from limited cone beam X-ray CT examination. *Japan Dent Radiol* 2001;40:251-9.
4. Ngan DCS, Kharbanda OP, Geenty JP, et al. Comparison of radiation levels from computed tomography and conventional dental radiographs. *Aust Dent J* 2003;19:67-75.
5. Arai Y, Tammissalo E, Iwai K, et al. Development of a compact computed tomographic apparatus for dental use. *Dentomaxillofac Radiol* 1999;28:245-8.
6. Patel S, Durack C, Abella F et al. European Society of Endodontology position statement: the use of CBCT in endodontics. *Int Endod J* 2014;47:502-4.
7. Koç C, Sönmez G, Yılmaz F, Karahan S, Kamburoğlu K. Comparison of the accuracy of periapical radiography with CBCT taken at 3 different voxel sizes in detecting simulated endodontic complications: an ex vivo study. *Dentomaxillofac Radiol* 2018;47.
8. Stramotas S, Geenty JP, Petocz P, Darendeliler MA. Accuracy of linear and angular measurements on panoramic radiographs taken at various positions in vitro. *Eur J Orthod* 2002;24:43-52.
9. Flores-Mir C, Rosenblatt MR, Major PW, et al. Measurement accuracy and reliability of tooth length on conventional and CBCT reconstructed panoramic radiographs. *Dental Press J Orthod*. 2014;19:45-53.
10. Vertucci FJ. Root canal anatomy of the human permanent teeth. *Oral Surg Oral Med Oral Pathol* 1984;58:589-99.

11. Ramamurthy R, Scheetz JP, Clark SJ, et al. Effects of imaging system and exposure on accurate detection of the second mesio-buccal canal in maxillary molar teeth. *Oral Surg Oral Med Oral Pathol Oral Radiol Endodontol* 2006;102:796-802.
12. Bender IB, Seltzer S. Roentgenographic and direct observation of experimental lesions in bone I. *J Am Dent Assoc* 1961;62:152-60.
13. Abuabara A, Baratto-Filho F, Aguiar Anele J, et al. Efficacy of clinical and radiological methods to identify second mesiobuccal canals in maxillary first molars. *Acta Odontol Scand* 2013;71:205-9.
14. Baratto Filho F, Zaitter S, Haragushiku GA, et al. Analysis of the internal anatomy of maxillary first molars by using different methods. *J Endod* 2009;35:337-42.
15. Low MTL, Dula KD, Bürgin W, et al. Comparison of periapical radiography and limited cone-beam tomography in posterior maxillary teeth referred for apical surgery. *J Endod* 2008;34:557-62.
16. Cotti E, Campisi G. Advanced radiographic techniques for the detection of lesions in bone. *Endod Topics* 2004;7:52-72.
17. Flores MT, Andreasen JO, Bakland LK et al. Guidelines for the management of traumatic dental injuries. I. Fractures and luxations of permanent teeth. *Dent Traumatol* 2007;2:66-71.
18. Bender IB, Seltzer S. Roentgenographic and direct observation of experimental lesions in bone II. *J Am Dent Assoc* 1961;62:708-16.
19. Stavropoulos A, Wenzel A. Accuracy of cone beam dental CT, intraoral digital and conventional film radiography for the detection of periapical lesions. An ex vivo study in pig jaws. *Clin Oral Invest* 2007;11:101-6.
20. Özen T, Kamburoğlu K, Cebeci ARI, et al. Interpretation of chemically created periapical lesions using 2 different dental cone-beam computerized tomography units, an intraoral digital sensor, and conventional film. *Oral Surg, Oral Med, Oral Pathol, Oral Radiol Endodontol* 2009;107:426-32.
21. Patel S, Wilson R, Dawood A, et al. The detection of periapical pathosis using periapical radiography and cone beam computed tomography - part 1: pre-operative status. *Int Endod J*

- 2012;45:702-10.
22. Cheung GS, Wei WL, McGrath C. Agreement between periapical radiographs and cone-beam computed tomography for assessment of periapical status of root filled molar teeth. *Int Endod J* 2013;46:889-95.
 23. Corbella S, Del Fabbro M, Tamse A, et al. Cone beam computed tomography for the diagnosis of vertical root fractures: a systematic review of the literature and meta-analysis. *Oral Surg Oral Med Oral Pathol Oral Radiol* 2014;118:593-602.
 24. Kruse C, Spin-Neto R, Wenzel A, et al. Cone beam computed tomography and periapical lesions: a systematic review analysing studies on diagnostic efficacy by a hierarchical model. *Int Endod J* 2015;48:815-28.
 25. Patel S, Durack C, Abella F, et al. Cone beam computed tomography in Endodontics – a review. *Int Endod J* 2015;48:3-15.
 26. Rosen E, Taschieri S, Del Fabbro M, et al. The Diagnostic Efficacy of Cone-beam Computed Tomography in Endodontics: A Systematic Review and Analysis by a Hierarchical Model of Efficacy. *J Endod* 2015;41:1008-14.
 27. Brüllmann D, Schulze RK. Spatial resolution in CBCT machines for dental/maxillofacial applications-what do we know today? *Dentomaxillofac Radiol* 2015;44:20140204.
 28. Setzer FC, Hinckley N, Kohli MR, et al. A Survey of Cone-beam Computed Tomographic Use among Endodontic Practitioners in the United States. *J Endod* 2017;43:699-704.

Figure Legends

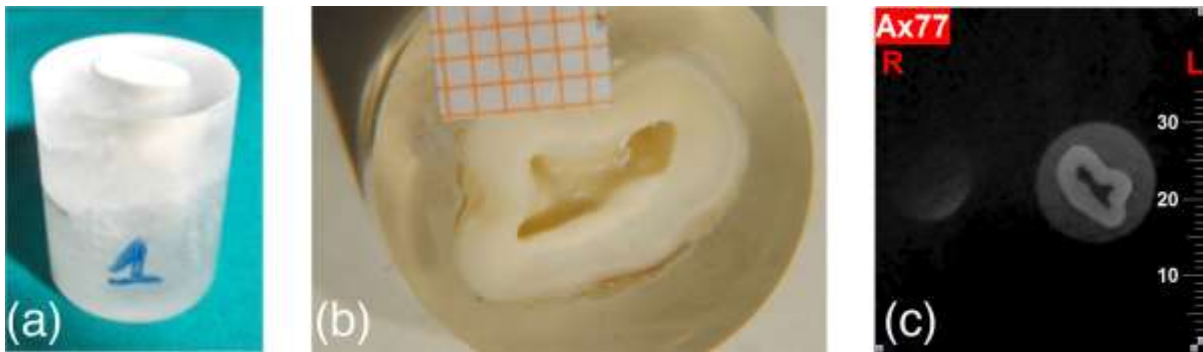


Figure 1: Preparation of the models and image recording. (a) an included, cut and refined tooth; (b) a tooth section with graph paper, photographed through the microscope (10x magnification); (c) the CBCT image of the same section.




Figure 2: Procedure for measuring areas. (a) a 1 mm reference line was drawn and the pulp chamber was selected with the thresholding tool; (b) the software was calibrated and the area of interest was highlighted; (c) the area of interest was measured with the dedicated software.

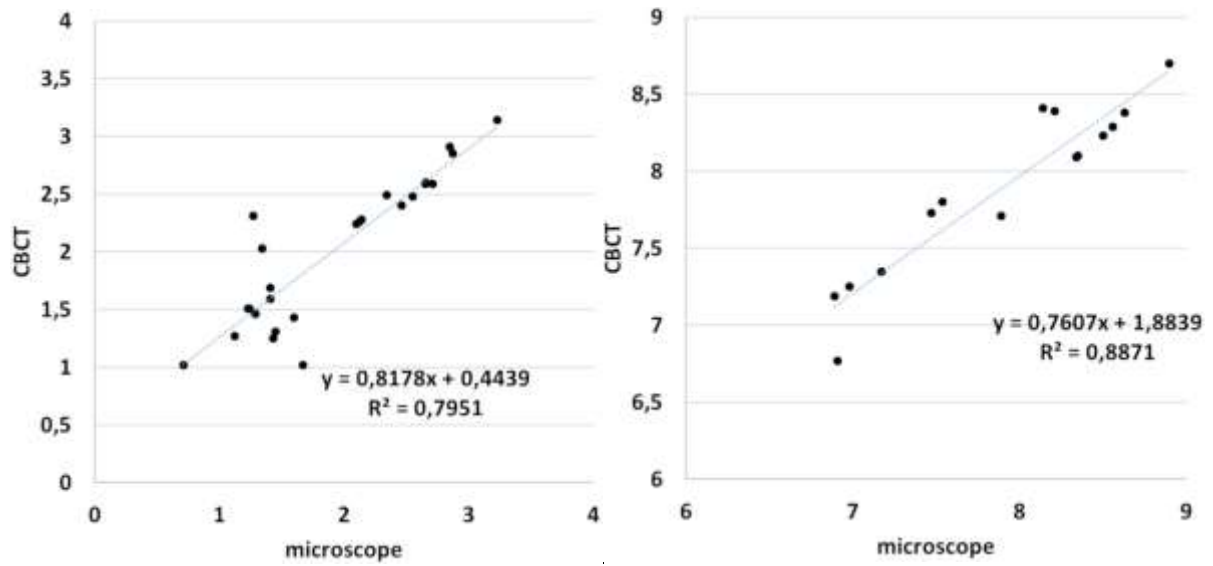


Figure 3: Scatter plots of the measured areas. (a) single-rooted teeth (b) multiple rooted teeth.

Linear regression equations and coefficients are shown.

Table 1 – NewTom VG specifications

Specification	NewTom VG
X- ray source	High frequency, constant potential (CD), rotating anode, 110 kV\120 mA (pulsed emission)
Field of View (FOV)	8" × 10"
Cone-Beam X-ray	Device control "Safe Beam" to reduce radiation
Dose	Approximately 50 µSv
Imaging	360 images by rotation of 360°
Detector images	Amorphous Silicon Flat Panel, 20 × 25 cm
Grey levels	14 bit
Voxel	0.3 mm cubic isometric, default and typical
Duration test	24 seconds
Reconstruction time	Typically, 3 minutes
Processing software	NNT NewTom
Weight	Scanning unit: 272 kg; control box: 100 kg
Alimentation	10A @ 100/115 V~, 5A @ 200/215/230/240 V~, 50/60 Hz

Table 2 – Descriptive statistics of the measurement of pulp chamber floor area performed by CBCT and microscopic techniques. Results are expressed in mm²

	Monoradicular		Multiradicular teeth	
	teeth (n = 25)		(n = 15)	
	CBCT	Microscope	CBCT	Microscope
Minimum	1.020	0.7100	6.770	6.890
25th percentile	1.445	1.315	7.530	7.320
Median	2.240	1.670	8.090	8.140
75th percentile	2.540	2.600	8.385	8.530
Maximum	3.140	3.230	8.700	8.900
Mean	2.009	1.914	7.893	7.899
Std. Deviation	0.6354	0.6927	0.5534	0.6852
Lower 95% CI	1.747	1.628	7.586	7.519
Upper 95% CI	2.271	2.200	8.199	8.278
