

Prophylactic arterial catheterization in the management of high risk patients for obstetric haemorrhage

S. GERLI, A. FAVILLI, G. AFFRONTI, M.M. ACANFORA, A. SABATINI¹,
C. FLORIDI¹, S. MOSCA¹, G.C. DI RENZO, M. SCIALPI¹

Department of Obstetrics and Gynecology, University of Perugia – Azienda Ospedaliera di Perugia, Perugia, Italy

¹Department of Radiology, University of Perugia, Perugia, Italy

Abstract. – OBJECTIVES: Post-partum haemorrhage still remains one of the major causes of maternal morbidity and mortality. In case of abnormal placentation it is possible to carry out preventive and therapeutic actions. To maintain fertility in reproductive-aged women and to avoid a more radical surgery, embolization has been introduced in patients at high risk for haemorrhage.

To describe a new option in the management of patients with abnormal placentation by an elective, preventive arterial catheterization and selective embolization of pelvic arteries.

PATIENTS AND METHODS: A retrospective study including thirty six patients with abnormal placental invasion. All patients were prepared in the angiographic room and preventive arterial catheterization was performed before elective caesarean delivery. Materials for interventional angiography were transferred to the operating room. During surgery, selective embolization of pelvic arteries was realized in case of uncontrolled bleeding.

RESULTS: Thirty-six elective arterial catheterizations were performed: 4 cases (11.1%) required embolization, haemorrhage was stopped in 2 patients. Hysterectomy was performed in two cases (5.5%). No death was reported. Two humeral thrombosis (5.5%) were registered.

CONCLUSIONS: Prophylactic arterial catheterization appears to be safe. The main advantage is the reduction of the interval between the onset of bleeding and the embolization. This new option of management may contribute to reduce the risk of hysterectomy and maternal death.

Key Words:

Arterial embolization, Postpartum haemorrhage, Arterial catheterization, Abnormal placenta, Postpartum hysterectomy.

Introduction

Post-partum haemorrhage (PPH) still remains one of the major causes of maternal morbidity and mortality^{1,2}.

Among the several causes of PPH, only abnormal placentation is reasonably expected and in such cases it is possible to carry out preventive actions. Therapeutic options for PPH, are: the use of uterotonic drugs and surgical conservative or radical procedures. Embolization is also considered an efficient therapeutic tool in PPH³. Vascular embolization is used in emergency^{4,5}, but prophylactic embolization of uterine arteries is also used in high risk of bleeding in pregnancy⁶. Other prevention techniques include the placement of bilateral arterial catheters containing a balloon, possibly inflated, during caesarean delivery^{7,8} or the association of balloon and embolization⁹.

To maintain fertility in reproductive-aged women and to avoid a more radical surgery, embolization has been introduced in patients at high risk for haemorrhage¹⁰.

The purpose of this study is to describe our experience in the management of patients at high risk of PPH by an elective, preventive arterial catheterization. We report a novel approach using prophylactic angiographic introducer, that allows, in emergency, an immediate vascular embolization without patient's transportation to the angiography room.

Patients and Methods

From January 2007 to August 2010 thirty six patients with abnormal placental invasion (ultrasound findings consistent with placenta previa and/or placenta accreta) have been included in the study.

Prior to the prophylactic arterial catheterization all patients were examined and counseled by a multidisciplinary team including gynaecologist,

obstetrician, anaesthesiologist, vascular and interventional radiologist.

Placenta praevia was, therefore, better characterized describing the anterior or posterior position and the presence of accretism. Abnormal placentation was diagnosed by ultrasound and confirmed by pelvic MRI. Diagnosis of placenta accreta was made by MRI and pathologically confirmed.

All patients were prepared in the angiographic room (Artis Zee Floor, Siemens). In the first 21 patients the humeral access under fluoroscopic guidance, with a 5 F angiographic catheter 125 cm long (Head-Hunter, Cordis) and ends just above the aortic bifurcation, was chosen. In the remaining 15 patients the right femoral artery access was preferred through 5-F vascular sheath (Terumo) attached to the skin by suture (Figure 1).

In all patients 3-8 ml of contrast medium with low concentration of iodine (300 mgI/ml) was used and the required radio protectionist measures (low-dose radiation and protection of the abdomen and pelvis with sealed shirt) were put in place.

After preparation of the patient, a mobile C-arm (OEC 9800 Plus, GE) and a special truck with materials for interventional angiography were transferred to the operating room for the planned caesarean section.

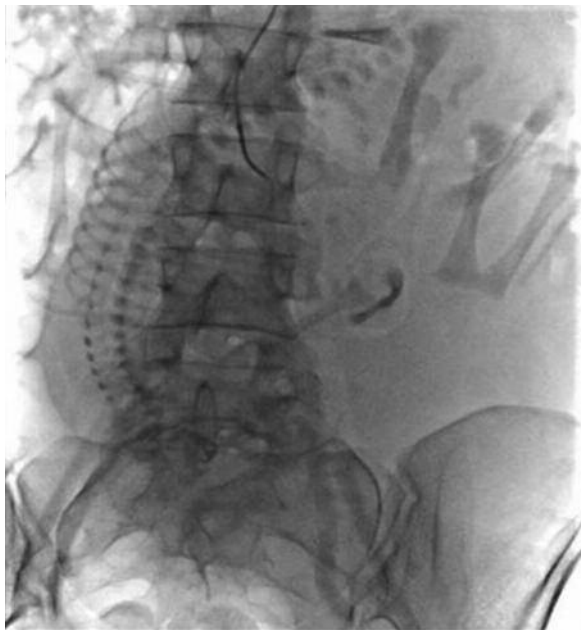

Figure 1. Angiography with low concentration contrast medium demonstrates the correct right femoral access with opacification of right iliac artery.

In case of intra-operative bleeding pharmacological and surgical procedures were implemented (uterotonic drugs, haemostatic square sutures, B-Lynch suture, insertion of Bakri-Balloon).

In case of uncontrolled bleeding, to avoid hysterectomy, a selective embolization of the uterine arteries was performed. In case of anatomical complexity and severity of the blood loss, the anterior branch of the hypogastric artery could also be embolized via the previously positioned angiocatheter.

Gelatin sponge powder (Spongostan Powder, Johnson-Johnson), metallic coils (Trufill, Johnson-Johnson) and non-absorbable particles (Contour SE, Boston Scientific) have been used as embolic agents. Absorbable gelatin sponge, inexpensive and readily available, were always preferred as first choice (Figures 2 and 3).

Clinical monitoring was realised to exclude a possible haematoma or thrombosis of the humeral or femoral arteries. Maternal and neonatal outcomes were considered for the analysis of results.

Results

Patients aged 35.7 years on average, mean gestational age at the time of caesarean was 36.0 weeks. Median neonatal birth weight was 2,700.0 g (2010-3660) and median Apgar Score were 7 (3-10) at 1 minute and 9 (7-10) at 5 minutes.

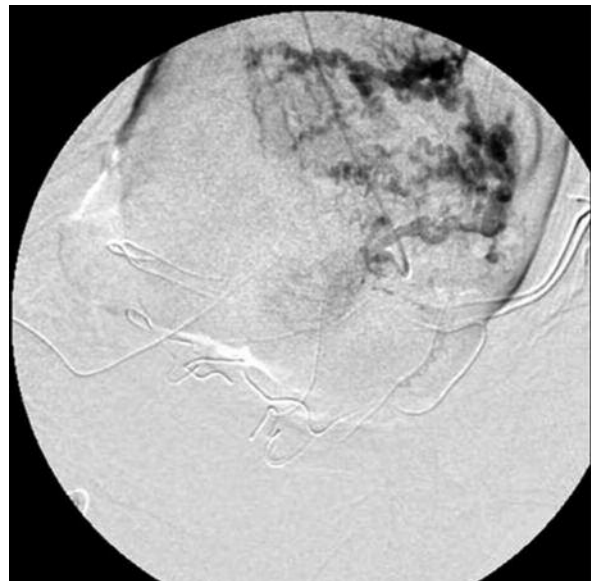


Figure 2. Left pre-embolization uterine artery selective angiography shows uncontrolled bleeding.

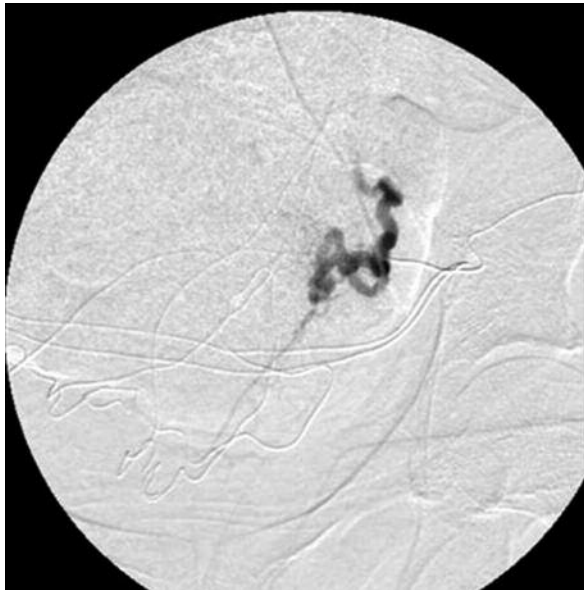


Figure 3. Angiographic control after selective left uterine artery embolization.

Among 36 elective procedures, 4 cases (11.1%) required embolization: a selective embolization of the uterine arteries was performed in three cases, while the anterior branch of the hypogastric artery was chosen in one case. The haemorrhage was stopped in 2 patients, while hysterectomy was performed in the other two cases (5.5% of cases) when a first embolization was not effective. In two patients, due to the persistence of significant blood loss after hysterectomy, non-absorbable embolic agents (coils and particles) were used. No death was reported.

The average blood loss was 968 ml; the coagulation factor VII, the haemostatic balloon and uterine compressive sutures were used in 8.3%, 72.2% and 61.1% of cases, respectively. In one case the ligation of uterine arteries was necessary; 4 patients (3 embolized) were transferred to the intensive care unit after the surgery. Two humeral thrombosis (5.5% of cases), fully recovered after treatment, have been reported and no late complications of embolization were registered.

Discussion

Post-partum haemorrhage is still today one of the most important causes of maternal morbidity and mortality. Among causes of PPH, only placenta previa and placenta accreta could be previously diagnosed before bleeding.

In the past abnormal placental invasion could only be detected during the 3rd stage of labour when bleeding became evident, with severe difficulties for the implementation of all surgical procedures able to stop bleeding⁷. Nowadays it is possible to prevent bleeding much earlier than the event occurs. The embolization technique in PPH was firstly described by Brown in 1979 when it was carried out in an emergency condition¹¹. A detailed embolization technique and the possibility of a preventive catheterization was firstly reported by Mitty et al in 1993¹². The main advantage of preventive catheterization techniques, compared with the emergency technique, is the reduction of the interval between the onset of bleeding and the embolization. In emergency conditions patients must be transferred from the operating room to the angiography room, where catheterization and embolization take place: the period of time between the onset of bleeding and the embolization is therefore significantly prolonged. Moreover, vascular spasms, caused by hypovolemia, occurs as often as more massive is the bleeding and it can interfere with the execution of the embolization technique⁶. The present study describes the possibility to offer the patient a preventive arterial catheterization, in a safe and elective setting, without the risks of performing the same procedure in emergency conditions.

Embolization in absence of bleeding has been proposed in the management of women with placenta previa/placenta accreta: Yu et al⁶ suggested to perform embolization immediately after extraction of the foetus.

Another technique proposed for the prevention of PPH is the use of intra-arterial balloon catheters inflated in case of PPH⁴. This procedure, implemented by an interventional radiologist in the angiography room on the morning of the caesarean section under fluoroscopic guide, needs a bilateral femoral access.

Compared to these angiographic techniques our proposal has therefore the advantage to offer the same results with lower costs, reduced invasiveness (only 1 femoral/humeral access versus 2 accesses), reduced time interval between the onset of bleeding and embolization, lower incidence of complications.

In this series only 4 women were embolized: the aim of our report was not to prove the efficacy of the embolization technique, but to describe a new option in the management of high risk patients. Different surgeons were involved

during caesarean deliveries and results could therefore be influenced by the specific surgical experience.

Complications have been described such as arterial dissection, allergic reactions or nephropathy due to the contrast medium, fever, abscesses, hematoma/thrombosis at the site of catheter insertion, and uterine necrosis^{4,13,14}.

Other complications could be related to the diameter and the amount of particles injected: in fact materials too small penetrate more distally and are more frequently responsible of ischemia and necrosis. On the other hand particles too large may be responsible of the failure of the procedure, because they may cause a too proximal embolization and the development of collateral network¹⁵.

Two cases of thrombosis of the humeral artery were detected. Thrombosis occurs more often in humeral artery than in femoral artery and for this reason the right femoral artery access was later preferred and should be considered as a first choice.

Another important issue is the fetal exposure to radiation in the angiography room during catheter placement. Wagner estimated that the 99.5% of foetuses exposed to radiation at doses up to 10 rads will not develop tumours during childhood¹⁶.

Some studies showed that embolization does not alter fertility of the patients^{13,17}, because the gelatine sponge particles are absorbed in about 1-3 weeks, with complete restoration of vascularization¹⁴.

Surgical techniques and preventive catheterization are complementary: it is possible to go through embolization after surgery and, in case of failure of the embolization technique, artery ligation and hysterectomy are still possible alternatives^{18,19}. Moreover embolization may be very useful in uncontrolled bleeding after hysterectomy²⁰. We have also to consider psychological implications of the proposed pre-surgical catheterization: the multidisciplinary team and the presence of the angiocatheter may actually offer the opportunity to the surgeon to act a safer surgical haemostasis during caesarean delivery and, in emergency conditions, during hysterectomy.

Conclusions

This new option of prophylactic management might have a major role in high risk patients with abnormal placental invasion and that the preventive arterial catheterization, with selective em-

bolization of pelvic arteries in case of uncontrolled bleeding during surgery, may allow a non-invasive and immediate treatment able to avoid hysterectomy and to preserve maternal life.

Conflict of Interest

The Authors declare that they have no conflict of interests.

References

- 1) HALL MH. Haemorrhage. In: Lewis G (ed). Why mothers die 2000-2002. The sixth report of the confidential enquiries into maternal deaths in the United Kingdom. London: RCOG Press, 2004: pp. 86-93.
- 2) AMERICAN COLLEGE OF OBSTETRICIAN AND GYNECOLOGIST. ACOG Practice Bulletin: Clinical Management Guidelines for Obstetricians-Gynecologists Number 76 October 2006: Postpartum Haemorrhage. *Obstet Gynecol* 2006; 108: 1039-1047.
- 3) ROYAL COLLEGE OF OBSTETRICIANS AND GYNAECOLOGISTS. Green-top Guideline No. 27. Placenta praevia, placenta praevia accreta and vasa praevia: diagnosis and management. London: RCOG; 2011.
- 4) SALAZAR GM, PETROZZA JC, WALKER TG. Transcatheter endovascular techniques for management of obstetrical and gynecologic emergencies. *Tech Vasc Interventional Rad* 2009; 12: 139-147.
- 5) BOULLERET C, CHAHID T, GALLOT D, MOFID R, TRAN HAI D, RAVEL A, GARCIER JM, LEMERY D, BOYER L. Hypogastric arterial selective and superselective embolization for severe postpartum hemorrhage: a retrospective review of 36 cases. *Cardiovasc Intervent Radiol* 2004; 27: 344-348
- 6) YU PC, OU HY, TSANG LL, KUNG FT, HSU TY, CHENG YF. Prophylactic intraoperative uterine artery embolization to control haemorrhage in abnormal placentation during late gestation. *Fertil Steril* 2009; 91: 1951-1955.
- 7) LEVINE AB, KUHLMAN K, BONN J. Placenta accreta: comparison of cases managed with and without pelvic artery balloon catheters. *J Matern Fetal Med* 1999; 8: 173-176.
- 8) TAN CH, TAY KH, SHEAH K, KWEEK K, WONG K, TAN HK, TAN BS. Perioperative endovascular internal iliac artery occlusion balloon placement in management of placenta accreta. *Am J Roentgenol* 2007; 189: 1158-1163.
- 9) HANSCH E, CHITKARA U, McALPINE J, EL-SAYED Y, DAKE MD, RAZAVI MK. Pelvic arterial embolization for control of obstetric hemorrhage: a five-year experience. *Am J Obstet Gynecol* 1999; 180: 1454-1460.
- 10) ORNAN D, WHITE R, POLLAK J, TAL M. Pelvic embolization for intractable postpartum hemorrhage: long-term follow-up and implications for fertility. *Obstet Gynecol* 2003; 102: 904-910.

- 11) BROWN BJ, HEASTON DK, POULSON AM, GABERT HA, MINEAU DE, MILLER FJ Jr. Uncontrollable postpartum bleeding: a new approach to hemostasis through angiographic arterial embolization. *Obstet Gynecol* 1979; 54: 361-365.
- 12) MITTY HA, STERLING KM, ALVAREZ M, GENDLER M. Obstetric hemorrhage: prophylactic and emergency arterial catheterization and embolotherapy. *Radiology* 1993;188: 183-187.
- 13) CHAULEUR C, FANGET C, TOURNE G, LEVY R, LARCHEZ C, SEFFERT P. Serious primary post-partum hemorrhage, arterial embolization and future fertility: a retrospective study of 46 cases. *Hum Reprod* 2008; 23: 1553-1559.
- 14) GILBERT WM, MOORE TR, RESNIK R, DOEMENY J, CHIN H, BOOKSTEIN JJ. Angiographic embolization in the management of hemorrhagic complications of pregnancy. *Am J Obstet Gynecol* 1992; 166: 493-497.
- 15) UCHIYAMA D, KOGANEMARU M, ABE T, HORI D, HAYABUCHI N. Arterial catheterization and embolization for management of emergent or anticipated massive obstetrical hemorrhage. *Radiat Med* 2008; 26: 188-197.
- 16) WAGNER LK, LESTER RG, SALDANA LR. Exposure of the pregnant patient to diagnostic radiations: a guide to medical management. Madison, WI: Medical Physics Publishing, 1997; p. 88.
- 17) FIORI O, DEUX JF, KAMBALE JC, UZAN S, BOUGDHENE F, BERKANE N. Impact of pelvic arterial embolization for intractable postpartum hemorrhage on fertility. *Am J Obstet Gynecol* 2009; 200: 384.e1-384.e4.
- 18) DESCARGUES G, DOUVRIN F, DEGRÉ S, LEMOINE JP, MARPEAU L, CLAVIER E. Abnormal placentation and selective embolization of the uterine arteries. *Eur J Obstet Gynecol Reprod Biol* 2001; 99: 47-52.
- 19) GERLI S, FAVILLI A, BINI V, DI RENZO GC. Postpartum hysterectomy: a regional multicentre analysis in Italy. *J Obstet Gynaecol* 2010; 30: 829-832.
- 20) OJALA K, PERÄLÄ J, KARINIEMI J, RANTA P, RAUDASKOSKI T, TEKAY A. Arterial embolization and prophylactic catheterization for the treatment for severe obstetric hemorrhage. *Acta Obstet Gynecol Scand* 2005; 84: 1075-1080.