

Concise report

Current evidence of methotrexate efficacy in childhood chronic uveitis: a systematic review and meta-analysis approach

Gabriele Simonini¹, Priyamvada Paudyal², Gareth T. Jones², Rolando Cimaz¹ and Gary J. Macfarlane²

Abstract

Objective. To summarize evidence regarding the effectiveness of MTX in the treatment of childhood autoimmune chronic uveitis (ACU).

Methods. A systematic search of articles between January 1990 and June 2011 was conducted using EMBASE, Ovid MEDLINE, Evidence-Based Medicine Reviews—ACP Journal Club, the Cochrane Library and EBM Reviews. Studies investigating the efficacy of MTX as a single immunosuppressant medication in the treatment of ACU refractory to therapy with topical treatment and/or systemic treatment in children (≤ 16 years) were eligible for inclusion. The primary outcome measure was the improvement of intraocular inflammation, expressed as Tyndall, as defined by the Standardization of Uveitis Nomenclature working group criteria. The effect measure for each study was the proportion of people classified as responders. We determined a combined estimate of the proportion of children in the eligible studies responding to MTX.

Results. The initial search identified 246 articles of which 52 were potentially eligible. Nine eligible articles, all retrospective chart reviews, remained in the analysis. The number of children in studies ranged from 3 to 25, and the dose of MTX varied from 7.5 to 30 mg/m². Altogether, 95 of 135 children responded to MTX. The pooled analysis suggested that MTX has a favourable effect in the improvement of intraocular inflammation: the proportion of responding subjects was 0.73 (95% CI 0.66, 0.81).

Conclusion. Although randomized controlled trials are needed, the available evidence supports the use of MTX in the treatment of childhood ACU: approximately three-quarters of patients on MTX can expect improvement in intraocular inflammation.

Key words: methotrexate, autoimmune chronic uveitis, childhood, refractory uveitis.

Introduction

Non-infectious uveitis in childhood, with an incidence and prevalence estimated at 5 and 30 per 100 000, respectively, is a serious disease, with the potential for significant long-term complications and eventually blindness.

Although frequently associated with an underlying systemic disease, e.g. JIA, Behçet's disease, sarcoidosis or tubulointerstitial nephritis, a significant number of cases are idiopathic. In case of refractory uveitis, early and aggressive immune-modulatory treatment, even in children, seems a reasonable approach to control inflammation, to achieve a CS-sparing effect and to decrease the risk of sight-threatening ocular damage [1]. However, there is much less experience and fewer cumulative data in treating children with uveitis or other inflammatory ocular diseases [2], and a lack of randomized controlled trials (RCTs) means that treatment with immunosuppressive drugs is supported only at evidence level III: expert opinion, clinical experience or descriptive studies [3]. MTX, a folate analogue inhibiting the enzyme

¹Rheumatology Unit-Department of Paediatrics, University of Florence, Firenze, Italy and ²Musculoskeletal Research Programme-Epidemiology Group, Institute of Applied Health Sciences, University of Aberdeen, UK.

Submitted 17 January 2012; revised version accepted 30 May 2012.

Correspondence to: Gabriele Simonini, Rheumatology Unit-Department of Pediatrics, University of Florence, Anna Meyer's Children Hospital, viale Pieraccini 24, Firenze 50139, Italy.
E-mail: gabriele.simonini@unifi.it

dihydrofolate reductase, is the most frequently used immunosuppressive in the paediatric uveitis population, but the lack of evidence from RCTs limits our understanding of effectiveness, the optimal time to start therapy and optimal duration [2, 3]. Due to its common use as steroid-sparing treatment in children, the purpose of this review is to summarize the best available evidence to date regarding the effectiveness of MTX in childhood autoimmune chronic uveitis (ACU).

Methods

Eligibility criteria

The following criteria were used to select eligible studies: (i) patients had vision-threatening non-infectious autoimmune uveitis; (ii) autoimmune uveitis was refractory to therapy with topical and/or systemic treatment, thus showing a chronic disease course with regard to steroid therapy according to the Standardization of Uveitis Nomenclature (SUN) criteria definition, that is persistent uveitis characterized by relapse within 3 months after discontinuation of therapy; (iii) patients had disease onset at or before 16 years of age; (iv) patients received MTX as single immunosuppressant medication for the treatment of uveitis; (v) outcome measures to assess the effectiveness of MTX were collected according to the SUN criteria [4]. Intraocular inflammation was considered active or uncontrolled if the inflammatory activity was grade $\geq 1+$ at any examination. Uveitis was defined as improved, and MTX as successful, when its activity decreased by two steps in the level of inflammation (anterior chamber cells and/or vitreous haze) or decreased to grade 0 [4]. For studies not completely adherent to the SUN criteria and those performed before 2005, where possible, we retrospectively applied the SUN activity terminology with regard to reported activity grading and only an activity grade of 0 was considered as improved; (vi) studies were published in English. Exclusion criteria were as follows: (i) the concomitant use of other immunosuppressant agents in addition to MTX; (ii) starting time of MTX administration after 16 years of age; and (iii) lack of applicability/adherence to the SUN working group criteria definition of improvement in uveitis activity.

Outcome measures

The main outcome measure used to assess the effect of MTX was the improvement of intraocular inflammation as Tyndall (anterior chamber cells), according to the definition of improvement of the SUN working group criteria [4]. As secondary outcomes, tapering and/or stopping systemic steroid administration, improvement in visual acuity post MTX treatment according to the SUN working group criteria, discontinuation of MTX, time to remission (the duration of MTX treatment needed to achieve remission-inactive disease), time on remission on therapy (the duration of on-going/persistent remission, while MTX treatment continued) and time on remission off therapy (the period with on-going/persistent remission after

discontinuing MTX treatment), and safety of administered drug were considered.

Information sources

Publications were retrieved using a computerized search of the following databases: EMBASE, Ovid MEDLINE, Evidence-Based Medicine (EBM) Reviews—ACP Journal Club, EBM Reviews—Cochrane Central Register of Controlled Trials, EBM Reviews—Cochrane Database of Systematic Reviews and EBM Reviews—Database of Abstracts of Reviews of effects. Publications between January 1990 and June 2011 were included.

Search strategy

Databases were searched with the key words chronic uveitis or chronic iridocyclitis or recurrent uveitis or refractory uveitis or non-infectious uveitis or autoimmune uveitis or inflamma\$ ocul\$ or inflamma\$ eye and were crossed with Metotrexate or Methotrexate or MTX. Of note, we did not include children, age or age limits in the search as MeSH terms because we may have been able to extract, if possible, a subcohort of children from studies including both children and adults. No limitation with regard to the type of the study was entered. This strategy excluded records related to infectious and/or suppurative uveitis.

Study selection

Two reviewers (G.S., P.P.) independently screened the retrieved titles and abstracts and excluded duplicates and those obviously irrelevant. If the information in the abstracts was insufficient to make a decision, full papers were retrieved. Full papers of the selected articles were examined to determine whether they satisfied the criteria (G.S.) and then confirmed by a second reviewer (P.P.). The references of all eligible articles including reviews, expert opinion papers and systematic reviews were manually searched for potentially eligible publications. During consensus meetings (G.S., P.P., G.J., G.M.), disagreements of selections were resolved. In addition, we contacted authors of studies to determine whether data on an eligible subgroup were available.

Data extraction and items

Data were extracted by a single reviewer (G.S.) using a standard form, and checked by a second reviewer (P.P.). The data items extracted were as follows: study design, study start/end dates, length of follow-up, aim of the study, characteristics of participants (number of children, gender, age and associated conditions), dose of MTX and all outcome measures.

Statistical analysis

A meta-analysis was conducted to determine a combined estimate of the proportion of children in the eligible studies responding to MTX. The effect measure for each study was the proportion of participants classified as responders on MTX, with respect to intraocular inflammation [p(i)], where i refers to study i. If not provided in the

original manuscript, we calculated a 95% CI for the observed proportion. We tested for heterogeneity between the effect estimates from studies by conducting Cochrane's χ^2 test, which has $k - 1$ degrees of freedom, where k is the number of studies. In combining estimates, each study estimate was given a weight as the inverse of the proportion variance [i.e. $n(i)/(p(i)[1 - p(i)])$ for study i], where $n(i)$ is the number of persons in study i . The combined estimate (p) and its standard error were then calculated in order to provide a 95% CI for this combined estimate of the proportion of patients improving.

Results

A total of 246 articles were identified by searches of databases, and, from these, 194 were excluded by examination of their titles and abstracts. Excluded studies were mainly studies not reporting paediatric cases, duplicates, studies on diseases other than autoimmune non-infectious uveitis, studies on overall mortality among patients receiving immunosuppressive treatment and studies on drugs other than MTX. Full text of the remaining 52 studies and 20 additional papers obtained by screening of their references were scrutinized. From the selection process, a total of nine relevant articles were deemed eligible. The other 63 potential eligible papers were excluded because they were reviews and/or expert opinion papers, they had no information regarding MTX efficacy as single immunosuppressive therapy, it was not possible to extract data on children from an overall study population and this was not available from authors, they did not include data on the principal outcome and/or were non-adherent to SUN criteria.

Table 1 summarizes data items from each eligible paper. All of the included studies were retrospective chart reviews, with a median follow-up time of 22.5 months (range 1–96). The number of children in these studies ranged from 3 to 28, providing a total of 135 children. It was not possible to extract detailed childhood descriptive data from some of the included studies: regarding gender from three studies [6, 9, 11] and age at uveitis onset from one [11]. Twenty-three subjects were male, 46 were female, and the median age of uveitis onset was 8 years (range 1.8–16). Chronic uveitis was associated with JIA ($n = 121$), early-onset sarcoidosis ($n = 5$) and tubulointerstitial nephritis ($n = 3$); the remaining were idiopathic. Six of the nine studies, with a total of 119 patients, were exclusively in JIA patients. Four studies reported a MTX dose between 7.5 and 30 mg/m², weekly, with 15 mg/m² the most commonly used dose. Four studies did not report the dose per m² of body surface and the MTX dose varied from 7.5 to 40 mg/week (median dose/week 12.5 mg); in one study MTX was administered at a dose of 0.5–1 mg/kg, weekly [13].

All included studies reported our main outcome measure: the improvement of intraocular inflammation as Tyndall (anterior chamber cells), according to the definition of improvement of the SUN working group criteria. Altogether, 95 children out 135 included responded to the treatment. The pooled analysis suggested that MTX has a

favourable effect in the improvement of intraocular inflammation: 0.73 (95% CI 0.67, 0.81) was the combined estimate of the proportion of subjects improving on MTX (Fig. 1), and there was no evidence of heterogeneity across studies ($P = 0.5$). In a subanalysis including only those studies exclusively on JIA the estimate was very similar (0.74, 95% CI 0.67, 0.82).

Not all of the secondary outcome variables were present in each study and often were reported in diverse ways; thus we were not able to perform effect size analyses on these. All eligible papers, except Samson *et al.* [11], which did not report separate childhood data, had information regarding MTX discontinuation: MTX was discontinued in 35 (32.7%) out of 107 children, due to persistent remission in 21 (19.6%), lack of efficacy in 7 (6.5%) and adverse events in the remaining 7. Time to remission on MTX was described in 5 [5–7, 9, 12] out of 9 eligible papers: 45 (73.8%) out of 61 children obtained remission over a median time of 3.5 months (range 1–12). In addition, Foeldvari *et al.* [7] along with Weiss *et al.* [13] reported that 25/29 children remained on remission on MTX for a median time of 10.6 months (range 3–27). However, Heiligenhaus *et al.* [6] reported that remission as per SUN criteria was not obtained in any of the patients during a follow-up period of 27.6 months, and Foeldvari showed that, after MTX discontinuation, 2 of 6 children experienced uveitis flares 3 and 8 months later [7]. During MTX administration, tapering and/or stopping systemic steroid administration was possible in 22 of 23 children, but data were available from only four papers [5, 6, 8, 12]. Data regarding visual outcome have been reported in three articles [6, 8, 10]: 11 of 13 children (84.6%) showed improvement or stable visual acuity post MTX treatment. We could not extract information from Heiligenhaus study [6] because some of their patients (7 of 35) received MTX along with other immunomodulatory drugs. Among 107 MTX exposed children (data regarding children were not available from Samson *et al.*'s study [11]), 21 (19.6%) experienced adverse events due to MTX administration: 10 children had gastrointestinal discomfort, mostly nausea, 6 showed elevation of liver enzymes, reversible in 3, the remaining 5 children presented both nausea and increased liver function tests.

Discussion

We have estimated that the overall probability of improvement of intraocular inflammation in children affected by refractory ACU treated with MTX is 73%. The estimates of response were similar across studies, in particular when we considered those studies (6 of 9) that included only patients with JIA. However, several caveats have to be discussed before drawing firm conclusions from our systematic review. We recognize RCTs as the gold standard in assessing drug effectiveness; thus because none are available we acknowledge the generally poor quality of evidence. The majority of eligible studies only included patients with JIA, along with other diseases. However, the small number of the available studies meant we

TABLE 1 Main outcome measure and secondary outcomes entered for each of nine eligible studies

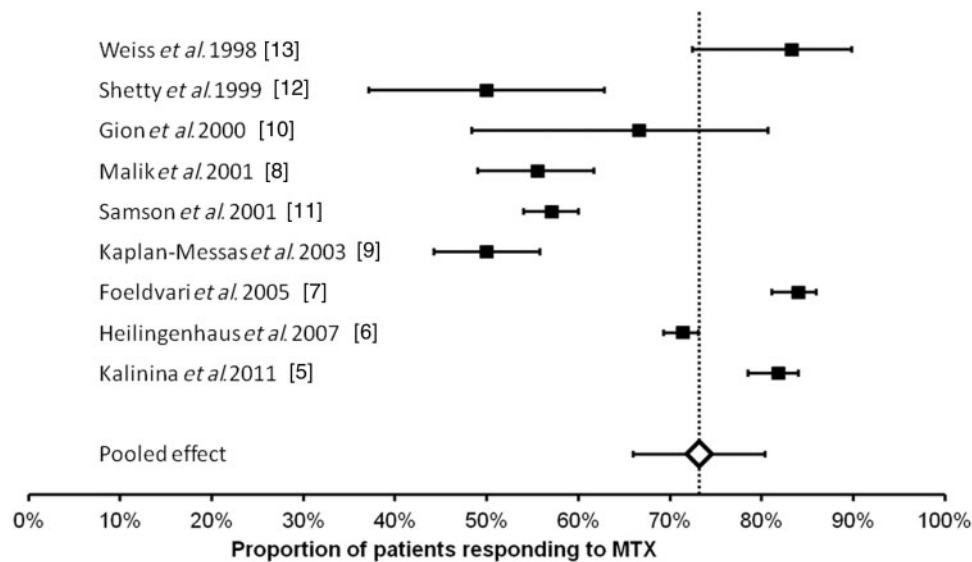
Reference, country	Follow-up	n (male/female)	Age, years	Disease	Dose of MTX	Results/outcomes	Adverse events
Kalinina Ayuso et al. (2011) [5], The Netherlands	3.1 years	22 (7/15)	8 (±4.0)	JIA	10–15 mg/m ²	<p>Uveitis activity: Improved activity in 18 (82%) patients. Discontinuation of MTX: One patient due to gastrointestinal side effects. One patient due to elevated liver enzymes. Thirteen patients due to persistent remission.</p> <p>Steroid intake: Three of four patients on steroid stopped the intake within 2 months after the MTX treatment.</p> <p>Time for remission on MTX: Fifteen patients achieved remission within 1 year (median = 0.5).</p> <p>Time on remission on MTX: 1.5 years (1 month–3 years)</p>	<p>Eleven patients: Gastrointestinal complaints in 7. Elevated liver enzyme in 2. Combination of both in 2.</p>
Heiligenhaus et al. (2007) [6], Germany	27.6 (11–89) months	35 (15/20)	4.1 (1–7) arthritis; 4.8 (2–10) onset uveitis	JIA	15 mg/m ²	<p>Uveitis activity: Improved activity in 25 (71%) patients. Mean time for uveitis flares up after the treatment: 10.3 (3–25) months. Discontinuation of MTX: One patient due to nausea. Three patients due to lack of efficacy. Time for improvement on MTX: 3.75 (2–11) months. Time on remission without MTX: None achieved remission. Steroid intake: All eight patients on steroid stopped the intake after MTX treatment.</p> <p>Visual acuity: Information available on 66 eyes out of 70 eyes; 91% stable and/or improved. Uveitis complications: No new complication occurred in 20. Progression was observed in 15 others.</p>	<p>Increased liver enzyme, 2 patients, nausea, 1 patient</p>
Földvari and Wierk (2005) [7], Germany	2.2 years	25 (11/14)	7.9 (1.25–15.7) onset arthritis; 8 (1.8–9) onset uveitis	JIA	15.6 (10–25) mg/m ²	<p>Uveitis activity: Improved activity in 21 (84%) patients. Discontinuation of MTX: Six patients due to persistent remission for 12 months. One patient discontinued due to MTX adverse events. Time for remission on MTX: 4.5 (1–12) months. Time on remission on MTX: 10.3 months (3–27).</p>	<p>One patient</p>

(continued)

TABLE 1 Continued

Reference, country	Follow-up	n (male/female)	Age, years	Disease	Dose of MTX	Results/outcomes	Adverse events
Malik and Pavesio (2005) [8], UK	22.5 (4–40) months	9 (2/7)	11.9 (7–16)	Six patients with idiopathic uveitis and three with Sarcoidosis	23.8 (17.5–30) mg/m ²	Uveitis activity: Improved activity in 5 (55%) patients. Discontinuation of MTX: None. Steroid intake: All the seven children, taking steroid reduced intake after MTX treatment. Initial dose 18 (10–40) mg/die, final dose 2.85 (5–7.5) mg/die. Visual acuity: Improved or stable in all patients. Uveitis activity: Improved activity in 5 (50%) patients. Discontinuation of MTX: Three patients due to side effects. Two patients due to lack of efficacy. Two patients due to persistent remission after 20.9 (±9.2) months. Time for remission: 2.4 (±0.8) months. Uveitis activity: Improved activity in 2 (67%) patients. Discontinuation of MTX: One patient due to lack of efficacy. Steroid intake: Discontinued in the two patients in whom activity improved. Visual acuity: Among patients who improved in activity: one stable, one improved.	Nausea, 2 patients
Kaplan-Messas <i>et al.</i> (2003) [9], Israel	21.5 months (±12.6)	10	3–16	JIA	10–15 mg/week	Uveitis activity: Improved activity in 5 (50%) patients. Discontinuation of MTX: Three patients due to side effects. Two patients due to lack of efficacy. Two patients due to persistent remission after 20.9 (±9.2) months. Time for remission: 2.4 (±0.8) months. Uveitis activity: Improved activity in 2 (67%) patients. Discontinuation of MTX: One patient due to lack of efficacy. Steroid intake: Discontinued in the two patients in whom activity improved. Visual acuity: Among patients who improved in activity: one stable, one improved.	Nausea/vomiting, elevated liver enzymes, 3 patients
Gion <i>et al.</i> (2000) [10], USA	19.6 months (6–34)	3 (2/1)	13 (13–15)	TINU	7.5–12.5 mg/week	Uveitis activity: Improved activity in 2 (67%) patients. Discontinuation of MTX: One patient due to lack of efficacy. Steroid intake: Discontinued in the two patients in whom activity improved. Visual acuity: Among patients who improved in activity: one stable, one improved.	Abdominal pain, 1 patient
Samson <i>et al.</i> (2001) [11], USA	16.4 months (1–96)	21	-	JIA	12.3 (7.5–40) mg/week	Uveitis activity: Improved activity in 12 (59%) patients. Uveitis activity: Improved activity in two patients. Discontinuation of MTX: None. Steroid intake: Reduced intake in all patients. One patient stopped steroid within 30 months of MTX and three reduced the dose up to 0.15 mg/die in 20 months.	-
Shetty <i>et al.</i> (1999) [12], USA	28.8 months	4 (1/3)	10.5	2 JIA 2 Sarcoidosis	7.5–12.5 mg/week	Uveitis activity: Improved activity in two patients. Discontinuation of MTX: None. Steroid intake: Reduced intake in all patients. One patient stopped steroid within 30 months of MTX and three reduced the dose up to 0.15 mg/die in 20 months.	No adverse events
Weiss <i>et al.</i> (1998) [13], USA	10 months (6–12)	6 (-/6)	7 (4–14)	JIA	0.5–1 mg/kg/week	Uveitis activity: Improved activity in five patients. Discontinuation of MTX: One patient due to lack of efficacy. Time for remission: 3.5 (2.5–4) months (for four patients). Time on remission on MTX: 11 (8–12) months available for four patients.	Reversible liver toxicity, 2 patients

Fig. 1 Proportion of children with refractory ACU responding to MTX in each study and the overall effect size showed by the pooled analysis, 95% CI are shown.



could not consider results separately according to the underlying disease. We did not include studies when it was not possible to extract information on eligible children from those studies (e.g. a study of Behçet's disease [14]). This affected several large studies on this topic—e.g. Yu *et al.* [15]. We contacted authors to determine whether information was specifically available on children to allow the study to be included, but this did not result in any additional study being eligible. The main outcome measure used in this systematic review might be considered another limitation: the definition of improvement of the SUN working group criteria [4] is not assessed in childhood, and therefore not validated for childhood use. However, it is otherwise the only standardized measure available for assessing differences in uveitis inflammation, and thus to date, the only item able to compare different studies, across different decades and different childhood diseases. The different steroid use, as systemic administration rather than eye drop, significantly changed over the considered time period, might be an additional potential caveat.

There are no clear recommendations for MTX use in childhood, even though it is largely used in chronic uveitis, mostly when associated with JIA [2, 3, 16–20]. The results of this review could be helpful for clinicians in judging the utility of this treatment and its effect size on visual prognosis, as well as in making a therapeutic decision based on current available evidence. Our findings support the clinical use of MTX for refractory ACU in children. However, it needs to be considered in the context that all the current evidence is from retrospective chart reviews. The results of this meta-analysis should prompt the conduct of RCTs on this topic, involving paediatric rheumatologists,

ophthalmologists and pharmaceutical companies, to provide a higher quality evidence base.

Rheumatology key messages

- There are few cumulative data on treating children with chronic uveitis.
- MTX seems an effective therapy for childhood non-infectious uveitis associated with JIA and possibly other conditions.
- Randomized clinical trials in childhood ACU treatment seem mandatory.

Disclosure statement: G.T.J. has received grants/research support from Pfizer Inc, NY, USA. All other authors have declared no conflicts of interest.

References

- 1 Cunningham ET. Uveitis in children. *Ocul Immunol Inflamm* 2000;8:251–61.
- 2 Agle LMA, Vazquez-Cobian LB, Lehman TJA. Clinical trials in pediatric uveitis. *Curr Rheum Rep* 2003;5:477–81.
- 3 Simonini G, Cantarini L, Bresci C *et al.* Current therapeutic approaches to autoimmune chronic uveitis in children. *Autoimmun Rev* 2010;9:674–83.
- 4 Jabs DA, Nusseblatt RB, Rosebaum JT. Standardization of uveitis nomenclature for reporting clinical data. Results of the first international workshop. *Am J Ophthalmol* 2005;140:509–16.
- 5 Kalinina Ayuso V, van de Winkel EL, Rothova A, de Boer JH. Relapse rate of uveitis post-methotrexate

- treatment in juvenile idiopathic arthritis. *Am J Ophthalmol* 2011;151:217–22.
- 6 Heiligenhaus A, Mingels A, Heinz C, Ganser G. Methotrexate for uveitis associated with juvenile idiopathic arthritis: value and requirement for additional anti-inflammatory medication. *Eur J Ophthalmol* 2007;17:743–8.
 - 7 Foeldvari I, Wierk A. Methotrexate is an effective treatment for chronic uveitis associated with juvenile idiopathic arthritis. *J Rheumatol* 2005;32:362–5.
 - 8 Malik AR, Pavesio C. The use of low dose methotrexate in children with chronic anterior and intermediate uveitis. *Br J Ophthalmol* 2005;89:806–8.
 - 9 Kaplan-Messas A, Barkana Y, Avni I, Neumann R. Methotrexate as a first-line corticosteroid-sparing therapy in a cohort of uveitis and scleritis. *Ocul Immunol Inflamm* 2003;11:131–9.
 - 10 Gion N, Stavrou P, Foster CS. Immunomodulatory therapy for chronic tubulointerstitial nephritis-associated uveitis. *Am J Ophthalmol* 2000;129:764–8.
 - 11 Samson CM, Waheed N, Baltatzis S, Foster CS. Methotrexate therapy for chronic noninfectious uveitis: analysis of a case series of 160 patients. *Ophthalmology* 2001;108:1134–9.
 - 12 Shetty AK, Zganjar BE, Ellis GS Jr, Ludwig IH, Gedalia A. Low-dose methotrexate in the treatment of severe juvenile rheumatoid arthritis and sarcoid iritis. *J Pediatr Ophthalmol Strabismus* 1999;36:125–8.
 - 13 Weiss AH, Wallace CA, Sherry DD. Methotrexate for resistant chronic uveitis in children with juvenile rheumatoid arthritis. *J Pediatr* 1998;133:266–8.
 - 14 Zakka FR, Chang PY, Giuliari GP, Foster CS. Current trend in the management of ocular symptoms in Adamantiades-Beçhet's disease. *Clin Ophthalmol* 2009;3:567–9.
 - 15 Yu ENY, Meniconi ME, Tufail F, Baltatzis S, Foster CS. Outcomes of treatment with immunomodulatory therapy in patients with corticosteroid-resistant juvenile idiopathic arthritis-associated chronic iridocyclitis. *Ocul Immunol Inflamm* 2005;13:353–60.
 - 16 Lyon F, Gale RP, Lightman S. Recent developments in the treatment of uveitis: an update. *Expert Opin Investig Drugs* 2009;18:609–16.
 - 17 Jabs DA, Rosenbaum JT, Foster CS *et al.* Guidelines for the use of immunosuppressive drugs in patients with ocular inflammatory disorders: recommendations of an expert panel. *Am J Ophthalmol* 2000;130:492–513.
 - 18 Zierhut M, Doycheva D, Biester S *et al.* Therapy of uveitis in children. *Int Ophthalmol Clin* 2008;48:131–52.
 - 19 Holzinger D, Frosch M. New treatment approaches in juvenile idiopathic arthritis. *Int J Adv Rheumatol* 2009;7:1–7.
 - 20 Sharma SM, Dick AD, Ramanan AV. Non-infectious pediatric uveitis: an update on immunomodulatory management. *Paediatr Drugs* 2009;11:229–41.