

CLINICAL IMPLANT DENTISTRY and Related Research

Soft tissue augmentation applying a collagenated porcine dermal matrix during second-stage surgery: A prospective multi-center case series

Journal:	<i>Clinical Implant Dentistry and Related Research</i>
Manuscript ID	CID-19-093.R1
Manuscript Type:	Original Article
Date Submitted by the Author:	n/a
Complete List of Authors:	Fischer, Kai; University Witten Herdecke Faculty of Health, Department for Periodontology Testori, Tiziano; IRCCS Istituto Ortopedico Galeazzi Wachtel, Hannes; Geriatric Dentistry and Craniomandibular Disorders, Charité, Department of Prosthodontics Mühlemann, Sven; Center of Dental Medicine, Clinic of fixed and removable prosthodontics and Dental Material Science Happe, Arndt; University of Cologne, Department of Oral and Maxillofacial Plastic Surgery and Implantology Del Fabbro, Massimo; Università degli Studi di Milano, Department of Biomedical, Surgical and Dental Sciences
Keywords:	gingival thickness, acellular dermal matrix, second stage surgery, dental implant, soft tissue augmentation
Abstract:	<p>Background: The achievement and preservation of an adequate amount of soft tissue around implants is a critical factor for the prognosis of the treatment.</p> <p>Purpose: To evaluate the effectiveness of a porcine dermal matrix applied during second stage implant surgery for horizontal soft tissue augmentation and preservation of dimensional stability.</p> <p>Material & Methods: Twenty patients (mean age 50.2±11.9 (standard deviation) years) candidate to implant therapy and requiring soft tissue augmentation were recruited in four centers. Augmentation was performed in 24 cases. A porcine dermal matrix was placed into a buccal split-thickness pouch during uncovering surgery. Silicone impressions were taken before surgery (T0), two weeks later at suture removal (T2), six months (T3) and 24 months (T4) post augmentation. Dimensional changes of soft tissue were evaluated using superimposition of digitalized study casts.</p> <p>Results: Nineteen patients (23 implants) could be evaluated at six months and 13 patients (17 implants) at 24 months. After 6-month follow-up there was a significant dimensional gain respect to baseline, averaging 0.83±0.64mm (p<0.01). This did not change significantly at 24 months (0.77±0.65mm, p=0.19). The gain was >0.5 mm in 65.2% and 64.7% of the cases, respectively. Soft tissue shrinkage averaged 34.2%±77.0% from T2 to T3 (p<0.01) and did not change thereafter (p=0.39). Shrinkage was more consistent in the posterior mandible than in the maxilla, but not significantly (p=0.23 at 6-month and 0.36 at 24-</p>

1
2
3
4
5
6
7
8
9
10
11
12
13
14
15
16
17
18
19
20
21
22
23
24
25
26
27
28
29
30
31
32
33
34
35
36
37
38
39
40
41
42
43
44
45
46
47
48
49
50
51
52
53
54
55
56
57
58
59
60

	month). No adverse events occurred. Conclusions: Within the limitations of this prospective case series, the use of a porcine dermal matrix may provide consistent soft tissue augmentation that maintains up to 24-month follow-up, though graft shrinkage may occur in the first 6 months, depending on the location of surgery.

SCHOLARONE™
Manuscripts

Title:

Soft tissue augmentation applying a collagenated porcine dermal matrix during second-stage surgery: A prospective multi-center case series.

Running head:

Soft tissue augmentation with a porcine matrix

Authors:

Kai R. Fischer, DDS; Senior Clinical Lecturer, Department for Periodontology, Faculty of Health, Witten/Herdecke University, Germany. Division for Periodontology & Peri-implant Disease, [University of Zurich—University, Switzerland](#).

Tiziano Testori, MD, DDS; Adjunct Clinical Associate Professor, Department of Periodontics and Oral Medicine, University of Michigan, School of Dentistry, Ann Arbor, Michigan, USA. IRCCS Orthopedic Institute Galeazzi, Milan, Italy. [Private practice, Como, Italy](#).

Hannes Wachtel, DDS, PhD, Professor, Department of Prosthodontics, Geriatric Dentistry and Craniomandibular Disorders, Medicine Charité, University of Berlin, Germany. [Private practice, München, Germany](#).

Sven Mühlemann, DDS; Senior teaching and Research Assistant, Clinic of Fixed and Removable Prosthodontics, Zurich University, Switzerland

Arndt Happe*, DDS, PhD; Assistant Professor, Department of Oral and Maxillofacial Plastic Surgery and Implantology, University of Cologne, Germany. Private practice, [Münster, Germany](#).

Massimo Del Fabbro*, MSc, PhD; Associate Professor, Department of Biomedical, Surgical and Dental Sciences, Università degli Studi di Milano, Milan, Italy. IRCCS Orthopedic Institute Galeazzi, Milan, Italy.

*these two authors shared the senior position as last authors

Corresponding author:

Dr. Kai Fischer, DDS, [Divison of Periodontology & Peri-implant disease; Clinic of Preventive Dentistry, Periodontology and Cariology; University of Zurich; Plattenstraße 11, 8032 Zurich, Switzerland](#)~~Department for Periodontology, Faculty of Health, Witten/Herdecke University, Witten, Germany~~; E-mail: kai.fischer@uni-wh.dezzm.uzh.ch

1
2
3 **Conflict of interest statement.**
4

5 There was no financial support for this study. The materials for augmentation were
6 kindly provided by Tecnos® Dental S.r.l., [GiavenoTorino](#), Italy. The Authors declare
7 they have no conflicts of interest.
8
9
10
11
12
13
14
15
16
17
18
19
20
21
22
23
24
25
26
27
28
29
30
31
32
33
34
35
36
37
38
39
40
41
42
43
44
45
46
47
48
49
50
51
52
53
54
55
56
57
58
59
60

For Review Only

Author contribution statement

Kai R. Fischer: Concept/Design, data acquisition, drafting the paper, critical revision, final approval of the version to be published, agreement to be accountable for all aspects of the work in ensuring that questions related to the accuracy or integrity of any parts of the work are appropriately investigated and resolved.

Tiziano Testori: Concept/Design, data acquisition, critical revision of the paper, final approval of the version to be published, agreement to be accountable for all aspects of the work in ensuring that questions related to the accuracy or integrity of any parts of the work are appropriately investigated and resolved.

Hannes Wachtel: Concept/Design, data acquisition, critical revision of the paper, final approval of the version to be published, agreement to be accountable for all aspects of the work in ensuring that questions related to the accuracy or integrity of any parts of the work are appropriately investigated and resolved.

Sven Mühlemann: data acquisition and analysis, critical revision of the paper, final approval of the version to be published, agreement to be accountable for all aspects of the work in ensuring that questions related to the accuracy or integrity of any parts of the work are appropriately investigated and resolved.

Arndt Happe: Concept/Design, data acquisition, drafting the paper, critical revision, final approval of the version to be published, agreement to be accountable for all aspects of the work in ensuring that questions related to the accuracy or integrity of any parts of the work are appropriately investigated and resolved.

Massimo Del Fabbro: statistical analysis and interpretation of data, drafting the paper and critical revision, final approval of the version to be published, agreement to be accountable for all aspects of the work in ensuring that questions related to the accuracy or integrity of any parts of the work are appropriately investigated and resolved.

Abstract

Background: The achievement and preservation of an adequate amount of soft tissue around implants is a critical factor for the prognosis of the treatment.

Purpose: To evaluate the effectiveness of a porcine dermal matrix applied during second stage implant surgery for horizontal soft tissue augmentation and preservation of dimensional stability.

Material & Methods: Twenty patients (mean age 50.2 ± 11.9 (standard deviation) years) candidate to implant therapy and requiring soft tissue augmentation were recruited in four centers. Augmentation was performed in 24 cases. A porcine dermal matrix was placed into a buccal split-thickness pouch during uncovering surgery. Silicone impressions were taken before surgery (T0), two weeks later at suture removal (T2), six months (T3) and 24 months (T4) post augmentation. Dimensional changes of soft tissue were evaluated using superimposition of digitalized study casts.

Results: Nineteen patients (23 implants) could be evaluated at six months and 13 patients (17 implants) at the end of the study 24 months. After 6-month follow-up there was a significant dimensional gain respect to baseline, averaging 0.83 ± 0.64 mm ($p < 0.01$). This did not change significantly at 24 months (0.77 ± 0.65 mm, $p = 0.19$). The gain was > 0.5 mm in 65.2% and 64.7% of the cases, respectively. Soft tissue shrinkage averaged $34.2\% \pm 77.0\%$ from T2 to T3 ($p < 0.01$) and did not change thereafter ($p = 0.39$). Shrinkage was more consistent in the posterior mandible than in the maxilla, but not significantly ($p = 0.23$ at 6-month and 0.36 at 24-month). No adverse events occurred.

Conclusions: Within the limitations of this prospective case series, the use of a porcine dermal matrix may provide consistent soft tissue augmentation that maintains up to 24-month follow-up, though graft shrinkage may occur in the first 6 months, depending on the location of surgery.

Keywords: gingival thickness, acellular dermal matrix, second stage surgery, dental implant, soft tissue augmentation

Introduction

Dental implants show high survival and success rates on the implant level in fully and partially edentulous patients.¹⁻³ Osseointegration and peri-implant soft tissue stability are important factors to achieve predictable long-term outcomes. The amount of soft tissue volume may improve the aesthetics and partially compensate for missing bone on the buccal aspect of dental implants.⁴⁻⁵

Soft tissue augmentation surgery can be performed at different stages of the implant therapy.⁵⁻¹¹ In general, the use of subepithelial connective tissue grafts (SCTG) harvested from the palate is considered the gold standard for soft tissue augmentation around dental implants.¹²⁻¹⁴ However, the harvesting procedure with the second surgical site increases treatment time and patient morbidity. Therefore, current research focuses on alternative techniques and materials. A porcine acellular dermal collagen matrix has been introduced as an alternative to SCTGs in order to avoid surgical risks and to decrease patient morbidity.¹⁵⁻¹⁹ These matrices proved their ability to increase soft tissue thickness in preclinical animal studies.²⁰⁻²² In a comparative dog study a porcine collagen matrix has shown similar results as SCTG after a 10-month follow-up.²¹ Preclinical studies suggested that acellular dermal matrices may represent a suitable scaffold for three-dimensional soft tissue thickening, showing good biocompatibility and appropriate biodegrading features.²³ Collagen-based dermal matrices have shown good clinical integration in plastic periodontal surgery^{24,25} and implant surgery.^{26,27} Linkevicius et al. showed in a clinical study that mucosa thickness can be increased predictably with an acellular dermal matrix of allogenic origin in the molar region.²⁸

Today, the use of collagen matrices as an alternative to SCTGs for the correction of localized ridge defects around dental implants cannot be recommended clinically, due to insufficient evidence regarding the effectiveness of the method in providing suitable three-dimensional tissue dimension and long-term stability.^{5,12}

The aim of the present multicenter study was to test the effectiveness of a porcine acellular dermal matrix, applied at the time of second stage surgery, in providing adequate soft tissue augmentation at the buccal aspect, up to 24-month follow-up. The working hypothesis was that using a porcine acellular dermal matrix buccally positioned, soft tissue volume can be increased predictably, achieving and maintaining a horizontal gain of at least 0.5 mm.

Materials and Methods

Study design

The Witten/Herdecke University's Ethical Committee of the Medical Faculty approved the consent form and study protocol (18/2015). Subjects were enrolled treated at four different University-clinical centres between May and November 2015. Three clinics were located in Germany (Witten/Herdecke University (K.F.), Private practice in München (H.W.)München, Private practice in Münster (A.H.) & Witten), Germany; and one in Italy (Private practice in Como (T.T.)Milan, Italy). In total, four surgeons (one per each centre) performed the interventions. All of them were highly skilled and equally trained, with more than 10 years of experience in implant dentistry and tissue augmentation procedures. Specific clinical procedures and instructions for handling of all materials used in this study were thoroughly reviewed in a preliminary meeting in the presence of the four surgeons. The study started only when all surgeons declared they were comfortable with the operative procedures of the surgical and prosthetic protocol.

between May and November 2015. Within this prospective case series, 20 patients (5 patients per center) in need of minor soft tissue volume augmentation during second stage surgery were to be enrolled after thorough explanation of the study and after signing informed consent. The following inclusion and exclusion criteria were applied:

Inclusion Criteria:

- (1) partially edentulous patients scheduled for fixed implant-supported rehabilitation;
- (2) implant treatment was performed with a two-piece implant system (bone-level implant);
- (3) implants underwent submerged healing;
- (4) minor localized buccal ridge contour deficiency (less than 1 mm defect, clinically estimated), with no exposure of the implant surface.

Exclusion Criteria:

- (1) uncontrolled diabetes mellitus (HbA1c > 6.5%);
- (2) pregnant or lactating women;
- (3) infectious diseases (AIDS, Hepatitis B, C);

- (4) moderate or heavy smoking (> 10 cigarettes per day);
- (5) untreated periodontitis;
- (6) implants planned for a removable denture;
- (7) immediate implants in fresh postextraction sockets.

Surgical Intervention (uncovering-second stage)

Anaesthesia was induced with 4% articaine chlorhydrate and epinephrine (1:100,000). After a crestal incision above the implant, a split-thickness flap was prepared to create a buccal pouch. A rehydrated, 2-mm thick acellular porcine dermal matrix (APDM; OsteoBiol® Derma Standard, Tecnos®[®], Giaveno, Italy) was placed into the recipient site as reported in an earlier study.²⁹ Thereafter, a healing cap replaced the implant cover screw and the flap was readapted to fully cover the transplant using microsurgical sutures (6-0 Seralene, Serag Wiessner, Naila, Germany). In Fig.1 are shown pre-surgical, as well as intra-surgical images of one case, to illustrate positioning of the matrix.

Each patient was instructed not to brush in the surgical area for 14 days and to rinse with 0.2% chlorhexidine digluconate three times per day. Furthermore, each patient was prescribed 600mg ibuprofen, to be taken as required.

Clinical measurements:

Silicone impressions of the whole jaw (Impregum, 3M Espe, Neuss, Germany) were taken directly before surgery (T0), at suture removal (14 days post-surgery; T2), after 6 (T3) and 24 months (T4) of follow-up. At the end of surgery (T1) only clinical pictures were taken. The fixed prosthetic restoration was delivered 14 days after T2. There was no standardization regarding the prosthetic protocol: each center was free to choose the most appropriate fixed prosthetic restoration for each patient. In order to measure tissue contour changes, master casts were fabricated from dental stone casts (GC Fujirock type 4, GC Corp., Tokyo, Japan) using the pre-surgery and follow-up impressions. The casts were then optically scanned with a CEREC scan utility (inEosX5, Sirona Dental Systems, Bensheim, Germany) resulting in digital STL files (Standard Tessellation Language). All study centers sent their impressions to Witten/Herdecke University, where all the scans were performed. One single expert evaluator (S.M.), unaware of the type of surgery performed, undertook all measurements.

Dimensional analysis

The obtained digital images of the casts reflecting the different treatment time points (pre-surgery, 14 days post-surgically, 6 and 24 months post-surgically) were then transferred into another digital imaging software (Swissmeda/SMOP, Zürich, Switzerland). This software allowed the superimposition and matching of the different digital models. The best-fit algorithm was used to superimpose the digital surface models based on unchanged tooth structures as reference.

The area of interest at the buccal aspect of the study-specific implant was defined according to the technique published in previous studies.³⁰⁻³² The mesial and distal papillary midline, the mucogingival line, and the crown margin served as anatomical reference structures. If necessary, the coronal area of interest was shifted 1-2 mm more apical to avoid non-readable measurements because of invalid superimposition. Consequently, in each patient the area of interest was of different size. To allow for a direct comparison between patients, the mean dimensional change per area was calculated, resulting in a linear buccal distance. Therefore, the study sites could be compared irrespective of their size and the size of the area of interest. Before the dimensional analysis, a calibration session was conducted to ensure reproducibility.

Outcome measures

Primary outcomes: 1. Horizontal ridge augmentation. It was considered successful when augmentation was greater than 0.5 mm in the horizontal dimension, respect to baseline (T0). Such value was arbitrarily taken, based on previous similar studies, that showed a considerable shrinking after initial augmentation.^{20,31} In the present study a net horizontal gain of 0.5 mm was considered clinically relevant.

2. Graft horizontal shrinkage after six (T3) and 24 months (T4) of healing, as compared to the 2-week dimension (T2).

Secondary outcomes: Incidence of adverse events following the surgical interventions defined as flap dehiscence, graft exfoliation or allergic reactions.

Statistical analysis:

Descriptive statistics such as mean values, standard deviations, median and percentiles were calculated using the software SPSS Statistics 22 (IBM, Ehningen, Germany). The normality of the distributions was assessed by means of the D'Agostino and Pearson omnibus normality test. The differences in horizontal soft tissue gain between T2, T3 and T4, as well as in shrinkage at T3 and T4, was

1
2
3 assessed by means of Wilcoxon matched-pairs signed rank test. The difference in
4 soft tissue shrinkage between regions (posterior maxilla vs posterior mandible) was
5 assessed using the Mann Whitney test. The single case was considered as the unit
6 of analysis. A p-value <0.05 was considered as statistically significant.
7
8
9

10 11 **Results**

12 *Participant Flow*

13 ~~Subjects were enrolled at four different University clinical centres (München, Münster~~
14 ~~& Witten, Germany; Milan, Italy) between May and November 2015.~~ In total, 20
15 healthy patients were screened for eligibility, ~~and~~ gave their informed consent for
16 participation in this study ~~and were recruited~~. Each centre contributed with five
17 patients. ~~One participant was not available at T3 and other 6 participants were not~~
18 ~~available at T4 hence, they were excluded from the data analysis.~~

19 All patients were of Caucasian ethnicity (10 female and 10 male), with an age
20 ranging from 33 to 66 years (average: 50.3±11.9 (standard deviation, SD)). All
21 participants were systemically and periodontally healthy and two were minor smokers
22 (<10 cigarettes per day). Soft tissue augmentation was performed at 24 implants (11
23 in the mandible and 13 in the maxilla), ~~Twenty-four augmentations were performed~~
24 but not all of them could be followed throughout the study.

25 *Suture removal (T2).*

26 One patient (one implant) refused to continue the study and was considered drop-
27 out. In the remaining 19 patients, in four implants out of 23 (all in the posterior
28 maxilla), the horizontal soft tissue gain at T2 could not be estimated due to
29 inappropriate overlapping of the digital scan at T2 with the reference scan at T1. So,
30 19 paired observations were available for statistical comparisons between different
31 time frames at T2 (2 weeks).

32 *Six-month follow-up (T3)*

33 One participant was not available at T3. (6-month follow-up) Nineteen subjects with a
34 total of 23 implants were evaluated at the 6-month follow-up. The majority of implants
35 (21/23) were located at premolar and molar level. Comparison with T1 was possible
36 for all 23 cases.

37 *Twenty-four-month follow-up*

38 ~~and other 6~~ Six more participants (six implants) were not available at T4 (24-month
39 follow-up). ~~hence, All of them~~ They were considered lost to follow-up and they were
40
41
42
43
44
45
46
47
48
49
50
51
52
53
54
55
56
57
58
59
60

~~excluded from the final data analysis. Nineteen subjects with a total of 23 implants were evaluated at the 6-month follow-up and Hence, 13 patients (17 implants) were evaluated at 24 months. The majority of implants (21/23 at 6 months and 15/17 at 24 months) were located at premolar and molar level. Horizontal gain respect to T1 could be correctly estimated at T4 in all 17 cases, but shrinkage could be calculated only for 14 cases matching with T2 measurements (5 in the mandible and 9 in the maxilla).~~

A clinical case is shown in Fig. 2a-d. Occlusal pictures of T0, T1, T2 and T3 are shown. The digital analysis of the same case, followed up to 24 months, is shown in Fig. 3.

~~In four cases out of 23 (all in the posterior maxilla), the horizontal soft tissue gain at T2 could not be estimated due to inappropriate overlapping of the digital scan at T2 with the reference scan at T1. So, 19 paired observations were available for statistical comparisons between different time frames at T2 (26 monthsweeks). Conversely, horizontal gain could be correctly estimated at T4 in all 17 cases, but shrinkage could be calculated only for 14 cases matching with T2 measurements (5 in the mandible and 9 in the maxilla).~~

Primary Outcomes

Soft tissue gain after 2 weeks was 1.57 ± 0.76 mm (median 1.53, 95% CI (confidence intervals): 1.20, 1.93 mm), though a reduction was expected in the first months. Six months after soft tissue augmentation, the mean change in horizontal dimension respect to T1 was $+0.83 \pm 0.64$ mm (median 0.62, 95% CI: 0.56, 1.11 mm) ($p < 0.01$). Fifteen out of 23 implants (65.2%) achieved a clinically relevant horizontal gain of >0.5 mm. In 5 cases (21.7%) the horizontal gain was >1 mm. The highest chance for success was observed in the upper posterior jaw (82%; 9 of 11), while in the other regions it was 50%. At 24-month follow-up, the horizontal gain averaged 0.77 ± 0.65 mm (median 0.61, 95% CI: 0.44, 1.11 mm), being not significantly different from T3 ($p = 0.19$). The gain was >0.5 mm in 64.7% of the cases (in 5 cases (29.4%) it was >1 mm). Figure 4 is a box-and-whiskers plot showing the horizontal gain at T2, T3 and T4. As the data did not follow a Gaussian distribution, non-parametric tests were used for comparisons.

The mean overall horizontal shrinkage of soft tissue observed at T3 and T4, compared to the data evaluated at T2, was $34.2\% \pm 77.0\%$ (median 67%, 95% CI: -3.1, 71.5%) ($p < 0.01$) and $19.9\% \pm 96.1\%$ (median 65.3, 95% CI: -31.2, 71.1%),

1
2
3 respectively. There was no significant difference in shrinkage between T3 and T4
4 (p=0.39), suggesting a fair volume maintenance from 6 to 24 months. The standard
5 deviation is rather high, as in some cases a further expansion instead of a shrinkage,
6 was observed. Figure 5 compares the shrinkage observed in the posterior maxilla vs
7 posterior mandible. The difference in shrinkage between the two posterior regions
8 was not statistically significant (p=0.23 and p=0.36 at 6 and 24 months, respectively).
9 The two cases located in the anterior region of the maxilla (both were lateral incisors)
10 were excluded from such comparison. Such cases showed a rather high shrinkage at
11 T3, equal to 74% and 66.5%. Such values remained essentially unchanged at T4.

12 13 14 15 16 17 18 *Secondary Outcomes*

19 No adverse event such as dehiscence, post-measurement infection or bleeding was
20 recorded at any time.
21
22
23
24

25 26 **Discussion**

27 In the present prospective multi-center case series, we aimed to assess 1) the
28 possibility to augment the horizontal ridge dimension by using an APDM during
29 second stage implant surgery and 2) how much graft shrinkage needs to be expected
30 6-month post-surgery.
31
32

33 -The main limitation of this study could be considered the absence of a control group.

34 The latter, with just repositioning of the flap, could certainly have added value to this
35 study, and possibly confirm that the observed results were dependent on the
36 application of APDM. Ideally, each test site should have a matched control, with
37 similar anatomical and morphological features, which may not be as easy to find.
38
39

40 Furthermore, the sample size is limited, especially if comparisons between different
41 jaw regions (requiring data split into subgroups) are to be made. Also, though a
42 multicenter study design may allow to recruit a larger number of patients in a
43 relatively short time, one has to consider possible differences in patient management
44 and prosthetic protocols among different centrescenters. Given the similar
45 experienceetise of the surgeons, and their specific training on the procedures used in
46 this study, it was assumed that there was no relevant inter-operator difference. This
47 implies a rather poor standardization among cases. Finally, no specific clinical
48 parameters like plaque index, soft tissue bleeding or inflammation, that might play a
49 role in affecting tissue volume, were not systematically measured in the different
50 centrescenters. So, this may be considered a pilot study, whose results need to be
51
52
53
54
55
56
57
58
59
60

1
2
3 ~~confirmed by further prospective studies.~~ Within the limitations of this case series, it
4
5 seems to be possible to predictably gain at least 0.5 mm of soft tissue in the
6
7 horizontal dimension applying an APDM during second stage surgery, especially in
8
9 the posterior maxilla, where in a few cases even more than 2 mm augmentation were
10
11 observed at 6 months. Defects in the mandible, anterior sites and free-end situations
12
13 seem to be less favorable. We underline that the flap at second stage was not
14
15 buccally repositioned but it was only closely adapted to the healing abutment, and
16
17 the observed increase in thickness was likely only due to the porcine dermal matrix.

17
18 When using this technique, "graft" shrinkage of around 30-40% may occur after 6
19
20 months, depending on the location of surgery. The quite variable shrinkage observed
21
22 (Fig. 4), and the fact that in some cases an expansion occurred between T2 and T3
23
24 deserves further studies with larger sample size to investigate the factors that may
25
26 affect augmentation prognosis. So Therefore, this may be considered a pilot study,
27
28 whose results need to be confirmed by further prospective studies.

27
28 Mucosal thickness is an important factor regarding esthetics and long-term tissue
29
30 stability. The difference in light reflection (translucency) of soft tissue covering
31
32 titanium or zirconia abutments is no longer noticeable for the human eye when the
33
34 mucosa thickness exceeds 2 mm.³²

34
35 Multiple pre-clinical investigations regarding the effectiveness and safety of different
36
37 soft tissue substitutes have been published, focusing on graft integration and
38
39 dimensional changes.^{20,27,30-33} One of the major concern of such studies was to
40
41 determine to what extent xenograft collagen matrices would be resorbed by the host,
42
43 namely the soft tissue gain stability along time. One animal study showed that the
44
45 gain in volume is rather stable after a few months.²² The authors concluded that in
46
47 spite of the degradation of the xenograft, which leads to a significant amount of
48
49 volume loss, part of the collagen matrix may remain, or being replaced by newly
50
51 formed connective tissue.²²

50
51 In a split-mouth study, Fickl et al. compared SCTG and APDM for the treatment of
52
53 buccal dehiscence defects at upper canines in five dogs.³⁴ After 4-month follow-up,
54
55 they found no statistical significant difference neither in soft tissue height nor
56
57 thickness and, thereby, concluded that the applied APDM might be a valid alternative
58
59 to autologous grafts. Schmitt et al. used a similar pre-clinical model applying another
60
61 type of APDM.²¹ The mean horizontal gain was 0.65 mm for SCTG and 0.96 mm for
62
63 APDM directly after surgery, however, after 10 months, only 0.13 mm for SCTG and

1
2
3 0.01 mm for residual APDM, showing a net tissue loss. In 2010, Thoma et al.
4 evaluated a porous collagen matrix (CM) for volumetric augmentation in chronic ridge
5 defects in dogs.²² While they used a 5 mm thick CM folded twice, they gained 1.4
6 mm in thickness after 84 days. They found similar results for SCTG folded twice – 5
7 mm thick before removal of epithelium remnants, fatty & glandular tissue - and CM
8 after 28 and 84 days. However, they did not report on the volumetric gain directly
9 after surgery, which would have been interesting to evaluate graft shrinkage. More
10 recently, the same group used a similar cross-linked, porous CM for soft tissue
11 augmentation after bone grafting using guided-bone-regeneration.³⁵ While the
12 achieved dimensional gain was stable for the first two months, a significant loss was
13 observed in the following four months. Only a minimal gain of 0.55 mm for the SCTG
14 and 0.23 mm for CM was noted in the most coronal aspect compared to 2.5 mm
15 (SCTG) and 2.1 mm (CM) after 1 month, while around 50% of the tissue gain (SCTG:
16 0.64 mm, CM: 0.68 mm; $p = 0.98$) was maintained at the level of implant shoulder.
17 The observed dimensional gain in our study population using a 2-mm thick and rather
18 dense APDM might be comparable to the above reported results using a thicker,
19 porous CM. It remains unclear whether a more porous – and maybe more prone to
20 compression - or a denser structure of soft tissue substitutes is more favorable
21 regarding long-term stability.

22
23
24 Clinically, Puisys & Linkevicius showed that mucosal thickness around dental
25 implants can be successfully increased with an ADM of allogenic origin with
26 concomitant reduction of bone loss compared to untreated cases with thin
27 tissues.^{36,37} Allogenic ADM was also used to correct horizontal ridge defects before
28 prosthetic rehabilitation.³⁸ About 40% horizontal volume loss was observed, with the
29 highest change occurring within the first 3 months. It was concluded that allogenic
30 ADM may be a suitable material for the treatment of soft tissue ridge deformities due
31 to its biocompatibility, color matching and horizontal gain. However, only in few cases
32 was the desired tissue gain achieved.³⁸ De Bruyckere et al. used SCTG to correct
33 horizontal alveolar defects around single implants in the anterior maxilla.³⁹ Horizontal
34 tissue thickness gain averaged 0.97, mm equivalent to 90.5% of the gain observed
35 immediately after SCTG placement. This represents one of the lowest reported tissue
36 loss after soft tissue augmentation. In that study, however, all implants had been
37 restored with screw-retained provisional, as opposed to our cases and the majority of
38 reports in literature.

1
2
3 As previously said, the major limitation of the present clinical study is the lack of a
4 control group. SCTG is still seen as the gold-standard and could have been served
5 as a control, however, it is complicated to standardize graft thickness and
6 composition (connective vs. fatty/glandular tissue), especially in a multi-center study.
7 Also, as SCTG is an operator-sensitive technique, the variability introduced by the
8 different operators involved should have been taken into account.
9

10 The present preliminary data confirmed that using acellular porcine dermal matrix, a
11 soft tissue augmentation greater than 0.5mm may be achieved after 6 months of
12 follow-up, and maintained up to 2 years, in two-thirds of cases. Future studies should
13 aim at providing clear indication of possible achievements and limitations of
14 substitutes used for soft tissue augmentation in the clinical practice. These studies
15 should focus on the comparison of collagen matrices with different features (e.g.
16 xenogenic versus allogenic origin, or dense versus porous structure), in order to give
17 recommendations for the proper indication and use of these materials as a feasible
18 alternative to autologous grafts. Standardized research protocols should be
19 established to allow comparison of different studies.
20
21
22
23
24
25
26
27
28
29
30
31
32
33
34
35
36
37
38
39
40
41
42
43
44
45
46
47
48
49
50
51
52
53
54
55
56
57
58
59
60

References

1. Gallucci GO, Morton D, Weber HP. Loading protocols for dental implants in edentulous patients. *Int J Oral Maxillofac Implants* 2009;24 (Suppl):132-146.
2. Jung RE, Zembic A, Pjetursson BE, Zwahlen M, Thoma DS. Systematic review of the survival rate and the incidence of biological, technical, and aesthetic complications of single crowns on implants reported in longitudinal studies with a mean follow-up of 5 years. *Clin Oral Implants Res* 2012; 23 (Suppl 6):2-21.
3. Pjetursson BE, Thoma D, Jung R, Zwahlen M, Zembic A. A systematic review of the survival and complication rates of implant-supported fixed dental prostheses (FDPs) after a mean observation period of at least 5 years. *Clin Oral Implants Res* 2012; 23 (Suppl 6):22-38.
4. Benic GI, Mokti M, Chen CJ, Weber HP, Hämmerle CH, Gallucci GO. Dimensions of buccal bone and mucosa at immediately placed implants after 7 years: a clinical and cone beam computed tomography study. *Clin Oral Implants Res* 2012;23:560-566.
5. Thoma DS, Buranawat B, Hammerle CH, Held U, Jung RE. Efficacy of soft tissue augmentation around dental implants and in partially edentulous areas: a systematic review. *J Clin Periodontol* 2014;41 (Suppl 15):S77-91.
6. Studer S, Naef R, Scharer P. Adjustment of localized alveolar ridge defects by soft tissue transplantation to improve mucogingival esthetics: a proposal for clinical classification and an evaluation of procedures. *Quintessence Int* 1997;28:785-805.
7. Studer SP, Lehner C, Bucher A, Scharer P. Soft tissue correction of a single-tooth pontic space: a comparative quantitative volume assessment. *J Prosthet Dent* 2000;83:402-411.
8. Schneider D, Grunder U, Ender A, Hammerle CH, Jung RE. Volume gain and stability of peri-implant tissue following bone and soft tissue augmentation: 1-year results from a prospective cohort study. *Clin Oral Implants Res* 2011;22:28-37.
9. Grunder U. Crestal ridge width changes when placing implants at the time of tooth extraction with and without soft tissue augmentation after a healing

- 1
2
3 period of 6 months: report of 24 consecutive cases. *Int J Periodontics*
4 *Restorative Dent* 2011;31:9-17.
5
6
7 10. Tsuda H, Rungcharassaeng K, Kan JY, Roe P, Lozada JL, Zimmerman G.
8 Peri-implant Tissue Response Following Connective Tissue and Bone Grafting
9 in Conjunction with Immediate Single-Tooth Replacement in the Esthetic
10 Zone: A Case Series. *Int J Oral Maxillofac Implants* 2011;26:427-436.
11
12
13 11. Akcali A, Schneider D, Unlu F, Bicakci N, Kose T, Hammerle CH. Soft tissue
14 augmentation of ridge defects in the maxillary anterior area using two different
15 methods: a randomized controlled clinical trial. *Clin Oral Implants Res*
16 2015;26:688-695.
17
18
19 12. Thoma DS, Benic GI, Zwahlen M, Hammerle CH, Jung RE. A systematic
20 review assessing soft tissue augmentation techniques. *Clin Oral Implants Res*
21 2009;20 (Suppl 4):146-165.
22
23
24 13. Zuhr O, Baumer D, Hurzeler M. The addition of soft tissue replacement grafts
25 in plastic periodontal and implant surgery: critical elements in design and
26 execution. *J Clin Periodontol* 2014;41 (Suppl 15):S123-142.
27
28
29 14. Sanz M, Simion M, Working Group 3 of the European Workshop on
30 Periodontology. Surgical techniques on periodontal plastic surgery and soft
31 tissue regeneration: consensus report of Group 3 of the 10th European
32 Workshop on Periodontology. *J Clin Periodontol* 2014;41 (Suppl 15):S92-97.
33
34
35 15. Pabst AM, Happe A, Callaway A, et al. In vitro and in vivo characterization of
36 porcine acellular dermal matrix for gingival augmentation procedures. *J*
37 *Periodontal Res* 2014;49:371-381.
38
39
40 16. Sanz M, Lorenzo R, Aranda JJ, Martin C, Orsini M. Clinical evaluation of a
41 new collagen matrix (Mucograft prototype) to enhance the width of keratinized
42 tissue in patients with fixed prosthetic restorations: a randomized prospective
43 clinical trial. *J Clin Periodontol* 2009;36:868-876.
44
45
46 17. Ghanaati S, Schlee M, Webber MJ, et al. Evaluation of the tissue reaction to a
47 new bilayered collagen matrix in vivo and its translation to the clinic. *Biomed*
48 *Mater* 2011;6:015010. doi: 10.1088/1748-6041/6/1/015010.
49
50
51 18. Schmitt CM, Tudor C, Kiener K, et al. Vestibuloplasty: porcine collagen matrix
52 versus free gingival graft: a clinical and histologic study. *J Periodontol*
53 2013;84:914-923.
54
55
56
57
58
59
60

- 1
2
3 19. Nocini PF, Castellani R, Zanotti G, et al. Extensive keratinized tissue
4 augmentation during implant rehabilitation after Le Fort I osteotomy: using a
5 new porcine collagen membrane (Mucoderm). *J Craniofac Surg* 2014;25:799-
6 803.
7
8
- 9
10 20. Thoma DS, Naenni N, Benic GI, Hammerle CH, Jung RE. Soft tissue volume
11 augmentation at dental implant sites using a volume stable three-dimensional
12 collagen matrix - histological outcomes of a preclinical study. *J Clin*
13 *Periodontol* 2017; 44:185-194.
14
15
- 16 21. Schmitt CM, Matta RE, Moest T, et al. Soft tissue volume alterations after
17 connective tissue grafting at teeth: the subepithelial autologous connective
18 tissue graft versus a porcine collagen matrix - a pre-clinical volumetric
19 analysis. *J Clin Periodontol* 2016;43:609-617.
20
21
- 22 22. Thoma DS, Jung RE, Schneider D, et al. Soft tissue volume augmentation by
23 the use of collagen-based matrices: a volumetric analysis. *J Clin Periodontol*
24 2010;37:659-666.
25
26
- 27 23. Guo J, Chen H, Wang Y, Cao C-B, Guan G-Q. A novel porcine acellular
28 dermal matrix scaffold used in periodontal regeneration. *Int J Dent Sci*
29 2013;5:37-43.
30
31
- 32 24. Fickl S, Nannmark U, Schlagenhaut U, Hurzeler MB, Kerschull M. Porcine
33 dermal matrix in the treatment of dehiscence-type defects--an experimental
34 split-mouth animal trial. *Clin Oral Implants Res* 2015;26:799-805.
35
36
- 37 25. Fickl S, Jockel-Schneider Y, Lincke T, Bechtold M, Fischer KR, Schlagenhaut
38 U. Porcine dermal matrix for covering of recession type defects: a case series.
39 *Quintessence Int* 2013;44:243-246.
40
41
- 42 26. Zafiroopoulos GG, Deli G, Hoffmann O, John G. Changes of the peri-implant
43 soft tissue thickness after grafting with a collagen matrix. *J Indian Soc*
44 *Periodontol* 2016;20:441-445.
45
46
- 47 27. Bassetti RG, Stahli A, Bassetti MA, Sculean A. Soft tissue augmentation
48 around osseointegrated and uncovered dental implants: a systematic review.
49 *Clin Oral Invest* 2017;21:53-70.
50
51
- 52 28. Linkevicius T, Puisys A, Linkeviciene L, Peciuliene V, Schlee M. Crestal bone
53 stability around implants with horizontally matching connection after soft tissue
54 thickening: A prospective clinical trial. *Clin Implant Dent Relat Res*
55 2015;17:497-508.
56
57
58
59
60

- 1
2
3 29. Fischer KR, Fickl S, Mardas N, Bozec L, Donos N. Stage-two surgery using
4 collagen soft tissue grafts: Clinical cases and ultrastructural analysis.
5 Quintessence Int 2014;45:853-860.
6
7
- 8 30. Windisch SI, Jung RE, Sailer I, Studer SP, Ender A, Hammerle CH. A new
9 optical method to evaluate three-dimensional volume changes of alveolar
10 contours: a methodological in vitro study. Clin Oral Implants Res 2007;18:545-
11 551.
12
13
- 14 31. Fickl S, Schneider D, Zuhr O, et al. Dimensional changes of the ridge contour
15 after socket preservation and buccal overbuilding: an animal study. J Clin
16 Periodontol 2009;36:442-448.
17
18
- 19 32. Schneider D, Grunder U, Ender A, Hammerle CH, Jung RE. Volume gain and
20 stability of peri-implant tissue following bone and soft tissue augmentation: 1-
21 year results from a prospective cohort study. Clin Oral Implants Res
22 2011;22:28-37.
23
24
- 25 33. van Brakel R, Noordmans HJ, Frenken J, de Roode R, de Wit GC, Cune MS.
26 The effect of zirconia and titanium implant abutments on light reflection of the
27 supporting soft tissues. Clin Oral Implants Res 2011;22:1172-1178.
28
29
- 30 34. Fickl S, Nannmark U, Schlagenhauf U, Hurzeler MB, Kerschull M. Porcine
31 dermal matrix in the treatment of dehiscence-type defects - an experimental
32 split-mouth animal trial. Clin Oral Implants Res 2015;26:799-805.
33
34
- 35 35. Thoma DS, Naenni N, Benic GI, Hammerle CH, Jung RE. Soft tissue volume
36 augmentation at dental implant sites using a volume stable three-dimensional
37 collagen matrix - histological outcomes of a preclinical study. J Clin
38 Periodontol 2017;44:185-194.
39
40
- 41 36. Puisys A, Linkevicius T. The influence of mucosal tissue thickening on crestal
42 bone stability around bone-level implants. A prospective controlled clinical
43 trial. Clin Oral Implants Res 2015;26:123-129.
44
45
- 46 37. Puisys A, Vindasiute E, Linkeviciene L, Linkevicius T. The use of acellular
47 dermal matrix membrane for vertical soft tissue augmentation during
48 submerged implant placement: a case series. Clin Oral Implants Res
49 2015;26:465-470.
50
51
- 52 38. Batista EL, Jr., Batista FC, Novaes AB, Jr. Management of soft tissue ridge
53 deformities with acellular dermal matrix. Clinical approach and outcome after 6
54 months of treatment. J Periodontol 2001;72:265-273.
55
56
57
58
59
60

- 1
2
3 39. De Bruyckere T, Eghbali A, Younes F, De Bruyn H, Cosyn J. Horizontal
4 stability of connective tissue grafts at the buccal aspect of single implants: a 1-
5 year prospective case series. J Clin Periodontol 2015;42:876-882.
6
7
8
9
10
11
12
13
14
15
16
17
18
19
20
21
22
23
24
25
26
27
28
29
30
31
32
33
34
35
36
37
38
39
40
41
42
43
44
45
46
47
48
49
50
51
52
53
54
55
56
57
58
59
60

For Review Only

Figure legends

Figure 1. a) atop left:- Clinical case of a female patient of 55 years, rehabilitated with an implant placed in the upper left lateral incisor site. Initial situation at uncovering (T0), with the implant placed in region 22 and the adhesive bridge, splinted to adjacent teeth; b) -

b)top right:- Horizontal defect soon before second stage surgery. The occlusal view showings insufficient contour profile, in need for augmentation;- ~~Horizontal defect before second stage surgery~~

c-) middle left: Augmentation of the soft tissue with dermal matrix;

d-) middle right: Occlusal view soon after suturing, at the end of surgery (T1);

e) bottom left:- Clinical situation 2 weeks post-surgery (T2);

f-) bottom right: Buccal view of the caseBuccal view of the case two years after surgery (T4). In spite of a light tissue shrinking, the patient expressed full satisfaction.

~~Clinical occlusal view of a 42-year old male patient, rehabilitated with an implant placed at upper left second premolar site. a) Pre-surgical clinical view, note the buccal contour invagination before 2nd stage surgery; b) acellular porcine dermal matrix (APDM) in place after split-flap preparation on the buccal aspect; c) Post-surgical view after flap closure, care was taken to completely cover the ADM; d) After 6 months, nearly complete maintenance of the augmented volume with healthy peri-implant tissues.~~

Figure 2. Clinical occlusal pictures of a male patient of 33 years, that was rehabilitated through a submerged implant placed in the upper right first premolar site. a) top panel, left: pre-surgical clinical view (T0), note the vestibular contour invagination before 2nd stage surgery; b) top, right: Post-surgical view after flap closure (T1), care was taken to completely cover the APDM; c) bottom panel, left: Primary soft tissue healing: note the relevant gain in vestibular contour volume 14 days after surgery (T2); d) bottom, right: After 6 months follow-up, nearly complete maintenance of the augmented volume with healthy peri-implant tissues is observed (T3).

Figure 3. Top images: digital reconstruction of casts of the clinical case shown in Fig. 1, taken at T0, T2, T3, T4. Bottom images: examples of analysis of the volume gain, obtained by overlapping two digital reconstructions. From left to right: T2-T0, T3-T0, T4-T0.

1
2
3
4
5 **Figure 4.** Whiskers box plots of the horizontal dimensional gain at 2 weeks (T2), 6
6 months (T3) and 24 months (T4) after soft tissue augmentation. Median values
7 (horizontal black lines) and mean values (crosses) are shown, with the 25th and 75th
8 percentiles outline by the box plot. Vertical lines with horizontal bars extend to the
9 95% confidence intervals (C.I.). Values outside 95% C.I. are shown (hollow circles).
10 The Wilcoxon matched-pairs signed rank test showed statistically significant
11 difference at T3 respect to T2 ($p=0.001$), while no significant difference was found
12 between T2 and T3 ($p=0.19$), indicating good maintenance.
13
14
15
16
17
18
19

20 **Figure 5.** Whiskers box plots of the soft tissue shrinkage between T2 (2 weeks post-
21 augmentation) and T3 (6-month follow-up), and between T2 and T4 (24-month
22 follow-up) in cases located in the posterior mandible ($n=5$) and in the posterior
23 maxilla ($n=9$). Negative values indicate expansion. Median values (horizontal black
24 lines) and mean values (crosses) are shown, with the 25th and 75th percentiles
25 outline by the box plot. Vertical lines with horizontal bars extend to the 95%
26 confidence intervals (C.I.). Values outside 95% C.I. are shown (hollow circles). The
27 Mann Whitney test showed non-significant difference in shrinkage between posterior
28 arches ($p=0.22$). Variability tended to increase with follow-up time.
29
30
31
32
33
34
35
36
37
38
39
40
41
42
43
44
45
46
47
48
49
50
51
52
53
54
55
56
57
58
59
60

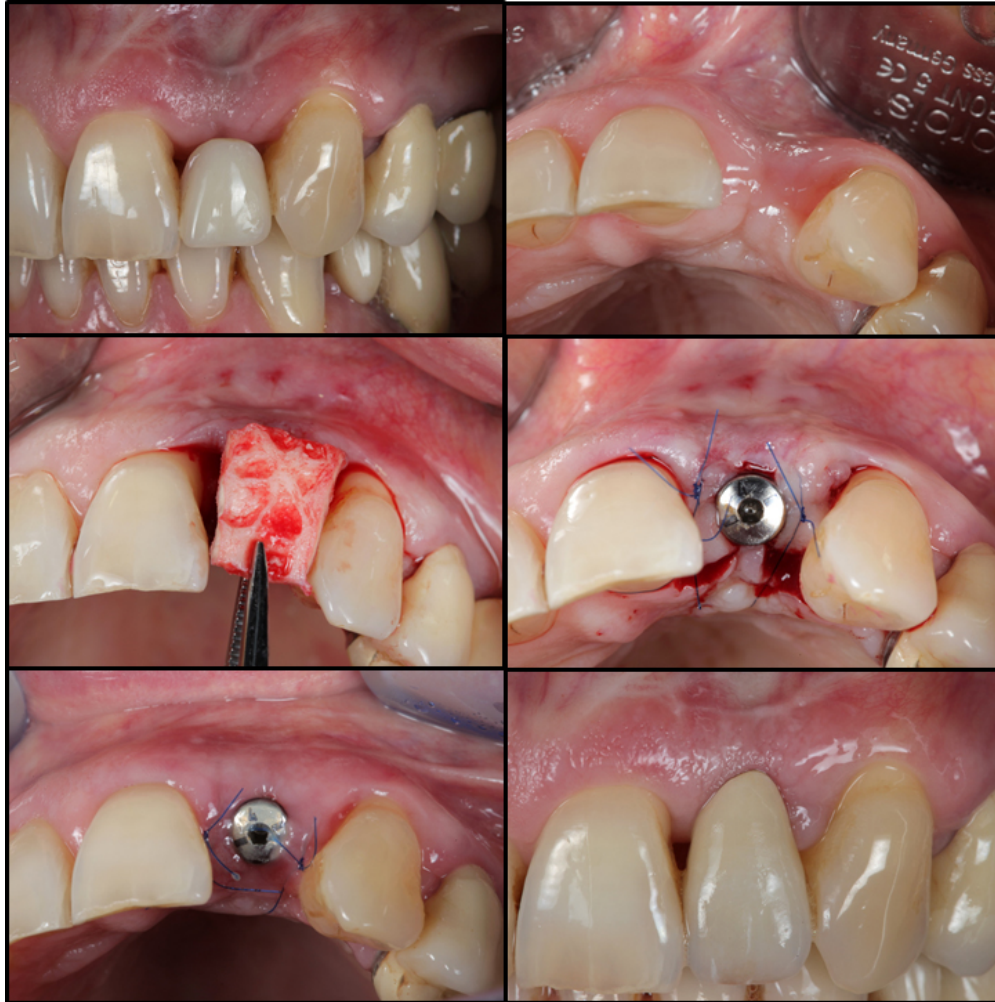

Figure 1. a) top left: Clinical case of a female patient of 55 years, rehabilitated with an implant placed in the upper left lateral incisor site. Initial situation at uncovering (T0), with the implant placed in region 22 and the adhesive bridge, splinted to adjacent teeth; b) top right: Horizontal defect soon before second stage surgery. The occlusal view shows insufficient contour profile, in need for augmentation; c) middle left: Augmentation of the soft tissue with dermal matrix; d) middle right: Occlusal view soon after suturing, at the end of surgery (T1); e) bottom left: Clinical situation 2 weeks post-surgery (T2); f) bottom right: Buccal view of the case two years after surgery (T4). In spite of a light tissue shrinking, the patient expressed full satisfaction.

61x61mm (300 x 300 DPI)

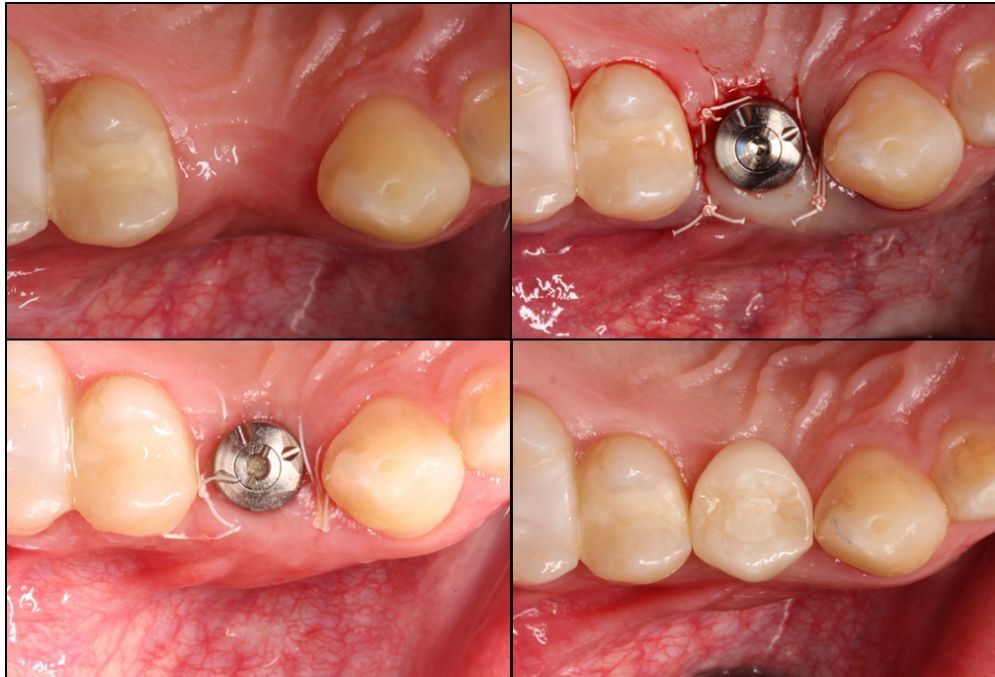

Figure 2. Clinical occlusal pictures of a male patient of 33 years, that was rehabilitated through a submerged implant placed in the upper right first premolar site. a) top panel, left: pre-surgical clinical view (T0), note the vestibular contour invagination before 2nd stage surgery; b) top, right: Post-surgical view after flap closure (T1), care was taken to completely cover the APDM; c) bottom panel, left: Primary soft tissue healing: note the relevant gain in vestibular contour volume 14 days after surgery (T2); d) bottom, right: After 6 months follow-up, nearly complete maintenance of the augmented volume with healthy peri-implant tissues is observed (T3).

85x57mm (300 x 300 DPI)

1
2
3
4
5
6
7
8
9
10
11
12
13
14
15
16
17
18
19
20
21
22
23
24
25
26
27
28
29
30
31
32
33
34
35
36
37
38
39
40
41
42
43
44
45
46
47
48
49
50
51
52
53
54
55
56
57
58
59
60

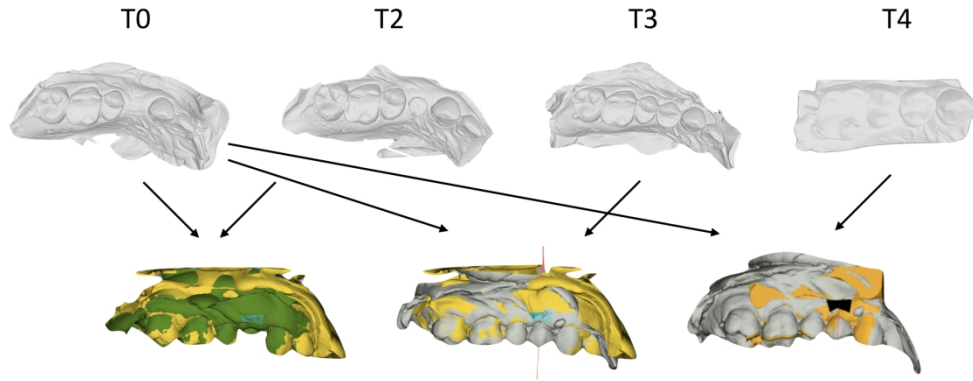


Figure 3. Top images: digital reconstruction of casts of the clinical case shown in Fig. 2, taken at T0, T2, T3, T4. Bottom images: examples of analysis of the volume gain, obtained by overlapping two digital reconstructions. From left to right: T2-T0, T3-T0, T4-T0.

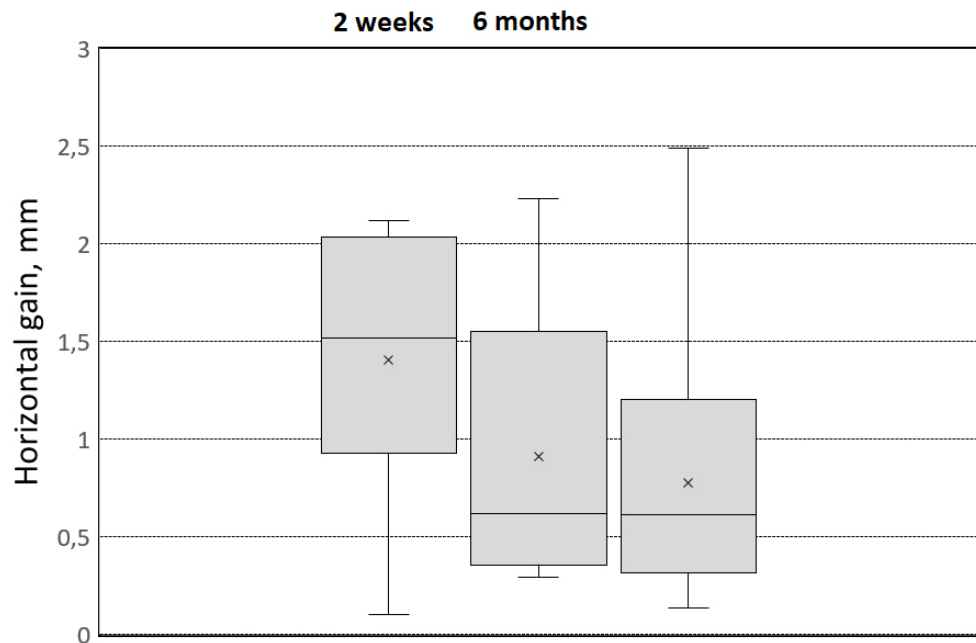


Figure 4. Whiskers box plots of the horizontal dimensional gain at 2 weeks (T2), 6 months (T3) and 24 months (T4) after soft tissue augmentation. Median values (horizontal black lines) and mean values (crosses) are shown, with the 25th and 75th percentiles outline by the box plot. Vertical lines with horizontal bars extend to the 95% confidence intervals (C.I.). Values outside 95% C.I. are shown (hollow circles). The Wilcoxon matched-pairs signed rank test showed statistically significant difference at T3 respect to T2 ($p=0.001$), while no significant difference was found between T2 and T3 ($p=0.19$), indicating good maintenance.

77x51mm (300 x 300 DPI)

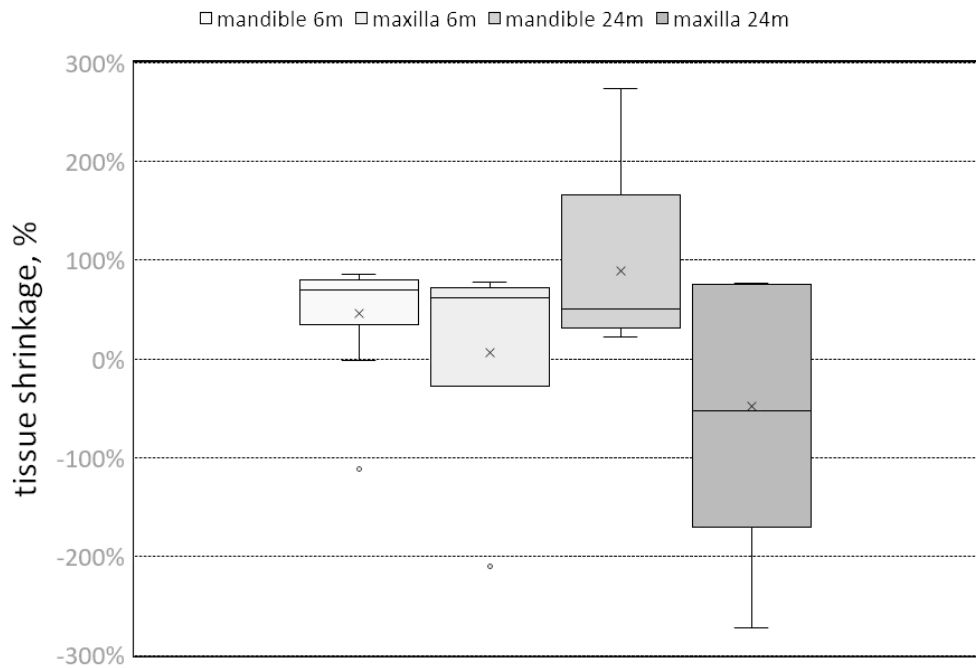


Figure 5. Whiskers box plots of the soft tissue shrinkage between T2 (2 weeks post-augmentation) and T3 (6-month follow-up), and between T2 and T4 (24-month follow-up) in cases located in the posterior mandible (n=5) and in the posterior maxilla (n=9). Negative values indicate expansion. Median values (horizontal black lines) and mean values (crosses) are shown, with the 25th and 75th percentiles outline by the box plot. Vertical lines with horizontal bars extend to the 95% confidence intervals (C.I.). Values outside 95% C.I. are shown (hollow circles). The Mann Whitney test showed non-significant difference in shrinkage between posterior arches (p=0.22). Variability tended to increase with follow-up time.

75x54mm (300 x 300 DPI)