

## Case Report

# Segmental testicular infarction: Case series and brief literature review of a great mime

Franco Palmisano<sup>1,2</sup>, Mariapia Serrago<sup>1</sup>, Andrea Gallioli<sup>1,2</sup>, Vito Lorusso<sup>1,2</sup>, Franco Gadda<sup>1</sup>, Matteo Giulio Spinelli<sup>1</sup>, Emanuele Montanari<sup>1,2</sup>

<sup>1</sup>Department of Urology, Foundation IRCCS Ca' Granda Ospedale Maggiore Policlinico, <sup>2</sup>University of Milan, Milan, Italy

### Abstract

Segmental testicular infarction is rare, and the etiology is mostly idiopathic. We report a case series of four young patients, one of them with metachronous bilateral disease, presenting with an acute scrotum and treated with a testis-sparing approach, if feasible, after a negative intraoperative biopsy. Etiology, differential diagnosis, and management are reviewed. To be aware of clinical and imaging features of this benign testicular pathology, it is crucial to avoid unnecessary orchiectomies to preserve vital testicular tissue left.

**Keywords:** Acute scrotum, testicular hemorrhage, testicular infarction, testicular pathologies, testis-sparing surgery

**Address for correspondence:** Dr. Franco Palmisano, Department of Urology, Foundation IRCCS Ca' Granda Ospedale Maggiore Policlinico, University of Milan, Via Della Commenda 15, 20122 Milan, Italy.  
E-mail: franco.palmisano@hotmail.it

**Received:** 10.09.2018, **Accepted:** 09.04.2019

### INTRODUCTION

Segmental testicular infarction (STI) is a rare event that has been associated with a wide range of pathologies, such as prothrombotic states or inflammatory local diseases like mistreated epididymitis. It may also result from complications related to inguinal or scrotal surgeries. However, up to 70% of reported cases are idiopathic.<sup>[1]</sup>

In addition, clinical manifestation of STI represents a great challenge for urologists miming testicular tumors, abscess, or torsion.

In this article, we report a series of four cases of STI diagnosed between 2016 and 2017 and treated in our institution, reviewing the diagnostic flowchart and tools currently utilized.

### CASE REPORTS

#### Case 1


A 28-year-old male was admitted to the emergency department (ED) for acute left testicular pain that had been gradually increasing for 3 days. Physical examination revealed a mildly swollen left testis that was painful on palpation, with no nodules being apparent. Biochemical tests showed no leukocytosis, and testicular markers were normal. Scrotal color Doppler ultrasound (SCDU) showed a hypoechoic and hyperemic area with faded outlines of 2.5 cm, located anteriorly, surrounded by poorly vascularized testicular parenchyma. At the posterior side of this area, there were two hypoechoic pseudonodular images of 3 and 13 mm [Figure 1].

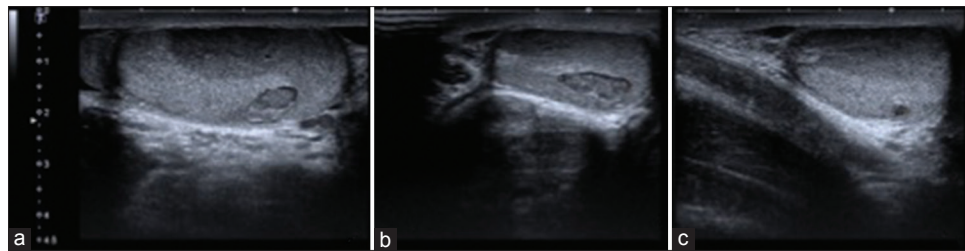
Since testicular torsion with a suspicious testicular neoplasm could not be excluded, an explorative inguinoscopy was

This is an open access journal, and articles are distributed under the terms of the Creative Commons Attribution-NonCommercial-ShareAlike 4.0 License, which allows others to remix, tweak, and build upon the work non-commercially, as long as appropriate credit is given and the new creations are licensed under the identical terms.

**For reprints contact:** reprints@medknow.com

**How to cite this article:** Palmisano F, Serrago M, Gallioli A, Lorusso V, Gadda F, Spinelli MG, *et al.* Segmental testicular infarction: Case series and brief literature review of a great mime. *Urol Ann* 2019;11:334-7.

Access this article online	
<b>Quick Response Code:</b> 	<b>Website:</b> <a href="http://www.urologyannals.com">www.urologyannals.com</a>
	<b>DOI:</b> 10.4103/UA.UA_125_18



**Figure 1:** Left testicle ultrasound showing regular thickness of the scrotal sheaths while the testis, of regular size, has a hyperemic and hypogenous area with faded outlines of diameters of about 2.5 cm × 1 cm surrounded by a testicular parenchyma of increased and scarcely vascularized echogenicity (a), in the context of which, posteriorly, are present two hypoechoic focal points with pseudonodular aspects, with diameters of 3 and 13 mm, respectively (b and c). Moreover, slight signs of hyperemia of the tail of the epididymis with a moderate corpuscular hydrocele and ectasia of the spermatic plexus are observable

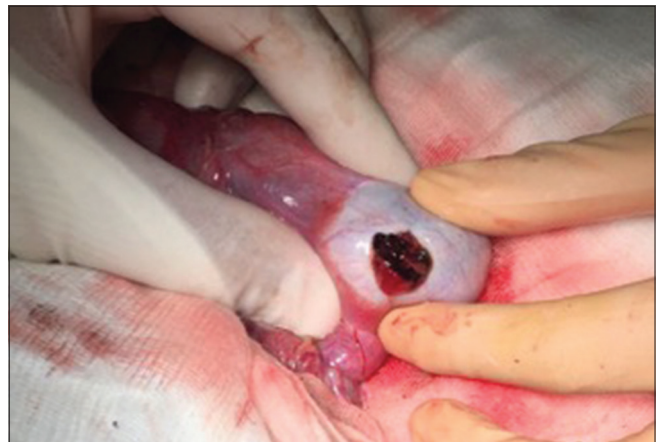performed showing no torsion of the spermatic cord. The tunica albuginea was incised, and the hypoechoic nodule was removed [Figure 2]. The pathological examination showed diffuse hemorrhagic infarction of the testis tissue, surrounded by normal parenchyma without neoplastic findings. No surgical complication was reported; the patient was discharged after 2 days and then lost to follow-up.

### Case 2

A 43-year-old male presented to our ED with severe left scrotal pain with fever. A scrotal examination revealed a painful and swollen lower pole of the left testicle. Blood analysis showed leukocytosis while testicular markers were normal. SCDU evaluation revealed that the lower two-thirds of the left testicle were constituted of a neoformation with a dishomogeneous structure. Because of the SCDU findings and refractory pain, an explorative inguinoscrotomy was performed. No torsion was found during surgery, but the left testicle had a bluish-white appearance; numerous subalbugineal clots were evacuated allowing for the visualization of poor, necrotic parenchyma. Radical orchiectomy was performed after the intraoperative frozen section analysis showed fresh hemorrhage with no appreciable tumor. One day after surgery, his pain was under control, and he was discharged from our hospital. To exclude systemic causes of testicular infarction, a hematological screening was performed revealing moderately elevated levels of homocysteine (18.9  $\mu\text{mol/L}$ ).

### Case 3

A 36-year-old male presented with a 1-day history of acute right-sided testicular pain. His medical history was marked by an episode of paroxysmal atrial fibrillation regressed with flecainide 3 years earlier, hemorrhoidectomy 7 years earlier for several episodes of hemorrhoidal thrombosis, and a recent finding of patent foramen ovale. He had undergone screening for thrombophilia with mild positivity for anti-beta-2 glycoprotein 1 immunoglobulin G (IgG) (21 U/mL). The testis was tender on palpation, and all



**Figure 2:** Macroscopic features during surgery: no testis discoloration or torsion of the spermatic cord is observable, whereas a clot-like nodule, surrounded by normal parenchyma, is easily recognized under the tunica albuginea

hematological markers including inflammatory and tumor markers were negative except for lactate dehydrogenase (300 U/l). SCDU performed on day 1 revealed multiple heterogeneous nodular formations of solid appearance, the largest measuring 13 mm, with irregular vascularization. The left testis was normal. A provisional diagnosis of testicular neoplasm was suggested, and a surgical testicular exploration was scheduled. A total-body contrast-enhanced computed tomography was performed without significant findings. Seven days after the onset of symptoms in the right testis, the patient experienced a sudden and severe pain in the left testis. His laboratory tests were positive for leukocytosis. His examination revealed that the right testis was still slightly increasing in volume and consistency, whereas the left testicle had now markedly increased in volume and acquired an irregular surface that was very painful and tender on palpation. The patient underwent a second SCDU that showed an appearance similar to that originally seen on the right didymus. A left explorative inguinoscrotomy was performed showing multiple testicular hematomas; several clots were evacuated preserving residual testicular trophic parenchyma. An intraoperative

frozen section analysis of the testicular tissue showed hemorrhage with no observable tumor. Considering the clinical history and the histological findings, a testis-sparing approach was performed without contralateral exploration. The patient was discharged 5 days after surgery. The subsequent 9 months were without event.

#### Case 4

A 48-year-old patient presented with acute left testicular pain that had begun 1 day ago and was referred to the ED for evaluation. Physical examination showed a nodule on the upper pole of the testicle. His laboratory tests were positive for leukocytosis while tumoral markers were negative. A 3.1 cm poorly vascularized inhomogeneous nodule with slightly delimitable margins was confirmed by SCUDU. Because the mass was very firm to palpation and a hypovascular tumor could not be excluded, the patient underwent testicular exploration 10 days later. An inguinal approach was performed; intraoperatively, a superior polar testicular nodule was confirmed to be in close contact with the head of the epididymis. Frozen section analysis of the lesion revealed the hemorrhagic nature of the lesion but no neoplastic elements; a testis-sparing approach was thus performed. No surgical complication was reported; immunological blood tests were positive for anti-beta-2 glycoprotein 1 IgG (25 U/mL). SCUDU was repeated after 3 and 12 months, and no recurrences were documented.

#### DISCUSSION

STI usually occurs between the second and fourth decades of life and is generally rare after the 50s, although some cases have been described.<sup>[2,3]</sup>

Despite the fact that more than a half of STI cases are idiopathic, it has been related to epididymitis, intermittent testicular torsion, trauma, bell-clapper anomaly, sickle cell anemia, vasculitis, polycythemia, hypercoagulable states such as S-Protein or antithrombin deficiency, hypersensitivity angitis, polyarteritis nodosa, familial Mediterranean fever, thrombotic endocarditis, cholesterol embolism, diabetic microangiopathy, defects of folate metabolism, and intimal fibroplasia of the spermatic artery.<sup>[1-5]</sup> It has been described as a surgical complication following laparoscopic inguinal hernia repair, herniorrhaphy, varicocelectomy, vasectomy, or radical cystectomy.<sup>[2,6-9]</sup>

Fernández-Pérez *et al.* speculate that an abnormality in the posterior epididymal artery or centripetal arteries might predispose some men to a segmental infarction. The authors explain that the majority of cases may occur in the upper pole of the testicle due to the precarious

vascular supply of this hemisphere;<sup>[10]</sup> conversely, only one of the reported cases predominantly involved this area. In all cases, the onset of presentation was acute, a nodule was palpable in one patient, whereas only a metachronous bilateral disease was reported. Anti-beta-2 glycoprotein 1 IgG was elevated in two-fourths of the cases, consistent with the report by Srivastava *et al.* on a patient who experienced STI as a complication of antiphospholipid syndrome.<sup>[11]</sup>

SCDU findings of STI may vary from hypoisoechoic to pseudonodular and are of utmost importance since the absence of vascularization in the affected area represents a radiologic landmark of STI.

In our series, no magnetic resonance imaging (MRI) was performed. It is reported that STI shows markedly enhanced borders on postcontrast images, with a triangular form direct to the mediastinum.<sup>[10]</sup> On the other hand, MRI is expensive and often not readily available in an urgent care setting. In addition, in the series reported by Ernst *et al.*, MRI was not successful in safely ruling out malignant conditions, and inguinal explorations of the testis were thus always performed.<sup>[2]</sup>

Importantly, testicular cancer may present with sudden pain which is often associated with hemorrhage within the tumor, being a cause of acute scrotum in 4.3% of cases.<sup>[12]</sup> In this context, even if painful testicular enlargement is generally only infectious or inflammatory, Smith *et al.* insist that any mass in the testicular body must be considered as a cancer until proven otherwise being that >95% of intratesticular masses are malignant.<sup>[13]</sup>

#### CONCLUSIONS

This monocentric surgical series highlights the heterogeneous presentation of STI, a generally underestimated pathology. To obtain a differential diagnosis between STI, testicular cancer, or torsion, a hematologic evaluation should always be performed. The definitive diagnosis is, nevertheless, achieved through excisional biopsy, with a testis-sparing intent in case of negative frozen section.

#### Declaration of patient consent

The authors certify that they have obtained all appropriate patient consent forms. In the form the patient(s) has/have given his/her/their consent for his/her/their images and other clinical information to be reported in the journal. The patients understand that their names and initials will not be published and due efforts will be made to conceal their identity, but anonymity cannot be guaranteed.

### Financial support and sponsorship

Nil.

### Conflicts of interest

There are no conflicts of interest.

### REFERENCES

1. Gianfrilli D, Isidori AM, Lenzi A. Segmental testicular ischaemia: Presentation, management and follow-up. *Int J Androl* 2009;32:524-31.
2. Ernst S, Saar M, Brenneis H, Kubale R, Ueberdiek S, Ohlmann CH, *et al.* Segmental testicular infarction: Case series and literature review of a rare diagnosis in men with acute testicular pain. *Urol Int* 2018;101:114-6.
3. Adachi S, Tsutahara K, Kinoshita T, Hatano K, Kinouchi T, Kobayashi M, *et al.* Segmental testicular infarction due to cholesterol embolism: Not the first case, but the first report. *Pathol Int* 2008;58:745-8.
4. Dogra V. Bell-clapper deformity. *AJR Am J Roentgenol* 2003;180:1176.
5. El Atat R, Derouiche A, Kourda N, Hammami A, Chebil M, Ben Jilani S, *et al.* Segmental infarction of the testis: An exceptional complication of diabetes microangiopathy. *Int J Impot Res* 2007;19:615-6.
6. Mincheff T, Bannister B, Zobel P. Focal testicular infarction from laparoscopic inguinal hernia repair. *JSLs* 2002;6:211-3.
7. Calcagno C, Gastaldi F. Segmental testicular infarction following herniorrhaphy and varicocelectomy. *Urol Int* 2007;79:273-5.
8. Yoo KH, Jeon SH, Lee HL, Lim SJ, Chang SG. Vasectomy is not a simple procedure: Subtotal testicular infarction. *Scand J Urol Nephrol* 2010;44:361-3.
9. Alleemudder AI, Amer T, Rao A. Segmental testicular infarction following cysto-prostatectomy. *Urol Ann* 2011;3:42-3.
10. Fernández-Pérez GC, Tardáguila FM, Velasco M, Rivas C, Dos Santos J, Cambrono J, *et al.* Radiologic findings of segmental testicular infarction. *AJR Am J Roentgenol* 2005;184:1587-93.
11. Srivastava A, Ko J, Ogunsile J, Moliterno A, Westra WH, Semerjian A, *et al.* Patient with antiphospholipid syndrome presenting with testicular torsion-like symptoms. *Urol Case Rep* 2017;15:26-7.
12. Roth B, Giannakis I, Ricklin ME, Thalmann GN, Exadaktylos AK. An accurate diagnostic pathway helps to correctly distinguish between the possible causes of acute scrotum. *Oman Med J* 2018;33:55-60.
13. Smith ZL, Wertz RP, Eggener SE. Testicular cancer: Epidemiology, diagnosis, and management. *Med Clin North Am* 2018;102:251-64.