

# Three-dimensional evaluation of rapid maxillary expansion anchored to primary molars: direct effects on maxillary arch and spontaneous mandibular response



A. Di Ventura<sup>\*\*\*</sup>,  
V. Lanteri\*, G. Farronato\*,  
F. Gaffuri\*, M. Beretta\*\*,  
C. Lanteri\*\*, G. Cossellu\*

\*Department of Biomedical, Surgical and Dental Sciences, University of Milan, Fondazione IRCCS Ca' Granda, Ospedale Maggiore Policlinico, Milan, Italy  
\*\*Private practice, Alessandria, Italy  
\*\*\*Private practice, Teramo, Italy

e-mail: gianguido.cossellu@unimi.it

DOI 10.23804/ejpd.2019.20.01.08

## Abstract

**Aim** The purpose of this study was to evaluate the effects of rapid maxillary expansion (RME) on maxillary and mandibular arch in the mixed dentition.

**Methods** Forty-four consecutive patients with transverse maxillary deficiency were recruited. Test group: 21 patients (10 male, 11 female;  $7.4 \pm 1.2$  years) who underwent RME (Haas type) therapy banded on the primary second molars. Control group: 17 patients (10 male, 7 female;  $7.3 \pm 1.1$  years old) who did not receive any orthodontic treatment. Dental casts obtained pre-treatment and after appliance removal (11 months) were processed by means of a three-dimensional scanner (3Shape D250 laser, DK). Digital landmarks were traced using the VAM software (Canfield Scientific Inc., Fairfield-NJ, USA). Arch Length, interdental width and torque differences were measured before and after the removal of the appliance. The t-test ( $P < 0.05$ ) for paired data was applied to evaluate the measurements values before and after treatment. The linear regression model was employed to assess the correlations between treatment effects.

**Results** The efficacy of the RME was confirmed both on maxillary and mandibular arch. Mandibular intermolar width (+2.02 mm) together with primary intermolar (+1.39 mm), intercanine width (+0.95mm) and torque variations significantly increased. The untreated control group showed no significant statistical differences between T0 and T1. The linear regression between maxillary and mandibular data showed correlations between the torque of the teeth 16/46 and 65/85 ( $P < 0.05$ ).

**Conclusions** RME anchored on primary molars is an effective treatment option to correct transverse maxillary deficiencies. All the measurements increased significantly confirming the indirect effect of RME on the mandibular arch.

## Introduction

Maxillary arch constriction and posterior crossbite are common malocclusions in the primary and mixed dentition with an incidence ranging from 7 to 23% [Kutin G and Hawes RR, 1969; Agostino P et al., 2014; Ferro et al., 2016].

Posterior crossbite can result in mandibular shift and postural alterations, with a possible asymmetrical growth, asymmetrical development of the right and left sides of the mandible and dysfunction of the skeletal and muscle structures [Iodice et al., 2016; Cossellu et al., 2016; Cossellu et al., 2015]. Rapid Maxillary Expansion (RME) is a common therapy for the correction of this condition. The RME has not only been used to increase the maxillary transversal dimension but also to create additional space in constricted maxillary dental arches to correct upper crowding [Harrison and Ashby, 2002; McNamara Jr et al., 2003; Cossellu et al., 2013; Gianolio et al., 2014].

Problems associated with mandibular crowding are more challenging to treat. Indeed, orthodontic and orthopaedic forces applied on the mandibular arch are opposed by the highly resistant body of the mandible.

Spontaneous changes in the mandibular dentition under the influence of maxillary expansion have been reported since the '70s [Gryson, 1977]. Even Andrew Haas, the developer of the current RME, claimed that a permanent increase in the maxillary apical base leads to a spontaneous, permanent, and significant increase in mandibular arch width [Haas, 1961].

Although this orthodontic treatment has been extensively discussed in the literature, mandibular arch decompensation during RME is still not clearly assessed neither with invasive (x-rays) nor with non-invasive analysis. Only few studies supporting the indirect effects of RME on mandibular arch with a 3D non-invasive analysis were published [Baysal A et al., 2011; Primožič et al., 2013; Baccetti et al., 2005].

The aim of this study is to quantitatively evaluate the maxillary and mandibular changes after RME treatment in patients with maxillary arch constriction, banded on the primary second

**KEYWORD** Crossbite, Crowding, 3-D Imaging, Maxillary Expansion, Palatal Expansion Technique, Torque.

molars and to compare the outcomes between patients with and without maxillary crossbite.

## Materials and methods

Forty-four consecutive Caucasian patients, 20 male and 24 female, with a mean age at the beginning of the treatment of  $7.5 \pm 1.4$  years, presenting with transverse deficiency (posterior crossbite or anterior crowding without crossbite), were recruited at the Department of Biomedical Surgical and Dental Sciences, University of Milan, Italy.

The study has been approved by the Local Ethic Committee, Fondazione IRCCS Ospedale Maggiore Policlinico, Milan, Italy (Prot. n° 573/15).

Subjects were selected according to the following eligible criteria: early or mid-mixed dentition, cervical vertebral stage 1 through 3 (CVS methods 1-3) [Baccetti et al., 2005], Angle Class I or Class II malocclusion, no previous orthodontic treatments, maxillary arch constriction.

Exclusion criteria were the presence of craniofacial abnormalities, previous extraction or surgical treatment, angle Class III malocclusion, TMJ dysfunctions.

The test group consisted of 22 patients (11 male - 11 female), mean age  $7.3 \pm 1.2$  years, who underwent RME (Haas type) therapy. The appliances were banded by the same operator on the primary second molars. The expanders presented the same type of screw, an anterior arm to the canines and a posterior arm to the first permanent molars; no subsequent orthodontic treatment was applied in either the maxilla or the mandible. The screw was activated three times per day ( $0.2 \text{ mm} \times 3$ ) until the desired expansion was achieved. The expansion was considered complete when the occlusal aspect of the maxillary lingual cusp of the first upper molars contacted the occlusal aspect of the vestibular cusp of the mandibular first molars. All the expanders were removed after 11 months (2 months of active phase and 9 month of stabilisation).

The control group consisted of 22 subjects with maxillary arch constriction (9 male, 13 female); mean age  $7.3 \pm 1.3$  years, to be treated with RME therapy but that did not receive any orthodontic treatment during the study period.

During the treatment one patient in the test group was excluded from the study due to a wrong activation of the screw and five patients in the control group were excluded because they started an orthodontic treatment. The final sample consisted of 21 patients in the test group (10 male, 11 female;  $7.4 \pm 1.2$  years) and 17 patients in the control group (10 male, 7 female;  $7.3 \pm 1.1$  years old).

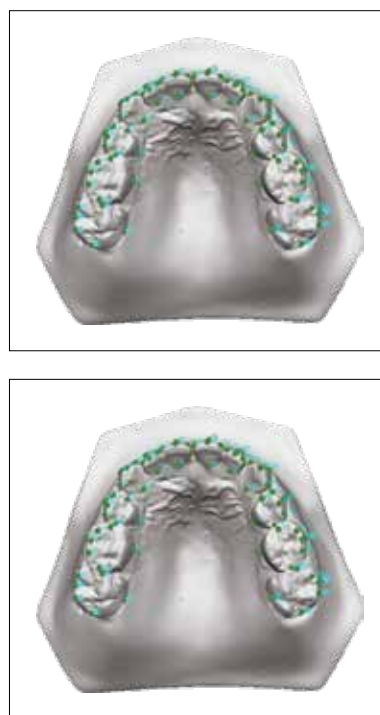
The differences between patients with a maxillary crossbite and those without a crossbite have also been evaluated in order to assess if this malocclusion might influence the mandibular growth as suggested by Cozzani et al. [2007].

Dental casts were obtained pre-treatment and upon appliance removal; maxillary and mandibular casts were processed by means of an intraoral scanner (3Shape D250 laser, 3Shape, Copenhagen, DK). The sample consisted of 76 cast models (38 of the upper and 38 of the lower arch).

Digital landmarks were traced by means of VAM software according to a previously described protocol (Canfield Scientific Inc., Fairfield-NJ, USA) (Fig. 1) [Huanca Ghislanzoni et al., 2013].

Each patient was randomly identified with a number, and ten linear variables and sixteen angular variables were considered and traced by a single blinded examiner.

Arch length was measured for all subjects, together with intermolar, primary first and second intermolar and primary



**FIG. 1** Maxillary and mandibular dental arches showing distribution and position of digital landmarks

intercanine width. The reference points for intermolar widths were the most occlusal point of the vestibular sulci and for the intercanine width were the cusp tips. When either the deciduous or the permanent teeth were missing or not fully erupted, the measurements for that variable were eliminated.

For each tooth we also measured the torque differences before and after the removal of the appliance. Torque was measured as the labiolingual inclination of the facial axis of the clinical crown (FACCs) relative to the reference plane (traced as a best-fit plane among all of the lingual points, with the inter-molar lingual distance set as the reference X-axis. This reference plane was constructed nearly parallel to the occlusal plane, avoiding variability due to tooth position and torque and curve of Spee, or curve of Wilson) [Ugolini et al., 2015].

### Method error

All the measurements were calculated by the same expert operator. One month later, on 20 randomly selected dental casts, the measurements were made by a different operator and recalculated by the first one in order to assess intra- and inter-operator variability. Intraclass correlation coefficients (ICC) were calculated to compare within-subject variability to between-subject variability; correlation coefficients results were larger than 0.91. The mean error was less than 0.2 mm for linear variables and less than  $1^\circ$  for angular variables. The method error was considered negligible.

### Statistical analysis

Sample size was calculated a priori to obtain a statistical power of the study greater than 0.85 at an alpha of 0.05, using the mean values and standard deviations of mandibular molar expansion after RME therapy found by Ugolini et al. [2015].

The statistical packages Wickham 2009 and Walker 2015 (software R Core Team 2015) were used for statistical analysis with a P value of  $<0.05$  considered to be statistically significant.

Numerical data are given as means and standard deviations.

The Shapiro-Wilk test for normality was applied to the data. The data on T1 and T2 were found to be normally distributed;

	Mean	SD	Significance
tq36	2.67	1.49	*
tq75	2.43	0.978	*
tq74	2.19	1.36	*
tq73	0.714	2.37	NS
tq46	2.71	0.902	*
tq85	3.05	1.24	*
tq84	1.67	2.01	*
tq83	1.95	2.33	*
36-46 width	2.02	1.43	*
75-85 width	1.75	1.38	*
74-84 width	1.39	1.18	*
73-83 width	0.952	1.1	*
Arch perimeter	0.724	1.2	*

Mean and standard deviation (SD) of the torque and interdental width increase after RPE treatment - Test Group, mandibular arch. Tq = torque values (degree); interdental width (millimeters); P value < 0.05 \* ; NS = not significant

TABLE 1 Group 1, mandible.

	Crossbite Group		No Crossbite Group		Significance
	Mean	SD	Mean	SD	
tq36	2.4	2.0	2.8	1.1	NS
tq75	2.9	1.0	2.2	0.9	NS
tq74	2.0	1.2	2.3	1.5	NS
tq73	1.9	1.6	0	2.5	NS
tq46	2.9	0.8	2.6	1.0	NS
tq85	3.8	0.7	2.6	1.3	*
tq84	2.6	1.5	1.1	2.1	NS
tq83	1.9	1.2	2.0	2.9	NS
36-46 width	1.9	1.1	2.1	1.6	NS
75-85 width	1.6	1.6	1.8	1.3	NS
74-84 width	1.1	1.3	1.6	1.1	NS
73-83 width	0.7	1.4	1.1	0.9	NS
Arch perimeter	0.9	1.5	0.6	1.0	NS

Mean and standard deviation (SD) of the torque and interdental width values increase after RPE treatment - Crossbite vs no crossbite groups, mandibular arch. Tq = torque values (degree); interdental width (millimeters); P value < 0.05 \* ; NS = not significant

TABLE 3 Mandibular arch comparisons.

the t-test for paired data was applied to evaluate the treated group (measurements carried out on the same patients before and after treatment).

A linear regression model was employed to assess correlations between treatment effects on the maxillary and on the mandibular variables (both linear and angular) using the formula  $y_i = \alpha + \beta * x_i + \epsilon_i$  ( $x_i$  the acting variable and  $y_i$  the variable caused by  $x_i$ ).

**Results**

Descriptive statistics and statistical comparisons of maxillary and mandibular linear (mm) and angular (degree) measurements before (T1) and after treatment (T2) with RME are shown in Table 1, 2. In the test group all the measurements before and after treatment, except for the torque of tooth 73, showed statistically significant differences (P<0.05).

	Mean	SD	Significance
tq16	3.43	1.6	*
tq55	3.33	1.77	*
tq54	1.48	2.06	*
tq53	2.14	2.15	*
tq26	3.24	1.48	*
tq65	3.81	1.75	*
tq64	2.76	1.55	*
tq63	1.76	1.67	*
16-26 width	3.81	1.38	*
55-65 width	3.23	1.45	*
54-64 width	3.34	1.22	*
53-63 width	3.63	1.52	*
Arch perimeter	2.87	1.37	*

Mean and standard deviation (SD) of the torque and interdental width increase after RPE treatment - Test Group, maxillary arch. Tq = torque values (degree); interdental width (millimeters); P value < 0.05 \* ; NS = not significant

TABLE 2 Group 1, maxilla.

	Crossbite Group		No Crossbite Group		Significance
	Mean	SD	Mean	SD	
tq16	3.6	1.1	3.3	1.9	NS
tq55	3.4	1.8	3.2	1.9	NS
tq54	1.6	2.3	1.4	2.1	NS
tq53	1.4	2.6	2.5	1.9	NS
tq26	2.7	1.4	3.5	1.6	NS
tq65	4.6	1.7	3.6	1.6	NS
tq64	3.0	1.3	2.5	1.7	NS
tq63	1.6	1.7	1.8	1.8	NS
16-26 width	4.5	1.4	3.4	1.3	NS
55-65 width	3.3	2.0	3.2	1.1	NS
54-64 width	3.6	1.5	3.2	1.0	NS
53-63 width	3.6	1.4	3.7	1.6	NS
Arch perimeter	2.6	1.6	3.0	1.2	NS

Mean and standard deviation (SD) of the torque and interdental width increase after RPE treatment - Crossbite vs no crossbite groups, maxillary arch. Tq = torque values (degree); interdental width (millimeters); P value < 0.05 \* ; NS = not significant

TABLE 4 Maxillary arch comparisons.

In the treated subjects (RME group), mandibular intermolar width significantly increased by 2.02 mm, primary intermolar width increased of 1.39 and 1.75 mm respectively for first and second primary molars; intercanine width increased of 0.9 mm and total arch length of 0.7 mm. Significant differences were noticed also for the torque of all the mandibular teeth except for the lower left canine (Table 1).

The comparison between the crossbite vs non-crossbite patients in the Test group showed only one significant difference (Table 3, 4).

The linear regression between the maxillary and mandibular data showed two significant correlations: the first one between the torque of the right first molars; the second one between the torque of the left second primary molars (Fig. 2, 3). A significant trend was found between the canine (p=0.06) and the first primary molars (p=0.08) of the right side. With regard to linear measurements, no correlations were found.




FIG. 2 Linear regression result between the torque of the right first molars.

The untreated control group showed no significant statistical differences between T0 and T1 (data not shown).

**Discussion**

The first main clinical result achieved is that the maxillary molar crossbite was corrected in all the patients of the test group even if the RME was anchored to the primary molars.

We obtained also significant results for the lower interdental width and the torque measurements.

Minimal data has been previously reported about the effects of the RME on the mandibular arch considering both linear and angular measurements in both deciduous and permanent teeth [Baysal et al., 2011; Ugolini et al., 2015; Lombardo et al., 2015; Lima et al., 2004; Lanteri et al., 2018].

Our data fulfill and strengthen the observations about the influence of RME on the maxillary arch and on the width and angulations of mandibular teeth.

In the upper arch the greatest increase was observed at the intermolar width (+3.81 mm ±1.38 mm) and at the intercanine width (+3.63 mm ± 1.52 mm) even if the RME was banded on the primary molars.

Although no direct forces were applied on first permanent molars, significant changes in their inclination were found. The comparison in torque increasing between the permanent maxillary molars and the primary molars showed no significant differences: this result underlines the effect of RME, even when banded on the deciduous teeth, on the inclination of the permanent molars. These torque variations should be considered as the result of the real change of teeth inclination (mainly caused by the arms) and the effect on the alveolar structure known as "alveolar bending" [Ugolini et al., 2015; Lombardo et al., 2015; Lima et al., 2004; Garrett et al., 2008; Weissheimer et al., 2011].

Canine's torque did not change as much as posterior teeth' one: this might suggest that the RME bonded on primary molars, thus with the screw placed in a more central palatal position, promoted a uniform maxillary expansion reducing the flaring of the alveolar bone.

Significant differences in torque values have been reported also for the mandibular teeth both on the right and left side: +2.67° for tooth 3.6; +2.71° for tooth 4.6; +2.43° for tooth 7.5;

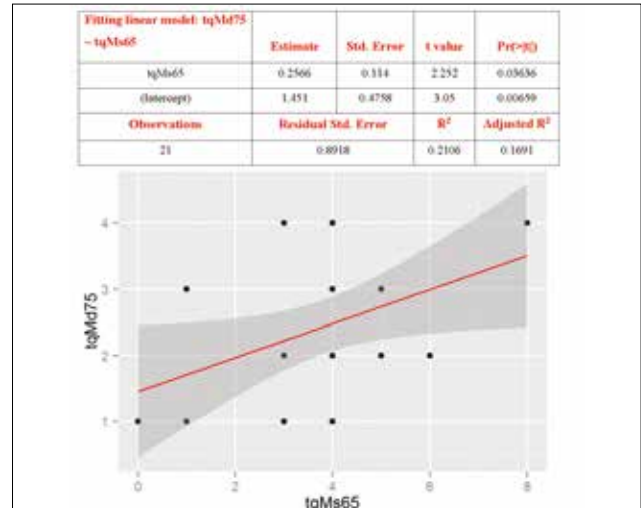


FIG. 3 Linear regression result between the torque of the left second primary molars.

+3.05° for tooth 8.5. Only the torque values of the lower left canine did not show a significant difference, in accordance with the current literature [Weissheimer et al., 2011; Kartalian et al., 2010].

Similar results have been reported by Haas since 1961 confirming that a permanent increase in the maxillary apical base leads to a spontaneous, permanent, and significant increase in mandibular arch width.

Unlike previous researches, deciduous teeth were included in our study. In the lower arch, we observed a more relevant increase of the interdental width than reported before [Gryson, 1977; Cozzani et al., 2007; Ugolini et al., 2015] a significant increase for canines (+0.95 mm), first deciduous molars (+1.39 mm), second deciduous molars (+1.75 mm) and first permanent molars (+2.02 mm). The slightest difference was the arch perimeter length that increased less than 1 mm.

All previous studies reported an intercanine width increase up to 5 mm [Lima et al., 2004; Haas, 2010; Lagravère et al., 2006]. In our study the intercanine width increase is in accordance with data reported by Cozzani et al. (+0.9 mm) [Cozzani M et al., 2007] and Ugolini et al. (+1.0 mm) [Ugolini A et al., 2016]. Furthermore, we found a considerable variation in intermolar distance in contrast with Cozzani et al. [2007].

All other studies evaluating the RME's effects on the mandibular arch cannot be directly compared to our due to the different ages of treated subjects (ranging from children to adults) [Haas J, 1961; Wertz RA, 1970] or the use of other fixed or removable appliances [Sandstorm RA et al., 1988; Moussa R et al., 1995; McNamara JA Jr, 2002].

Despite interdental width enlargements, no relevant mandibular arch length increase was obtained. This outcome suggests that those improvements were mainly due to the dental decompensation obtained after maxillary expansion and not to the normal or secondary growth of the mandible.

The regression analysis confirmed the influence of the maxillary improvements on the mandibular arch: a significant correlation has been noticed for the torque of the teeth 4.6/1.6 and 7.5/6.5.

We obtained a coefficient that might be used in order to assess the torque changes on mandibular arch after RME activation using the formula:

$$(\text{estimate} + \text{intercept}) \times \text{torque change of 1.6 or 6.5.}$$

The coefficients for tooth 4.6 are -0.2821 (estimate) and +3.682 (intercept); for tooth 7.5 estimate is +0.2566 and intercept +1.451.

However, the R2 value (Fig. 2, 3) must be considered: this data represents the percentage (0.25 = 25%) of the change that is going to be expressed clinically.

In our sample the torque changes obtained from the formula are +11.62° for tooth 4.6 and +6.35° for tooth 7.5; considering the coefficients only 25% and 21% of these torque variations will be always expressed clinically.

The interdental mandibular width enhancement has to be considered the result gained from the increased tongue pressure, reduced lip and cheek pressures and new occlusal contacts [Kartalian et al., 2010]. Moreover, the lower position of the tongue due to the presence of the RME can influence and promote the changes in the mandibular teeth position. Another important consideration is that the new occlusal contacts (the intercuspitation between the maxillary lingual cusp of upper first molars and the vestibular cusp of the mandibular first molars) during chewing can also promote torque variations in the mandibular arch.

The control group was used to identify confounding factors such as spontaneous growth during the study period. Interdental width of the test group was significantly higher than that measured for the untreated control group indicating that in our sample the crossbite correction does not improve spontaneously with growth. Considering that patients were still far from their puberty growth peak and that the measurements have been taken only after 9 months from baseline, we can theorise that improvements are the direct consequence of RME action without a meaningful influence of the normal skeletal growth. However, we can assume that the main limitation of the study is the lack of a long-term follow-up.

In the comparison between crossbite and non-crossbite groups we did not notice any significant differences in the mandibular arch as reported by Cozzani [2007], who stated that the mandibular arch in patients with a crossbite had a wider interdental width than those treated with RME. In our patients we did not notice these differences, suggesting that the presence of the crossbite seems not to have any influence on the development of the lower arch. Furthermore, the use of the primary teeth to anchor the RME proved to be effective and these might always be considered as a valid option in order to avoid the undesirable effects for permanent teeth used as anchorage such as root resorption, periodontal damage and gingival recession [Greenbaum and Zachrisson, 1982].

## Conclusions

Therapy with RME anchored to primary molars is an effective treatment option to correct maxillary transverse deficiencies.

All the mandibular and maxillary interdental arch widths increased significantly in the test group.

The torque values of mandibular teeth showed a significant increase after 9 months of RME therapy.

Within the limitations of this study, our results demonstrated the effectiveness of RME anchored to primary molars; the spontaneous mandibular response to this orthodontic treatment is a valuable and important outcome to be considered during the therapy.

## References

Agostino P, Ugolini A, Signori A, Silvestrini-Biavati A, Harrison JE, Riley P. Orthodontic treatment for

- posterior crossbites. *Cochrane Database Syst* 2014;Rev 8:8.
- Baccetti T, Franchi L, McNamara JA. The cervical vertebral maturation (CVM) method for the assessment of optimal treatment timing in dentofacial orthopedics. *Seminars in Orthodontics* 2005;11:119–29.
- Baysal A, Veli I, Ucar FI, Erüz M, Ozer T, Uysal T. Changes in mandibular transversal arch dimensions after rapid maxillary expansion procedure assessed through cone-beam computed tomography. *Korean J Orthod* 2011;41:200–10.
- Cossellu G, Seramondi R, Benedicenti S, Farronato G, Olivi G, Angiero F. Tooth developmental anomalies in severe combined immunodeficiency disease and juvenile myelomonocytic leukemia: common clinical features and treatment outcomes. *Eur J Paediatr Dent* 2013;14(4):328–32.
- Cossellu G, Farronato G, Nicotera O, Biagi R. Transverse maxillary deficit and its influence on the cervical vertebrae maturation index. *Eur J Paediatr Dent* 2016;17(2):147–50.
- Cossellu G, Biagi R, Faggioni G, Farronato G. Orthodontic treatment of Binder syndrome: a case report with 5 years of follow-up. *Cleft Palate Craniofac J* 2015;52(4):484–8.
- Cozzani M, Guiducci A, Mirengi S, Mutinelli S, Siciliani G. Arch width changes with a rapid maxillary expansion appliance anchored to the primary teeth. *Angle Orthod* 2007;77: 296–302.
- Ferro R, Besostri A, Olivieri A, Quinzi V, Scibetta D. Prevalence of cross-bite in a sample of Italian preschoolers. *Eur J Paediatr Dent* 2016;17(4):307–309.
- Garrett BJ, Caruso JM, Rungcharassaeng K, Farrage JR, Kim JS, Taylor GD. Skeletal effects to the maxilla after rapid maxillary expansion assessed with cone-beam computed tomography. *Am J Orthod Dentofacial Orthop* 2008;134:8–9.
- Gianolio A, Lanteri V, Chierchi C. Rapid and slow maxillary expansion: a postero-anterior cephalometric study. *Eur J Paediatric Dent* 2014; 15(4): 415–8.
- Greenbaum KR, Zachrisson BU. The effect of palatal expansion therapy on the periodontal supporting tissues. *Am J Orthod* 1982;81:12–21.
- Gryson JA. Changes in mandibular interdental distance concurrent with rapid maxillary expansion. *Angle Orthod* 1977;47:186–92.
- Haas AJ. Rapid expansion of the maxillary dental arch and nasal cavity by opening the midpalatal suture. *Angle Orthod* 1961;31: 73–90.
- Haas AJ. Long-term posttreatment evaluation of rapid palatal expansion. *Angle Orthod* 1980;50:189–217.
- Harrison JE, Ashby D. Orthodontic treatment for posterior crossbites. *Cochrane Database Syst Rev* 2002;(2):CD000979.
- Huanca Ghislanzoni LT, Lineberger M, Cevidanes L, Mapelli A, Sforza C, McNamara JA Jr. Evaluation of tip and torque on virtual study models: a validation study. *Prog Orthod* 2013;14:19.
- Iodice G, Danzi G, Cimino R, Paduano S, Michelotti A. Association between posterior crossbite, skeletal, and muscle asymmetry: a systematic review. *Eur J Orthod* 2016;38(6):638–651.
- Kartalian A, Gohl E, Adamina M, Enciso R. Cone-beam computer tomography evaluation of the maxillary dentoskeletal complex after rapid palatal expansion. *Am J Orthod Dentofacial Orthop* 2010;138:486e92.
- Kutin G, Hawes RR. Posterior cross-bites in the deciduous and mixed dentitions. *Am J Orthod* 1969;56:491–504.
- Lagravère MO, Heo G, Major PW, Flores-Mir C. Meta-analysis of immediate changes with rapid maxillary expansion treatment. *J Am Dent Assoc* 2006;137:44–53.
- Lanteri V, Gianolio A, Gualandi G, Beretta M. Maxillary tridimensional changes after slow expansion with leaf expander in a sample of growing patients: a pilot study. *Eur J Paediatr Dent* 2018;19(1):29–34.
- Lima AC, Lima AL, Filho RM, Oyen OJ. Spontaneous mandibular arch response after rapid palatal expansion: a long-term study on Class I malocclusion. *Am J Orthod Dentofacial Orthop* 2004;126(5):576–82.
- Lombardo L, Albertini E, Arreghini A, D'Alessandro AC, Siciliani G. Rapid maxillary expansion on the permanent teeth versus the deciduous teeth: Comparison of skeletal and dentoalveolar effects by volumetric tomography. *JWFO* 2015;4(1): 2 – 7.
- McNamara JA Jr, Baccetti T, Franchi L, Herberger TA. Rapid maxillary expansion followed by fixed appliances: a long-term evaluation of changes in arch dimensions. *Angle Orthod* 2003;73:344–353.
- McNamara JA Jr. Early intervention in the transverse dimension: is it worth the effort? *Am J Orthod Dentofacial Orthop* 2002;121:572–574.
- Moussa R, O'Reilly MT, Close JM. Long-term stability of rapid palatal expansion treatment and edgewise mechanotherapy. *Am J Orthod Dentofacial Orthop* 1995;108:478–88.
- Primožič J, Baccetti T, Franchi L, Richmond S, Farčnik F, Ovsenik M. Three-dimensional assessment of palatal change in a controlled study of unilateral posterior crossbite correction in the primary dentition. *Eur J Orthod* 2013;35(2):199–204.
- Primožič J, Richmond S, Kau C H, Zhurov A, Ovsenik M. Three-dimensional evaluation of early crossbite correction: a longitudinal study. *Eur J Orthod* 2013;35(1):7–13.
- Sandstrom RA, Klapper L, Papaconstantinou S. Expansion of the lower arch concurrent with rapid maxillary expansion. *Am J Orthod Dentofacial Orthop* 1988;94:296–302.
- Ugolini A, Cerruto C, Di Vece L, Ghislanzoni LH, Sforza C, Doldo T, Silvestrini-Biavati A, Caprioglio A. Dental arch response to Haas-type rapid maxillary expansion anchored to deciduous vs permanent molars: A multicentric randomized controlled trial. *Angle Orthod* 2015;85(4):570–6.
- Ugolini A, Doldo T, Ghislanzoni LT, Mapelli A, Giorgetti R, Sforza C. Rapid palatal expansion effects on mandibular transverse dimensions in unilateral posterior crossbite patients: a three-dimensional digital imaging study. *Prog Orthod* 2016;17:1.
- Weissheimer A, de Menezes LM, Mezomo M, Dias DM, de Lima EM, Rizzato SM. Immediate effects of rapid maxillary expansion with Haas-type and hyrax-type expanders: a randomized clinical trial. *Am J Orthod Dentofacial Orthop* 2011;140:366–76.
- Wertz RA. Skeletal and dental changes accompanying rapid midpalatal suture opening. *Am J Orthod* 1970;58:41–66.