Preoperative and postoperative ultrasound assessment of stress urinary incontinence

Patrizio Antonazzo [1], Ilenia di Bartolo [1], Francesca Parisi [1], Irene Cetin [1], Valeria M. Savasi [1*]

[1] Unit of Obstetrics and Gynecology, Center for Fetal Research Giorgio Pardi, Department of Biomedical and Clinical Sciences, Hospital Luigi Sacco, via GB Grassi 74, Università degli Studi di Milano, Milan, Italy

Corresponding author:
Valeria M. Savasi
Unit of Obstetrics and Gynecology
Hospital Luigi Sacco
mail address: via G.B. Grassi 74, 20157 Milano, Italy
e-mail: valeria.savasi@unimi.it

ABSTRACT

INTRODUCTION: The role of ultrasound imaging in urogynecology is not defined. Significant developments in visualization techniques and interpretation of images allowed to study structures of the lower genitourinary tract and pelvic floor.

EVIDENCE ACQUISITION: PubMed and Scopus database were searched for publications on the following item: stress urinary incontinence, ultrasound, perineal ultrasound and preoperative and postoperative assessment.

EVIDENCE SYNTHESIS: The role of ultrasound in urogynecology could be helpful in diagnosing of urinary incontinence and urethral hypermobility, to document pelvic floor anatomy and to assess anatomic and functional changes before and after surgery.

CONCLUSIONS: Ultrasound could be an important step during preoperative and post-operative assessment of patients affected by stress urinary incontinence.

Key words: stress urinary incontinence, ultrasound, perineal ultrasound.

INTRODUCTION

Currently, imaging plays a limited clinical role in the investigation of pelvic floor disorders. Although compared to other forms of imaging, such as magnetic resonance imaging, it has the advantage of being a dynamic and non-static examination. Surely, translabial or transperineal ultrasound is helpful in evaluating residual urine, detrusor wall thickness, bladder neck mobility, urethral integrity, anterior, central, and posterior compartment prolapse and levator anatomy and function (1). Recently, an International Federation of Gynecology and Obstetrics (FIGO) Working Group suggests that the only useful application of ultrasound examination in the evaluation of patients with urinary incontinence is the measure of the post-void residual volume (PVR) (2) Similarly, the 5th International Consultation on Incontinence (3) concluded that ultrasound is not recommended in the primary evaluation of patients with urinary incontinence and it is an optional test in those with complex or recurrent urinary incontinence. In this review we analyzed the potential applications of ultrasound in preoperative and postoperative evaluation of patients affected by stress urinary incontinence.

EVIDENCE ACQUISITION

A Medline search was used to identify articles of interest investigating the use of ultrasound in evaluation of patients with stress urinary incontinence. There were 38 articles identified in our search, which were included in this review.

EVIDENCE SYNTHESIS

Preoperative assessment

Multiple physiologic factors, only one of which is urethral support, affect the female continence mechanism. Abnormal urethral support leads to deficient transmission of abdominal pressure to the urethra, which results in stress urinary incontinence in some women (4). Despite this, the urethral mobility is not useful in the diagnosis of urinary incontinence but provides important information about which surgical procedure is most appropriate for the correction of stress incontinence. The concept of primary measurement of some ultrasound parameters is associated

with the evaluation of vertical urethral mobility in order to accurately identify the urethral topography in a system of orthogonal coordinates (5).

Table I summarizes sensitivity, specificity and positive predictive value of the ultrasound parameters related to urinary stress incontinence.

The best method to evaluate this functional system is perineal ultrasound. Transperineal ultrasound (TUS) is carried out using a 3.5 to 6 MHz curved array transducer placed on the perineum in the midsagittal line. Examination is usually performed in the dorsal lithotomy position with the hips flexed and abducted. The resulting image contains the symphysis pubis, urethra, bladder, vagina, rectum and anal canal (Figure 1). Other findings include the uterus, the cul-de-sac with bowels and fluid as well as synthetic implants or pelvic pathologies. The symphysis pubis (SP) is used as a stable landmark serving as a reference for evaluation of the bladder neck position and mobility. Starting from this image it is possible to obtain a series of measurements. The most important ultrasound parameters are: the "pubic–urethral distance", the "pubo-urethral angle" and the "anatomical urethral length". The *pubo-urethral distance* represents the line joining the pubis and the midpoint of the urethra (Figure 2). Reference values for women aged 48-60 years are 14.07 ± 1.99 mm at rest and 16.78 ± 1.20 mm under stress, as demonstrated by Di Pietto et al. (15). The *pubo-urethral angle* defines the urethral axis between the pubic bone and the internal urethral orifice (Figure 2). Reference values for women aged 48-60 years are 85.50° ± 8.94° at rest and 105.20° ± 10.16° under stress, as demonstrated by Di Pietto et al. (Table II) (15). The perineal ultrasound measurement of the *anatomical urethral length* differs significantly between continent and incontinent patients. The differences is best seen in the examinations at rest and under pressure and least during pelvic muscle contraction. Under these two conditions the urethral length is significantly longer in women with stress incontinence (over 14 mm), probably due to the frequent association with genital prolapse (16), so the insufficiency of the urethral tissue itself could be explained the longer anatomical urethral length.

Bladder neck mobility

The assessment of bladder neck mobility and funneling of the internal urethral meatus are both important in women with urinary incontinence. With the exact determination of the bladder neck position, the effect of surgery can be controlled. Several techniques have been proposed to quantify bladder neck mobility: Q-tip test, lateral cystourethrography, introital, rectal, vaginal and perineal ultrasound (17). Perineal ultrasound is easy to learn and has the adavantage of greater comfort and safety for the patient because characterization is not nedeed and because there is no irradiation. In addition, perineal ultrasound is also a valuable tool for dynamic tests such as the evaluation of bladder and urethral behaviour during coughing, pelvic floor contractions and micturition and it can be used simultaneously with urodynamic examination, providing information about the functional anatomy. Interestingly, a study on a twin model suggested that bladder neck mobility may be to some extent determined genetically (18). For bladder neck localization, a rectangular coordinate system is used, with the inferior border of the symphysis as the reference point (Figure 2) (6). The x axis is constructed by drawing a line between the superior and inferior border of the symphysis (central line of the symphysis). The y axis is constructed perpendicular to the x axis at the inferior symphysis border. The posterior urethrovescical angle is formed by the urethral axis on one side and by at least one third of the bladder base near the bladder neck. Reference values are 140° ± 28° at rest, 158° ± 36° under stress. This measurement is a weak index to analyze the bladder neck position because of its low reproducibility. On the contrary, an important ultrasound parameter to evaluate bladder neck mobility at cephalocaudal plane is the “desensus diameter” which represents the difference between the intersection point of coronal plane passing through the urethro-vesical junction and the horizontal plane passing below the symphysis pubis measured at rest and during Valsalva maneuver (12). This diameter is found to be longer in patients with stress urinary incontinence. Despite a lack of standardization of Valsalva manoeuvre, the cut off point of bladder neck mobility is 15 mm. A desensus diameter >15 mm correlates with poor support of bladder neck in patients with stress incontinence. Otherwise, It has been observed an higher incidence of

elevated post-void residual volume (over 150 mL) among patients with stress urinary incontinence (19, 20).

Chen et al. (21) demonstrated the importance of some specific ultrasound parameteres togheter with clinical factors such as BMI gain, constipation and previous delivery mode, in the evaluation and prediction of stress urinary incontinence at an early stage of pregnancy. Three pelvic floor ultrasound parameters, β angle at rest, bladder neck funneling, and hiatal area at Valsalva Maneuver were highly predictive of stress urinary incontinence; the larger the β angle and hiatal area, the weaker the pelvic floor support. This study underlined the role of perineal ultrasound even in pregnancy to predict the onset of stress urinary incontinence.

Post-voiding residual (PVR) volume

Post-voiding residual (PVR) volume (also known as residual urine, bladder residual) is the amount of urine that remains in the bladder after voiding. It indicates poor voiding efficiency, which may result from a number of contributing factors. Ultrasound estimations may be performed using either three diameters (length, height, width) or the surface area in the transverse image and the length obtained in the longitudinal image with an inaccuracy of 20-25%, however sufficient for clinical purposes. According to the recent International Federation of Gynecology and Obstetrics (FIGO) Working Group guidelines, the only useful application of ultrasound examination in the evaluation of patients with urinary incontinence is the measure of the post-void residual volume (PVR) (2).

Post-operative assessment

Distance and Angle

Using perineal ultrasound, Torella M et al (22) measured the mean values of the pubo-urethral distance and angle in 51 patients who underwent TVT-O, to evaluate whether these measures may be determinants of success in prosthetic surgery for stress urinary incontinence. Patients with persistent SUI after TVTO have a mean pubo-urethral distance and angle greater than those in women with successful treatment. The Authors found a difference in the average pubo-urethral

distance of 3 mm ± 1.2 at rest and 2.7 mm ± 1.2 under stress and in the average pubo-urethral angle of 13° ± 6.3° at rest and 8° ± 6.3° under stress between the two groups, suggesting that the success of trans-obturator sling placement decreases in proportion to the increase of the pubo-urethral distance and angle.

Tape position and outcome of suburethral sling

Ultrasound is superior to magnetic resonance in identifying implants, providing information about their position, mode of action and pathophysiology of complications (23). In fact, it is very helpful in the evaluation of women with suburethral slings' complications such as voiding dysfunction and urgency's symptoms, helping the surgeon to decide whether to cut a sling. In the case of suburethral slings, ultrasound enables precise localization of the tape position in relation to the urethra and other structures which is considered one of the most important factors determining surgical success. Several studies have shown that the the tape should be optimally placed between 50 and 75% of the urethral length, measured from the bladder neck to the external urethral meatus (24 - 27) in which there is the greater pressure area of the urethra (28). The worst results are obtained when a tape is placed under the proximal urethra, with the failure rate exceeding 50% (27 - 30). The role of tape position on success rate is very important when minisling were used to treat stress incontinence. Spelzini F et al (31) evaluated MiniArc efficacy considering the role of tape position along the urethral axis and the tip's position in relation to the obturator membranes. Women underwent perineal ultrasound examination by a combined 2D translabial and 3D transvaginal approach to assess bladder neck and tape mobility, tape position along the urethral axis, and tape anchorage. The Authors underlined that in 77 % of patients MiniArc didn't reach the obturator membrane on both sides. This feature affected significantly bladder neck mobility but not the efficacy of the procedure, suggesting that tape position seems to be the most important factor for success. Anyway, the relationship between tape position and the success rate is related to the procedure. There are differences in urethral morphology during straining and resting in women with TVT and those with TVT-O, regardless of tape procedure. An urethral compression effect of the slings may have an

important role in the continence mechanism (32). Anatomical position of the tape could modify therapeutic management when post-operative complications occur. To avoid long-term complications, Rautenberg et al. (33) performed early TVT mobilization in patients with postoperative voiding dysfunctions when the distance between the tape and the longitudinal smooth muscle layer of the urethra was < 3 mm and the Post-voiding residual (PVR) volume was > 100 ml. Normal voiding was restored in 96.7% of the patients and 95.1% of women were still continent at 6-month follow-up visits.

Post-voiding residual (PVR) volume

Postoperative urinary retention is a frequent consequence of gynecologic surgery, especially with surgical correction of urinary incontinence and pelvic organ prolapse (34, 35). Estimates of transient urinary retention after urinary incontinence and prolapse surgery range from 2.5%–24% reaching 43% after tension-free transvaginal sling placement (35, 36). A significant challenge in the diagnosis of POUR comes from the fact that there is no universal definition of urinary retention. When using the broader definition of "voiding dysfunction" to characterize postoperative bladder function, estimates are even higher, with a range of 39%–84% (37, 38). These higher rates include any transient voiding dysfunction that is documented in the postoperative period, as early as in the recovery room. During the post-operative period, bladder outlet obstruction contribute to the development of PVR. There is no evidence to define a threshold between normal and abnormal PVR values. Expert opinion has therefore been used to produce definitions of elevated PVR values (30 - 33), but unfortunately these differ from one another. Ultrasound provides an accurate estimate of post-voiding residual and it is recommended.

Sexual dysfunctions after urogynecological surgery

Female sexual dysfunctions such as disorders of desire, arousal, lubrication and orgasm, as well as dyspareunia are a common problem among the general population, expecially after urogynecological surgery (39). Although the literature has underlined the relationship between stress urinary incontinence and sexual dysfunctions, there were still few studies about sexual

function change after treatment of stress urinary incontinence. The fact that currently the incidence of sexual dysfunctions in patients with urinary incontinence or genital prolapse after surgery seemed to be reduced could depend on the better knowledge of the anatomic aspects of the clitoral urethral vaginal complex, and on the types of prostheses. Surgical techniques that perforate the paraurethral spaces to position suburethral slings could diminish sexual functioning because of scarring and reduced elasticity of the vaginal wall resulting in a reduced blood supply to the erectile tissues of the clitoris, as demonstrated by Caruso et al (40). It couldbe appropriate, as suggested by some authors, to use validated instruments that evaluate quality of life impact of urinary incontinence and women's sexual function such as the incontinence quality of life (I-QoL) questionnaire and the Female Sexual Function Index (FSFI) in order to investigate sexual function change after treatment of urinary incontinence (41).

CONCLUSIONS

Ultrasound imaging is now an essential tool in obstetrical gynecological discipline. In recent years, the improvement of image quality, the possibility of three-dimensional reconstructions and, above all, its being a dynamic examination have made ultrasound an integral part of the uro-gynecological assessment. Probably, for the pelvic reconstructive surgeon ultrasound adds information about the typical anatomical findings of stress urinary incontinence and allow to exclude a high residual urine or unexpected incidental pathology (1). On the contrary, in the treatment of incontinence, the use of ultrasound with a double meaning. First, ultrasound could be useful in the diagnostic analysis of the complications of surgical treatment of stress incontinence. Second, allowing anatomical identification of the benderella, causes the failure and / or the complication itself. It would be interesting to be able to have a real-time ultrasound examination during the treatment to improve the safety and effectiveness of the procedure.

Ultrasound and magnetic resonance imaging have already an important impact on clinical research and audit. Imaging techniques will very likely help us to further elucidate the etiology and

pathophysiology of pelvic floor dysfunction, assess the outcomes of conservative and surgical treatment, allowing the development of entirely new therapeutic concepts.

REFERENCES

1. Dietz HP. Pelvic floor ultrasound in incontinence: what's in it for the surgeon? Int Urogynecol J. 2011; 22: 1085-1097.
2. Medina CA, Costantini E, Petri E, Mourad S, Singla A, Rodríguez-Colorado S et al. Evaluation and surgery for stress urinary incontinence: A FIGO working group report. Neurourol Urodyn. 2017; 36:518-528.
3. Tubaro A, Vodušek BD, Amarenco G, et al. Imaging, neurophysiological testing and other tests. In: Abrams P, Cardozo L, Khoury S, Wein A eds. Incontinence, 5th edn. Health Publication, Paris. 2012; 507-621.
4. Norton P, Brubaker L. Urinary incontinence in women. Lancet. 2006; 367: 57–67.
5. Brandt FT, Albuquerque CD, Lorenzato FR, Lopes DS, da Cunha AS, da Costa RF. The value of transvulvar ultrasonography in the assessment of relevant anatomical parameters in the management of female stress urinary incontinence. Radio Bras. 2007; 40: 371–376.
6. Schaer GN, Koechli OR, Schuessler B, Haller U. Perineal ultrasound: determination of reliable examination procedures. Ultrasound Obstet Gynecol. 1996; 7: 347-352.
7. Meyer S, De Grandi P, Schreyer A, Caccia G. The assessment of bladder neck position and mobility in continent nullipara, mulitpara, forceps-delivered and incontinent women using perineal ultrasound: a future office procedure? Int Urogynecol J Pelvic Floor Dysfunct. 1996; 7: 138-146.
8. Chen GD, Su TH, Lin LY. Applicability of perineal sonography in anatomical evaluation of bladder neck in women with and without genuine stress incontinence. J Clin Ultrasound. 1997; 25: 189-194.
9. Bai SW, Chung KA, Rha KH, Kim SU, Kim SK, Park KH. Correlation between urodynamic test results, perineal ultrasound and degree of stress urinary incontinence. J Reprod Med. 2003; 48: 718-722.

10. Alper T, Cetinkaya M, Okutgen S, Kökçü A, Malatyalioğlu E. Evaluation of urethrovesical angle by ultrasound in women with and without urinary stress incontinence. Int Urogynecol J Pelvic Floor Dysfunct. 2001; 12:308-311.
11. Pregazzi R, Sartore A, Bortoli P, Grimaldi E, Troiano L, Guaschino S. Perineal ultrasound evaluation of urethral angle and bladder neck mobility in women with stress urinary incontinence. BJOG. 2002; 109: 821-827.
12. Sendag F, Vidinli H, Kazandi M, Itil IM, Askar N, Vidinli B et al. Role of perineal sonography in the evaluation of patients with stress urinary incontinence. Aust N Z J Obstet Gynaecol. 2003; 43: 54-57.
13. Peschers UM, Fanger G, Schaer GN, Vodusek DB, DeLancey JO, Schuessler B. Bladder neck mobility in continent nulliparous women. BJOG. 2001; 108: 320–324.
14. Brandt FT, Albuquerque CD, Lorenzato FR, Amaral FJ. Perineal assessment of urethrovesical junction mobility in young continent females. Int Urogynecol J Pelvic Floor Dysfunct. 2000; 11: 18–22.
15. Di Pietto L, Scaffa C, Torella M, Lambiase A, Cobellis L, Colacurci N. Perineal ultrasound in the study of urethral mobility: proposal of a normal physiological range. Int Urogynecol J. 2008; 19: 1405–1409.
16. Macotela-Nakagaki KA, del Puerto HS, Valente-Acosta B, Chabat-Manzanera P. Relationship between urinary incontinence and pelvic organ prolapse. Ginecol Obstet Méx. 2013; 81: 711–715.
17. Minardi D ,Piloni V ,Amadi A, El Asmar Z, Milanese G, Muzzonigro G. Correlation between urodynamics and perineal ultrasound in female patients with urinary incontinence. Neurourol Urodyn. 2007; 26: 176-182.
18. Dietz HP, Hansell NK, Grace ME, Eldridge AM, Clarke B, Martin NG. Bladder neck mobility is a heritable trait. BJOG. 2005; 112: 334-339.

19. Gehrich A, Stany MP, Fischer JR, Buller J, Zahn CM. Establishing a mean postvoid residual volume in asymptomatic perimenopausal and postmenopausal women. Obstet Gynecol. 2007; 110: 827-832.
20. Tseng LH, Liang CC, Chang YL, Lee SJ, Lloyd LK, Chen CK. Postvoid residual urine in women with stress incontinence. Neurourol Urodyn. 2008; 27: 48-51.
21. Chen L, Luo D, Yu X, Jin M, Cai W. Predicting stress urinary incontinence during pregnancy: combination of pelvic floor ultrasound parameters and clinical factors. Acta Obstet Gynecol Scand. 2018; doi: 10.1111/aogs.13368. [Epub ahead of print]
22. Torella M, De Franciscis P, Russo C, Gallo P, Grimaldi A, Ambrosio D et al. Stress urinary incontinence: usefulness of perineal ultrasound. Radiol Med. 2014; 119: 189-194.
23. Dietz HP, Wilson PD. The 'iris effect': how two-dimensional and three-dimensional ultrasound can help us understand anti-incontinence procedures. Ultrasound Obstet Gynecol. 2004; 23: 267-271.
24. Kociszewski J, Rautenberg O, Perucchini D, Eberhard J, Geissbühler V, Hilgers R et al. Tape functionality: sonographic tape characteristics and outcome after TVT incontinence surgery. Neurourol Urodyn. 2008; 27: 485-424.
25. Yang JM, Yang SH, Huang WC. Correlation of morphological alterations and functional impairment of the tension-free vaginal tape obturator procedure. J Urol. 2009; 181: 211-218.
26. Yang JM, Yang SH, Huang WC, Tzeng CR. Correlation of tape location and tension with surgical outcome after transobturator suburethral tape procedures. Ultrasound Obstet Gynecol. 2012; 39: 458-465.
27. Bogusiewicz M, Monist M, Gałczyński K, Woźniak M, Wieczorek AP, Rechberger T. Both the middle and distal sections of the urethra may be regarded as optimal targets for 'outside-in' transobturator tape placement. World J Urol. 2014; 32:1605-1611.

28. Westby M, Asmussen M, Ulmsten U. Location of maximum intraurethral pressure related to urogenital diaphragm in the female subject as studied by simultaneous urethrocystometry and voiding urethrocystography. Am J Obstet Gynecol. 1982; 144: 408-412.
29. Jiang YH, Wang CC, Chuang FC, Ke QS, Kuo HC. Positioning of a suburethral sling at the bladder neck is associated with a higher recurrence rate of stress urinary incontinence. J Ultrasound Med. 2013; 32: 239-245.
30. Bogusiewicz M, Monist M, Stankiewicz A, Woźniak M, Wieczorek AP, Rechberger T. Most of the patients with suburethral sling failure have tapes located outside the high-pressure zone of the urethra. Ginekol Pol. 2013; 84:334-338.
31. Spelzini F, Cesana MC, Verri D, Polizzi S, Frigerio M, Milani R. Three-dimensional ultrasound assessment and middle term efficacy of a single-incision sling. Int Urogynecol J. 2013; 24: 1391-1397.
32. Lin KL, Juan YS, Lo TS, Liu CM, Tsai EM, Long CY. Three-dimensional ultrasonographic assessment of compression effect on urethra following tension-free vaginal tape and transobturator tape procedures. Ultrasound Obstet Gynecol. 2012; 39: 452-790.
33. Rautenberg O, Kociszewski J, Welter J, Kuszka A, Eberhard J, Viereck V. Ultrasound and early tape mobilization – a practical solution for treating postoperative voiding dysfunction, Neurourol Urodyn. 2014; 33:1147-1151.
34. Buchko BL, Robinson LE. An evidence-based approach to decrease early postoperative urinary retention following urogynecologic surgery. Urol Nurs. 2012; 32: 260–264.
35. Dörflinger A, Monga A. Voiding dysfunction. Curr Opin Obstet Gynecol. 2001; 13: 507–512.
36. Partoll LM. Efficacy of tension-free vaginal tape with other pelvic reconstructive surgery. Am J Obstet Gynecol. 2002; 186: 1292–1295.

37. Foster RT, Borawski KM, South MM, Weidner AC, Webster GD, Amundsen CL. A randomized, controlled trial evaluating 2 techniques of postoperative bladder testing after transvaginal surgery. Am J Obstet Gynecol. 2007; 197: 627.e1–627.e4.
38. Geller EJ, Hankins KJ, Parnell BA, Robinson BL, Dunivan GC. Diagnostic accuracy of retrograde and spontaneous voiding trials for postoperative voiding dysfunction: a randomized controlled trial. Obstet Gynecol. 2011; 118: 637–642.
39. Laumann EO, Paik A, Rosen RC. Sexual dysfunction in the United States: prevalence and predictors. JAMA 1999;281:537–544.
40. Caruso S, Bandiera S, Cavallaro A, Cianci S, Vitale SG, Rugolo S. Quality of life and sexual changes after double transobturator tension-free approach to treat severe cystocele. Eur J Obstet Gynecol Reprod Biol. 2010;151:106-109.
41. Vitale SG, La Rosa VL, Rapisarda AMC, Laganà AS. Sexual Life in Women with Stress Urinary Incontinence. Oman Med J. 2017;32:174-175.

NOTES

Conflicts of interest.— The authors certify that there is no conflict of interest with any financial organization regarding the material discussed in the manuscript.

Authors' contributions.— All authors wrote, read and approved the final draft of the paper.

TABLES

Table I.— Sensitivity, specificity and positive predictive value of the ultrasound parameters related to SUI.

Authors	N	Desease	Parameters	NVP	Sensitivity (%)	Specificity (%)	PPV
Scaher et al., 1996 (6)	60 SUI		Distance Dx,Dy PUVA[a]	≤ 10 mm 90-110°	NE	NE	NE
Meyer et al., 1996 (7)	32 SUI 74 continent nulliparous		Dx Dy	>14 mm >12 mm	78 75	89 85	
Chen et al., 1997 (8)	37 SUI 65 controls	SUI	RA (Rotational angle) DBN (Descent of bladder neck) RA+DBN	≤ 28 < 13mm	73 73 62,2	76,9 76,9 83,1	64,3 64,3 67,6
Bai et al., 2003 (9)	90 SUI 38 controls	SUI	BSD[b]	≤ 13,6 mm	68,8	54,1	73,8
Alper et al., 2001 (10)	50 SUI 50 controls	SUI	Δ-PUVA	≤ 8°	44	88	78
Pregazzi et al., 2002 (11)	33 SUI 50 controls	UI	Bladder-sympysis distance Angle β[c]	≤ 26 mm ≤ 14°	87 96	68 92	55 85
Sendag et al., 2003 (12)	30 SUI 17 controls	SUI	PUVA[a] Desensus diameter	> 120° > 15 mm	53 96	100 85	100 90,6
Dietz, 2011 (1)	106 continent nulliparous		BSD[b]	17 mm (median)	NE	NE	NE
Peschers et al., 2001 (13)	39 continent nulliparous		Dx, Dy	15 mm (median)	NE	NE	NE
Brandt et al., 2000 (14)	40 continent nulliparous		BSD[b]	5,3 mm (median)	NE	NE	NE

Table note: NVP: normal value proposed; PPV: positive predicitive value; NE: not evaluated. aPUVA: posterior urethrovescical angle bBSD: descent of bladder-symphysis distance cangle β: urethral angle (between proximal and distal ends of urethra).

Table II.— . Proposal of a normal physiological range of Pubic-urethra distance and Urethral axis inclination angle.

	Pubic-urethra distance under stress (mm)	Urethral axis inclination angle under stress (°)
Patients cured following TVT-O	10-15	60-100
Patients with persistent SUI after TVT-O.	15-18	80-120

TITLES OF FIGURES

Figure 1.— schematic representation of imaging obtained using perineal ultrasound.

Figure 2.— schematic representation of pubo-urethral distance (RED LINE), pubo-urethral angle (GREEN LINE) and posterior urethrovescical angle (ORANGE LINE). P: Pubic bone. B: Bladder. U: Urethra.

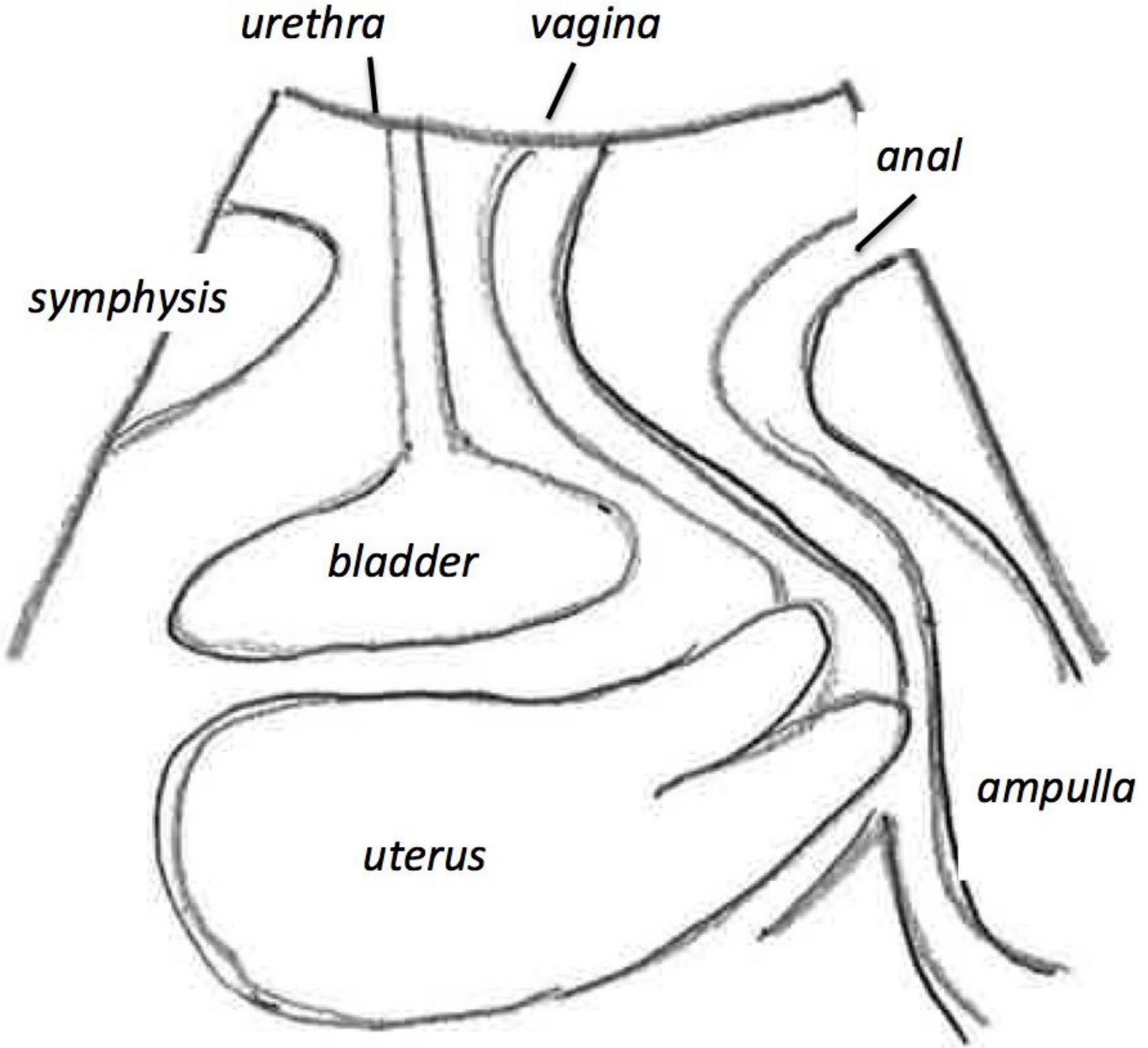
urethra
vagina
anal
symphysis
bladder
ampulla
uterus

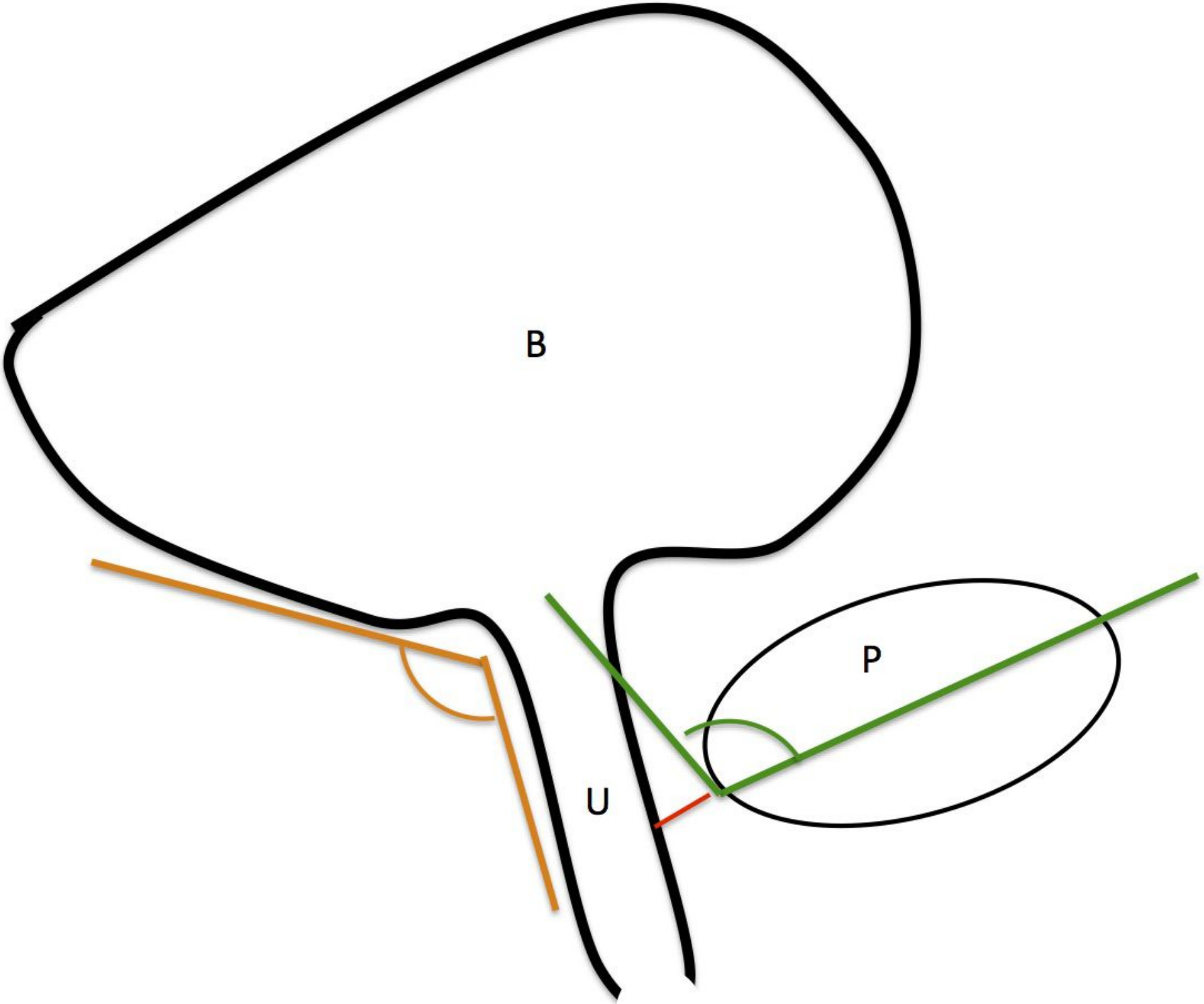
B
P
U