

Jellyfish in the Heart

Maria Dieli, MD; Caterina Simon, MD; Antonio Brucato, MD; Patrizia Pedrotti, MD; Tiziano Colombo, MD; Antonella Moreo, MD; Giorgio Fasolini, MD; Mauro Gori, MD; Andrea Gianatti, MD; Giuseppe Medolago, MD; Paolo Ferrazzi, MD

A 41-year-old man with a partially cystic cardiac mass was referred to our institutions. About 17 years previously, he had undergone the excision of a lipoma in the left popliteal region. The patient had been well until 3 to 4 months earlier, when dyspnea on exertion developed.

Two-dimensional echocardiography (Figure 1A and 1B), computed tomography (Figure 2A and 2B), and magnetic resonance imaging (Figure 3A and 3B and Movies I–3 in the online-only Data Supplement) displayed a patchy lobulated epicardial mass (transversal diameter, 7 cm; thickness, 4 cm) near the left cardiophrenic angle, partially occupying the left ventricular chamber.

Cardiac catheterization showed dislocation of the left anterior descending artery by the mass without a significant coronary stenosis.

A review of his medical history revealed that the tumor resected in the popliteal region was actually a myxoid liposarcoma. Whole-body positron emission tomography revealed only a mild myocardial uptake, and a gated myocardial perfusion single-photon emission computed tomography (Figure 4 and Movies IV and V in the online-only Data Supplement) showed a perfusion defect in the myocardial area occupied by the mass. Surgical resection of the mass was judged technically feasible, so the patient underwent surgery (Figure 5A and 5B).

First, the left phrenic nerve was dissected from the pericardium via an intrapleural approach, and then dissection of the mass was started with an incision of the pericardium around the mass. The epicardial fat above the left descending anterior coronary artery was dissected, and the mass was separated

from the epicardial surface of the heart. Extracorporeal circulation was then started. A cleavage plane was found, and the mass was resected up to the base of the posterior papillary muscle, which was partially reimplanted. The hole in the left ventricular wall was closed by a Dacron patch (2.5 × 3 cm). The histopathological analysis of the tumor, which macroscopically resembled a jellyfish (Figure 5B), revealed a low-grade myxoid liposarcoma (Figure 6).

The postoperative course was uneventful, and the patient was discharged after 12 days.

The patient presented 8 months later with disease progression (heart, mediastinum, pleura), so chemotherapy with trabectedin was begun and is still ongoing 1 year after surgical treatment.

Liposarcoma is the most common soft-tissue sarcoma; the myxoid subtype is the most prevalent and the least aggressive. These tumors arise more commonly in the lower extremities and have an indolent course, with high disease-free survival rates when appropriate surgical resection with or without radiotherapy is performed.¹ Histological grade remains the most important prognostic factor. Myxoid tumors tend to metastasize to extrapulmonary and unusual sites, with an overall rate of 14.5% at 5 years and 15.3% at 10 years¹; the time to distant metastases may vary from 3 to 73 months.² Definitive differentiation between metastatic disease and metachronous primary disease is often elusive. Primary cardiac sarcoma has a worse prognosis compared with secondary tumors, with a median overall survival of 6 versus 93 months in a series³; median survival is significantly better for patients suitable for

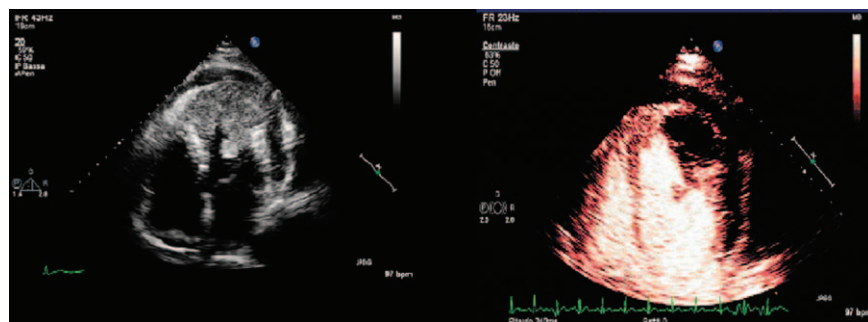


Figure 1. Echocardiography. Apical 4-chamber view showing a large cardiac mass infiltrating the apex, lateral, and anterior walls of the left ventricle. A second small cardiac mass is attached to the left wall; presence of pericardial effusion. Contrast-enhanced ultrasound shows the large infiltrative cardiac mass. Inside the mass are large nodular, nonperfused or hypoperfused areas surrounded by vascularized nonmyocardial tissue infiltrating the normal myocardium.

Departments of Internal Medicine (M.D., A.B.), Cardiovascular Surgery (C.S., P.F.), Radiology (G.F.), Cardiology (M.G.), Pathology (A.G.), and Nuclear Medicine (G.M.), Ospedale Papa Giovanni XXIII (previously named Ospedali Riuniti), Bergamo, Italy, and CRM Unit Cardiology Department (P.P.), Cardiovascular Surgery, (T.C.), and Cardiology (A.M.), Ospedale Niguarda Ca'Granda, Milano, Italy.

The online-only Data Supplement is available with this article at <http://circ.ahajournals.org/lookup/suppl/doi:10.1161/CIRCULATIONAHA.112.116848/-/DC1>.

Correspondence to Antonio Brucato, MD, Ospedale Papa Giovanni XXIII, Piazza OMS 1, 24127 Bergamo. E-mail albrucato@hpg23.it

(*Circulation*. 2013;127:e443-445.)

© 2013 American Heart Association, Inc.

Circulation is available at <http://circ.ahajournals.org>

DOI: 10.1161/CIRCULATIONAHA.112.116848

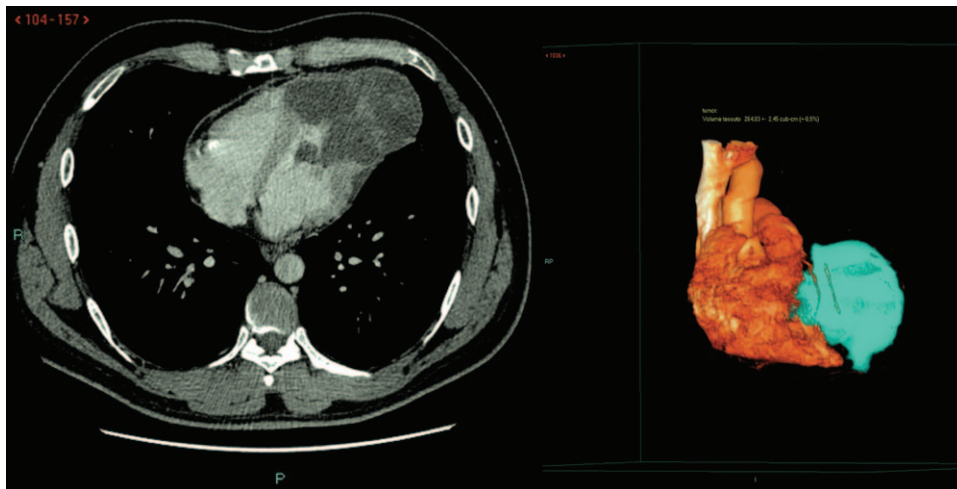


Figure 2. Multislice computed tomography axial image of the mass projecting inside the left ventricle. Volume-rendering technique reconstruction on a coronal plane showing the mass in green and the ventricle in red.

surgery,^{3,4} which remains the best therapeutic option, even if most patients eventually die of widespread disease. Few anecdotal reports have been published on cardiac myxoid liposarcomas, so the role of adjuvant therapy (radiotherapy or chemotherapy) still needs to be defined. Chemotherapy is indicated in extensive disease. Anthracyclines and ifosfamide are the agents of choice, but recently the novel agent trabectedin has proved to have special antitumor activity in myxoid liposarcoma.

Disclosures

None.

References

1. Pearlstone DB, Pisters PW, Bold RJ, Feig BW, Hunt KK, Yasko AW, Patel S, Pollack A, Benjam in RS, Pollock RE. Patterns of recurrence in extremity liposarcoma: implications for staging and follow-up. *Cancer*. 1999;85:85–92.
2. Fiore M, Grosso F, Lo Vullo S, Pennacchioli E, Stacchiotti S, Ferrari A, Collini P, Lozza L, Mariani L, Casali PG, Gronchi A. Myxoid/round cell and pleomorphic liposarcomas: prognostic factors and survival in a series of patients treated at a single institution. *Cancer*. 2007;109:2522–2531.
3. Hamidi M, Moody JS, Weigel TL, Kozak KR. Primary cardiac sarcoma. *Ann Thorac Surg*. 2010;90:176–181.
4. Truong PT, Jones SO, Martens B, Alexander C, Paquette M, Joe H, Hart J, Allan SJ. Treatment and outcomes in adult patients with primary cardiac sarcoma: the British Columbia Cancer Agency experience. *Ann Surg Oncol*. 2009;16:3358–3365.

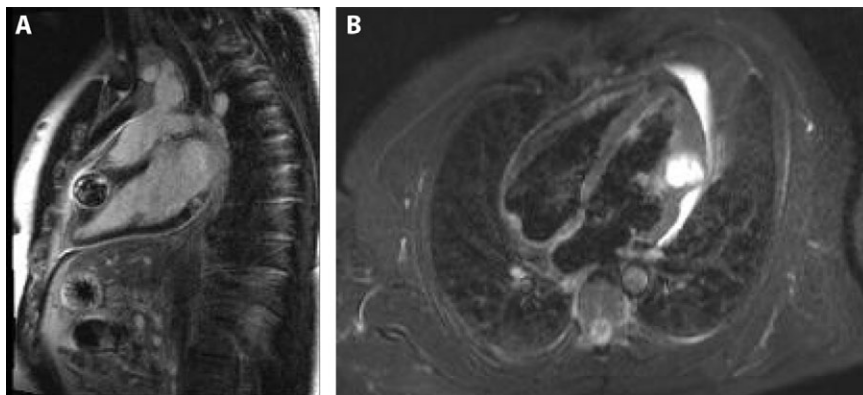


Figure 3. Magnetic resonance imaging (2-chamber off-axis view, **A** and 4-chamber off-axis view, **B**). The mass, expanding from the wall to the cavity of the left ventricle, is hyperintense on T2–Short Tau Inversion Recovery sequences (**B**) because of the myxoid component and presents inhomogeneous late enhancement that extends to the pericardium on post-contrast images (**A**).

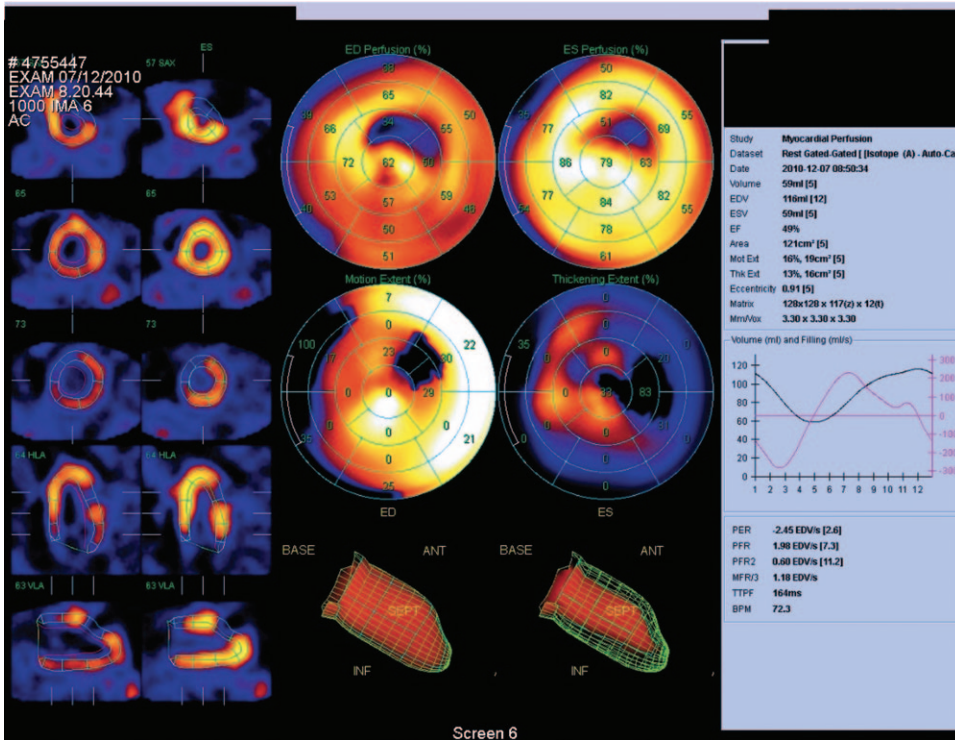


Figure 4. Single-photon emission computed tomographic images (short axis, vertical long axis, horizontal long axis) demonstrate a severe transmurular (no viable myocardium) perfusion defect involving the following akinetic segments with absent systolic thickening: apical anterior, apical septal, and apex, and a moderate nontransmurular (viable myocardium) perfusion defect of a medium anterolateral normokinetic segment in the distribution territory of left descending coronary artery.

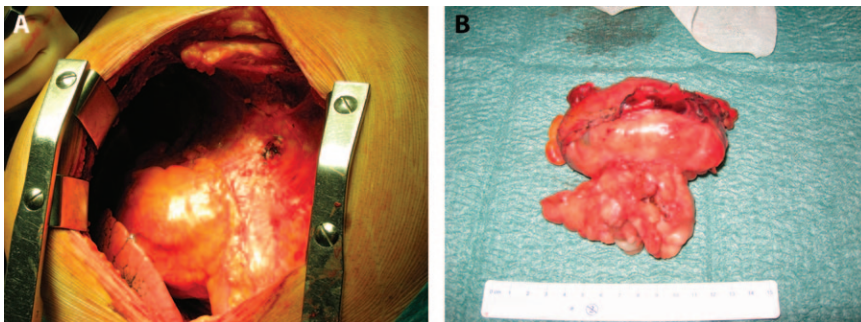


Figure 5. Macroscopic view of the mass after thoracotomy (A) and at the end of surgery (B).

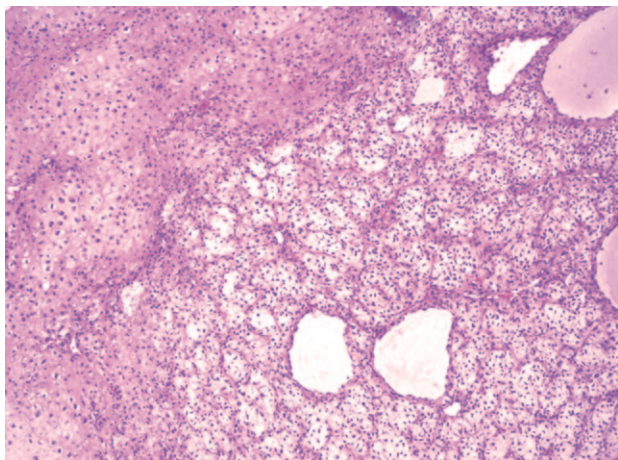


Figure 6. Low-power image of a myxoid liposarcoma that contains a multinodular proliferation of fusiform and round cells suspended in a myxoid matrix, creating a lace-like pattern with contiguous cartilaginous differentiation (hematoxylin-eosin stain; magnification x50).