

## Severe Hypertension in Childhood Due to Prolonged Skin Application of a Mineralocorticoid Ointment

ANTONIO BARTORELLI AND ANDREA RIMONDINI

**SUMMARY** We report the case of a 9-year-old boy suffering from exzematous dermatitis who was treated for 6 years with a daily dose of 100 mg of a dermatological ointment containing 9 $\alpha$ -fluoroprednisolone-21-acetate. At examination the patient's blood pressure was persistently 230/160 mm Hg and was considered essential in origin after secondary forms of arterial hypertension had been excluded. Treatment with nifedipine and labetalol lowered the blood pressure to 150/100 mm Hg. When we became aware of the dermatological treatment, we advised its discontinuance. In the subsequent 7 days, the blood pressure fell to hypotensive levels (75/40 mm Hg) and then became normal a few days after discontinuance of the antihypertensive therapy. This case suggests that prolonged use of topical steroids, commonly prescribed for skin diseases, may cause hypertension, especially in childhood. (Hypertension 6: 586-588, 1984)

**KEY WORDS** • topical mineralocorticoids • 9 $\alpha$ -fluoroprednisolone-21-acetate • hypertension in childhood

**V**ARIOUS agents such as drugs, poisons, and food can induce hypertension by interfering with mechanisms that regulate arterial pressure.<sup>1,2</sup> Mineralocorticoid administration elevates blood pressure through retention of sodium.<sup>3-5</sup> We report a case in which severe hypertension resulted from prolonged application of a dermatological ointment containing a potent mineralocorticoid.

### Case Report

A 9-year-old boy was admitted to our Hypertension Unit in June, 1981, because of severe hypertension. Blood pressure had first been found elevated (240/140 mm Hg) 4 months earlier during a routine medical examination. There was no family history of hypertension. Childhood diseases had included measles, rubella, and chicken pox, all of which had followed a benign course. A twin brother had been operated on successfully for a medulloblastoma of the cerebellum.

### Examination

On admission, the patient had a blood pressure of 230/160 mm Hg supine and 220/160 mm Hg upright

with no differences between measurements of the upper and lower parts of the body. The patient was asymptomatic, and physical examination was normal except for a cardiac gallop rhythm. Electrocardiography (ECG) showed voltage changes due to ventricular hypertrophy and mild repolarization abnormalities; Grade II hypertension retinopathy was evident. Laboratory tests documented normal renal function and moderate hypokalemia; plasma and urine catecholamine and aldosterone concentrations and plasma renin activity were normal (Table 1). Angiography ruled out renal artery stenosis and coarctation of the aorta.

TABLE 1. Laboratory Findings

Laboratory study	Values	Normal range*
Serum potassium	3.0 mEq/liter	(3.5-5)
Plasma aldosterone		
supine	75 pg/ml	(12-125)
upright	130 pg/ml	(70-295)
Urinary aldosterone	9.3 $\mu$ g/24 hr	(5-15)
Plasma renin activity		
supine	0.27 ng·ml <sup>-1</sup> ·hr <sup>-1</sup>	(0.16-0.66)
upright	0.95 ng·ml <sup>-1</sup> ·hr <sup>-1</sup>	(0.73-2.13)
Plasma norepinephrine	0.263 $\mu$ g/liter	(0.12-0.28)
Plasma epinephrine	0.075 $\mu$ g/liter	(0.03-0.08)
Urinary catecholamine	74 $\mu$ g/24 hr	(10-80)

\*Normal range in our laboratory.

From the Istituto di Ricerche Cardiovascolari "Giorgio Sisini," Centro Ricerche Cardiovascolari del Consiglio Nazionale delle Ricerche, Cattedra di Cardiologia, University of Milan, Milan, Italy.

Address for reprints: Antonio Bartorelli, M.D., Istituto di Ricerche Cardiovascolari, Via Bonfadini 214, 20138 Milan, Italy.

Received July 20, 1983; revision accepted December 22, 1983.

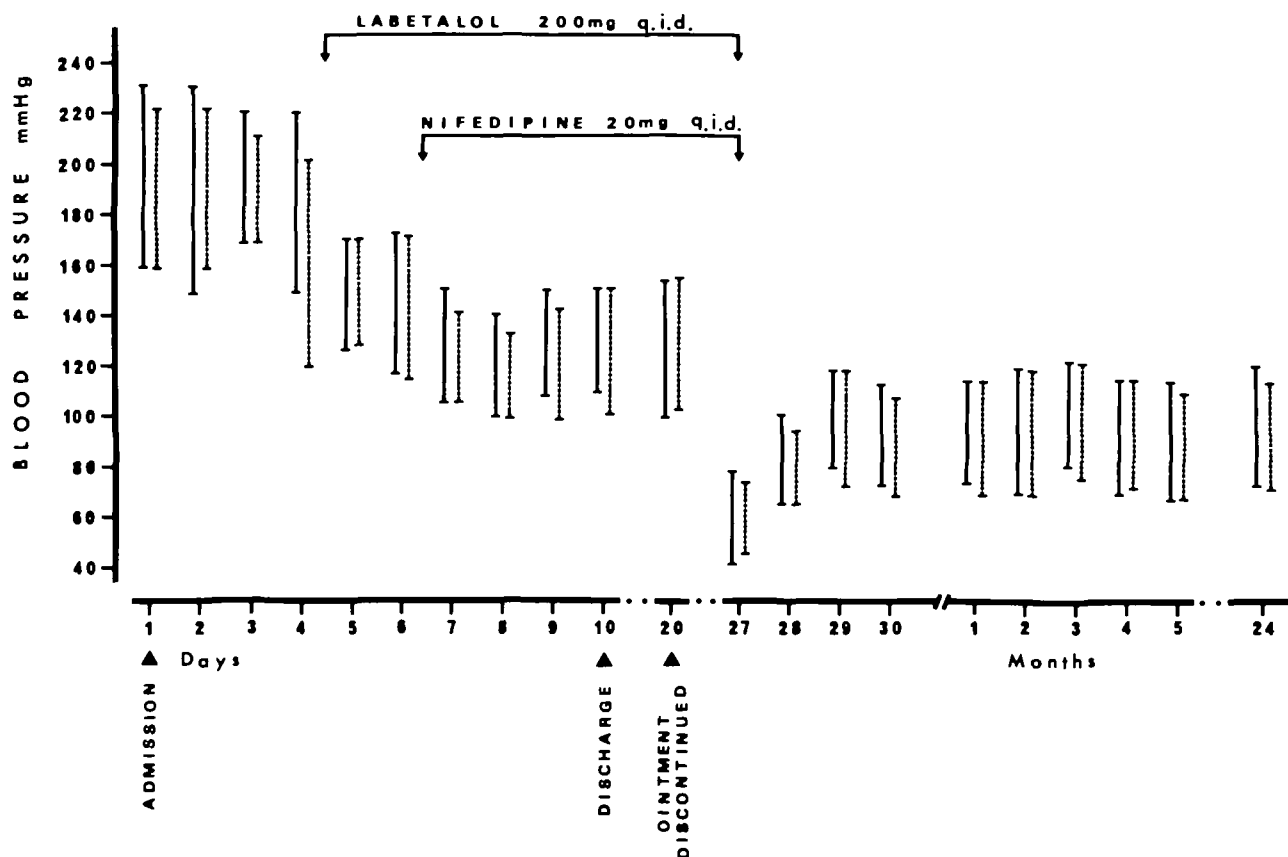


FIGURE 1. Supine (solid lines) and upright (dotted lines) systolic and diastolic blood pressure levels in the untreated condition, under labetalol plus nifedipine treatment, and during the 2-year follow-up after discontinuance of the ointment and antihypertensive drug.

### Treatment

The patient was treated first with an alpha- and beta-blocking agent (labetalol, 200 mg four times daily), which was partially effective. Subsequently, labetalol was combined with a calcium-channel-blocking agent (nifedipine, 20 mg four times daily), which lowered the supine and upright blood pressures to 150/100 mm Hg (Figure 1).

### Course

The patient was discharged from the hospital under this therapeutic regimen. When he returned to our Hypertension Unit 10 days later for a periodic check-up, we noticed eczematous lesions on the forehead. The mother said that these lesions reappeared whenever administration of a skin ointment was discontinued. She also reported that these lesions had been evident a few weeks after birth and were diagnosed as atopic eczematous dermatitis of the legs, arms, and face. When her son was 3 years old, a physician prescribed a dermatological ointment to alleviate his itching and scratching. The eczematous lesions and pruritus regressed afterward but returned within a few days after discontinuance of the treatment. The mother had therefore continued to spread the ointment on the child's skin and rubbed it over nearly the entire surface of the body until completely absorbed.

The compound was found to contain a potent mineralocorticoid (9 $\alpha$ -fluoroprednisolone-21-acetate) in the concentration of 10 mg per gram; it was formulated as an ointment in a greasy, water-insoluble base. We estimated that this child had received approximately 100 mg of the fluorinated steroid per day during the previous 6 years. We suspected that the ointment was related to the blood pressure elevation and immediately discontinued it while maintaining antihypertensive therapy.

After 7 days, the patient returned complaining of dizziness and lightheadedness, and faintness during exercise. Blood pressure was found to be 75/40 mm Hg when the patient was both supine and upright. Antihypertensive treatment was immediately discontinued, and the blood pressure returned to normal within a few days (Figure 1).

During the last 24 months, the blood pressure has remained 120/80 mm Hg without any treatment; fundi and electrocardiogram have reverted to normal.

### Discussion

Since 1952 when Sulzberger and Witten<sup>6</sup> reported the beneficial effects of cortisol on skin lesions, corticosteroids in topical preparations have gained in popu-

larity. Although they may be regarded as the most commonly prescribed preparations for treatment of skin diseases,<sup>7</sup> little attention has been devoted to their potential systemic effects. Accumulated evidence,<sup>8-12</sup> however, indicates that topically administered steroids can be absorbed through the skin and that the risk of serious systemic effects exists when high doses are used for long periods of time over large areas of the body. The magnitude of percutaneous absorption is related mainly to the concentration and potency of the drug, the severity of the dermatitis, the frequency, method, and extent of application, and the vehicle used.<sup>13</sup> Ointments are very effective since they form an occlusive layer, which increases the hydration of the stratum corneum epidermidis and, consequently, the penetration of the active constituent. Adverse effects observed with highly potent topical mineralocorticoids include suppression of pituitary-adrenal function,<sup>13-16</sup> development of Cushing's syndrome,<sup>17-20</sup> and changes in urinary electrolyte excretion and urine volume, sodium retention, and edema.<sup>14-21, 22</sup> Blood pressure elevation has been associated with hypokalemia, alkalosis, suppressed plasma renin activity, and low aldosterone plasma levels in cases of habitual use of large doses of nasal drops containing 9 $\alpha$ -fluoroprednisolone.<sup>23-25</sup>

There is little doubt that the hypertension in this case was caused by the topical mineralocorticoid. Family history was negative, laboratory and angiographic studies excluded secondary forms of hypertension, and ointment discontinuance promptly resulted in symptomatic hypotension followed by normal blood pressure when antihypertensive treatment was withdrawn. Failure to find depressed plasma renin activity, which would have been predictable, is not fully understood given the available data. However, it may have been that the plasma renin activity was considered normal when indeed it reflected suppression of renin secretion, as suggested by the finding during follow-up of renin levels consistently exceeding those detected before ointment discontinuance. Apart from the potency and high dosage of the mineralocorticoid, which was applied for a long period of time over large areas of the body, the age of the patient may have played an important role. Compared with adults and in relation to body weight, children have a greater proportion of body surface area and a relatively thinner skin. Their absorption of drugs through the skin may be enhanced as is the likelihood of the development of systemic effects.

This case emphasizes that the medical history should be accurate and detailed and should include specific inquiries concerning use of skin ointments containing powerful fluorinated steroids. This case also emphasizes the need to carefully monitor patients under prolonged treatment with topical preparations containing fluorinated steroids; this may be particularly true in childhood.

## References

- Messerli FH. Chemically induced disorders of arterial pressure. *Pract Card* 1982;8:107-114
- Messerli FH, Frohlich ED. High blood pressure, a side effect of drugs, poisons and food. *Arch Intern Med* 1979;139:682-637
- Biglieri EG, Stockigt JR. Adrenal mineralocorticoids causing hypertension. *Am J Med* 1972;52:623-632
- Chobanian AV, Voicer L, Tifft CP, Gavras H, Liang C, Faxon D. Mineralocorticoid-induced hypertension in patients with orthostatic hypotension. *N Engl J Med* 1979;301:68-73
- Monteleone JA. Hypertensive encephalopathy with overdosage of desoxycorticosterone. *Pediatrics* 1969;43:294-295
- Sulzberger MB, Witten VH. Effects of topically applied compound F in selected dermatoses. *J Invest Dermatol* 1952;19:101-102
- Miller JA, Munro DD. Topical corticosteroids: clinical pharmacology and therapeutic use. *Drugs* 1980;19:119-133
- Scott A, Kalz F. Penetration and distribution of C14-hydrocortisone in human skin after its topical application. *J Invest Dermatol* 1956;26:149-158
- Malkinson FD, Ferguson EH. Percutaneous absorption of hydrocortisone-4-C14 in 2 human subjects. *J Invest Dermatol* 1955;25:281-283
- Malkinson FD, Ferguson EH, Wang MC. Percutaneous absorption of cortisone-4-C14 through normal human skin. *J Invest Dermatol* 1957;28:211-216
- Malkinson FD. Studies on percutaneous absorption of C14-labeled steroids by use of gas-flow cell. *J Invest Dermatol* 1958;31:19-28
- Malkinson FD, Kirschenbaum MB. Percutaneous absorption of C14-labeled triamcinolone acetonide. *Arch Dermatol* 1963;88:427-439
- Carruthers JA, August PJ, Staughton RCD. Observation on the systemic effect of topical clobetasol propionate (Dermovate). *Br Med J* 1975;4:203-204
- Scoggins RB, Kliman B. Percutaneous absorption of corticosteroids. *N Engl J Med* 1965;273:831-840
- Gill KA, Baxter DL. Plasma cortisol suppression by steroid creams. *Arch Dermatol* 1964;89:734-740
- Lehner T, Lyne C. Adrenal function during topical oral corticosteroid treatment. *Br Med J* 1969;4:138-141
- Nilsson JE, Lennart JC. Systemic effects of local treatment with high doses of potent corticosteroids in psoriatics. *Acta Derm Venerol* 1979;59:245-248
- Staughton RCD, August PJ. Cushing's syndrome and pituitary-adrenal suppression due to clobetasol propionate. *Br Med J* 1975;2:419-421
- Keipert J, Kelly R. Temporary Cushing's syndrome from percutaneous absorption of betamethasone 17-valerate. *Med J Aust* 1971;1:542-544
- Nilsson JE. Cushing's syndrome induced by betamethasone 17-valerate. Case demonstrations. Presented at the 21st Nordiske Dermatolog Kongress, Aarhus, Norway, 1977
- Fitzpatrick TB, Griswold HC, Hicks JH. Sodium retention and edema from percutaneous absorption of fludrocortisone acetate. *JAMA* 1955;158:1149-1152
- Livingood CS, Hildebrand JF, Key JS, Smith RW. Studies on the percutaneous absorption of fludrocortisone. *Arch Dermatol* 1955;72:313-327
- Armbruster H, Vetter W, Reck G, Beckerhoff R, Siegenthaler W. Severe arterial hypertension caused by chronic abuse of a topical mineralocorticoid. *Int J Clin Pharmacol Ther Toxicol* 1975;12:170-173
- Mantero F, Armanini D, Opocher G, et al. Mineralocorticoid hypertension due to a nasal spray containing 9-alpha-fluoroprednisolone. *Am J Med* 1981;71:352-357
- Ghione S, Clerico A, Fommei E, Cocci F, Bartolomei G, Riccioni N. Hypertension and hypokalemia caused by 9-alpha-fluoroprednisolone in a nasal spray. *Lancet* 1979; 1:1301