



## Medical Imagery

## Haemoptysis and fever in a young refugee from Somalia



## ARTICLE INFO

## Article history:

Received 10 September 2018

Received in revised form 2 October 2018

Accepted 4 October 2018

**Corresponding Editor:** Eskild Petersen,

Aarhus, Denmark

Keywords:

Haemoptysis

Bronchoscopy

Tuberculosis

EUS-B-FNA

Migration

A 19-year-old Somali man, who had crossed the Mediterranean Sea from Libya 4 months before, was admitted to hospital complaining of a 1-month history of fever and mild haemoptysis. Radiological examinations showed a lung nodule in the left lower lobe and necrotic hilar and mediastinal lymphadenopathy (Figure 1A–D). Bronchoscopy revealed left bronchial stenosis with endobronchial lesions caused by compression from an enlarged lymph node (Figure 1E). Endobronchial biopsies and bronchial washing were performed. Due to the patient's persistent coughing, ultrasound-guided transbronchial needle aspiration was not performed. Instead, an echo-bronchoscope was introduced into the oesophagus. An endoscopic ultrasound (with bronchoscope) fine needle aspiration (EUS-B-FNA) of a subcarinal lymph node showing a heterogeneous echo-structure was performed (Figure 1F).

Smear microscopy of the bronchial washing was negative; however, Xpert MTB/RIF was positive for rifampicin-susceptible *Mycobacterium tuberculosis* complex (MTC), later confirmed by liquid culture results. Bronchial biopsies and node aspirates showed necrotizing granulomas (Figure 2A, B). Only needle aspirate smear microscopy and nested PCR were positive. Ziehl–Neelsen staining was used for smear microscopy of every sample collected.

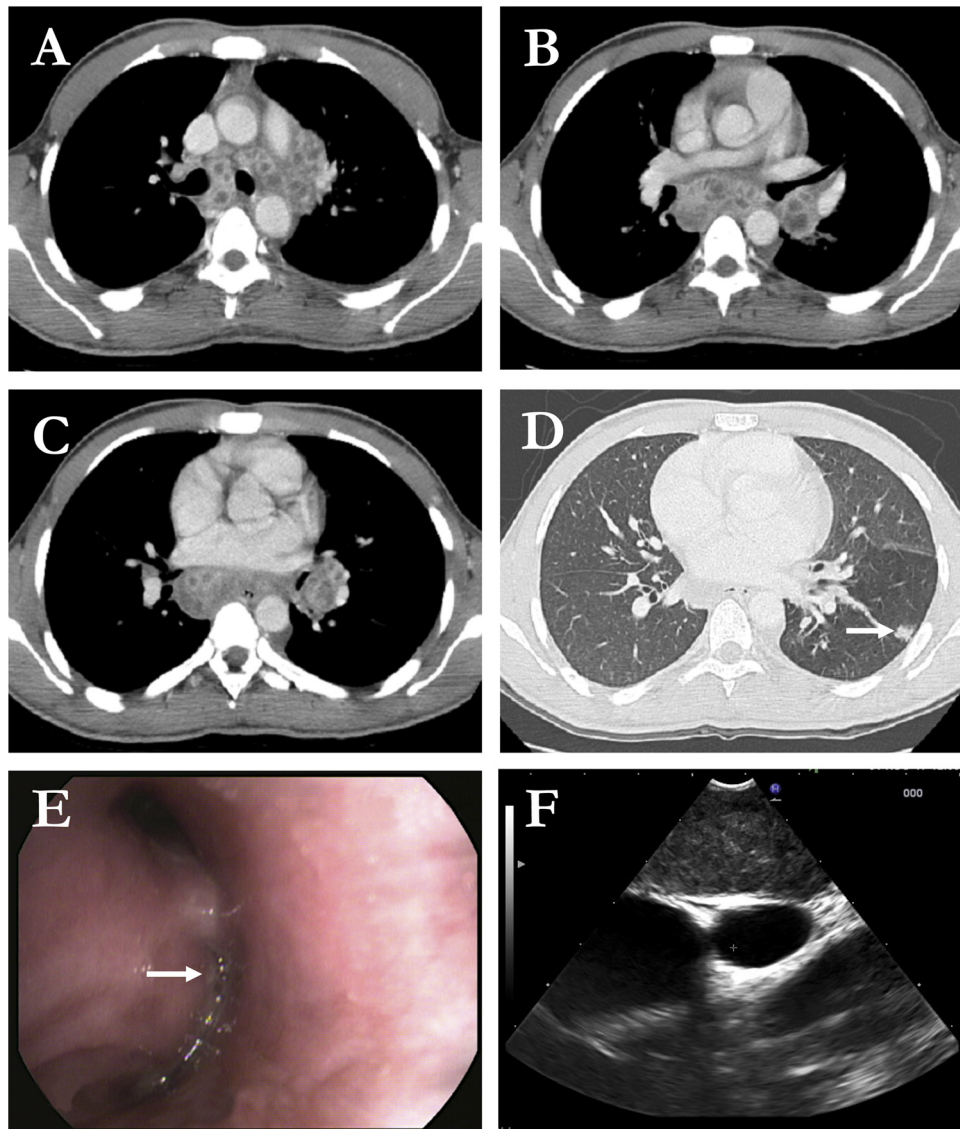
The patient started the World Health Organization (WHO) recommended standardized regimen (i.e., daily isoniazid (H), rifampicin (R), ethambutol, and pyrazinamide for 2 months, and HR for 4 months) with clinical improvement (Nahid et al., 2016). A bronchoscopy performed at the end of the treatment showed complete recovery with bronchial patency and a white scar in the left lower lobe (Figure 2C, D). A collected bronchial washing specimen was negative (smear microscopy, Xpert MTB/RIF, and culture).

This is a representative case of tuberculosis (TB) diagnosed in a low TB incidence country during a time period of intensified migration flow from Africa to Europe. In recent years, TB in migrants has represented a major public health challenge for low TB incidence countries such as Italy (Lönnroth et al., 2017; Sotgiu et al., 2017a). Incidence rates in foreign-born populations coming from high TB burden areas (e.g., Somalia) are higher than those recorded in the native European population; furthermore, migrants show a higher probability of developing the disease from latent TB infection acquired in the country of origin or on the route to Europe (Sotgiu et al., 2017a; Walker et al., 2018).

Migrants from high TB incidence countries (e.g., Somalia) are medically screened on arrival in Italy. Physical examination and tuberculin skin testing are performed routinely. In the case of a suspicion of active TB disease, radiological and microbiological tests are prescribed to rule out TB disease. In asymptomatic patients with a positive tuberculin skin test, therapy for latent TB infection is offered following WHO guidelines on the programmatic management of latent TB infection.

The patient arrived in Italy in March 2017, but reliable information on his health status was only available when he arrived at a refugee hospitality centre in Milan in June 2017. The completed symptom-based questionnaire was negative and tuberculin skin test was positive. The administration of the therapy for latent TB infection was scheduled for August 2017, but the patient was admitted to hospital complaining of a 1-month history of fever and haemoptysis in the same month.

Active TB is an uncommon cause of haemoptysis in Italy, but represents an important bleeding aetiology in high TB incidence countries (Mondoni et al., 2018). Patients with haemoptysis from these areas should be screened promptly for the disease and a

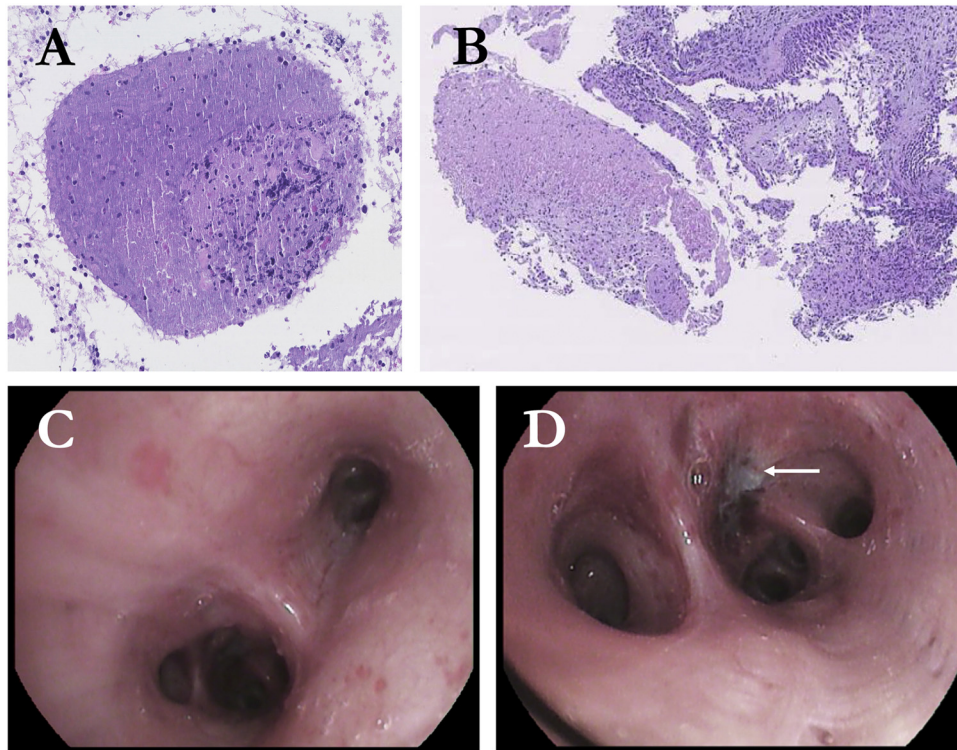


**Figure 1.** Computed tomography scan showing necrotic mediastinal and hilar lymph nodes (A–C) and a small parenchymal lung nodule (arrow) in the left lower lobe (D). (E) Bronchoscopy showing a broadening of the left interlobar carina with marked stenosis of the ostium of both the superior and inferior lobar bronchi due to extrinsic compression from an enlarged hilar lymph node; the mucosal surface is covered by a subtle layer of scattered rice-like white nodules (arrow). (F) Enlarged subcarinal lymph node with a heterogeneous echo-structure detected during endoscopic ultrasound with the bronchoscope (EUS-B).

bronchoscopy should be considered to exclude endobronchial tuberculosis (EBTB) (Mondoni et al., 2017). EBTB is a rare disease form involving the tracheobronchial tree; TB lymphadenitis is the most frequent extrapulmonary disease form. Both conditions may occur without any clinically significant parenchymal involvement (Mondoni et al., 2017). Furthermore, extrapulmonary TB (particularly lymphatic) is more incident in African patients (Sotgiu et al., 2017b).

Bronchoscopy is crucial to collect biological samples in the case of sputum negative/scarce patients, in the case of

suspected EBTB, to exclude severe complications (i.e., atelectasis, obstructive pneumonia, etc.), and in sampling mediastinal lymph nodes (Mondoni et al., 2017). As demonstrated for other diseases, the association of endoscopic sampling techniques increases the diagnostic yield of bronchoscopy (Mondoni et al., 2015a). In the case of enlarged mediastinal lymph nodes, EUS-B-FNA is an accurate and safe technique when the transbronchial approach is poorly tolerated (Dhooria et al., 2015; Mondoni et al., 2015b).



**Figure 2.** Haematoxylin and eosin staining of EUS-B needle aspirate (A) showing necrotic tissue with scant cellular debris and histiocytic infiltrate, and bronchial biopsy (B) showing well formed histioid necrotizing granulomas. Bronchoscopic view of the complete recovery, with bronchial patency after therapy (C), and a small white scar in the bronchial mucosa (arrow) of the left lower lobe (D).

### Funding sources

This research did not receive any specific grant from funding agencies in the public, commercial, or not-for-profit sectors.

### Ethical approval

According to Italian laws, ethical approval from the local institutional review board was not required.

### Conflict of interest

The authors declare that they do not have any conflict of interest.

### References

Dhooria S, Aggarwal AN, Singh N, Gupta D, Behera D, Gupta N, et al. Endoscopic ultrasound-guided fine-needle aspiration with an echobronchoscope in undiagnosed mediastinal lymphadenopathy: first experience from India. *Lung India* 2015;32:6.

Lönnroth K, Mor Z, Erkens C, Bruchfeld J, Nathavitharana RR, van der Werf MJ, et al. Tuberculosis in migrants in low-incidence countries: epidemiology and intervention entry points. *Int J Tuberc Lung Dis* 2017;21:624–36.

Mondoni M, Radovanovic D, Valenti V, Patella V, Santus P. Bronchoscopy in sarcoidosis: union is strength. *Minerva Med* 2015a;106:1–7.

Mondoni M, D'Adda A, Terraneo S, Carlucci P, Radovanovic D, Di Marco F, et al. Choose the best route: ultrasound-guided transbronchial and transesophageal needle aspiration with echobronchoscope in the diagnosis of mediastinal and pulmonary lesions. *Minerva Med* 2015b;106:13–9.

Mondoni M, Repposi A, Carlucci P, Centanni S, Sotgiu G. Bronchoscopic techniques in the management of patients with tuberculosis. *Int J Infect Dis* 2017;64:27–37.

Mondoni M, Carlucci P, Job S, Parazzini EM, Cipolla G, Pagani M, et al. Observational, multicentre study on the epidemiology of haemoptysis. *Eur Respir J* 2018;51:1701813.

Nahid P, Dorman SE, Alipanah N, Barry PM, Brozek JL, Cattamanchi A, et al. Official American Thoracic Society/Centers for Disease Control and Prevention/ Infectious Diseases Society of America Clinical Practice Guidelines: Treatment of Drug-Susceptible Tuberculosis. *Clin Infect Dis* 2016;63:e147–95.

Sotgiu G, Dara M, Centis R, Matteelli A, Solovic I, Gratziau C, et al. Breaking the barriers: migrants and tuberculosis. *Presse Med* 2017a;46:e5–e11.

Sotgiu G, Falzon D, Hollo V, Ködmön C, Lefebvre N, Dadu A, et al. Determinants of site of tuberculosis disease: an analysis of European surveillance data from 2003 to 2014. *PLoS One* 2017b;12:e0186499.

Walker TM, Merker M, Knoblauch AM, Helbling P, Schoch OD, van der Werf MJ, et al. A cluster of multidrug-resistant *Mycobacterium tuberculosis* among patients arriving in Europe from the Horn of Africa: a molecular epidemiological study. *Lancet Infect Dis* 2018;18:431–40.

Michele Mondoni<sup>a</sup>

Ottavia Viganò<sup>b</sup>

Maurizio Ferrarese<sup>c</sup>

Manuela Bimbatti<sup>d</sup>

Mirta Cavallini<sup>a</sup>

Luigi Codecasa<sup>c</sup>

Antonella D'Arminio Monforte<sup>b</sup>

Gaetano Bulfamante<sup>d</sup>

Stefano Centanni<sup>a</sup>

Giovanni Sotgiu<sup>e,\*</sup>

<sup>a</sup>Respiratory Unit, ASST Santi Paolo e Carlo, San Paolo Hospital,  
Department of Health Sciences, Università degli Studi di Milano,  
Milan, Italy

<sup>b</sup>Clinic of Infectious and Tropical Diseases, Department of Health  
Sciences, University of Milan, Milan, Italy

<sup>c</sup>Lombardia Region TB Reference Clinic, Villa Marelli Institute/  
Niguarda, Ca' Granda Hospital, Milan, Italy

<sup>d</sup>Human Pathology and Molecular Pathology Unit, San Paolo Hospital,  
Department of Health Sciences, Università degli Studi di Milano,  
Milan, Italy

<sup>e</sup>Clinical Epidemiology and Medical Statistics Unit, Department of  
Medical, Surgical and Experimental Medicine, University of Sassari,  
Via Padre Manzella, 4, Sassari, Italy

\* Corresponding author.

E-mail address: [gsotgiu@uniss.it](mailto:gsotgiu@uniss.it) (G. Sotgiu).

**Corresponding Editor:** Eskild Petersen, Aarhus, Denmark

Received 10 September 2018

Received in revised form 2 October 2018

Accepted 4 October 2018