

## Remitting Tics and Narcolepsy Overlap Associated with Streptococcal Infection: A Case Report

Simone Baiardi, MD,<sup>1</sup> Elena Antelmi, MD,<sup>1</sup> Marco Filardi, PsyD,<sup>2</sup> Fabio Pizza, MD, PhD,<sup>1,3</sup> Stefano Vandì, RPSGT,<sup>1,3</sup> Pierangelo Veggiotti, MD,<sup>4</sup> Rocco Liguori, MD,<sup>1,3</sup> Giuseppe Plazzi, MD, PhD<sup>1,3,\*</sup>

Narcolepsy is a rare hypersomnia of central origin characterized by hypersomnolence, direct transition from wakefulness to rapid eye movement (REM) sleep, and other dissociated states of wake-REM sleep. It is distinguished into narcolepsy type 1 (with cerebrospinal fluid [CSF] hypocretin-1 [hcr1-1] deficiency and/or with cataplexy) and narcolepsy type 2 (without cataplexy and normal CSF hcr1-1).<sup>1</sup> Narcolepsy is associated with human leukocyte antigen (HLA) DQB1\*0602 allele, and evidence suggests that a T-cell-mediated autoimmune process may destroy hypothalamic hypocretinergic cells causing narcolepsy.<sup>2</sup> Indeed, streptococcal and H1N1 influenza infections are considered the strongest candidates as environmental triggers.<sup>2</sup> Therefore, narcolepsy could also be considered an autoimmune poststreptococcal disease as with some basal ganglia disorders with acute onset in childhood of motor and behavioral symptoms and episodic course.<sup>3</sup> This case report suggests a common underlying immune-mediated mechanism for both narcolepsy and tics.

### Case Report

A 16-year-old boy previously in good health presented in November 2012, following a febrile throat infection, with an acute onset of somnolence, with long-lasting night-sleep period, remarkable sleep inertia, and nonrestorative, prolonged (up to hours) daytime-sleep episodes. Facial tics, irritability, and aggressiveness were also noted. The patient's mother had a past history of tics during adolescence. The rest of the family history was unremarkable. Although, throughout the ensuing months, most of the patient's symptoms spontaneously improved, there was persistent hypersomnolence and the patient was referred to our center 10 months later.

Clinical and neurological examinations were normal, except for facial tics, namely, eye blinking, nose wrinkling, and grimacing. Growth and sexual development were in the age average (see Video). The patient was not aware of his tics, and he denied any associated preceding urge to perform them. How-

ever, he was able to completely suppress them on demand. Objective assessments by means of established tic scales yielded the following results: Yale Global Tic Severity Scale (YGTSS) score, 8; Rush videotape rating scale score, 5. Serological assays disclosed elevated anti-streptolysin O (ASO) titers (939 UI/mL), but were negative for antibasal ganglia and anti-N-methyl-D-aspartate antibodies. The Obsessive Compulsive Inventory-Revised questionnaire did not suggest an obsessive-compulsive disorder (score, 14; normal, <21). Subjective sleepiness was pathological (Epworth Sleepiness Scale [ESS] score: 12; normal, ≤10). A 7-day actigraphic monitoring showed a 24-hour profile characterized by prolonged nighttime sleep period, remarkable sleep inertia, and recurring (4/week) prolonged daytime naps (Fig. 1A). Nighttime polysomnography (PSG) was unremarkable (total sleep time [TST]: 7 hours and 49 minutes, sleep latency [SL]: 5 minutes; sleep efficiency [SE]: 95%), but the multiple sleep latency test (MSLT) showed pathological mean sleep latency (5 minutes and 53 seconds; pathological, <8 minutes) with three sleep-onset REM-sleep periods (SOREMPs) of five sleep opportunities. Brain MRI and CSF hcr1-1 (33,988 pg/mL) were normal. The patient carried the HLA DQB1\*0602 allele. Accordingly, narcolepsy type 2 was diagnosed. A treatment with modafinil up to 200 mg daily was started and immediately withdrawn for insomnia. After a further 9 months, at clinical follow-up, the patient and parents reported a remarkable global improvement of both tics and hypersomnolence (YGTSS score: 5; Rush videotape rating scale score: 3; ESS score: 4). Actigraphic monitoring confirmed a decrease of 24-hour TST, shorter night-sleep, and fewer (2/week) and shorter daytime naps (Fig. 1B). The MSLT confirmed hypersomnolence disappearance, showing normal mean sleep latency (9 minutes and 30 seconds) without SOREMPs. PSG disclosed a normal nighttime sleep (TST, 6 hours and 24 minutes; SL, 10 minutes; SE, 94%), with a reduced total sleep time compared to previous assessment. ASO titer was normalized (218 UI/mL).

<sup>1</sup>DIBINEM—Department of Biomedical and Neuromotor Sciences, Alma Mater Studiorum, University of Bologna, Bologna, Italy; <sup>2</sup>Department of Psychology, Alma Mater Studiorum, University of Bologna, Bologna, Italy; <sup>3</sup>IRCSS—Istituto delle Scienze Neurologiche, Bologna, Italy; <sup>4</sup>Department of Child Neurology and Psychiatry, C. Mondino National Neurological Institute, Pavia, Italy

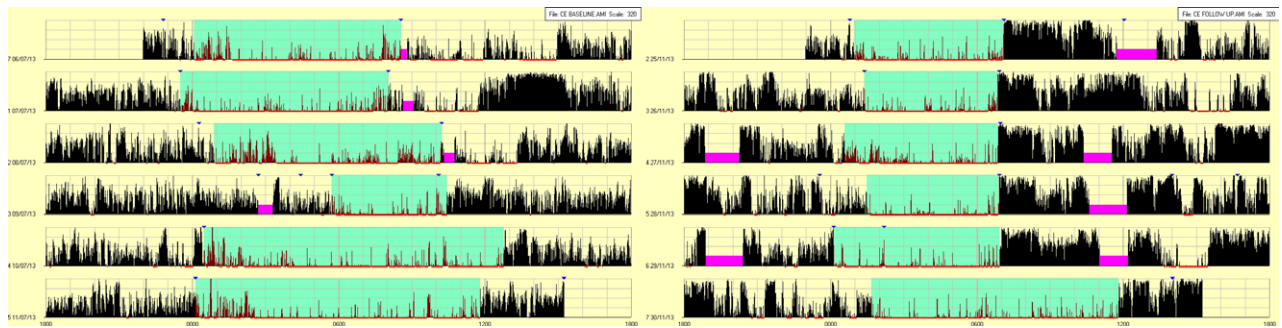
\*Correspondence to: Dr. Giuseppe Plazzi, DIBINEM—Department of Biomedical and Neuromotor Sciences, Alma Mater Studiorum, University of Bologna, Via Altura 3, 40139 Bologna, Italy; E-mail: giuseppe.plazzi@unibo.it

**Keywords:** narcolepsy, tics, basal ganglia, autoimmunity, hypersomnia.

Relevant disclosures and conflicts of interest are listed at the end of this article.

Received 6 February 2014; revised 23 June 2014; accepted 29 June 2014.

Published online 23 October 2014 in Wiley InterScience (www.interscience.wiley.com). DOI:10.1002/mdc3.12079



**Figure 1** (A) A 7-day actigraphic and self-report monitoring performed during the symptomatic phase showed a prolonged nighttime sleep period (nocturnal TST:  $500 \pm 116$  minutes; normative values:  $>440$ ), remarkable sleep inertia, recurring (4/week) long-duration daytime naps (mean nap duration:  $110.6 \pm 22.19$  minutes), and overall reduced daytime motor activity (mean motor activity:  $126.3 \pm 27.31$ ). (B) Actigraphic and self-report monitoring performed during the relapsing phase. A clear-cut total sleep time reduction and a global motor activity increase were showed by the follow-up actigraphic monitoring (5 months after baseline), when compared with the recording obtained during the symptomatic phase. The actigraphic monitoring indeed shows a reduction of nighttime major sleep episode duration (TST,  $406 \pm 103$  minutes) and of daytime naps frequency (2/week) and duration ( $86 \pm 11.31$  min), counterbalanced by daytime motor activity increase (mean motor activity:  $175.9 \pm 29.39$ ). An actigraphic monitor was placed on the nondominant wrist. Sky-blue highlight = sleep time period reported by the patient. Red underline: sleep time estimated by actigraphic algorithm analysis. Fuchsia highlight = periods when the actigraph was not worn by the patient.

## Discussion

Our case suggests that a central disorder of hypersomnolence (narcolepsy type 2) and motor disorders (tics) may cluster in association with streptococcal infection. The parallel waning course of both phenomena endorses this link. Either for narcolepsy, as well as for basal ganglia disorders, an association with autoimmunity is strongly suspected. High ASO titers are indeed frequently detected around the onset of narcolepsy<sup>4,5</sup> and of Sydenham chorea, basal ganglia encephalitis, pediatric autoimmune neuropsychiatric disorder associated with streptococcal infection (PANDAS), and tic disorders.<sup>3</sup> In many of these disorders, sleepiness has been seldom reported,<sup>6,7</sup> but never systematically investigated, suggesting that it may have been overlooked. A link between hypersomnolence and movement disorders has also been highlighted by the constellation of movement disorders that identify childhood narcolepsy type 1,<sup>5</sup> pinpointing the need of a more systematic and comprehensive evaluation of this overlap. Narcolepsy and tic disorders also share an impaired functioning of hypothalamus-hypophysis axis that has been suggested in Tourette syndrome<sup>8</sup> and in narcolepsy type 1.<sup>9</sup> However, our patient did not show clinical or brain MRI evidence of such a wider hypothalamic involvement. Although our patient did not experience any premonitory sensation, he was able to suppress his tics when required, highlighting that premonitory urges are indeed not a prerequisite of voluntary tic inhibition, as previously suggested.<sup>10</sup>

Finally, although, in this case, we speculate on a common underlying immune-mediated mechanism for both narcolepsy and tics, we acknowledge that we cannot exclude a pre-existing mild tic disorder enhanced by hypersomnolence.

## Author Roles

(1) Research Project: A. Conception, B. Organization, C. Execution; (2) Statistical Analysis: A. Design, B. Execution,

C. Review and Critique; (3) Manuscript: A. Writing of the First Draft, B. Review and Critique.

S.B.: 1C, 2C, 3A

M.F.: 1C, 2C, 3A

F.P.: 1C, 2C, 3A

G.P.: 1C, 2C, 3A

E.A.: 1C, 3A

S.V.: 1C, 2C

P.V.: 1C, 3A

R.L.: 1C, 3A

## Disclosures

**Funding Sources and Conflicts of Interest:** The authors report no sources of funding and no conflicts of interest.

**Financial Disclosures for previous 12 months:** Giuseppe Plazzi has consulted in advisory board for UCB Pharma and Jazz Pharmaceuticals.

## References

- American Academy of Sleep Medicine. *International Classification of Sleep Disorders*. 3rd ed. Darien, IL: American Academy of Sleep Medicine; 2014. ICSD3.
- De la Herrán-Arita AK, Kornum BR, Mahlios J, et al. CD4+ T cell autoimmunity to hypocretin/orexin and cross-reactivity to a 2009 H1N1 influenza A epitope in narcolepsy. *Sci Transl Med* 2013;5:216ra176.
- Dale RC, Brilot F. Autoimmune basal ganglia disorders. *J Child Neurol* 2012;27:1470–1481.
- Aran A, Lin L, Nevsimalova S, et al. Elevated anti-streptococcal antibodies in patients with recent narcolepsy onset. *Sleep* 2009;32:979–983.
- Plazzi G, Pizza F, Palaia V, et al. Complex movement disorders at disease onset in childhood narcolepsy with cataplexy. *Brain* 2011; 134:3480–3492.
- Das A, Radhakrishnan A. A case of PANDAS with Kleine-Levin type periodic hypersomnia. *Sleep Med* 2012;13:319–320.
- Vilensky JA, Foley P, Gilman S. Children and encephalitis lethargica: a historical review. *Pediatr Neurol* 2007;37:79–84.

8. Martino D, Macerollo A, Leckman JF. Neuroendocrine aspects of Tourette syndrome. *Int Rev Neurobiol* 2013;112:239–279.
9. Poli F, Pizza F, Mignot E, et al. High prevalence of precocious puberty and obesity in childhood narcolepsy with cataplexy. *Sleep* 2013;36:175–181.
10. Ganos C, Kahl U, Schunke O, et al. Are “premonitory” urges a prerequisite of tic inhibition in Gilles de la Tourette syndrome? *J Neurol Neurosurg Psychiatry* 2012;10:975–978.

## Supporting Information

A video accompanying this article is available in the supporting information here.

**Video.** The video shows the characteristics of facial simple motor tics (eye blinking, nose wrinkling, and grimacing) as the patient was watching a movie, alone in the examination room.