



Contents lists available at ScienceDirect

## International Journal of Surgery Case Reports

journal homepage: [www.casereports.com](http://www.casereports.com)

## Leiomyomatosis peritonealis disseminata: A case report of recurrent presentation and literature review

Luca Ferrario<sup>a,\*</sup>, Pietro Zerbi<sup>b</sup>, Maria Rachele Angiolini<sup>a</sup>, Alberto Agarossi<sup>c</sup>, Eliana Riggio<sup>a</sup>, Andrea Bondurri<sup>a</sup>, Piergiorgio Danelli<sup>a</sup>

<sup>a</sup> Department of General Surgery, Department of Biomedical and Clinical Sciences “Luigi Sacco”, “Luigi Sacco” University Hospital, Università degli Studi di Milano, 20157 Milan, Italy

<sup>b</sup> Department of Pathology, Department of Biomedical and Clinical Sciences “Luigi Sacco”, “Luigi Sacco” University Hospital, Università degli Studi di Milano, 20157 Milan, Italy

<sup>c</sup> Department of Obstetrics and Gynecology, Department of Biomedical and Clinical Sciences “Luigi Sacco”, “Luigi Sacco” University Hospital, Università degli Studi di Milano, 20157 Milan, Italy

### ARTICLE INFO

#### Article history:

Received 17 April 2018

Received in revised form 25 May 2018

Accepted 10 June 2018

Available online 18 June 2018

#### Keywords:

Case report

Leiomyoma

Leiomyomatosis peritonealis disseminata (LPD)

Laparoscopic myomectomy

Laparotomy

Hormonal therapy

### ABSTRACT

**INTRODUCTION:** Leiomyomatosis peritonealis disseminata (LPD) is an uncommon disease featured by the presence of multiple nodules of smooth muscle cells scattered in the abdominal cavity. To date only about 150 cases have been reported in literature. We report a case of recurrent LPD after laparotomy.

**CASE PRESENTATION:** In March 2016 a 36-year-old female, with a history of multiple previous laparoscopic myomectomies, consulted her gynaecologist complaining abdominal pain; a MRI was performed and reported multiple pelvic masses, subsequently excised during laparotomy. The patient refused a total hysterectomy with bilateral salpingo-oophorectomy so a close follow-up was recommended. In November 2017 when a new MRI revealed recurrency of the disease, a second laparotomy is performed and all visible nodules are excised. The histological exam confirms LPD diagnosis. On follow-up after three months the patients is completely asymptomatic.

**DISCUSSION:** Differential diagnosis of LPD is challenging due to its similarity to carcinomatosis and to other benign abdominal disorders. Malignant transformation is rare, but it may occur, so a close follow-up is necessary. Even if there is no consensus regarding the treatment, hormonal therapy is probably the best first line approach, while surgery should be the second choice.

**CONCLUSIONS:** LPD is an uncommon but potentially severe disease. In our opinion larger studies are necessary to improve our diagnostic effectiveness and to define the best therapeutic strategy.

© 2018 The Author(s). Published by Elsevier Ltd on behalf of IJS Publishing Group Ltd. This is an open access article under the CC BY-NC-ND license (<http://creativecommons.org/licenses/by-nc-nd/4.0/>).

## 1. Introduction

Leiomyomatosis peritonealis disseminata (LPD) is an uncommon disease characterized by the presence of multiple nodules composed of smooth muscle cells, located in the abdominal cavity, both in peritoneal and subperitoneal spaces. This disease was first described by Wilson and Peale in 1952 [1], and later named LPD by Taubert et al. [2].

The disease is usually observed in premenopausal women and rarely seen in postmenopausal women and men. Up to now only about 150 cases have been reported in literature.

The aetiology remains unclear, but different hypotheses have been proposed: a hormonal theory with subperitoneal mesenchymal stem cells metaplasia, a genetic theory and an iatrogenic origin subsequent to laparoscopic surgery [3].

We report a case of recurrent LPD after laparotomy in woman with a history of multiple laparoscopic myomectomies, occurred in our academical institution.

## 2. Case report

The work has been reported in line with SCARE criteria [4].

A 36-year-old female was admitted to our Institution for elective laparotomy after a follow-up MRI reported disease recurrence, with appearance of two oval nodules (6 cm and 5 cm respectively), located subcutaneously in the left-anterior abdominal wall (Fig. 1); three nodules (2 cm) behind them, one nodule (2 cm) strictly adherent to the left ovary, two nodules (1 cm) behind the cervix uteri, one nodule (1 cm) below the cecum and several small nodules in the greater omentum. There was neither ascites nor lymphadenopathies and all the lesions showed benign appearance with non-invasive behaviour.

The patient had previous history of one Caesarean section in 2011, an abortion in August 2017 and multiple laparoscopic

\* Corresponding author.

E-mail address: [luca.s.ferrari@hotmail.it](mailto:luca.s.ferrari@hotmail.it) (L. Ferrario).

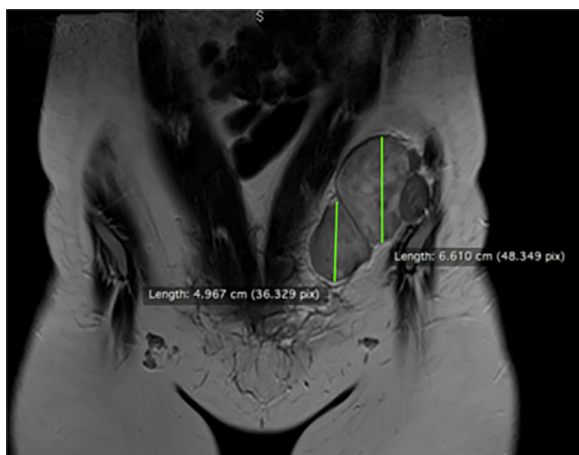


Fig. 1. Nodules of the left-anterior abdominal wall.

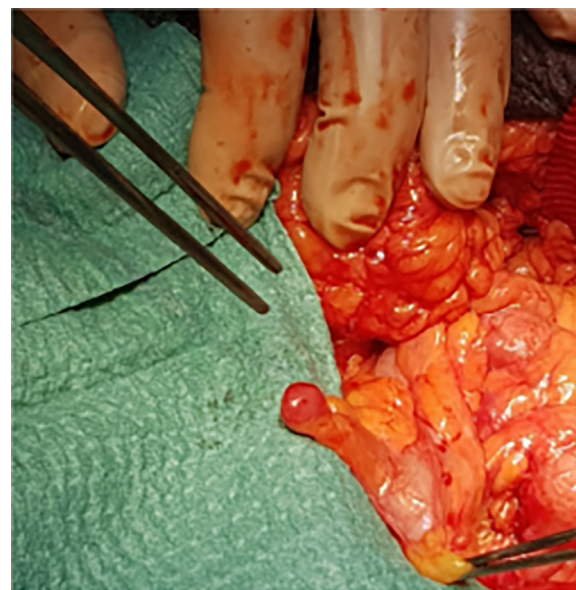


Fig. 2. Nodule of the sigmoid peritoneal surface.

myomectomies. She had no previous history of prolonged use of contraceptive pills. In 2005 the patient went to her gynaecologist after the appearance of vaginal bleeding and a uterine myoma was found, so she underwent a laparoscopic myomectomy. In the next ten years two other myomectomies were performed. In 2016 the patient consulted again her gynaecologist complaining of abdominal pain and abdominal swelling: an abdominal and pelvic ultrasound were performed detecting multiple pelvic masses, subsequently confirmed by MRI. The patient was referred to our medical centre on March 2016, and underwent an exploratory laparotomy that revealed multiple pelvic and omental neoformations, which were excised. Intraoperative frozen section revealed spindle cells without atypia, while at histopathology the tumors were composed by benign smooth muscle cells, without cell atypia or necrosis, similar to leiomyomas. The histology in combination with patient's history and intraoperative findings, confirmed the diagnosis of LPD. The patient was discharged after a ten days regular postoperative course. After the histological diagnosis a total hysterectomy with bilateral salpingo-oophorectomy was proposed to the patient but she refused because of her reproductive plans. A close radiological follow-up of the patient was then recommended and no further treatment was administered.

On November 2017, after MRI found new nodules, the patient was referred again to our department. At the moment of hospitalisation, she was completely asymptomatic, her physical examination was unremarkable and blood test, ECG and chest X-ray showed no anomalies, so a new exploratory laparotomy was scheduled. The patient preoperatively refused again the possibility of total hysterectomy with bilateral salpingo-oophorectomy.

At laparotomy, multiple grey nodules (Figs. 2 and 4), varying in size between 2 mm and 2 cm, were found on the surface of right and left ovary, uterus, cecum, sigmoid colon and greater omentum. The surgeons carefully excised all the visible lesions and partial omentectomy was made.

Another two bigger nodules, about 6 cm and 5 cm of diameter respectively, were found in the left-anterior abdominal wall, below a previous laparoscopic incision, and carefully excised (Fig. 3). Accurate haemostasis was performed and no drainage was placed to prevent further spread of neoplastic cells in the peritoneal cavity and to the abdominal wall. No intraoperative or postoperative complications were reported and patient was discharged 4 days after surgery. On follow-up after three months the patient was asymptomatic, with no evidence of recurrence clinically and on ultrasound; treatment with ulipristal acetate was about to be initiated, but in consequence of the review of ulipristal acetate started by EMA [5], due to cases of serious liver injury in women taking ulipristal acetate for uterine fibroids, we decided to wait for the results.

Histological exam showed multiple nodules with features of typical leiomyoma: tumors were formed by whorled bundles of smooth muscle cells separated by vascularized connective tissue, with scattered lymphocytes. Neither necrosis nor atypia were present. Tumor cells expressed almost 100% positivity for ER and

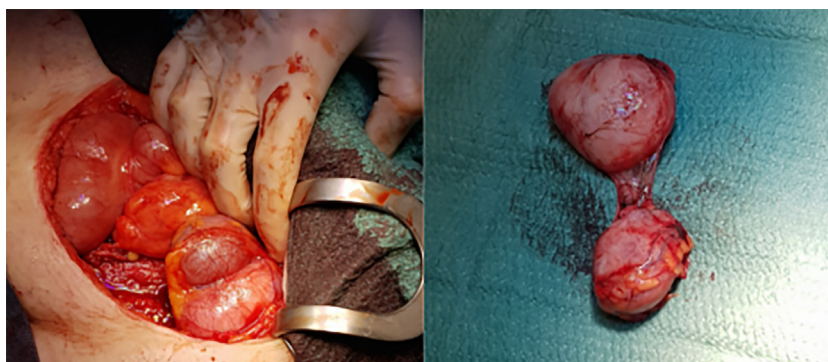


Fig. 3. Two large nodules of the anterior abdominal wall and the two nodules once removed.



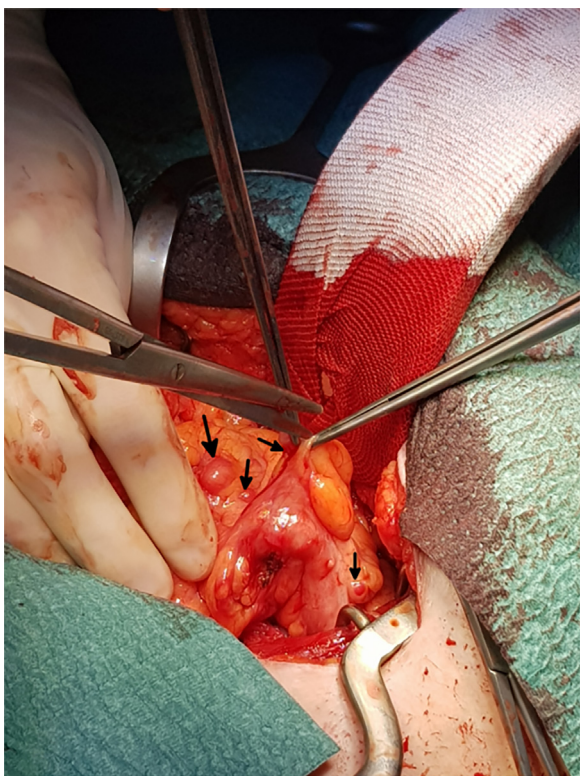


Fig. 4. Multiple subserosal nodules (arrows) of the colic wall.

PR. Cells were also decorated by smooth muscle actin and desmin. Proliferation index (Ki-67) was about 1% (Fig. 5).

3. Discussion

In 1952 Wilson and Peale first described a case of multiple peritoneal leiomyomas associated with ovarian granulosa cell tumor [1], but only in 1965 Taubert named it “Leiomyomatosis Peritonealis Disseminata” [2]. Since then only isolated cases and limited series have been reported, without consensus about the

aetiology and pathophysiology of this condition. In the English literature about 130 cases of LPD are described, of which 7 in postmenopausal women and 6 in males [3]. Even now the prevalence remains unknown, since most patients remain asymptomatic and LPD remains probably underdiagnosed.

Aetiology and pathophysiology are still unclear, but three main theories have been proposed: Hormonal, Genetic and Iatrogenic [3]. In most reported cases the proposed aetiology is exposure to high, endogenous or exogenous, estrogens levels (for example prolonged use of contraceptive pills, pregnancy or tumors secreting estrogens), probably associated with an underlying predisposition of the subcelomic mesenchymal cell to metaplastic change into myofibroblasts and fibroblasts cells [6]. Furthermore, cases of LPD subsequent to previous myomectomy or hysterectomy have been reported: laparoscopic hysterectomy with tumor morcellation may particularly increase the risk of LPD [7]. As in our case, LPD may present several years after laparoscopic myomectomy; in the case we describe, the aetiological correlation to previous myomectomy is suggested by presence of the two nodules exactly below the previous incision on the abdominal wall. Moreover, a case of familial clustering of LPD was identified and an autosomal-dominant model with varying degrees of penetrance was proposed [8,9].

Diagnosis is challenging: this condition is often absolutely asymptomatic and the diagnosis is incidental (e.g. during laparoscopy); however, patients may present non-specific symptoms such as abdominal pain or discomfort, bleeding from rectum or vagina, abdominal distension, palpable abdominal masses and intestinal obstruction [9]; rarely symptoms of malignancy as ascites, lymph nodes enlargement may be present at diagnosis [10]. Ultrasound and CT findings are nonspecific and often similar to peritoneal carcinomatosis, while at MRI the masses signal appears similar to that of skeletal and smooth muscle on both T1- and T2-weighted images [11]. Exploratory laparotomy or laparoscopy with histopathological analysis are mandatory to make a certain diagnosis of LPD. As regards differential diagnosis, LPD should be differentiated from malignancies such as peritoneal carcinomatosis or from benign conditions such as benign metastasizing leiomyomas, intravenous leiomyomatosis of the uterus and parasitic myoma [12].

Macroscopically the nodules are usually between 0,5 and 50 mm in diameter, round, grey and well circumscribed. Microscopically

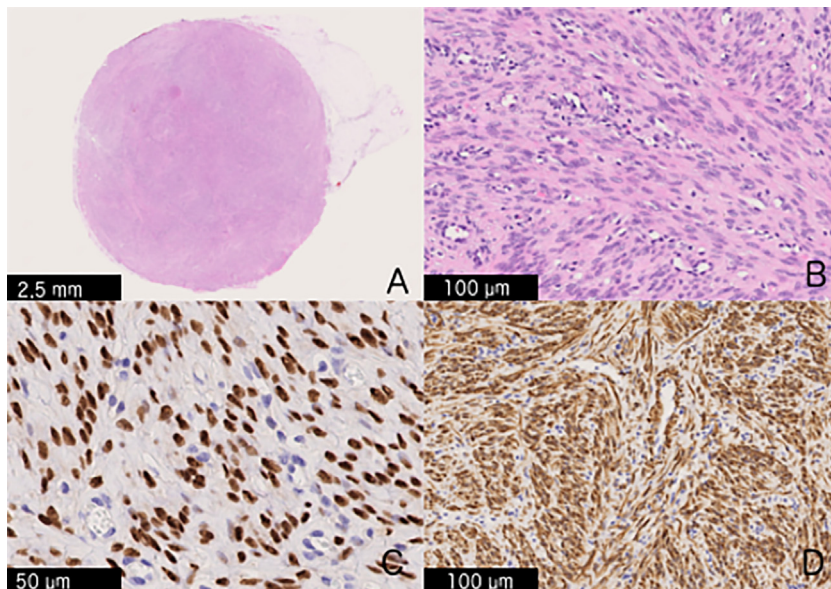


Fig. 5. Histological appearance of LPD tumor from peritoneal implants. (A) Low-power haematoxylin-eosin (H&E). (B) High-power H&E. (C) Progesterone receptor immunostaining. (D) Desmin immunostaining.

they show smooth-muscle cell without atypia or necrosis, furthermore, myofibroblasts, fibroblasts, collagen and decidual stromal cells can be also noted. On immunohistochemistry they show typical smooth-muscle pattern (vimentin+, desmin+, SMA+) and positivity for estrogen and progesterone receptors [3,12].

There is no consensus regarding the treatment of LPD. In case of women with reproductive desire, a conservative approach has to be preferred. Spontaneous regression has been described after discontinuation of oral contraception [3], while treatment with GnRH agonists [13], aromatase inhibitors [14] and selective progesterone receptor modulator (e.g. ulipristal acetate) [15] are described as effective, too; if surgical treatment is necessary (e.g. in case of intestinal obstruction), it should consist of debulking and omentectomy followed by hormonal therapy. In case of women with no reproductive desire, or post-menopausal women, a more extensive surgical approach with hysterectomy, salpingo-oophorectomy, omentectomy and debulking may be the best alternative [3].

Although LPD is a benign condition, rare cases of malignant transformation have been described in literature [16–18], so clinical and radiological (MRI) follow-up of the patients are therefore strongly recommended.

#### 4. Conclusion

LPD is a rare disorder with a usually benign course, but in rare cases malignant transformation may occur. The pathophysiology remains unclear, but an increasing number of LPD after laparoscopic myomectomy seems to be reported; for this reason, all procedures exposing the patient to the risk of scattering of fragments of myoma in abdominal cavity (e.g. morcellation or endo-abdominal irrigation) appear to be potentially dangerous and should be probably reconsidered. The diagnosis of LPD can be difficult because clinical and radiological findings may mimic a malignant disease, so an exploratory laparotomy or laparoscopy, with histological sampling is mandatory for a proper diagnosis. In premenopausal women hormonal therapy is probably the best approach, while surgery must be of second choice [19]. However, a close follow-up is necessary due to the risk of recurrence and malignant degeneration.

It is our opinion that larger studies are necessary to improve the diagnostic effectiveness and to define the best therapeutic strategy for this disease, even preventing, wherever possible, the risk of progression, recurrence and malignant transformation.

#### Conflicts of interests

The authors declare that they have no conflict of interest.

#### Sources of funding

There is no source of funding.

#### Ethical approval

Case reports are exempt from ethical approval in our institution.

#### Consent

Written informed consent was obtained from the patient for publication of this case report and accompanying images. A copy of the written consent is available for review by the Editor-in-Chief of this journal on request.

#### Author contribution

Ferrario Luca: conception and design of publication, collection of case report data and writing the manuscript.

Zerbi Pietro: providing pathology images and writing the manuscript.

Angiolini Maria Rachele: collection of case report data and writing the manuscript.

Agarossi Alberto: second surgeon, bibliography check, review the manuscript for important intellectual content.

Riggio Eliana: third surgeon, review the manuscript for important intellectual content.

Andrea Bondurri: grammar check, review the manuscript for important intellectual content.

Danelli Piergiorgio: first surgeon, supervising the case report.

#### Registration of research studies

None.

#### Guarantor

Ferrario Luca.

Danelli Piergiorgio.

#### References

- J.R. Willson, A.R. Peale, Multiple peritoneal leiomyomas associated with a granulosa-cell tumor of the ovary, *Am. J. Obstet. Gynecol.* 64 (2018) 204–208, [http://dx.doi.org/10.1016/S0002-9378\(16\)38757-9](http://dx.doi.org/10.1016/S0002-9378(16)38757-9).
- H.D. Taubert, S.E. Wissner, A.L. Haskins, Leiomyomatosis peritonealis disseminata; an unusual complication of genital leiomyomata, *Obstet. Gynecol.* 25 (1965) 561–574.
- A. Al-Talib, T. Tulandi, Pathophysiology and possible iatrogenic cause of leiomyomatosis peritonealis disseminata, *Gynecol. Obstet. Invest.* 69 (2010) 239–244, <http://dx.doi.org/10.1159/000274487>.
- R.A. Agha, A.J. Fowler, A. Saeta, I. Barai, S. Rajmohan, D.P. Orgill, et al., The SCARE statement: consensus-based surgical case report guidelines, *Int. J. Surg.* 34 (2016) 180–186, <http://dx.doi.org/10.1016/j.ijssu.2016.08.014>.
- PRAC, Women taking Esmya for uterine fibroids to have regular liver tests while EMA review is ongoing, *Eur. Med. Agency* 44 (2018) 2017–2019, . (Accessed 8 April 2018) [http://www.ema.europa.eu/ema/index.jsp?curl=pages/medicines/human/referrals/Esmya/human\\_referral\\_prac\\_000070.jsp&mid=WC0b01ac05805c516f](http://www.ema.europa.eu/ema/index.jsp?curl=pages/medicines/human/referrals/Esmya/human_referral_prac_000070.jsp&mid=WC0b01ac05805c516f).
- F.F. Nogales, A. Matilla, E. Carrascal, Leiomyomatosis peritonealis disseminata. An ultrastructural study, *Am. J. Clin. Pathol.* 69 (1978) 452–457, <http://dx.doi.org/10.1093/ajcp/69.4.452>.
- S. Kumar, J.B. Sharma, D. Verma, P. Gupta, K.K. Roy, N. Malhotra, Disseminated peritoneal leiomyomatosis: an unusual complication of laparoscopic myomectomy, *Arch. Gynecol. Obstet.* 278 (2008) 93–95, <http://dx.doi.org/10.1007/s00404-007-0536-9>.
- N. Halama, S.A. Grauling-Halama, I. Daboul, Familial clustering of Leiomyomatosis peritonealis disseminata: an unknown genetic syndrome? *BMC Gastroenterol.* 5 (2005) 33, <http://dx.doi.org/10.1186/1471-230X-5-33>.
- G. Psathas, M. Zarokosta, M. Zoulamoglou, D. Chrysikos, I. Thivaos, I. Kaklamanos, K. Birbas, T. Mariolis-Sapsakos, Leiomyomatosis peritonealis disseminata: a case report and meticulous review of the literature, *Int. J. Surg. Case Rep.* 40 (2018) 105–108, <http://dx.doi.org/10.1016/j.ijscr.2017.09.016>.
- L. Nappi, F. Sorrentino, S. Angioni, A. Pontis, I. Barone, P. Greco, Leiomyomatosis Peritonealis Disseminata (LPD) ten years after laparoscopic myomectomy associated with ascites and lymph nodes enlargement: a case report, *Int. J. Surg. Case Rep.* 25 (2018) 1–3, <http://dx.doi.org/10.1016/j.ijscr.2016.05.017>.
- N. Fasih, A.K. Prasad Shanbhogue, D.B. Macdonald, M.A. Fraser-Hill, D. Papadatos, A.Z. Kielar, G.P. Doherty, C. Walsh, M. McInnes, M. Atri, Leiomyomas beyond the uterus: unusual locations, rare manifestations, *RadioGraphics* 28 (2008) 1931–1948, <http://dx.doi.org/10.1148/rg.287085095>.
- B. Lu, J. Xu, Z. Pan, Iatrogenic parasitic leiomyoma and leiomyomatosis peritonealis disseminata following uterine morcellation, *J. Obstet. Gynaecol. Res.* 42 (2016) 990–999, <http://dx.doi.org/10.1111/jog.13011>.
- H.A. Hales, C.M. Peterson, K.P. Jones, J.D. Quinn, Leiomyomatosis peritonealis disseminata treated with a gonadotropin-releasing hormone agonist, *Am. J. Obstet. Gynecol.* 167 (2017) 515–516, [http://dx.doi.org/10.1016/S0002-9378\(11\)91445-8](http://dx.doi.org/10.1016/S0002-9378(11)91445-8).
- T. Takeda, K. Masuhara, S. Kamiura, Successful management of a leiomyomatosis peritonealis disseminata with an aromatase inhibitor, *Obstet.*

- Gynecol. 112 (2008) 491–493, <http://dx.doi.org/10.1097/AOG.0b013e318180219b>.
- [15] J. Verguts, G. Orye, S. Marquette, Symptom relief of leiomyomatosis peritonealis disseminata with ulipristal acetate, *Gynecol. Surg.* 11 (2014) 57–58, <http://dx.doi.org/10.1007/s10397-013-0816-2>.
- [16] A. Morizaki, H. Hayashi, M. Ishikawa, Leiomyomatosis peritonealis disseminata with malignant transformation, *Int. J. Gynecol. Obstet.* 66 (1999) 43–45, [http://dx.doi.org/10.1016/S0020-7292\(98\)00255-0](http://dx.doi.org/10.1016/S0020-7292(98)00255-0).
- [17] R.L.M. Bekkers, W.N.P. Willemsen, C.P.T. Schijf, L.F.A.G. Massuger, J. Bulten, J.M.W.M. Merkus, Leiomyomatosis peritonealis disseminata: does malignant transformation occur? A literature review, *Gynecol. Oncol.* 75 (2017) 158–163, <http://dx.doi.org/10.1006/gyno.1999.5490>.
- [18] P. Sharma, K.U. Chaturvedi, R. Gupta, S. Nigam, Leiomyomatosis peritonealis disseminata with malignant change in a post-menopausal woman, *Gynecol. Oncol.* 95 (2004) 742–745, <http://dx.doi.org/10.1016/j.ygyno.2004.09.007>.
- [19] G.B. Nassif, M.G. Galdon, G. Liberale, Leiomyomatosis Peritonealis Disseminata : Case Report and Review of the Literature, 2016, pp. 5458, <http://dx.doi.org/10.1080/00015458.2016.1139833>.

#### Open Access

This article is published Open Access at [sciedirect.com](http://sciedirect.com). It is distributed under the [IJSCR Supplemental terms and conditions](#), which permits unrestricted non commercial use, distribution, and reproduction in any medium, provided the original authors and source are credited.