

Magnusiomyces clavatus infection in a child after allogeneic hematopoietic stem cell transplantation: Diagnostic and therapeutic implications



Massimiliano Leoni^{c,*,1}, Nicolò Riccardi^{b,1}, Gioacchino Andrea Rotulo^a, Elisabetta Godano^a, Maura Faraci^c, Roberto Bandettini^d, Maria Carmela Esposto^e, Elio Castagnola^f

^a Pediatric Department, IRCCS Istituto Giannina Gaslini, Via Gaslini 5, 16147 Genova, Italy

^b Clinic of Infectious Diseases, Policlinico San Martino Hospital, University of Genoa, Largo Rosanna Benzi 10, 16132 Genova, Italy

^c Hematopoietic Stem Cell Transplantation Unit, IRCCS G Gaslini, via Gaslini 5, 16147 Genova, Italy

^d Laboratory of Microbiology, IRCCS Istituto Giannina Gaslini, Via Gaslini 5, 16147 Genova, Italy

^e Biomedical Sciences for Health Unit, University of Milan, Via Pascal 36, 20133 Milano, Italy

^f Infectious Disease Unit, IRCCS Istituto Giannina Gaslini, Via Gaslini 5, 16147 Genova, Italy

ARTICLE INFO

Keywords:

Magnusiomyces clavatus
Dimorphic fungi
Neutropenia
HSCT

ABSTRACT

Magnusiomyces clavatus is an ascomycetous fungus causing invasive disease in immuno-compromised patients. Neutropenia, contaminated venous catheters, previous antifungal treatment are risk factors for this infection. We report a case of *Magnusiomyces clavatus* fungemia with pulmonary, renal and skin localizations in a 6-year-old boy with prolonged neutropenia because of three allogeneic hematopoietic stem cell transplantations. The infection was controlled by aggressive and strictly monitored combination therapy with voriconazole and liposomal-amphotericin-B along with durable recover from neutropenia.

1. Introduction

Magnusiomyces clavatus (*M. clavatus*), formerly known as *Geotrichum clavatum*, is an ascomycetous fungus, that has been described as a rare cause of invasive fungal disease (IFD) in immuno-compromised patients [1,2]. Profound and prolonged neutropenia is a requisite for *M. clavatus* fungemia, which may lead to multiple organ localizations (1). Other risk factors, like contaminated venous catheters or previous antifungal treatment, have been also associated with this infection [3,4]. Clusters have been reported in hematological settings through Europe, but no clear source of infection has been found yet, due to its natural presence in human flora, soil and dietary products, as some kinds of milky-cheeses [2,3]. Poor outcome has been described with this pathogen (1), since no satisfy antifungal regimen has been found yet [5].

Approximately one hundred cases of IFD due to *M. clavatus* have been reported in adults, while only few cases of *Magnusiomyces capitatus* (*Saprochaete capitata*) fungemia have been described in children [1–3,6,7].

We describe the first pediatric case of *M. clavatus* fungemia with organ dissemination occurred in a neutropenic patient between the second and the third allogeneic hemopoietic stem cell transplantation (HSCT) performed in a tertiary Italian pediatric Research Institute.

2. Case

A 6-year-old boy, affected by bone marrow failure, received a first haploidentical stem cell transplantation using $\alpha/\beta/CD19$ depleted peripheral blood stem cells from his mother, after conditioning regimen including Fludarabine, Cyclophosphamide, low-dose of Total Body Irradiation, anti-thymocyte globulin, and Rituximab. His brother was excluded as a donor due to abnormalities in granulocytes colonies' growth.

On day + 24 after HSCT, rejection was documented and a second haploidentical HSCT was performed 16 days later. In this case, the patients received anti-mycotic prophylaxis with liposomal amphotericin B (LAMB) at 2.5 mg/kg two times a week, according to our standard protocol in cases of HSCT reject. In this case conditioning regimen included Fludarabine, Melphalan, Alemtuzumab, and Rituximab. The day after infusion the patient developed fever, empirically treated with piperacillin/tazobactam and amikacin, waiting for the culture results. Blood cultures were positive for yeasts subsequently identified as *M. clavatus* by molecular identification. In particular, the extracted genomic DNA was amplified using the universal fungal-specific primers ITS1 (TCCGTAGGTGAACCTGCGG) and ITS4 (TCCTCCGCTTATTGATA TGC) for internal transcribed spacer regions of fungal ribosomal DNA

* Corresponding author

E-mail address: leonimassi@gmail.com (M. Leoni).

¹ Equal contributors.

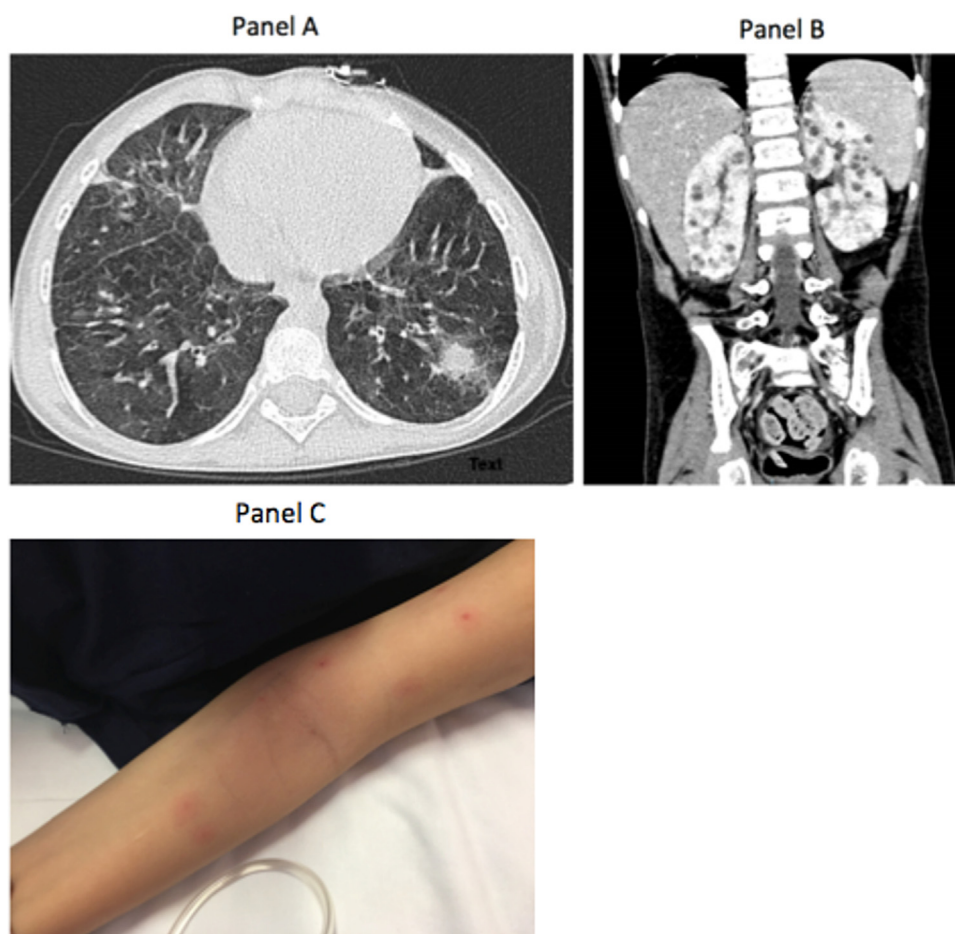


Fig. 1. Panel A: Pulmonary localization of *S. clavata*. Panel B: Multiple bilateral renal lesions due to *S. clavata*. Panel C: Multiple skin localization of *S. clavata*.

and nucleotide sequences were analyzed using Finch TV software Version 1.4.0. (www.geospiz.com) [8]. We inserted sequences in GeneBank (accession number of the closest hit in GenBank [MF142803.1](https://www.ncbi.nlm.nih.gov/nuclseq/MF142803.1)), but at the moment we do not yet have the datum related to the strain.

Antifungal susceptibility test performed by broth microdilution assay (Sensititre™ YeastOne - TREK Diagnostic Systems, Cleveland, OH, USA) according to manufacturer's indications, showed the following minimal inhibitory concentrations (MIC mg/L): amphotericin B (AMB) 1, caspofungine > 8, fluconazole 64, voriconazole 1, flucytosine 0.5. No standardized MICs interpretation is currently available for this pathogen [9].

AMB dose was increased to 3 mg/kg daily, but blood cultures remained positive. Substitution of intravascular access was performed but nodular lesions on the chin and left arm appeared, associated with pulmonary nodules and kidney's lesions (Fig. 1), seven days after the fever. The removed central venous line was cultured without growth of *M. clavatus*. Echocardiography was normal.

On day + 9 after HSCT, voriconazole at 9 mg/Kg for 2 doses and then 8 mg/Kg twice daily was added. Skin biopsy was not diagnostic but compatible with generic inflammation. Unfortunately the patient developed another HSCT rejection. Therefore the patient received a 3rd HSCT, from his HLA identical brother, after a secondary assessment to exclude abnormalities of granulocytes colonies growth. The conditioning regimen included Fludarabine, Treosulphan, ATG, and cyclosporine. Full donor engraftment occurred regularly, but blood cultures remained persistently positive for *M. clavatus*. Plasmatic level of liposomal amphotericin B and voriconazole were 7.4 mg/L (peak) and 3.5 mg/L (trough) respectively. LAMB was increased to 5 mg/Kg and

then to 10 mg/Kg/day, with the aim to increase the C_{max}/MIC ratio, while voriconazole dosage was unchanged since its plasma concentrations were considered in the therapeutic range, at least comparing with other fungi, as *Aspergillus*. Blood cultures remained positive for *M. clavatus* until day + 10 from the 3rd HSCT that corresponded to neutrophils engraftment and later blood cultures became negative. Combination treatment with LAMB and voriconazole was prolonged for 1 month after negativity of blood culture, and voriconazole 8 mg/kg was maintained for other 4 months. During this period the clinical, hematological and radiological picture improved. Eight months after the end of antifungal treatment the patient was still on treatment with cyclosporine with complete engraftment (100% donor) and no signs of IFD was demonstrated.

3. Discussion

This case report represents the first description of IFD due to *M. clavatus* in paediatrics.

Profound and prolonged neutropenia due to recurrent HSCT rejections was probably the most important risk factor for the development and persistence of this infection, since cultures of all vascular accesses removed were negative and the persistence of fungemia was related with documented organ localizations.

No known dietary products containing cheese, possibly contaminated by the fungus, were identified in the patient's daily diet, although it cannot be excluded.

Low dose liposomal amphotericin B, suggested as a possible prophylaxis of IFD in pediatric allogeneic HSCT (at least for aspergillosis), was not effective to prevent this infection.

Susceptibility to antifungal drugs of *M. clavatus* has been reported from in vitro studies [1–5,10]. In absence of any standardized breakpoint we adopted a treatment strategies with full doses of antifungal drugs and plasma levels evaluation, similar to that suggested for other fungi and a combination of liposomal amphotericin B (at increasing doses) and voriconazole, that in some way resulted effective in limiting the containing spreading at least until neutrophils recovery, that seems to have been pivotal for patient's final recovery [10]. Disseminated IFD due to *M. clavatus* is associated with high morbidity and mortality [2]. In this case combination therapy with LAMB and voriconazole seemed more effective to limit the infection and in our patient did not lead to any organ toxicity [1–11].

Finally, high level of awareness, a strict policy of high-risk patients' contact-isolation even before pathogen identification, as well as a rapid fungal diagnostic avoided a possible healthcare-associated outbreak [12].

No certain data about combination therapy vs mono-therapy and length of treatment are available yet. In our case aggressive and strictly monitored combination treatment along with durable recover from neutropenia seemed to be useful to control the infection.

Acknowledgements

None.

Conflict of interest

The Authors declare that there is no conflict of interest

References

- [1] S. Vaux, A. Criscuolo, M. Desnos-Ollivier, L. Diancourt, C. Tarnaud, M. Vandenberghe, S. Brisse, B. Coignard, F. Dromer, Multicenter outbreak of infections by *Saprochaete clavata*, an unrecognized opportunistic fungal pathogen, *MBio* 5 (2014) 6, <https://doi.org/10.1128/mBio.02309-14> Geotrichum (Geotrichum Investigation Group).
- [2] M.I. Del Principe, L. Sarmati, M. Cefalo, C. Fontana, G. De Santis, F. Buccisano, L. Maurillo, E. De Bellis, M. Postorino, G. Sconocchia, G. Del Poeta, M. Sanguinetti, S. Amadori, L. Pagano, A. Venditti, A cluster of *Geotrichum clavatum* (*Saprochaete clavata*) infection in haematological patients: a first Italian report and review of literature, *Mycoses* 59 (2016) 594–601, <https://doi.org/10.1111/myc.12508>.
- [3] L. DuránGraeff, D. Seidel, M.J. Vehreschild, A. Hamprecht, A. Kindo, Z. Racil, J. Demeter, S. De Hoog, U. Aurbach, M. Ziegler, H. Wisplinghoff, O.A. Cornely, Invasive infections due to *Saprochaete* and *Geotrichum* species: report of 23 cases from the fungiscope registry, *Mycoses* 60 (2017) 273–279, <https://doi.org/10.1111/myc.12595> (FungiScope Group).
- [4] I. Pottier, S. Gente, J.P. Vernoux, M. Guéguen, Safety assessment of dairy micro-organisms: *geotrichumcandidum*, *Int. J. Food Microbiol.* 126 (2008) 327–332.
- [5] M.C. Arendrup, T. Boekhout, M. Akova, J.F. Meis, O.A. Cornely, O. Lortholary, European Confederation of Medical Mycology. ESCMID and ECMJF joint clinical guidelines for the diagnosis and management of rare invasive yeast infections, *Clin. Microbiol. Infect.* 20 (2014) 76–98, <https://doi.org/10.1111/1469-0691.12360> (European Society of Clinical Microbiology and Infectious Diseases Fungal Infection Study Group).
- [6] Z.C. Özdemir, A. Bozkurt Turhan, Y. Düzenli Kar, Ç.E. Dinleyici, Ö. Bör, Fatal course of *Saprochaete capitata* fungemia in children with acute lymphoblastic leukemia, *Pediatr. Hematol. Oncol.* 34 (2017) 66–72, <https://doi.org/10.1080/08880018.2017.1316808>.
- [7] A.M. Parahym, P.J. Rolim Neto, C.M. da Silva, F. Domingos Ide, S.S. Gonçalves, E.P. Leite, V.L. de Moraes, D.P. Macêdo, R.G. de Lima Neto, R.P. Neves, Invasive infection due to *Saprochaete capitata* in a young patient with haematological malignancies, *Braz. J. Microbiol.* 46 (2015) 527–530, <https://doi.org/10.1590/S1517-838246220120447>.
- [8] T.J. White, T. Bruns, S. Lee, J. Taylor, Amplification and direct sequencing of fungal ribosomal RNA genes for phylogenetics, in: M.A. Innis, D.H. Gelfand, J.J. Sninsky, T.J. White (Eds.), *PCR Protocols: A Guide to Methods and Applications*. Academic Press, San Diego, CA, 1990, pp. 315–322.
- [9] J.N. Júnior de Almeida, J. Sztajnbock, A.R. Junior da Silva, V.A. Vieira, A.L. Galastri, L. Bissoli, N. Litvinov, G.M. Del Negro, A.L. Motta, F. Rossi, G. Benard, Rapid identification of moulds and arthroconidial yeasts from positive blood cultures by MALDI-TOF mass spectrometry, *Med. Mycol.* 54 (2016) 885–889, <https://doi.org/10.1093/mmy/myw044>.
- [10] A.H. Groll, E. Castagnola, S. Cesaro, J.H. Dalle, D. Engelhard, W. Hope, E. Roilides, J. Styczynski, A. Warris, T. Lehrnbecher; Fourth European Conference on Infections in Leukaemia; Infectious Diseases Working Party of the European Group for Blood Marrow Transplantation (EBMT-IDWP); Infectious Diseases Group of the European Organisation for Research and Treatment of Cancer (EORTC-IDG); International Immunocompromised Host Society (IHS); European Leukaemia Net (ELN). Fourth European Conference on Infections in Leukaemia (ECIL-4): guidelines for diagnosis, prevention, and treatment of invasive fungal diseases in paediatric patients with cancer or allogeneic haemopoietic stem-cell transplantation. *Lancet. Oncol.* 15 (2014) e327–340. [https://doi.org/10.1016/S1470-2045\(14\)70017-8](https://doi.org/10.1016/S1470-2045(14)70017-8).
- [11] S. Favre, A. Rougeron, L. Levoir, B. Pérard, N. Milpied, I. Accoceberry, F. Gabriel, S. Vigouroux, *Saprochaete clavata* invasive infection in a patient with severe aplastic anemia: efficacy of voriconazole and liposomal amphotericin B with adjuvant granulocyte transfusions before neutrophil recovery following allogeneic bone marrow transplantation, *Med. Mycol. Case Rep.* 11 (2016) 21–23, <https://doi.org/10.1016/j.mmc.2016.03.001>.
- [12] M.E. Bounoux, S. Brun, J.R. Zahar, Healthcare-associated fungal outbreaks: new and uncommon species, New molecular tools for investigation and prevention, *Antimicrob. Resist. Infect. Control.* 7 (2018) 45, <https://doi.org/10.1186/s13756-018-0338-9>.