

Carotid Artery Plaque Composition — Relationship to Clinical Presentation and Ultrasound B-mode Imaging*

European Carotid Plaque Study Group

Objective: To correlate B-mode ultrasound findings to carotid plaque histology.

Design: European multicentre study (nine centres).

Material and Methods: Clinical presentation and risk factors were recorded and preoperative ultrasound Duplex scanning with special emphasis on B-mode imaging studies was performed in 270 patients undergoing carotid endarterectomy. Perioperatively, macroscopic plaque features were evaluated and the removed specimens were analysed histologically for fibrous tissue, calcification and 'soft tissue' (primarily haemorrhage and lipid).

Results: Males had more soft tissue than females ($p = 0.0006$), hypertensive patients less soft tissue than normotensive ($p = 0.01$) and patients with recent symptoms more soft tissue than patients with earlier symptoms ($p = 0.004$). There was no correlation between surface description on ultrasound images compared to the surface judged intraoperatively by the surgeon. Echogenicity on B-mode images was inversely related to soft tissue ($p = 0.005$) and calcification was directly related to echogenicity ($p < 0.0001$). Heterogeneous plaques contained more calcification than homogeneous ($p = 0.003$), however, there was no difference in content of soft tissue.

Conclusion: Ultrasound B-mode characteristics are related to the histological composition of carotid artery plaques and to patient's history. These results may imply that patients with distant symptoms may be regarded and treated as asymptomatic patients whereas asymptomatic patients with echolucent plaques should be considered for carotid endarterectomy.

Key Words: Carotid artery disease; Ultrasound imaging; Carotid plaque histology.

Introduction

The natural history of carotid artery disease has been related to the degree of atherosclerotic narrowing of the vessel and two large randomised trials have documented the clinical value of prophylactic carotid endarterectomy in symptomatic patients with high-grade stenosis.^{1,2} Recent research has also indicated that the appearance of the atherosclerotic plaque, as evaluated by ultrasound B-mode imaging, as well as surface characteristics may be of pathogenic importance. Heterogeneous and echolucent plaques as well as ulcerated plaques may be associated with a greater risk of stroke as compared to homogeneous echogenic plaques.^{3–6} The relationship between appearance of internal carotid artery (ICA) plaques on ultrasound B-mode images and histological composition of the

plaque, as evaluated by histological analysis of the surgically removed specimen, has yielded conflicting results.^{7–10} Lipid-rich atherosclerotic plaques in the coronary arteries have been shown to be associated with a higher risk of cardiac infarction than more fibrous plaques¹¹.

The aim of the present study was to investigate if ultrasound examination prior to carotid endarterectomy as well as the clinical presentation could be related to histological analysis of the removed plaques. The study was funded by the European Economic Community (EEC) and had the participation of 13 centres from nine EEC countries (see acknowledgements).

Material and Methods

Entries into the study were provided by nine of the participating centres. From January 1992 until March 1993, 270 patients undergoing carotid endarterectomy were entered into the study. The 195 males (72%) and

*Presented at the European Society of Vascular Surgeons meeting in Berlin, 4–6 September, 1994.

Please address all correspondence to: Henrik Sillesen, MD, D.M.Sc. (project-leader), Dept. of Vasc. Surg. RK 2101, Rigshospitalet, University of Copenhagen, Blegdamsvej 9, DK 2100 Copenhagen Ø, Denmark.

75 females (28%) had a median age of 63 years (range 35–87).

Preoperative data included symptomatology, risk factors and medication. The type of symptoms, number of attacks, residual neurological deficits and date of last event were noted. Risk factors included hypertension, defined as elevated blood pressure requiring medical treatment, diabetes mellitus and smoking habits. Dosage and duration of platelet aggregation inhibitors and anticoagulants were noted.

Ultrasound examination included assessment of degree of stenosis as performed routinely by the individual centre with recording of peak systolic and end-diastolic velocities. In addition, ultrasound B-mode examination was performed with evaluation of plaque echogenicity, structure and surface.

Plaque echogenicity was evaluated using a scale from 1 to 3, where 1 denoted strong echoes and 3 low echogenicity or echolucency. Plaques were judged as being either homo- or heterogeneous; plaques consisting of homo- as well as heterogeneous parts were classified as heterogeneous. Plaque surface was described as either regular, irregular or not possible to evaluate.

Plaques were evaluated 'on-line' during examination and results recorded immediately. The quality of the ultrasound examination was evaluated by the investigator and scored as good, intermediate or poor.

Quality assessment of ultrasound investigation

All participating centres were experienced in vascular ultrasonography. The project leader visited centres to assure the quality of ultrasound examination technique and data entry. In collaboration with the manufacturers of the two ultrasound systems used by seven of the nine participating centres entering patients, Acuson and ATL, a protocol for quality assessment was developed using a newly developed test object, Gammex RMI 413A. The ultrasound systems were tested for penetration at 5 cm depth as well as axial and lateral resolution. The latter parameters were investigated by measuring axial and lateral diameters of 1 mm pins embedded in liver equivalent tissue at two depths corresponding to the depth of the carotid artery.

One centre which entered only seven patients into the study, was not visited. In the remaining eight centres the examination technique was found satisfactory. All ultrasound systems tested fulfilled the

penetration criteria and were found to have acceptable axial and lateral resolution.

Perioperative data

The surgeon was asked to assess intraoperatively whether ulceration or intraluminal thrombus was present macroscopically. The plaque was removed preferentially in one piece, and the portion of the plaque extending into the external carotid artery was marked by a suture.

Pathological analysis

The specimens were fixed in formalin and the length from the proximal common carotid to the distal internal carotid segments were measured. Serial 3–4 mm transverse sections were taken and labelled. The block nearest the bifurcation was specifically identified. Segments of the external carotid artery were not processed or, if included in blocks, were marked and excluded from subsequent analysis. Blocks were processed into paraffin, sections were cut and stained with haematoxylin and eosin and a connective tissue stain such as van Gieson and/or a stain for elastin.

In the majority of centres histomorphometry was performed directly from the stained sections using an eyepiece graticule. The specific features that were

Table 1. Microscopic features measured by histomorphometry

Fibrous intimal thickening
Calcification
Soft tissue
Old or recent haemorrhage
Lipid constituents
Cholesterol clefts
Foam cell aggregates
Amorphous eosinophilic lipid debris
Fibrin deposits
Inflammatory cell infiltrates

assessed histologically are summarized in Table 1. Since ultrasound cannot distinguish between all histologically discernible features, haemorrhage, lipid and other 'soft' constituents were grouped together as 'soft tissue'.¹² Although the analyses were performed on haematoxylin- and eosin-stained slides, adjacent sections stained by a connective tissue method were available to clarify specific features. Between 5 and 30 fields were examined in order to encompass the surface area of each block. In two centres an interactive image analysis system was used to compute the

area of each constituent. Using a colour monitor and a graphics tablet individual constituents were outlined with a light pen. The areas of these were computed from the number of pixels included within the area. The volume of each constituent was calculated as $V=EA t$ where E is the sum of the area A of the individual constituents in all blocks and t the mean distance between the levels examined in each block, that is the distance between the first and last blocks divided by the number of blocks examined.

Five centres performed pathological analysis, and the remaining centres had their plaques analysed in centre no 2.

Statistical analysis

Normally distributed data were compared with parametric analysis of variance and the remaining data were compared with the Mann-Whitney Rank sum test and Kruskal-Wallis test using the computer program SPSS-PC.

For results confirming the *a priori* hypothesis of the study a p -value < 0.05 was considered significant. However, for all other analyses, the Bonferroni method was applied to allow for multiple comparisons, and a p -value < 0.01 considered as significant.

Results

For a number of the risk factor variables there were occasional missing values, which accounts for the

Table 2. Symptoms, risk factors and medical treatment

Stroke	} (n = 270)	85 (31%)
TIA		65 (24%)
Amaurosis fugax		40 (15%)
Asymptomatic		56 (21%)
Unknown symptomatology		24 (9%)
Hypertension	(n = 200)	110 (55%)
Diabetes	(n = 201)	28 (14%)
Smokers	(n = 168)	93 (55%)
Anticoagulation	(n = 182)	23 (13%)
Aspirin		138 (76%)

varying numbers in tables. Table 2 summarises neurological symptoms, risk factors and medical treatment.

Comparison of risk factors and symptomatology to plaque composition

The distribution of plaque composition among centres is given in Fig. 1. The median percentages of each of the three constituents, fibrous tissue, calcification and soft tissue (primarily haemorrhage and lipid) was similar in all centres.

Age was not significantly related to the composition of plaques; percentage soft tissue related to age: $r = 0.111$, $p = 0.081$; percentage calcification related to age: $r = 0.081$, $p = 0.2$. Plaques from males had significantly more soft tissue than those from females ($p = 0.0006$, Table 3), whereas no difference was found for calcification. There was no difference in symptomatology between sexes. Plaques from patients with arterial hypertension had less soft tissue than normotensive patients ($p = 0.01$, Table 3). Patients with diabetes appeared to have plaques with a higher content of soft tissue; however, this did not reach statistical significance ($p = 0.06$). Smoking was unrelated to the composition of plaques as well as to symptomatology. Plaques from asymptomatic patients appeared to have less soft tissue than symptomatic patients; however, this was not significant. Medication, anticoagulation with warfarin and aspirin were unrelated to plaque composition.

The content of soft tissue was inversely correlated to the time interval between the last symptomatic episode and carotid endarterectomy (Fig. 2). Separating at 3 months, a highly significant difference in soft tissue content was found ($p = 0.0038$, Table 3). The presence of ulceration in plaques appeared to be related to the content of soft tissue; however, this did not reach statistical significance ($p = 0.06$, Table 3). The

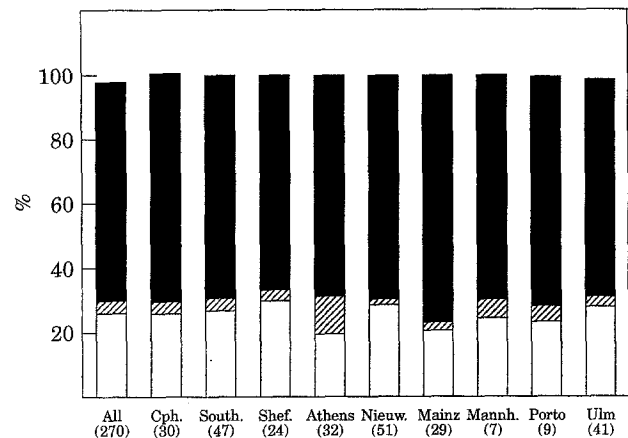


Fig. 1. Relative content of plaque constituents, fibrous tissue, calcification and soft tissue (haemorrhage, lipid) (median values) in total and in the individual centres entering patients into the study. (□) soft; (▨) calcification; (■) fibrous.

Table 3. Relative content of soft tissue and calcification in plaques (median values and range) compared to demographic data and risk factors

	<i>n</i>	% Soft tissue		% Calcification	
Males	195	27 (0-76)	<i>p</i> = 0.0006	2 (0-36)	<i>p</i> = 0.081
Females	75	19 (0-57)		2 (0-26)	
Hypertensive	110	21 (0-76)	<i>p</i> = 0.01	3 (0-25)	<i>p</i> = 0.23
Normotensive	90	29 (0-69)		1.5 (0-36)	
Symptoms within 3 months	92	26 (0-76)	<i>p</i> = 0.0038	3 (0-36)	<i>p</i> = 0.36
> 3 months	41	18 (2-51)		1 (0-27)	
Ulceration	77	27 (3-69)	<i>p</i> = 0.06	4 (0-36)	<i>p</i> = 0.35
No ulceration	56	20 (0-51)		2.5 (0-27)	
Intraluminal thrombus	24	27 (6-59)	<i>p</i> = 0.13	3.5 (0-25)	<i>p</i> = 0.8
No thrombus	108	23 (0-69)		3 (0-36)	

presence of an intraluminal thrombus was unrelated to plaque composition.

Comparison of ultrasound images and plaque composition

The content of soft tissue and echogenicity were inversely related ($p = 0.005$, Table 4) whereas increasing amounts of calcification in plaques correlated with increasing levels of echogenicity ($p < 0.0001$, Table 4). Heterogeneous plaques contained more calcification than homogeneous plaques ($p = 0.003$); no statistical difference was found for content of soft tissue (Table 4).

Surface irregularity, as evaluated by ultrasound imaging, was poorly related to the peroperative findings of ulceration. Of 62 plaques with regular surfaces on ultrasound images, 23 (37%) were found to have ulcerations. Of 57 irregular plaques, only 27

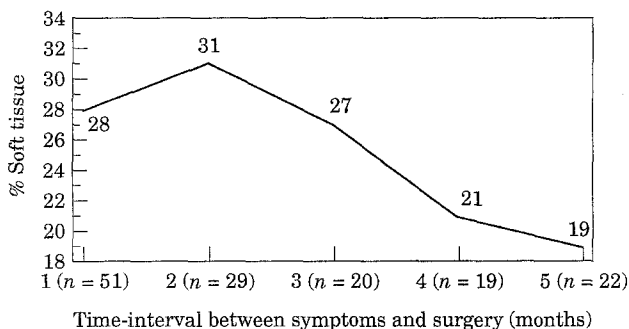


Fig. 2. Relationship between the time interval between presenting symptoms of patients and carotid endarterectomy (months) and the relative amount of soft tissue in the removed carotid artery specimens.

Table 4. Relative content of soft tissue and calcification in plaques (median values and range) compared to echogenicity and plaque structure

	<i>n</i>	% Soft tissue	% Calcification
Echogenicity = 1	61	20 (0-54)	4 (0-27)
Echogenicity = 2	115	26 (3-76)	2 (0-36)
Echogenicity = 3	78	28 (0-63)	1 (0-24)
Analysis of variance:		<i>p</i> = 0.0055	<i>p</i> < 0.0001
Homogeneous	129	26 (0-69)	1 (0-27)
Heterogeneous	136	25 (0-76), <i>p</i> = 0.8	3 (0-36), <i>p</i> = 0.0003

(47%) were found to have ulceration as evaluated intraoperatively. Thus, the observed difference was 10%, 95% confidence intervals -7% to 28%.

Plaque composition was correlated neither to degree of stenosis, peak systolic nor end-diastolic velocity. Plaque structure, homogeneity or heterogeneity, could not be related to clinical presentation. Correcting for ultrasound scan quality, i.e. disregarding the investigations scored to be of poor quality ($n = 31$, 12%), did not affect the results.

A stepwise regression test was performed for the variables found to be statistically related to soft tissue (soft tissue as the dependent factor) (Table 5), to examine their joint dependence. It was found that echogenicity and hypertension were independently related to the percentage of soft tissue.

Discussion

Ulceration and intraplaque haemorrhage are two features of the carotid plaque that have been discussed

Table 5. Results from multiple regression with % soft tissue as the dependent variable ($n = 108$)

Variable	Coefficient	SE	p
Sex	-6.29	3.20	0.052
Echogenicity	4.91	2.01	0.016
Time-event	-3.09	1.71	0.075
Hypertension	6.67	2.90	0.023

Overall $p = 0.001$.

and investigated intensively over the last 10–20 years. Initial reports describing ulcerative carotid lesions indicated an increased risk of stroke, but most of the literature has been unable to reproduce these findings.^{13–16} However, recently, a review of the NASCET data⁵ has thrown further light on this question. In a series of 659 symptomatic patients, 230 fulfilled angiographic criteria for an ulcerated plaque. Following patients in 24 months results showed that ulcerated, severely stenotic plaques carried a three-fold increase in stroke risk compared to non-ulcerated, similarly stenotic plaques. In the present study no relation between patients clinical presentation and ulceration was found; however, ulceration was not evaluated from arteriograms but by the surgeon intraoperatively.

Previous studies comparing B-mode ultrasound with carotid plaque morphology and composition, as evaluated by comparison with the surgically removed specimen, has shown conflicting results. Whereas Hennerici *et al.*¹⁷ and O'Donnell *et al.*¹⁸ found ulceration could be identified accurately by ultrasound, a number of other investigators reported poor correlation.^{7,9,19–22} Of interest was that the studies which also included arteriography did not find this diagnostic modality to be accurate for the identification of ulceration.^{18,21} As pointed out by Comerota *et al.*²¹ some of the disagreement in the literature may be the result of decreasing accuracy with increasing degree of stenosis of both ultrasound and arteriography for identification of ulceration. Since most specimens removed are high-grade lesions, this standard for comparison will not reflect the true accuracy. Furthermore, the lack of a standardised definition of ulceration contributes to this uncertainty.

Two mechanisms for the formation of intraplaque haemorrhage have been suggested: bleeding from the vasa-vasorum or fracture in the surface of the plaque with subsequent bleeding from the vessel lumen. Adapting the former theory, it has been suggested that aspirin therapy could increase the risk of intraplaque

haemorrhage. We did not find an increased content of soft tissue in patients on aspirin therapy. The surface-fracture theory suggests that in a soft lesion, consisting predominantly of a pool of fatty material covered with a fibrous cap, the latter may 'crack' or rupture, exposing the interior to the blood stream. Subsequently, intraplaque haemorrhage or intraluminal thrombus formation may occur, resulting in plaque growth and/or peripheral embolisation. The literature on human studies investigating the pathogenesis directly are naturally scarce. Considering coronary artery disease, a correlation between an increased risk of myocardial infarction and atherosclerotic plaques with high content of lipids has been described by Falk.¹¹ In a recent review on coronary artery disease, Fuster *et al.*²³ described that, in many patients, the acute ischaemic events are a complication not necessarily of severe stenosis but rather of the disruption of the associated mild-to-moderately stenotic, lipid-rich plaques. In contrast to the fibrotic and calcific stenoses, the softer plaques are more prone to disruption because of the high fat content. A high proportion of ruptured plaques were found in patients dying suddenly from coronary artery disease compared to sudden deaths from other causes.²⁴ Extrapolating these theories to the pathogenesis of carotid artery disease it would appear that a lipid-rich plaque would carry a higher risk of rapid growth and/or formation of thrombus with subsequent peripheral embolisation. Interestingly, the study of Leen *et al.*²⁵ found that rather than haemorrhage, the predominant feature in symptomatic plaques was a homogeneous material mixed with cholesterol. The present findings of increased soft tissue in patients presenting with recent symptoms as compared to asymptomatic patients or patients with more ancient symptoms supports these theories.

Early studies indicated that haemorrhage was found more frequently in symptomatic than in asymptomatic patients; however, in some later studies these findings were not reproduced.^{26–31} In a recent review Merritt and Bluth¹⁰ reported that intraplaque haemorrhage was found between 1.2 and 6.7 times more frequently in symptomatic patients as those in asymptomatic patients; however, two studies reporting higher frequency of haemorrhage in asymptomatic patients were not included.^{29,31} A correlation between recent haemorrhage and recent symptoms, in concordance with the theory of surface fracture with subsequent haemorrhage and embolisation, was suggested, but this was not convincingly reproduced by others.^{28,29,31} Our findings of increased soft tissue in patients with recent symptoms as compared to

patients with more remote symptoms is in concordance with these observations. It should be mentioned, however, that most previous studies evaluated the presence or absence of haemorrhage and quantitative data such as those presented here were not given. If the theory of rapid plaque growth following intraplaque haemorrhage is to make any sense, a relatively large amount of blood inside the plaque should be found, much more than reported in the studies giving quantitative data.^{6,25,31} In these reports haemorrhage was found to constitute only 1–2% of the total plaque area in the vast majority of cases. Beach *et al.*³² reported a correlation between increased systolic as well as diastolic velocities in five plaques with haemorrhage compared to five without. However, two of the reported five cases contained less than 2.5% of the average haemorrhage of the remaining three cases, thus, it is difficult to believe that the haemorrhage itself caused the stenosis to become severe in all five cases. The finding of increased stenotic velocity, neither systolic nor diastolic, was not reproduced in the present study. The possibility of 'blood contamination' during endarterectomy and preparation should be kept in mind when only minor haemorrhage is found.

The identification of intraplaque haemorrhage by ultrasound has also been investigated intensively. Focusing on the studies where the reference was histological examination of the removed specimen, Widder *et al.*⁷ among 169 cases, found echogenic plaques to consist primarily of fibrous tissue, whereas echolucent lesions consisted of atheromatous debris and haemorrhage. Gray-Weale *et al.*⁴ reporting on 244 cases, found that of four plaque-types, the echolucent types (1 and 2) were much more commonly associated with intraplaque haemorrhage than the more echogenic types (3 and 4). In a study of 53 cases, Bluth *et al.*³³ reported that heterogeneous plaques were more often associated with haemorrhage than homogeneous lesions. Whereas the three studies mentioned above only looked for the presence or absence of intraplaque haemorrhage, Rattliff *et al.*⁹ examined 42 patients where the histological results were graded semi-quantitatively on a scale from 1 to 3. The only significant correlation found was between high echogenicity and calcified plaques. Among the 27 echolucent lesions, only 13 had a high proportion of intramural thrombus, however, data for content of lipid was not provided. The only previous study on the accuracy of B-mode ultrasound for identification of intraplaque haemorrhage, and where histological results are quantified, is that of Feeley *et al.*⁶ The 52 cases were graded using the Gray-Weale classification⁴ and the echolucent lesions (types 1 and 2) were

found to contain more soft tissue, although the authors reported statistics that types 3 and 4 (echogenic types) had a sensitivity of 94% and a specificity of 67% in predicting a plaque with more than 80% fibrous tissue, a similar relative content of fibrous tissue found in echogenic plaques in the present study. Interestingly, these authors also found that the amount of fibrous tissue was higher in asymptomatic patients compared with patients experiencing increasing number of ischaemic events. The findings in the present study of an inverse correlation between echogenicity and content of soft tissue is in accordance with the study of Feeley *et al.*⁶ The finding of a direct relationship between echogenicity and content of calcification is in accordance with Rattliff *et al.*⁹

One major problem in trying to compare these studies is the lack of standardised criteria for ultrasound classification as well as histological evaluation. In the case of ultrasound some groups have adapted a classification system with certain 'plaque types' whereas others have related findings to plaque-structure (homogeneous/heterogeneous plaques) or echogenicity. We feel that the carotid artery plaque is best classified simply by describing the echogenicity and plaque structure separately. As mentioned previously, we are convinced that quantitative results are necessary to evaluate this relationship, in part due to the limited resolution of ultrasound B-mode imaging. It does not seem reasonable that an echolucent structure, occupying 1–2% of the plaque volume (i.e. haemorrhage), should be identifiable with the ultrasound equipment used over the last decade. The grouping together of lipid and haemorrhage into 'soft tissue' was done because ultrasound cannot distinguish between these two constituents.¹²

The risk associated with features evaluated by B-mode imaging of atherosclerotic carotid artery plaques has been described in some previous papers. Sterpetti *et al.*³⁴ followed 214 patients, not considered candidates for surgery, for an average of 34 months. Twenty-five patients developed new symptoms and multivariate analysis found heterogeneous plaques statistically correlated with development of new symptoms. In a study where 300 asymptomatic patients, with less than 60% stenosis, were followed for 4 years, Belcaro *et al.*³⁵ found that heterogeneous, echolucent plaques resulted in more cerebral symptoms than homogeneous, echogenic plaques. O'Halloran *et al.*³⁶ followed 293 asymptomatic patients for an average of 46 months. All 42 patients with a soft lesion of more than 75% reduction in cross-sectional area became symptomatic. Comparing patients with more than 75% stenosis, soft plaques resulted in a higher cumulative 5-year stroke risk than dense

plaques. Finally, Langsfield *et al.*³ studied 419 asymptomatic patients for an average of 15-22 months (different groups). Only 31 developed new symptoms; however, the data indicated that patients with heterogeneous plaques or plaques undergoing a change may be at increased risk. These studies clearly indicate that ultrasonic features are related to the natural history of carotid artery disease, a finding supported by the data of the present study. With the exception of the work of O'Halloran *et al.*³⁶ work, these reports suffer from the weakness that 'new symptoms' consists of both TIAs and stroke. The material in the study of O'Halloran *et al.*³⁶ was not uniform, thus, the need for a randomised trial taking ultrasound plaque features into account is most pressing. Classification of carotid artery plaques examined by B-mode ultrasound is performed differently by various authors. We feel that rather than defining plaque types, which may or may not correspond to histological features, plaques should be described by their appearance on the ultrasound image.

In conclusion, this study has shown that the ultrasound appearance of the carotid artery plaque is related to the histological composition: echogenicity is inversely related to the relative amount of soft tissue. Clinical presentation may also be related to plaque composition: symptomatic patients with recent symptoms had more soft tissue in plaques than those with distant symptoms. The clinical implications of this study could be dramatic. First, symptomatic patients with more distant symptoms might be regarded as asymptomatic and treated conservatively. Second, asymptomatic patients with poorly echogenic plaques, should probably be considered for surgery. It seems justified that a randomised trial where ultrasound B-mode based plaque characteristics are included should be performed.

Acknowledgements

The study was funded by the Commission of the European Community, Medical and Health Research Programme: Medical Technology Development, Contract # MR4*- 0318-DK. Participating centres: **Rigshospitalet, Copenhagen, Denmark**, H. Sillesen (project leader), T. Nielsen, H. Laursen and T.V. Schroeder; **Southampton General Hospital, U.K.**, P. Gallagher, V. Gazzard and M. Campbell; **Royal Hallamshire Hospital, Sheffield, U.K.**, S. Sherriff, K. Survana, S. Rogers and J.D. Beard; **St. Antonius Hospital, Nieuwegein, Holland**, R.G.A. Ackerstaff, A. van Swijndrecht, F. Moll and E. Elbers; **Johannes Gutenberg-Universität Mainz, Germany**, V.A. Knappertz, C. Sievers and G. Rotatcher; **Universität's Klinik Ulm, Germany**, B. Widder and M. Goertler; **Klinikum Mannheim, Germany**, U. Sliwka and W. Mess; **University of Crete Medical School and Air Force and VA General Hospital, Athens**, Municipal Hospital Athens and **University Hospital of Athens, Greece**, D. Kardoulas, G. Gourtsoyannis, D.

Georgopolous and A. Antoniou; **Hospital Geral de Santo Antonio, Porto, Portugal**, J. Galhano-Rodrigues and M. Caetano Pereira; **Southend General Hospital, Southend, U.K.**, T.K. Hames; **Centre Hospitalier Regional et Universitaire de Tours, France**, P. Arbeille; **L. Sacco Hospital, Milano, Italy**, M. Catalano; **Hospital Princesps d'España, Barcelona, Spain**, R. Vila.

References

- 1 EUROPEAN CAROTID SURGERY TRIALISTS GROUP. MRC European carotid surgery trial: interim results of symptomatic patients with severe (70-99%) or with mild (0-29%) stenosis. *Lancet* 1991; 337: 1235-1243.
- 2 NORTH AMERICAN SYMPTOMATIC CAROTID ENDARTERECTOMY TRIAL COLLABORATORS. Beneficial effect of carotid endarterectomy in symptomatic patients with high-grade carotid stenosis. *N Engl J Med* 1991; 325: 445-453.
- 3 LANGSFIELD M, GRAY-WEALE AC, LUSBY RJ. The role of plaque morphology and diameter reduction in the development of new symptoms in asymptomatic carotid disease. *J Vasc Surg* 1989; 9: 548-557.
- 4 GRAY-WEALE AC, GRAHAM JC, BURNETT JR, BYRNE K, LUSBY RJ. Carotid artery atheroma: Comparison of preoperative B-mode ultrasound appearance with carotid endarterectomy specimen pathology. *J Cardiovasc Surg* 1988; 29: 676-681.
- 5 ELIASZEW M, STREIFLER JY, FOX AJ, HACHINSKI VC, FERGUSON GG, BARNETT HJM. Significance of plaque ulceration in symptomatic patients with high-grade carotid stenosis. *Stroke* 1994; 25: 304-308.
- 6 FEELEY TM, LEEN EJ, COLGAN MP, MOORE DJ, HOURIHANE DO, SHANK GD. Histologic characteristics of carotid artery plaque. *J Vasc Surg* 1991; 13: 719-724.
- 7 WIDDER B, PAULAT K, HACKSPACHER J, HAMANN H, HUTCHSENREITER S, KREUTZER C *et al.* Morphological characterization of carotid artery stenoses by ultrasound duplex scanning. *Ultrasound Med Biol* 1990; 16: 349-354.
- 8 GOES E, JANNSENS W, MAILLET B, FRESON M, STEYAERT L, OSTEAUX M. Tissue characterization of atheromatous plaques: Correlation between ultrasound image and histological findings. *J Clin Ultrasound* 1990; 18: 611-617.
- 9 RATTLIFF DA, GALLAGHER PJ, HAMES TK, HUMPHRIES KN, WEBSTER JHH, CHANT ADB. Characterization of carotid artery disease: Comparison of duplex scanning with histology. *Ultrasound Med Biol* 1985; 11: 835-840.
- 10 MERRITT CRB, BLUTH EI. Ultrasound identification of plaque composition. In: LABS KH *et al.* eds. *Diagnostic Vascular Ultrasound* London: Edward Arnold, 1992; 213-224.
- 11 FALK E. Morphologic features of unstable atherothrombotic plaques underlying acute coronary syndromes. *Am J Cardiol* 1989; 63: 114E-120E.
- 12 BOCK RW, LUSBY RJ. Carotid plaque morphology and interpretation of the echolucent lesions. In: LABS KH *et al.* eds. *Diagnostic Vascular Ultrasound* London: Edward Arnold, 1992; 225-236.
- 13 MOORE WS, BOREN C, MALONE JM, ROON AJ, EISENBERG R, GOLDSTONE J *et al.* The natural history of non-stenotic, asymptomatic ulcerative lesions of the carotid artery. *Arch Surg* 1978; 113: 1352-1359.
- 14 KROENER JM, DORN PL, SHOOR PM, WICKBOM IG, BERNSTEIN EF. Prognosis of asymptomatic ulcerating carotid lesions. *Arch Surg* 1980; 115: 1387-1392.
- 15 HARWARD TRS, KROENER JM, WICKBOM IG, BERNSTEIN EF. Natural history of asymptomatic ulcerative plaques of the carotid bifurcation. *Am J Surg* 1983; 146: 208-212.
- 16 GROTTA JC, BIGELOW RH, HU H, HANKINS L, FIELDS WS. The significance of carotid stenosis or ulceration. *Neurology* 1984; 34: 437-442.

- 17 HENNERICI M, REIFSCHEIDER G, TROCKEL U, AULICH A. Detection of early atherosclerotic lesions by duplex scanning of the carotid artery. *J Clin Ultrasound* 1984; **12**: 455-464.
- 18 O'DONNELL TF, ERDOES L, MACKAY WC, MCCULLOUGH J, SHEPARD A, HEGGERICK P, ISNER J, CALLOW AD: Correlation of B-mode ultrasound imaging and arteriography with pathology findings at carotid endarterectomy. *Arch Surg* 1985; **120**: 443-449.
- 19 RICOTTA JJ, BRYAN FA, BOND MG, KURTZ A, O'LEARY DH, RAINES JK *et al*. Multicenter validation of real-time (B-mode) ultrasound, arteriography and pathologic examination. *J Vasc Surg* 1987; **6**: 512-520.
- 20 O'LEARY DH, HOLEN J, RICOTTA JJ, ROE S, SCHENK EA. Carotid bifurcation disease: Prediction of ulceration by B-mode US. *Radiology* 1987; **162**: 523-525.
- 21 COMEROTA AJ, KATZ ML, WHITE JV, GROSH JD. The preoperative diagnosis of the ulcerated atheroma. *J Vasc Surg* 1990; **11**: 505-510.
- 22 BLUTH EI, McVAY LV, MERRITT CRB, SULLIVAN MA. The identification of ulcerative plaque with high resolution duplex carotid scanning. *J Ultrasound Med* 1988; **7**: 73-76.
- 23 FUSTER V, BADIMON L, BADIMON JJ, CHESEBRO JH. The pathogenesis of coronary artery disease and the acute coronary syndromes. *N Engl J Med* 1992; **326**: 242-250.
- 24 DAVIES MJ, THOMAS A. Thrombosis and acute coronary artery lesions in sudden cardiac ischaemic death. *N Engl J Med* 1984; **310**: 1137-1140.
- 25 LEEN EJ, FEELEY TM, COLGAN MP, O'MALLEY K, MOORE DJ, HOURIHANE DO, SHANIK GD. 'Hemorrhagic' carotid plaques do not contain hemorrhage. *Eur J Vasc Surg* 1990; **4**: 123-128.
- 26 PERRSON AV, ROBICHAUX WT, SILVERMAN M. The natural history of carotid plaque development. *Arch Surg* 1983; **118**: 1048-1052.
- 27 IMPARATO AM, RILES TS, MINTZER R, BAUMANN FG. The importance of hemorrhage in the relationship between gross morphologic characteristics and cerebral symptoms in 376 carotid artery plaques. *Ann Surg* 1983; **197**: 195-203.
- 28 LUSBY RJ, FERRELL LD, EHRENFELD WK, STONEY RJ, WYLIE EJ. Carotid plaque hemorrhage. *Arch Surg* 1982; **117**: 1479-1487.
- 29 LENNIHAN L, KUPSKY WJ, MOHR JP, HAUSER AH, CORRELL JW, QUEST DO. Lack of association between carotid plaque hematomas and ischaemic cerebral symptoms. *Stroke* 1987; **18**: 879-881.
- 30 AMMAR AD, WILSON RL, TRAVERS H, LIN JJ, FARHA SJ, CHANG FC. Intra-plaque hemorrhage: Its significance in cerebrovascular disease. *Am J Surg* 1984; **148**: 840-843.
- 31 BASSIOUNY HS, DAVIS H, MASSAWA N, GEWERTZ BL, GLAGOW S, ZARINS CK. Critical Carotid stenosis: Morphologic and chemical similarity between symptomatic and asymptomatic plaques. *J Vasc Surg* 1989; **9**: 202-212.
- 32 BEACH KW, HATSUKAMI T, DETMAR PR, PRIMOZICH JF, FARGUSON MS, GORDON D, ALPERS CE, BURNS DH, THACKRAY BD, STRANDNESS DE. Carotid artery intraplaque hemorrhage and stenotic velocity. *Stroke* 1993; **24**: 314-319.
- 33 BLUTH EI, KAY D, MERRITT CRB, SULLIVAN M, FARR G, MILLS NL, FOREMAN M, SLOAN K, SCHLATER M, STEWART J. Sonographic characterization of carotid plaque: detection of hemorrhage. *AJR* 1986; **146**: 1061-1065.
- 34 STERPETTI AV, SCHULTZ RD, FELDHAUS RD, DAVENPORT KL, RICHARDSON M, FARINA C, HUNTER WJ: Ultrasonographic features of carotid plaque and the risk of subsequent neurologic deficits. *Surgery* 1988; **104**: 652-660.
- 35 BELCARO G, LAURORA G, CESARONE MR, DE SANCTIS ME, INCANDELA L, FASCETTI E, GEROUKAKOS G, RAMASWAMI G, PIERANGELI A, NICOLAIDES AN. Ultrasonic classification of carotid plaques causing less than 60% stenosis according to ultrasound morphology and events. *J Cardiovasc Surg* 1993; **34**: 287-294.
- 36 O'HALLORAN LW, KENNELLY MM, McCLURKEN M, JOHNSON JM. Natural history of asymptomatic carotid plaque. *Am J Surg* 1987; **154**: 659-661.

Accepted 25 November 1994