

Manuscript Number: YTVJL-D-17-00838R3

Title: Whole-slide imaging: cytomorphological descriptive capacity and intra-observer agreement in canine lymphoma samples

Article Type: Original article

Keywords: Whole slide imaging; Telepathology; Cytology; Lymphoma; Dogs.

Corresponding Author: Dr. Federico Bonsembiante, Ph.D

Corresponding Author's Institution: University of Padua

First Author: Federico Bonsembiante, Ph.D

Order of Authors: Federico Bonsembiante, Ph.D; Valeria Martini; Ugo Bonfanti; Giacomo Casarin; Davide Trez; Maria Elena Gelain

Abstract: The term 'whole-slide imaging (WSI)' refers to the use of robotic microscopes for computerising entire slides into digital images. This study aimed to assess the agreement between WSI and optical microscopy for evaluating canine lymphoma cytological samples. Forty-four slides were computerised using a WSI scanner. The digital and glass slides were examined by three observers with different levels of expertise. The morphology of neoplastic cells and the lymphoma grade were scored, on the basis of the updated Kiel classification, and the intra-observer agreement was assessed. Moreover, the accuracy of determining the lymphoma grade of the digital and glass slides based on the results of flow-cytometry (FC) was established.

The overall intra-observer agreement for the cytomorphological features was fair to moderate (from 0.34 to 0.52) for the three observers, whereas the intra-observer agreement for the evaluation of malignancy grade was moderate (from 0.44 to 0.53). The diagnostic agreement between FC and digital slides was slight (0.16) for the inexperienced observer, fair (0.32) for the mildly experienced observer, and moderate (0.50) for the experienced observer, whereas the diagnostic agreement between FC and glass slides was fair (0.37) for the inexperienced observer, substantial (0.63) for the mildly experienced observer, and moderate (0.50) for the experienced observer. Our findings underline the importance of observer experience in determining the malignancy grade, especially if digital slides are used. The study also identifies some technical limitations of the tested WSI scanner, mainly linked to image quality, which affected the morphological evaluation of the neoplastic cells.

1 **Original Article**

2

3 **Whole-slide imaging: cytomorphological descriptive capacity and intra-observer agreement in**
4 **canine lymphoma samples**

5

6 F. Bonsembiante ^{a,*}, V. Martini ^b, Ugo Bonfanti ^c, G. Casarin ^a, D. Trez ^a, M. E. Gelain ^a

7

8 ^a *Department of Comparative Biomedicine and Food Science, University of Padua, Viale*
9 *dell'Università 16, 35020 Legnaro (PD), Italy.*

10 ^b *Department of Veterinary Medicine, University of Milan, Via Celoria 10, 20133 Milan, Italy.*

11 ^c *La Vallonèa Veterinary Diagnostic Laboratory, Via Sirtori 9, 20017 Passirana di Rho (MI), Italy.*

12

13

14

15

16 * Corresponding author. Tel: +39 049 8272518

17 *E-mail address:* federico.bonsembiante@unipd.it (F. Bonsembiante)

18

19 **Abstract**

20 The term 'whole-slide imaging (WSI)' refers to the use of robotic microscopes for
21 computerising entire slides into digital images. This study aimed to assess the agreement between
22 WSI and optical microscopy for evaluating canine lymphoma cytological samples. Forty-four slides
23 were computerised using a WSI scanner. The digital and glass slides were examined by three
24 observers with different levels of expertise. The morphology of neoplastic cells and the lymphoma
25 grade were scored, on the basis of the updated Kiel classification, and the intra-observer agreement
26 was assessed. Moreover, the accuracy of determining the lymphoma grade of the digital and glass
27 slides based on the results of flow-cytometry (FC) was established.

28
29 The overall intra-observer agreement for the cytomorphological features was fair to
30 moderate (from 0.34 to 0.52) for the three observers, whereas the intra-observer agreement for the
31 evaluation of malignancy grade was moderate (from 0.44 to 0.53). The diagnostic agreement
32 between FC and digital slides was slight (0.16) for the inexperienced observer, fair (0.32) for the
33 mildly experienced observer, and moderate (0.50) for the experienced observer, whereas the
34 diagnostic agreement between FC and glass slides was fair (0.37) for the inexperienced observer,
35 substantial (0.63) for the mildly experienced observer, and moderate (0.50) for the experienced
36 observer. Our findings underline the importance of observer experience in determining the
37 malignancy grade, especially if digital slides are used. The study also identifies some technical
38 limitations of the tested WSI scanner, mainly linked to image quality, which affected the
39 morphological evaluation of the neoplastic cells.

40 *Keywords:* Whole-slide imaging; Telepathology; Cytology; Lymphoma; Dogs.

41

Comment [FB1]: Lines 23-40 of YTVJL-D17-00838R2 Deleted - The term 'whole-slide imaging (WSI)' is referred to robotic microscopes capable to computerize entire slides into digital images. The aim of this study is to assess the agreement between WSI and optical microscopy in the evaluation of canine lymphoma cytological samples. Forty-four slides were computerize using a WSI scanner. Digital and optical slides were examined by three observers with different levels of expertise. All the morphological features of the neoplastic cells, grading, and phenotype were scored, based on the Kiel-updated classification, and the intra-observer agreement was assessed. Moreover, the accuracy in determination of grading and immunophenotype of digital and optical slides based of the results of flow-cytometry (FC) was established.

The overall intra-observer agreement for the cytomorphological features was fair for all the observers (from 0.24 to 0.37), whereas the overall intra-observer agreement in the evaluation of grading and immunophenotype was fair to moderate (from 0.31 to 0.54). The diagnostic agreement between FC and digital slides was 0.33 for observer one, 0.63 for observer two, 0.47 for observer three, whereas the diagnostic agreement between FC and optical slides was 0.24 for observer one, 0.77 for observer two, 0.73 for observer three. Our study underlines the possibility of technical limitations of the WSI scanner tested, mainly linked to the quality of the images, especially for less experienced observers.

42 Introduction

43 Digital pathology is a branch of pathology in which images are visualised on a computer
44 monitor rather than directly through a microscope (Weinstein, 1986). Telepathology has evolved
45 from the transmission of static images captured using microscope-mounted cameras to the use of
46 robotic microscopes controlled by pathologists at distant sites and, more recently, to whole-slide
47 imaging (WSI) (Webster and Dunstan, 2014). A WSI scanner is a robotic microscope capable of
48 digitising an entire glass slide (GS) by using a software to merge the individually captured images
49 into a composite digital image (Pantanowitz et al., 2013). The digital images can be viewed either
50 on the computer used to scan the slides, by using a specific software designed to emulate a light
51 microscope (Webster and Dunstan, 2014), or at a remote site via a high-speed internet connection
52 (Steinberg and Ali, 2001). WSI maintains the relative simplicity of static-image transfer and
53 eliminates its limitations, by making available the entire specimen for review (Wilbur, 2011) and
54 allowing the magnification of the digital slide (DS) to be changed (Wilbur et al., 2009). Moreover,
55 the most updated scanners have the capability to perform multiple line scans of the same area at
56 different fields of focus (Webster and Dunstan, 2014). This function, the so-called 'z-stack' mode,
57 is most important in acquiring images of cytological specimens, in which cells are often arranged in
58 multiple layers (El-Gabry et al., 2014).

59
60 In human medicine, WSI is used for several reasons, mainly digital diagnostics and
61 teleconsultation (Al-Janabi et al., 2012). In veterinary medicine, despite the increased use of WSI
62 instruments in reference laboratories, few reports on digital pathology are present in the literature.
63 To the authors' knowledge, no papers focusing on the morphological descriptive capability of WSI
64 have been published. Moreover, the use of WSI has never been validated, and its capability to
65 replace the conventional microscope has not been assessed using cytological samples.
66

Comment [FB2]: Line 45 of YTVJL-D17-00838R2 Deleted – seen through

Comment [FB3]: Line 47 of YTVJL-D17-00838R2 Deleted - with

Comment [FB4]: Line 47 of YTVJL-D17-00838R2 Deleted - into

Comment [FB5]: Line 48 of YTVJL-D17-00838R2 Deleted - a

Comment [FB6]: Line 48 of YTVJL-D17-00838R2 Deleted – localized in a

Comment [FB7]: Line 48 of YTVJL-D17-00838R2 Deleted - ,

Comment [FB8]: Line 48 of YTVJL-D17-00838R2 Deleted – in the

Comment [FB9]: Line 49 of YTVJL-D17-00838R2 Deleted -

Comment [FB10]: Line 50 of YTVJL-D17-00838R2 Deleted -

Comment [FB11]: Line 50 of YTVJL-D17-00838R2 Deleted -

Comment [FB12]: Line 51 of YTVJL-D17-00838R2 Deleted -

Comment [FB13]: Line 52 of YTVJL-D17-00838R2 Deleted -

Comment [FB14]: Line 52 of YTVJL-D17-00838R2 Deleted -

Comment [FB15]: Line 53 of YTVJL-D17-00838R2 Deleted -

Comment [FB16]: Line 55 of YTVJL-D17-00838R2 Deleted -

Comment [FB17]: Line 55 of YTVJL-D17-00838R2 Deleted -

Comment [FB18]: Line 55 of YTVJL-D17-00838R2 Deleted -

Comment [FB19]: Line 56 of YTVJL-D17-00838R2 Deleted -

Comment [FB20]: Line 56 of YTVJL-D17-00838R2 Deleted -

Comment [FB21]: Line 57 of YTVJL-D17-00838R2 Deleted -

Comment [FB22]: Line 57 of YTVJL-D17-00838R2 Deleted -

Comment [FB23]: Line 57 of YTVJL-D17-00838R2 Deleted -

Comment [FB24]: Line 58 of YTVJL-D17-00838R2 Deleted -

Comment [FB25]: Line 59 of YTVJL-D17-00838R2 Deleted -

Comment [FB26]: Line 59 of YTVJL-D17-00838R2 Deleted -

Comment [FB27]: Line 62 of YTVJL-D17-00838R2 Deleted -

Comment [FB28]: Line 64 of YTVJL-D17-00838R2 Deleted -

Comment [FB29]: Line 65 of YTVJL-D17-00838R2 Deleted -

Comment [FB30]: Line 66 of YTVJL-D17-00838R2 Deleted -

Comment [FB31]: Line 66 of YTVJL-D17-00838R2 Deleted -

Comment [FB32]: Line 66 of YTVJL-D17-00838R2 Deleted -

67 One of the most commonly obtained cytological samples in canine medicine is the fine
68 needle aspirate (FNA) of lymph nodes. This technique is used to discriminate between
69 inflammatory and neoplastic disorders, among which, non-Hodgkin's lymphoma is the most
70 common primary neoplasia affecting the lymph node (Richards and Suter, 2015). The identification
71 of a clonal expansion of neoplastic lymphocytes is essential for lymphoma diagnosis. Histology,
72 immunocytochemistry, immunohistochemistry, flow cytometry (FC) and PCR to detect clonal
73 antigen receptor gene rearrangement (PARR) are fundamental tools that can be used to confirm the
74 diagnosis of lymphoma and to identify the phenotype for prognostic purposes (Burkhard and
75 Bienze, 2013). These diagnostic procedures can be performed only in specialized laboratories.
76 Commonly, the cytological examination of lymph node samples obtained via FNA is the first step
77 in the diagnosis of lymphoproliferative diseases in dogs, because it is minimally invasive,
78 inexpensive, and fast (Amores-Fuster et al., 2015). Moreover, the cytological features are used to
79 classify the different lymphoma subtypes with prognostic significance (Ponce et al., 2004).
80 However, the morphological evaluation of neoplastic lymphocytes is complex, and the opinion of a
81 skilled clinical pathologist is often required for the correct diagnosis and classification of the
82 different lymphoma subtypes.

84 The possibility to use WSI instruments could improve the quality of cytological services,
85 and could provide the possibility to share cytological samples of canine lymphomas with more
86 experienced clinical pathologists. However, before this technology can be applied in veterinary
87 cytology, the reliability of cytological evaluation and the technical aspects of the scanning process
88 must be evaluated. The aims of this study were to assess the following: 1) the intra-observer
89 agreement (IOA) between WSI (D-sight, A. Menarini Diagnostics S.r.l) and optical microscopy in
90 the evaluation of cellular morphology in canine lymphoma samples, by using the updated Kiel
91 classification (Ponce et al. 2010); 2) the IOA between WSI and optical microscopy in the
92 assessment of lymphoma grading; and 3) whether the accuracy of grading assessment varied

Comment [FB33]: Line 78 of YTVJL-D17-00838R2 Deleted - s'

Comment [FB34]: Line 78 of YTVJL-D17-00838R2 Deleted - by

Comment [FB35]: Line 78 of YTVJL-D17-00838R2 Deleted - used

Comment [FB36]: Line 79 of YTVJL-D17-00838R2 Deleted - '

Comment [FB37]: Line 80 of YTVJL-D17-00838R2 Deleted - a

Comment [FB38]: Line 82 of YTVJL-D17-00838R2 Deleted - often

Comment [FB39]: Line 82 of YTVJL-D17-00838R2 Deleted - -

Comment [FB40]: Line 83 of YTVJL-D17-00838R2 Deleted - s

Comment [FB41]: Line 86 of YTVJL-D17-00838R2 Deleted - giving

Comment [FB42]: Line 87 of YTVJL-D17-00838R2 Deleted - -

Comment [FB43]: Line 88 of YTVJL-D17-00838R2 Deleted - the

Comment [FB44]: Line 89 of YTVJL-D17-00838R2 Deleted - are

Comment [FB45]: Line 89 of YTVJL-D17-00838R2 Deleted - a

Comment [FB46]: Line 90 of YTVJL-D17-00838R2 Deleted - scanner

Comment [FB47]: Line 92 of YTVJL-D17-00838R2 Deleted - the

Comment [FB48]: Line 92 of YTVJL-D17-00838R2 Deleted -

Comment [FB49]: Line 93 of YTVJL-D17-00838R2 Deleted -

Comment [FB50]: Line 93 of YTVJL-D17-00838R2 Deleted -

Comment [FB51]: Line 93 of YTVJL-D17-00838R2 Deleted -

93 between WSI scanner and optical microscopy, by using FC as a reference method. Moreover, the
94 influence of the level of observer expertise on their performance was evaluated.

Comment [FB52]: Line 94 of YTVJL-D17-00838R2 Deleted - the

Comment [FB53]: Line 94 of YTVJL-D17-00838R2 Deleted - how

Comment [FB54]: Line 95 of YTVJL-D17-00838R2 Deleted – could influence

Comment [FB55]: Line 95 of YTVJL-D17-00838R2 Deleted – of the observers has also been

Comment [FB56]: Line 100 of YTVJL-D17-00838R2 Deleted - interrogated

Comment [FB57]: Line 101 of YTVJL-D17-00838R2 Deleted - based

Comment [FB58]: Line 103 of YTVJL-D17-00838R2 Deleted – in order

Comment [FB59]: Line 104 of YTVJL-D17-00838R2 Deleted - the

Comment [FB60]: Line 105 of YTVJL-D17-00838R2

Comment [FB61]: Line 106 of

Comment [FB62]: Line 106 of

Comment [FB63]: Line 107 of

Comment [FB64]: Line 107 of

Comment [FB65]: Line 108 of

Comment [FB66]: Line 108 of

Comment [FB67]: Line 109 of

Comment [FB68]: Line 109 of

Comment [FB69]: Line 110 of

Comment [FB70]: Line 111 of

Comment [FB71]: Line 112 of

Comment [FB72]: Line 113 of

Comment [FB73]: Line 113 of

Comment [FB74]: Line 117 of

Comment [FB75]: Line 117 of

Comment [FB76]: Line 118 of

Comment [FB77]: Line s 118-119

Comment [FB78]: Line 119 of

Comment [FB79]: Lines 119-120

Comment [FB80]: Line 120 of

96 Materials and methods

97 Cytological samples and observers

98 The database of the Flow Cytometry Service of the Department of Veterinary Medicine
99 (University of Milan, Milan, Italy) was searched to select consecutive canine lymphoma samples
100 diagnosed on the basis of clinical, clinico-pathological, cytological, and FC data, from January 2015
101 to June 2015. Only cases with good-quality lymph node cytological smears were enrolled in the
102 study, to allow for a detailed evaluation of the morphological features of the neoplastic cells. FC
103 analysis and the criteria for lymphoma diagnosis were applied as previously described (Gelain et al.,
104 2008). The following antibodies were used: CD45 (clone YKIX716.13, Serotec), CD3 (clone
105 CA17.2A12, Serotec), CD5 (clone YKIX322.3, Serotec), CD4 (clone YKIX302.9, Serotec), CD8
106 (clone YCATE55.9, Serotec), CD21 (clone CA21D6, Serotec), CD79a (clone MCA1298F,
107 Serotec), and CD34 (clone 1H6, Pharmingen, BD Bioscience). Neoplastic cells were identified on
108 the morphological cytogram (forward scatter [FSC] versus side scatter) or on the CD45 versus FSC
109 cytogram. The percentage of neoplastic cells, the phenotype, and the mean FSC (mean cellular size)
110 were used to identify the cell type (B-cell or T-cell) and cell size. GS were stained with May-
111 Grünwald-Giemsa stain, and for each case, the slide with higher cellularity and better preservation
112 was selected.

114 Three observers with different levels of expertise participated in the study, and all were
115 blinded to the FC results. The inexperienced observer, a PhD student, had the lower experience in
116 cytological evaluation; the mildly experienced observer, a postdoctoral researcher, had intermediate
117 experience in cytological evaluation; and the experienced observer, a board-certified clinical-

118 pathologist, had extensive experience in cytological evaluation. None of the observers had
119 previously used the WSI technology for routine diagnostic procedures.

Comment [FB81]: Lines 11120-121 of YTVJL-D17-00838R2 Deleted - represented the higher level of cytological expertise

120

Comment [FB82]: Line 121 of YTVJL-D17-00838R2 Deleted - never

121 *Digital slides*

Comment [FB83]: Line 121 of YTVJL-D17-00838R2 Deleted - before

122 All the GSs were scanned using the 40× objective with the z-stack modality by using a WSI

123 scanner (D-sight, A. Menarini Diagnostics S.r.l.) to obtain the DSs. The DSs were scanned using

Comment [FB84]: Line 126 of YTVJL-D17-00838R2 Deleted – digital slides ()

124 automated tissue detection and focus-point assignments with seven-line scans of the same area at

125 different fields of focus. The research case numbers assigned to the DSs were different from those

Comment [FB85]: Line 127 of YTVJL-D17-00838R2 Deleted - 7

126 assigned to the corresponding GSs to minimize recall bias. DSs were subsequently uploaded to a

Comment [FB86]: Line 127 of YTVJL-D17-00838R2 Deleted - s

127 server to be evaluated by the three observers using an online software (Telepathology, Visia

Comment [FB87]: Line 128 of YTVJL-D17-00838R2 Deleted - of

128 Imaging S.r.l.) (Fig. 1). The monitors used ranged from 14 to 15.6 inches, with a screen resolution

Comment [FB88]: Line 130 of YTVJL-D17-00838R2 Deleted – (Telepathology, Visia imaging S.r.l.)

129 of at least 1366×768 pixels, and no special monitor or setting was used. Each observer used his own

130 laptop’s screen to evaluate all the DSs. Between the evaluation of GS and DS by the same observer,

Comment [FB89]: Line 132 of YTVJL-D17-00838R2 Deleted - were

131 a wash-out period of at least one month was imposed, to ensure the observers did not remember the

Comment [FB90]: Line 134 of YTVJL-D17-00838R2 Deleted - waited

132 cases from the previous viewings.

Comment [FB91]: Line 134 of YTVJL-D17-00838R2 Deleted – avoid that

133

134 *Morphological features evaluated*

Comment [FB92]: Line 134 of YTVJL-D17-00838R2 Deleted - ed

135 According to the updated Kiel classification (Fournel-Fleury et al., 1997; Ponce et al., 2010)

136 the following parameters were recorded for both the DSs and GSs by each observer at 40×

Comment [FB93]: Line 137 of YTVJL-D17-00838R2 Deleted - -updated

137 magnification: pleomorphism of the neoplastic population, cellular size, amount and colour of

138 cytoplasm, nuclear shape, nuclear chromatin pattern, and nucleoli. Specifically, the following

139 features were evaluated:

Comment [FB94]: Line 142 of YTVJL-D17-00838R2 Deleted - with

140 a. The cellular size was based on the comparison between the red blood cells and nucleus of

Comment [FB95]: Line 142 of YTVJL-D17-00838R2 Deleted - and

141 the cells, and was defined as small, medium, or large depending on whether it was smaller,

Comment [FB96]: Line 142 of YTVJL-D17-00838R2 Deleted - if

142 equal to, or larger than two erythrocytes, respectively.

143 b. Pleomorphism of the neoplastic population was recorded if the cellular size and shape varied
144 among the neoplastic population.

145 c. Cytoplasm amount, distribution and colour: the cytoplasm was described as scarce—when
146 only a scant amount of cytoplasm was present—moderate, or abundant. The presence of
147 unipolar distribution was also recorded. The colour of the cytoplasm was identified as clear,
148 basophilic or deeply basophilic.

149 d. Nuclear shape and nuclear chromatin pattern: round, indented or convoluted and irregular
150 shape of the nucleus was recorded, and the chromatin was described as dense, granular or
151 finely granular, or smooth.

152 e. Presence of nucleoli: the presence of single or multiple prominent nucleoli was recorded.

153 Before the beginning of the study, the observers conferred to standardize the appearance of all
154 these morphological features.

155 Moreover the observers were asked to identify the malignancy grade (high or low grade).

156 Small-cell lymphomas were classified as low-grade lymphomas while large-cell and
157 pleomorphic mixed-small-large-cell lymphomas were classified as high-grade lymphomas.

158 All these morphological features were scored as shown in Table 1.

159 *Statistical methods*

160
161 In all the cases, the IOA between the DSs and GSs was assessed for each of the
162 morphological features and the grading. Moreover, the agreement between FC and DS and between
163 FC and GS in determining the malignancy grade was also evaluated for each observer to evaluate
164 the accuracy of the DS and GS, respectively, by using FC as a reference method, for determining of
165 the lymphoma grade. The IOA and the agreement in determining the malignancy grade were
166 assessed by using linearly weighted Cohen's K. The K coefficients were interpreted as
167 recommended by Landis and Koch (1977): <0.00, poor; 0.00-0.20, slight; 0.21-0.40, fair; 0.41-0.60,

Comment [FB97]: Line 143 of YTVJL-D17-00838R2 Deleted - :

Comment [FB98]: Line 145 of YTVJL-D17-00838R2 Deleted - ,

Comment [FB99]: Line 146 of YTVJL-D17-00838R2 Deleted - rime

Comment [FB100]: Line 146 of YTVJL-D17-00838R2 Deleted - , Moderate - ,

Comment [FB101]: Line 146 of YTVJL-D17-00838R2 Deleted - to

Comment [FB102]: Line 146 of YTVJL-D17-00838R2 Deleted - a

Comment [FB103]: Line 150 of YTVJL-D17-00838R2 Deleted - whereas

Comment [FB104]: Line 151 of YTVJL-D17-00838R2 Deleted - and

Comment [FB105]: Lines 153-154 of YTVJL-D17-00838R2 Deleted - based on the morphological criteria described in literature (Fournel-Fleury et al., 1997; Ponce et al., 2010),

Comment [FB106]: Line 154-155 of YTVJL-D17-00838R2 Deleted - the phenotype (B-cells or T-cells lymphoma), and

Comment [FB107]: Line 156 of

Comment [FB108]: Line 155 of

Comment [FB109]: Line 155 of

Comment [FB110]: Line 156 of

Comment [FB111]: Line 156 of

Comment [FB112]: Lines 157-164

Comment [FB113]: Line 169 of

Comment [FB114]: Line 169 of

Comment [FB115]: Line 170 of

Comment [FB116]: Line 170 of

Comment [FB117]: Line 170 of

Comment [FB118]: Line 171 of

Comment [FB119]: Line 172 of

Comment [FB120]: Line 172 of

Comment [FB121]: Line 173 of

168 moderate; 0.61-0.80, substantial; and >0.80, almost perfect. Differences in the number of corrected
169 classified lymphomas obtained by evaluating the DSs and GSs, compared to the results of FC, were
170 assessed using Fisher's exact test. Statistical analysis was performed using a commercially available
171 software program (MedCalc Statistical Software version 15.8, MedCalc Software bvba.).

Comment [FB122]: Line 176 of YTVJL-D17-00838R2 Deleted - (SPSS, version 12.0.0, SPSS Inc, Chicago, IL, USA).

173 Results

174 In total 250 samples arrived to the Flow Cytometry Service of the Department of Veterinary
175 Medicine, University of Milan from January to June 2015 and 163 of these (65%) also had
176 corresponding cytological slides. In 44 out of the 163 (27%) samples, the cytological smears had
177 good cellularity and preservation and were hence included in the present study. Based on the
178 phenotype and size of cells assessed using FC, 24 high-grade B-cell lymphomas, four low-grade B-
179 cell lymphomas, 10 high-grade T-cell lymphomas, and six low-grade T-cell lymphomas were
180 included in the study (Table 2).

Comment [FB123]: Line 179 of YTVJL-D17-00838R2 Deleted - the

Comment [FB124]: Line 179 of YTVJL-D17-00838R2 Deleted - by

182 The IOA results for the cytomorphological features are listed in Table 3. For the
183 inexperienced observer the agreement between the DSs and GSs was slight for the amount and
184 colour of cytoplasm, and fair for all the other morphological features. The mean IOA for
185 cytomorphological features was fair. For the mildly experienced observer, the agreement between
186 the DSs and GSs was slight for cellular size, chromatin pattern, nuclear shape, and cellular
187 pleomorphism; fair for the amount of cytoplasm; and moderate for cytoplasm colour and the
188 presence of nucleoli. The mean IOA for cytomorphological features was fair. For the experienced
189 observer the agreement between the DSs and GSs was fair for chromatin pattern, cytoplasm
190 amount, and nuclear shape; and moderate for cellular pleomorphism, cellular size, cytoplasm
191 colour, and the presence of nucleoli. The mean IOA for cytomorphological features was moderate.
192 For each cytomorphological feature, the mean IOA of the three observers was fair, except for

Comment [FB125]: Line 183 of YTVJL-D17-00838R2 Deleted - for the IOA

193 cytoplasm amount for which it was slight, and for cytoplasm colour and the presence of nucleoli for
194 which it was moderate.

195
196 Even if no statistical differences were present, the use of WSI brought about an
197 improvement in the percentage of high-grade lymphomas correctly identified by the mildly
198 experienced observer and in the percentage of low-grade lymphomas correctly identified by the
199 inexperienced observer. Nevertheless, it affected the percentage of high-grade lymphomas
200 identified by the inexperienced and experienced observers, and the percentage of low-grade
201 lymphomas identified by the mildly experienced observer (Table 2). The agreement between the FC
202 and DS results in the assessment of grading was slight for the inexperienced observer, fair for the
203 mildly experienced observer, and moderate for the experienced observer, while the agreement
204 between the FC and GS results in the assessment of grading was fair for the inexperienced observer,
205 substantial for the mildly experienced observer, and moderate for the experienced observer (Table
206 4).

208 Discussion

209 In this study, we assessed the reliability of the cytomorphological evaluation of canine
210 lymphoma samples by using a WSI scanner, and found a low IOA between the DSs and GSs for all
211 three observers for the morphological features assessed. The agreement between the DSs and FC
212 was slight for the inexperienced observer and fair to moderate for the two observers with more
213 experience. This underlines the importance of observer experience in the cytological evaluation of
214 lymphoma samples.

215
216 In recent years, researchers have shown increasing interest in both human and veterinary
217 digital pathology (Maiolino et al., 2006; Kelly, 2007; Al-Janabi et al., 2012; Webster and Dunstan,
218 2014; Bertram et al., 2018). The three-dimensional architecture of cells in FNA samples limited the

- Comment [FB126]: Lines 183-189 of YTVJL-D17-00838R2
- Comment [FB127]: Line 191 of
- Comment [FB128]: Line 191 of
- Comment [FB129]: Line 191 of
- Comment [FB130]: Line 191 of
- Comment [FB131]: Line 192 of
- Comment [FB132]: Line 192 of
- Comment [FB133]: Line 192 of
- Comment [FB134]: Line 193 of
- Comment [FB135]: Line 193 of
- Comment [FB136]: Line 193 of
- Comment [FB137]: Lines 193-194 of
- Comment [FB138]: Line 194 of
- Comment [FB139]: Line 194 of
- Comment [FB140]: Line 195 of
- Comment [FB141]: Line 195 of
- Comment [FB142]: Line 195 of
- Comment [FB143]: Line 195 of
- Comment [FB144]: Line 195 of
- Comment [FB145]: Line 196 of
- Comment [FB146]: Line 196 of
- Comment [FB147]: Line 196 of
- Comment [FB148]: Line 197 of
- Comment [FB149]: Line 197 of
- Comment [FB150]: Line 200 of
- Comment [FB151]: Line 201 of
- Comment [FB152]: Line 201 of
- Comment [FB153]: Lines 202-203 of
- Comment [FB154]: Line 203 of
- Comment [FB155]: Line 204 of
- Comment [FB156]: Line 204 of
- Comment [FB157]: Line 204 of
- Comment [FB158]: Line 204 of
- Comment [FB159]: Line 204 of
- Comment [FB160]: Lines 204-205 of
- Comment [FB161]: Line 205 of
- Comment [FB162]: Line 208 of
- Comment [FB163]: Line 208 of
- Comment [FB164]: Lines 208-209 of

219 application of digital pathology to cytological samples. However, with the introduction of WSI
 220 scanners with the z-stack function, FNA samples have become more suitable for digitalisation and
 221 visualisation on a monitor (El-Gabry et al., 2014). Nevertheless, no studies to date have validated
 222 the use of WSI scanners in veterinary cytology. In our study, we chose cytological samples of
 223 canine lymphoma to test our WSI scanner for many different reasons: first, lymphoma is the most
 224 common haematopoietic tumour in dogs (Richards and Suter, 2015); second, the first-step in
 225 diagnosis is often a FNA cytology of the lymph nodes; third, neoplastic lymphoid cells have
 226 peculiar morphological features that can be appreciated by cytological analysis (Fournel-Fleury et
 227 al., 2002; Ponce et al., 2003). To assess the concordance of information provided by the DSs and
 228 GSs we evaluated the intra-observer variability, which is the preferred measure of performance in
 229 digital pathology (Thrall et al., 2015). Moreover, to evaluate the diagnostic performance of our WSI
 230 scanner, we compared the results of FC analysis to the data provided by the DS and GS analyses for
 231 assessing the lymphoma grade on the basis of the fact that, nowadays, FC is considered a
 232 fundamental tool in lymphoma diagnosis (Comazzi and Gelain, 2011; Comazzi et al., 2016). The
 233 aim of this comparison was to evaluate whether the possible disagreement was due to the
 234 descriptive capacity of the DSs or whether the challenge in the morphological identification of
 235 grading was intrinsic to the cytological examination.

236

237 In the evaluation of morphological features, the overall IOA of the three observers was fair
 238 to moderate. These IOAs are lower than those reported in the validation studies of other WSI
 239 scanners used for histopathological analysis in veterinary pathology (Bertam et al., 2018) and for
 240 histopathological (Thrall et al., 2015), cytological (House et al., 2013), and haematological (Gomez-
 241 Gelvez et al., 2015) analyses in human pathology. The lower agreement obtained in our study is
 242 likely not only because of the shortcomings of the tested WSI scanner, but also because of the
 243 different design of our study compared to that of other studies in the literature. Indeed, the main
 244 goal of our study was to determine the descriptive capacity of the WSI scanner rather than its

Comment [FB165]: Line 211 of YTVJL-D17-00838R2 Deleted - the

Comment [FB166]: Line 212 of YTVJL-D17-00838R2 Deleted - also

Comment [FB167]: Line 212 of YTVJL-D17-00838R2 Deleted - are becoming

Comment [FB168]: Line 212 of YTVJL-D17-00838R2

Comment [FB169]: Line 212 of

Comment [FB170]: Line 213 of

Comment [FB171]: Line 213 of

Comment [FB172]: Line 214 of

Comment [FB173]: Line 214 of

Comment [FB174]: Line 216 of

Comment [FB175]: Line 218 of

Comment [FB176]: Line 220 of

Comment [FB177]: Line 221 of

Comment [FB178]: Line 223 of

Comment [FB179]: Line 223 of

Comment [FB180]: Line 223 of

Comment [FB181]: Line 224 of

Comment [FB182]: Line 224 of

Comment [FB183]: Line 225 of

Comment [FB184]: Line 226 of

Comment [FB185]: Line 227 of

Comment [FB186]: Line 227 of

Comment [FB187]: Line 229 of

Comment [FB188]: Line 230 of

Comment [FB189]: Line 230 of

Comment [FB190]: Line 231 of

Comment [FB191]: Line 231 of

Comment [FB192]: Line 231 of

Comment [FB193]: Line 232 of

Comment [FB194]: Line 233 of

Comment [FB195]: Line 233 of

Comment [FB196]: Line 233 of

Comment [FB197]: Line 233 of

Comment [FB198]: Line 234 of

Comment [FB199]: Line 234 of

Comment [FB200]: Line 235 of

245 'diagnostic performance'. The evaluation of morphological features of neoplastic lymphocytes
246 could also be difficult when using an optical microscope, and an unequivocal concordance on single
247 morphological features is challenging. However, our results clearly indicate that observer
248 experience is important in the cytological evaluation of lymphomas, as shown by the increasing
249 IOA from the inexperienced observer to the experienced one. Nevertheless, some technical
250 limitations of our WSI scanner contributed to the low level of agreement. In particular, the lowest
251 mean IOA was recorded in the evaluation of cytoplasm amount. The online software interface,
252 despite the z-stack scanning modality, does not have the capability to 'focus' up and down and does
253 not allow increasing the brightness of the DSs, thereby leading to a darker background than that
254 obtained for the GSs. The lack of these functions caused difficulties in the assessment of the edges
255 of the cells. Moreover, the cytoplasm was considered more frequently basophilic or deeply
256 basophilic in the DSs than in the GSs (Fig. 2). Conversely, the evaluation of the nucleoli was not
257 conditioned by the lack of these functions, and the presence of nucleoli was the microscopic detail
258 with the highest IOA. Thus, these limitations did not completely hamper our ability to evaluate
259 nuclear morphology.

261 The mitotic count (MC) is defined as the number of mitoses in 10 consecutive high-power
262 fields (Meuten et al., 2016), and it is a useful parameter to define the malignancy grade of
263 lymphomas (Ponce et al., 2010). MC in cytology is somewhat controversial because of the uneven
264 distribution of cells throughout a sample, but it is considered a more reproducible and reliable tool
265 in histopathological examinations (Sapierzyński et al., 2016). Moreover, in our study, even if the
266 magnification used to analyse the DSs and GSs was the same, the area occupied by the cells in the
267 DSs viewed on the monitor was smaller than that of cells in the GSs, because a portion of the
268 monitor is occupied by the online software interface with navigation icons and commands.
269 Therefore, the number of cells/40× field of a DS was lower than that of cells/40× field of a GS, and
270 thus, the different number of cells/40× field did not allow for a comparison of the MC between the

Comment [FB201]: Line 237 of YTVJL-D17-00838R2 Deleted - the

Comment [FB202]: Line 238 of YTVJL-D17-00838R2 Deleted - it is quite clear from

Comment [FB203]: Line 238 of YTVJL-D17-00838R2 Deleted - the

Comment [FB204]: Line 238 of YTVJL-D17-00838R2 Deleted - of the operator

Comment [FB205]: Line 239 of YTVJL-D17-00838R2 Deleted - based on

Comment [FB206]: Line 239 of YTVJL-D17-00838R2 Deleted - one

Comment [FB207]: Line 240 of

Comment [FB208]: Line 240 of

Comment [FB209]: Lines 241-242

Comment [FB210]: Line 242 of

Comment [FB211]: Line 243 of

Comment [FB212]: Line 243 of

Comment [FB213]: Line 243 of

Comment [FB214]: Line 243 of

Comment [FB215]: Line 244 of

Comment [FB216]: Lines 244-245

Comment [FB217]: Lines 245-246

Comment [FB218]: Line 247 of

Comment [FB219]: Line 247 of

Comment [FB220]: Line 248 of

Comment [FB221]: Line 249 of

Comment [FB222]: Line 249 of

Comment [FB223]: Line 252 of

Comment [FB224]: Line 254 of

Comment [FB225]: Line 255 of

Comment [FB226]: Line 255 of

Comment [FB227]: Line 255 of

Comment [FB228]: Line 256 of

Comment [FB229]: Line 258 of

Comment [FB230]: Line 258 of

Comment [FB231]: Line 259 of

Comment [FB232]: Line 260 of

Comment [FB233]: Line 261 of

271 DSs and GSs. An alternative approach to comparing mitosis between the two methods is to consider
272 the mitotic index (MI), which is the ratio of the number of cells in mitosis and the number of cells
273 not in mitosis (Meuten et al., 2016). Nevertheless, this approach is time-consuming because it is
274 necessary to also count the cells not in mitosis, usually 1,000, and it is not applicable in the routine
275 diagnostic practice. For all these reasons, the MI was not included as a malignancy feature in our
276 study.

Comment [FB234]: Line 262 of YTVJL-D17-00838R2 Deleted – compare the

Comment [FB235]: Line 263 of YTVJL-D17-00838R2 Deleted - between

Comment [FB236]: Line 265 of YTVJL-D17-00838R2 Deleted - also

Comment [FB237]: Line 266 of YTVJL-D17-00838R2 Deleted – mitotic index

277
278 In addition to the possibilities to diagnose a lymphoma, the cytological examination of
279 lymph node FNAs could be useful to predict the grading of the neoplastic process. Large cells
280 and/or cellular pleomorphism could be suggestive of high grade lymphomas (e.g centroblastic B-
281 cell lymphoma or pleomorphic large T-cell lymphoma), while small cells are more frequently
282 observed in low grade lymphomas (e.g. small lymphocytic B-cell lymphoma or small clear T-cell
283 lymphoma) (Fournel-Fleury et al., 2002; Ponce et al., 2010). Despite the technical limitations of our
284 WSI scanner that led to difficulties in the evaluation of some morphological features, the IOA in the
285 determinations of grading was moderate for all the observers. These results may suggest that,
286 despite some difficulties in the evaluation of some specific characteristics, it is possible to obtain
287 acceptable results by using digital smears even with non-optimal images.

Comment [FB238]: Line 269 of YTVJL-D17-00838R2 Deleted - Besides

Comment [FB239]: Line 270 of YTVJL-D17-00838R2 Deleted - also

Comment [FB240]: Line 270 of YTVJL-D17-00838R2 Deleted - : l

Comment [FB241]: Line 272 of YTVJL-D17-00838R2 Deleted - ,

Comment [FB242]: Line 273 of YTVJL-D17-00838R2 Deleted - ,

Comment [FB243]: Lines 274-278 of YTVJL-D17-00838R2 Deleted - On contrary, the precise determination of the immunophenotype in canine lymphomas, essential for the prognosis, requires objective techniques, like immunohistochemistry or flow cytometry, to demonstrate lineage-specific cell antigens (Ponce et al., 2010, Comazzi and Gelain, 2011). However, an attempt at determination of phenotype could be made based on morphological

Comment [FB244]: Line 278 of YTVJL-D17-00838R2 Deleted - T

Comment [FB245]: Line 279 of YTVJL-D17-00838R2

Comment [FB246]: Lines 280-281 of YTVJL-D17-00838R2

Comment [FB247]: Line 282 of YTVJL-D17-00838R2 Deleted - besides

Comment [FB248]: Line 283 of YTVJL-D17-00838R2

289 The first aim of FC exam is the objective determination of the lymphoma's phenotype.
290 However, the information derived from FC go far beyond the simply identification of cell origin: it
291 allows the assessment of the percentage of neoplastic cells within FNA sample, their size, based on
292 the mean FSC, and the pleomorphism, based on the standard deviation of the FSC (Gelain et al.,
293 2008). Moreover, it is possible to evaluate the phenotype aberrations (both qualitative and
294 quantitative) which, in combination with morphological features (e.g size) allows to recognized
295 some specific lymphoma subtypes (e.g small clear cell lymphoma). In our study, the lymphoma's
296 grade determined by flow cytometry was compared to the lymphoma's grade obtained with DS and

297 GS by the three observers. Regarding lymphoma grade, the results of the agreement with FC have
298 shown a correlation with observer experience. In fact, agreement was slight and fair for the DSs and
299 GSs, respectively, for the inexperienced observer, thus reflecting the observer's difficulty in
300 determining the lymphoma grade based only on the morphological features of the cells. In contrast,
301 the mildly experienced observer had good agreement when using the optical microscope and a
302 slightly decreased accuracy when using the WSI scanner, and the experienced observer had
303 moderate agreement when using both the DSs and GSs. These data confirm the importance of
304 observer experience in the evaluation of lymphoma samples and reflect the lower descriptive
305 capacity of the DSs than the GSs.

306
307 From a technical perspective, the scanning time for each DS was between three and four
308 hours, depending on the amount of material on the GS. The time interval is related to the z-stack
309 scanning mode with 40× magnification. The use of WSI scanners with such long scanning times
310 negatively affects their application in routine cytological diagnosis, wherein a single case often has
311 multiple GSs. However, when challenging cases require the opinion of skilled clinical-pathologists
312 at distant sites, this technology can be an efficient tool. To simulate a routine workflow in the use of
313 the WSI scanner, for each case, we chose the slide with higher cellularity and better preservation,
314 because high cellularity and good preservation are characteristics that a regular practitioner can also
315 recognize.

316 The limitation of the long scanning time could be solved using a more advanced WSI
317 scanner with a higher speed of acquisition. The size of the DS (from 1 to 2 gigabytes) could also be
318 a limitation and the use of a dedicated server is mandatory to facilitate the storage and sharing of the
319 files (Gomez-Gelvez et al., 2015).

320 321 Conclusions

Comment [FB249]: Line 286 of YTVJL-D17-00838R2 Deleted – In addition t

Comment [FB250]: Line 286 of YTVJL-D17-00838R2 Deleted - diagnostic

Comment [FB251]: Line 287 of YTVJL-D17-00838R2 Deleted - the

Comment [FB252]: Line 287 of YTVJL-D17-00838R2 Deleted – of the observer

Comment [FB253]: Line 287 of YTVJL-D17-00838R2 Deleted - it

Comment [FB254]: Line 287 of YTVJL-D17-00838R2 Deleted - both

Comment [FB255]: Line 287 of YTVJL-D17-00838R2 Deleted - one

Comment [FB256]: Line 288 of YTVJL-D17-00838R2 Deleted – the determination of

Comment [FB257]: Line 288 of YTVJL-D17-00838R2 Deleted – ing and phenotype of lymphoma

Comment [FB258]: Line 289 of YTVJL-D17-00838R2 Deleted – for unskilled observers

Comment [FB259]: Line 289 of

Comment [FB260]: Line 289 of

Comment [FB261]: Line 290 of

Comment [FB262]: Line 291 of

Comment [FB263]: Line 292 of

Comment [FB264]: Line 292 of

Comment [FB265]: Line 294 of

Comment [FB266]: Line 297 of

Comment [FB267]: Line 297 of

Comment [FB268]: Line 297 of

Comment [FB269]: Line 297 of

Comment [FB270]: Line 298 of

Comment [FB271]: Line 298 of

Comment [FB272]: Line 299 of

Comment [FB273]: Line 299 of

Comment [FB274]: Line 300 of

Comment [FB275]: Line 302 of

322 The data from our study underline some technical limitations of the tested WSI scanner,
323 mainly linked to image quality, which could limit the diagnostic power of the instrument. We have
324 also demonstrated the importance of observer experience in the correct interpretation of DSs.
325 However, given the technological advances and development of new functions, the digital
326 cytological workflow in veterinary medicine could also be improved.

328 **Conflict of interest statement:** None of the authors of this paper have a financial or personal
329 relationship with other people or organisations that could inappropriately influence or bias the
330 content of the paper.

332 Acknowledgements

333 The WSI scanner (D-sight, A. Menarini Diagnostics S.r.l.) was acquired thanks to the scientific
334 instrumentation grant (2012) by the University of Padua.

335 The authors gratefully acknowledge the assistance of Dr. Alessandra Faggionato and of Dr.
336 Francesco Cian in English editing.

337 The preliminary results of this study were presented as an Abstract at the 18th Congress of the
338 European Society of Veterinary Clinical Pathology, Nantes, 20-22 October 2016.

340 References

341 Al-Janabi, S., Huisman, A., Van Diest, P.J., 2012. Digital pathology: current status and future
342 perspectives. *Histopathology* 61, 1–9.

343 Amores-Fuster, I., Cripps, P., Graham, P., Marrington, A.M., Blackwood, L., 2015. The diagnostic
344 utility of lymph node cytology samples in dogs and cats. *Journal of Small Animal Practice*
345 56, 125–129.
346
347

Comment [FB276]: Line 306 of YTVJL-D17-00838R2 Deleted - tested

Comment [FB277]: Line 307 of YTVJL-D17-00838R2 Deleted - the

Comment [FB278]: Line 307 of YTVJL-D17-00838R2 Deleted – of the images

Comment [FB279]: Line 307 of YTVJL-D17-00838R2 Deleted - this

Comment [FB280]: Line 308 of YTVJL-D17-00838R2 Deleted – 's

Comment [FB281]: Line 308 of YTVJL-D17-00838R2 Deleted - for

Comment [FB282]: Line 309 of YTVJL-D17-00838R2 Deleted – digital slides

Comment [FB283]: Line 309 of YTVJL-D17-00838R2 Deleted - with

Comment [FB284]: Line 309 of YTVJL-D17-00838R2 Deleted – of technology

Comment [FB285]: Line 309 of YTVJL-D17-00838R2 Deleted – the release

Comment [FB286]: Line 310 of YTVJL-D17-00838R2 Deleted – also in veterinary medicine

Comment [FB287]: Line 312 of YTVJL-D17-00838R2 Deleted – Declaration of interest

348 Bertram, C.A., Gurtner, C., Dettwiler, M., Kershaw, O., Dietert, K., Pieper, L., Pischon, H., Gruber,
349 A.D., Klopfleish, R., 2018. Validation of digital microscopy compared with light
350 microscopy for the diagnosis of canine cutaneous tumors. *Veterinary Pathology*
351 [10.1177/0300985818755254](https://doi.org/10.1177/0300985818755254).
352

353 Burkhard, M.J. and Bienzle, D., 2013. Making sense of lymphoma diagnostics in small animal
354 patients. *Veterinary Clinics of North America: Small Animal Practice* 43, 1331–1347.
355

356 Comazzi, S. and Gelain, M.E., 2011. Use of flow cytometric immunophenotyping to refine the
357 cytological diagnosis of canine lymphoma. *The Veterinary Journal* 188, 149–155.
358

359 Comazzi, S., Avery, P.R., Garden, O.A., Riondato, F., Rütgen, B., Vernau, W., 2016. European
360 canine lymphoma network consensus recommendations for reporting flow cytometry in
361 canine hematopoietic neoplasms. *Cytometry Part B: Clinical Cytometry* 92, 411-419.
362

363 El-Gabry, E.A., Parwani, A.V., Pantanowitz, L., 2014. Whole-slide imaging: widening the scope of
364 cytopathology. *Diagnostic Histopathology* 20, 456–461.
365

366 Fournel-Fleury, C., Magnol, J.P., Bricaire, P., Marchal, T., Chabanne, L., Delverdier, A., Bryon,
367 P.A., Felman, P., 1997. Cytohistological and immunological classification of canine
368 malignant lymphomas: comparison with human non-Hodgkin's lymphomas. *Journal of*
369 *Comparative Pathology* 117, 35–59.
370

371 Fournel-Fleury, C., Ponce, F., Felman, P., Blavier, A., Bonnefont, C., Chabanne, L., Marchal, T.,
372 Cadore, J.L., Goy-Thollot, I., Ledieu, D., et al., 2002. Canine T-cell lymphomas: a
373 morphological, immunological, and clinical study of 46 new cases. *Veterinary Pathology* 39,
374 92–109.
375

376 Gelain, M.E., Mazzilli, M., Riondato, F., Marconato, L., Comazzi, S., 2008. Aberrant phenotypes
377 and quantitative antigen expression in different subtypes of canine lymphoma by flow
378 cytometry. *Veterinary Immunology and Immunopathology* 121, 179-188.
379

380 Gomez-Gelvez, J.C., Kryvenko, O.N., Chabot-Richards, D.S., Foucar, K., Inamdar, K.V., Karner,
381 K.H., 2015. Comparative analysis reveals potential utility of digital microscopy in the
382 evaluation of peripheral blood smears with some barriers to implementation. *American*
383 *Journal of Clinical Pathology* 144, 68–77.
384

385 House, J.C., Henderson-Jackson, E.B., Johnson, J.O., Lloyd, M.C., Dhillon, J., Ahmad, N., Hakam,
386 A., Khalbuss, W.E., Leon, M.E., Chhieng, D., et al., 2013. Diagnostic digital cytopathology:
387 are we ready yet? *Journal of Pathology Informatics* 4, 28.
388

389 Kelly, D.F., 2007. Veterinary pathology in the United Kingdom: past, present, and future. *Journal*
390 *of Veterinary Medical Education* 34, 383–389.
391

392 Landis, J.R. and Koch, G.G., 1977. The measurement of observer agreement for categorical data.
393 *Biometrics* 33, 159–174.
394

395 Maiolino, P., Restucci, B., Papparella, S., De Vico, G., 2006. Evaluation of static telepathology in
396 veterinary diagnostic cytology. *Veterinary Clinical Pathology* 35, 303–306.
397

- 398 Meuten, D.J., Moore, F.M., George, J.M., 2016. Mitotic count and the field of view area: time to
399 standardize. *Veterinary Pathology* 53, 7-9.
400
- 401 Pantanowitz, L., Sinard, J.H., Henricks, W.H., Fatheree, L.A., Carter, A.B., Contis, L., Beckwith,
402 B., Evans, A.J., Lal, A., Parwani, A.V., 2013. Validating whole slide imaging for diagnostic
403 purposes in pathology: guideline from the College of American Pathologists Pathology and
404 Laboratory Quality Center. *Archives of Pathology & Laboratory Medicine* 137, 1710–1722.
405
- 406 Ponce, F., Magnol, J.P., Marchal, T., Chabanne, L., Ledieu, D., Bonnefont, C., Felman, P., Fournel-
407 Fleury, C., 2003. High-grade canine T-cell lymphoma/leukemia with plasmacytoid
408 morphology: a clinical pathological study of nine cases. *Journal of Veterinary Diagnostic*
409 *Investigation* 15, 330–337.
410
- 411 Ponce, F., Magnol, J.P., Ledieu, D., Marchal, T., Turinelli, V., Chalvet-Monfray, K., Fournel-
412 Fleury, C., 2004. Prognostic significance of morphological subtypes in canine malignant
413 lymphomas during chemotherapy. *The Veterinary Journal* 167, 158–166.
414
- 415 Ponce, F., Marchal, T., Magnol, J.P., Turinelli, V., Ledieu, D., Bonnefont, C., Pastor, M.,
416 Delignette, M.L., Fournel-Fleury, C., 2010. A morphological study of 608 cases of canine
417 malignant lymphoma in France with a focus on comparative similarities between canine and
418 human lymphoma morphology. *Veterinary Pathology* 47, 414–433.
419
- 420 Richards, K.L. and Suter, S.E., 2015. Man’s best friend: what can pet dogs teach us about non-
421 Hodgkin’s lymphoma? *Immunological Reviews* 263, 173–191.
422
- 423 Sapierzyński, R., Kliczkowska-Klarowicz, K., Jankowska, U., Jagielski, D., 2016. Cytodiagnostics
424 of canine lymphomas-possibilities and limitations. *Polish Journal of Veterinary Science* 19,
425 433-439.
426
- 427 Steinberg, D.M. and Ali, S.Z., 2001. Application of virtual microscopy in clinical cytopathology.
428 *Diagnostic Cytopathology* 25, 389–396.
429
- 430 Thrall, M.J., Wimmer, J.L., Schwartz, M.R., 2015. Validation of multiple whole slide imaging
431 scanners based on the guideline from the college of american pathologists pathology and
432 laboratory quality center. *Archives of Pathology & Laboratory Medicine* 139, 656–664.
433
- 434 Webster, J.D. and Dunstan, R.W., 2014. Whole-slide imaging and automated image analysis:
435 considerations and opportunities in the practice of pathology. *Veterinary Pathology* 51, 211–
436 223.
437
- 438 Weinstein, R.S., 1986. Prospects for telepathology. *Human Pathology* 17, 433–434.
439
- 440 Wilbur, D.C., Madi, K., Colvin, R.B., Duncan, L.M., William, C., Ferry, J.A., Frosch, M.P.,
441 Houser, S.L., Kradin, R.L., Lauwers, G.Y., Louis, D.N., et al., 2009. Whole-slide imaging
442 digital pathology as a platform for teleconsultation: a pilot study using paired subspecialist
443 correlations. *Archives of Pathology & Laboratory Medicine* 133, 1949–1953.
444
- 445 Wilbur, D.C., 2011. Digital cytology: current state of the art and prospects for the future. *Acta*
446 *Cytologica* 55, 227–238.
447

Comment [FB288]: Lines 406-407 of
YTVJL-D17-00838R2
Deleted - Sayag, D., Fournel-Fleury,
C., Ponce, F., 2017. Prognostic
significance of morphotypes in
canine lymphomas: a systematic
review of literature. *Veterinary and*
Comparative Oncology 0:1-8.

448 **Table 1**

449 Morphological features and grading system used in the cytological evaluation.

Comment [FB289]: Line 431 of YTVJL-D17-00838R2 Deleted - cellular

Morphological features	1	2	3	4
Cellular size	Small	Medium	Large	
Cellular pleomorphism	Present	Absent		
Cytoplasm amount	Scarce	Moderate	Abundant	Unipolar
Cytoplasm colour	Clear	Basophilic	Deeply basophilic	
Nuclear shape	Round	Indented	Convolutd	Irregular
Chromatin pattern	Dense/Thickened	Granular/Coarse	Finely granular	Smooth
Nucleoli	Not present	Single	Multiple	

450

451 **Table 2**

452 Classification of the 44 lymphoma samples based on the flow cytometry results and the results of evaluation of the
453 digital and glass slides by the three observers.

	High grade lymphomas	Low grade lymphomas
Flow cytometry	34 (24 B-cells; 10 T-cells)	10 (4 B-cells; 6 T-cells)
Observer 1 - digital slides	23	9
Observer 2 - digital slides	30	5
Observer 3 – digital slides	27	7
Observer 1 – glass slides	26	8
Observer 2 – glass slides	28	8
Observer 3 – glass slides	30	7

454

455

Comment [FB290]: Line 435 of YTVJL-D17-00838R2 Deleted – using digital and glass slides

Comment [FB291]: Table 2 of YTVJL-D17-00838R2 Deleted - High grade B-cell lymphomas . Low grade B-cell lymphomas . High grade T-cell lymphomas . Low grade T-cell lymphomas
Flow cytometry 24 . 4 10 . 6
Observer 1 - digital slides 12 . 4 2 . 4
Observer 2 - digital slides 18 . 1 7 . 3
Observer 3 – digital slides 21 . 1 2 . 5
Observer 1 – glass slides 16 . 2 1 . 4
Observer 2 – glass slides 18 . 1 8 . 6
Observer 3 – glass slides 23 . 1 7 . 6

456 **Table 3**

457 Intra-observer agreement for morphological features, grading, and phenotype. Observer **one** corresponded to the lower
 458 level of cytological experience; observer **two** corresponded to the **intermediate** level of cytological experience; observer
 459 **three** corresponded to the higher level of cytological expertise. The intra-observer agreement was assessed by using
 460 linearly weighted Cohen's K. The K coefficients were interpreted as recommended by Landis and Koch (1977).

Morphological features	Coefficient K observer 1 (95% CI)	Coefficient K observer 2 (95% CI)	Coefficient K observer 3 (95% CI)	Mean coefficient K (95% CI)
Cellular size	0.29 (0.07-0.50)	0.00 (-0.26-0.21)	0.44 (0.14-0.72)	0.30 (0.16-0.44)
Cellular pleomorphism	0.24 (-0.04-0.52)	0.17 (-0.10-0.43)	0.41 (0.14-0.68)	0.29 (0.13-0.45)
Cytoplasm amount	0.03 (-0.16-0.21)	0.26 (0.04-0.47)	0.28 (0.04-0.51)	0.17 (0.04-0.31)
Cytoplasm colour	0.13 (-0.10-0.36)	0.55 (0.35-0.75)	0.43 (0.21-0.64)	0.43 (0.30-0.56)
Nuclear shape	0.28 (0.08-0.48)	0.14 (-0.23-0.52)	0.33 (-0.03-0.69)	0.31 (0.16-0.47)
Chromatin pattern	0.32 (0.10-0.55)	0.03 (-0.13-0.19)	0.22 (0.03-0.40)	0.22 (0.11-0.34)
Nucleoli	0.33 (0.11-0.55)	0.52 (0.21-0.72)	0.50 (0.25-0.75)	0.48 (0.36-0.60)
Mean cytomorphological features	0.34 (0.26-0.42)	0.40 (0.32-0.48)	0.52 (0.44-0.60)	
Malignancy grade	0.53 (0.29-0.78)	0.44 (0.10-0.78)	0.46 (0.18-0.74)	0.51 (0.34-0.70)

461

Comment [FB292]: Line 442 of YTVJL-D17-00838R2 Deleted – follows as

Comment [FB293]: Table 3 of YTVJL-D17-00838R2 Deleted - 3

Comment [FB294]: Table 3 of YTVJL-D17-00838R2 Deleted - 24

Comment [FB295]: Table 3 of YTVJL-D17-00838R2 Deleted - 7

Comment [FB296]: Table 3 of YTVJL-D17-00838R2 Deleted - 9

Comment [FB297]: Table 3 of YTVJL-D17-00838R2 Deleted - 37

Comment [FB298]: Table 3 of YTVJL-D17-00838R2 Deleted - 25

Comment [FB299]: Table 3 of YTVJL-D17-00838R2 Deleted – 19

Comment [FB300]: Table 3 of YTVJL-D17-00838R2 Deleted - 5

Comment [FB301]: Table 3 of YTVJL-D17-00838R2 Deleted - 24

Comment [FB302]: Table 3 of YTVJL-D17-00838R2 Deleted - 28

Comment [FB303]: Table 3 of YTVJL-D17-00838R2 Deleted - 37

Comment [FB304]: Table 3 of YTVJL-D17-00838R2 Deleted – Phenotype 0.08 0.63 0.34 0.35 Mean 0.31 0.54 0.40

Comment [FB305]: Table 3 of YTVJL-D17-00838R2 Deleted - 48

462 **Table 4**

463 Agreement between flow-cytometry results and the digital and glass slide assessments of lymphoma grading. Observer
 464 one corresponded to the lower level of cytological experience; observer two corresponded to the intermediate level of
 465 cytological experience; observer three corresponded to the higher level of cytological expertise. The diagnostic
 466 agreement was assessed by using linearly weighted Cohen's K. The K coefficients were interpreted as recommended by
 467 Landis and Koch (1977).

	Coefficient K observer 1 (95% CI)	Coefficient K observer 2 (95% CI)	Coefficient K observer 3 (95% CI)
Flow cytometry results vs digital slide assessments	0.16 (-0.13-0.50)	0.32 (0.06-0.58)	0.50 (0.23-0.77)
Flow cytometry results vs optical slide assessments	0.37 (0.12-0.62)	0.63 (0.39-0.87)	0.50 (0.24-0.75)

468

Comment [FB306]: Line 446 of YTVJL-D17-00838R2 Deleted - optical

Comment [FB307]: Line 446 of YTVJL-D17-00838R2 Deleted - s in the

Comment [FB308]: Line 446 of YTVJL-D17-00838R2 Deleted - and phenotype

Comment [FB309]: Line 449 of YTVJL-D17-00838R2 Deleted - as follows

Comment [FB310]: Table 4 of YTVJL-D17-00838R2 Deleted - 0.33 0.63 0.47 0.24 0.77 0.73

469 **Figure legends**

470

471 Fig. 1. **Whole-slide imaging** microscope imaging workstation (**D-sight**, A. Menarini Diagnostics
472 S.r.l.). 1a. The system consists of a **five-slide** capacity scanner with **four objectives** (4×, 10×, 20×,
473 and 40×) and a high-performance **desktop** computer. 1b. **The main page of the online software** used
474 **for analysis** (**Telepathology**, Visia Imaging S.r.l). The system allows to digitise, store, and preview
475 all digitalised slides. Thus, the user can **scroll** through the archive and select the slide of interest. 1c.
476 **The online software's** navigation page: using the image multi-preview, the user can select and edit
477 any area of interest (black asterisk). Information regarding the different magnifications available
478 (white asterisk), the current magnification (yellow asterisk), and the navigation map of the area
479 selected (red asterisk) are also present.

480

481 Fig. 2. **Small-clear-cell** lymphoma: 2a. Digital slide and 2b. Glass slide of the same sample (40×
482 magnification). **Compared to the glass slide**, the digital slide, **clearly shows** the darker background
483 and, consequently, the more basophilic cytoplasm of the **cells**.

Comment [FB311]: Line 455 of YTVJL-D17-00838R2 Deleted - 5

Comment [FB312]: Line 455 of YTVJL-D17-00838R2 Deleted - s

Comment [FB313]: Line 455 of YTVJL-D17-00838R2 Deleted - 4

Comment [FB314]: Line 456 of YTVJL-D17-00838R2 Deleted - desktop

Comment [FB315]: Line 456 of YTVJL-D17-00838R2 Deleted - M

Comment [FB316]: Line 456 of YTVJL-D17-00838R2 Deleted - server

Comment [FB317]: Line 457 of YTVJL-D17-00838R2 Deleted - z

Comment [FB318]: Line 457 of YTVJL-D17-00838R2 Deleted - to

Comment [FB319]: Line 457 of YTVJL-D17-00838R2 Deleted - z

Comment [FB320]: Line 458 of YTVJL-D17-00838R2 Deleted - move

Comment [FB321]: Line 458 of YTVJL-D17-00838R2 Deleted – Server's

Comment [FB322]: Line 464 of YTVJL-D17-00838R2 Deleted – Server's Deleted - s

Comment [FB323]: Line 464 of YTVJL-D17-00838R2 Deleted – Server's Deleted - s

Comment [FB324]: Line 465 of YTVJL-D17-00838R2 Deleted – Server's Deleted - In

Comment [FB325]: Line 466 of YTVJL-D17-00838R2 Deleted – Server's Deleted – compared to the glass slide is evident

Figure1_R1
[Click here to download high resolution image](#)

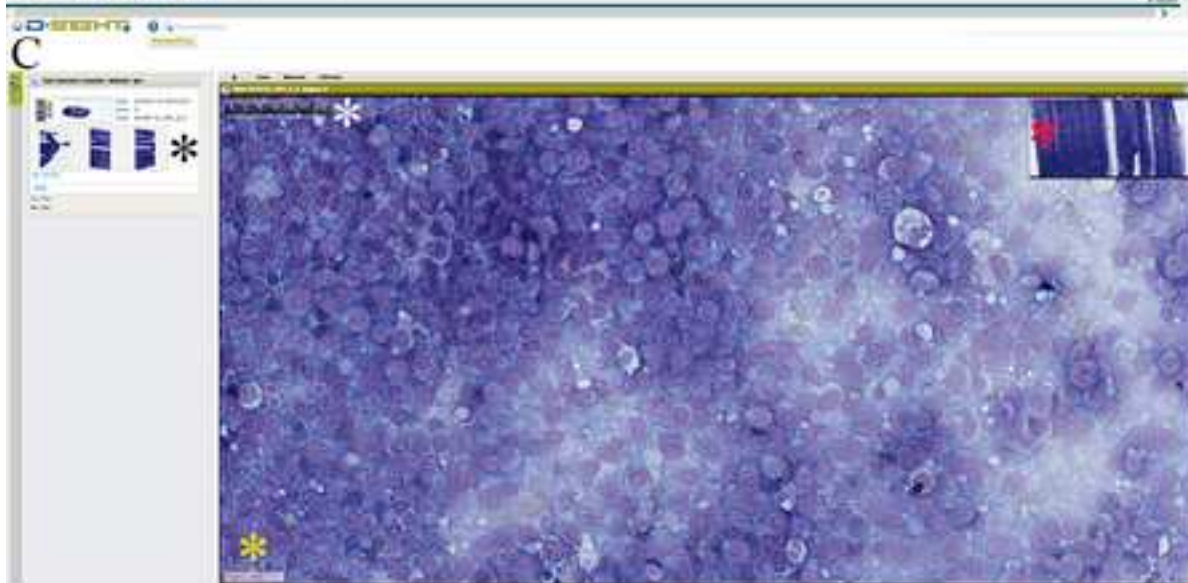
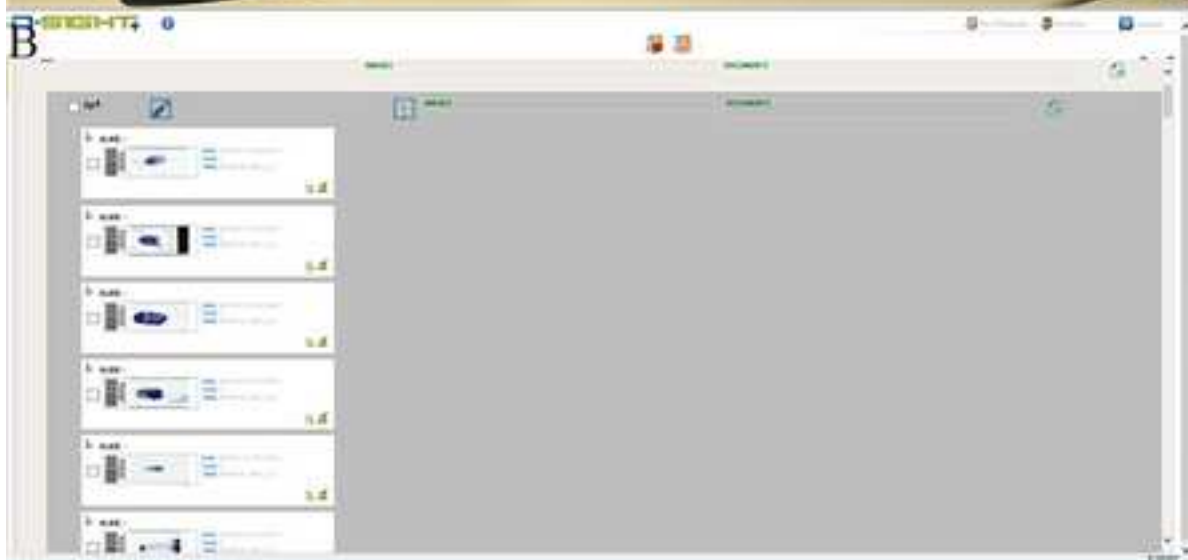
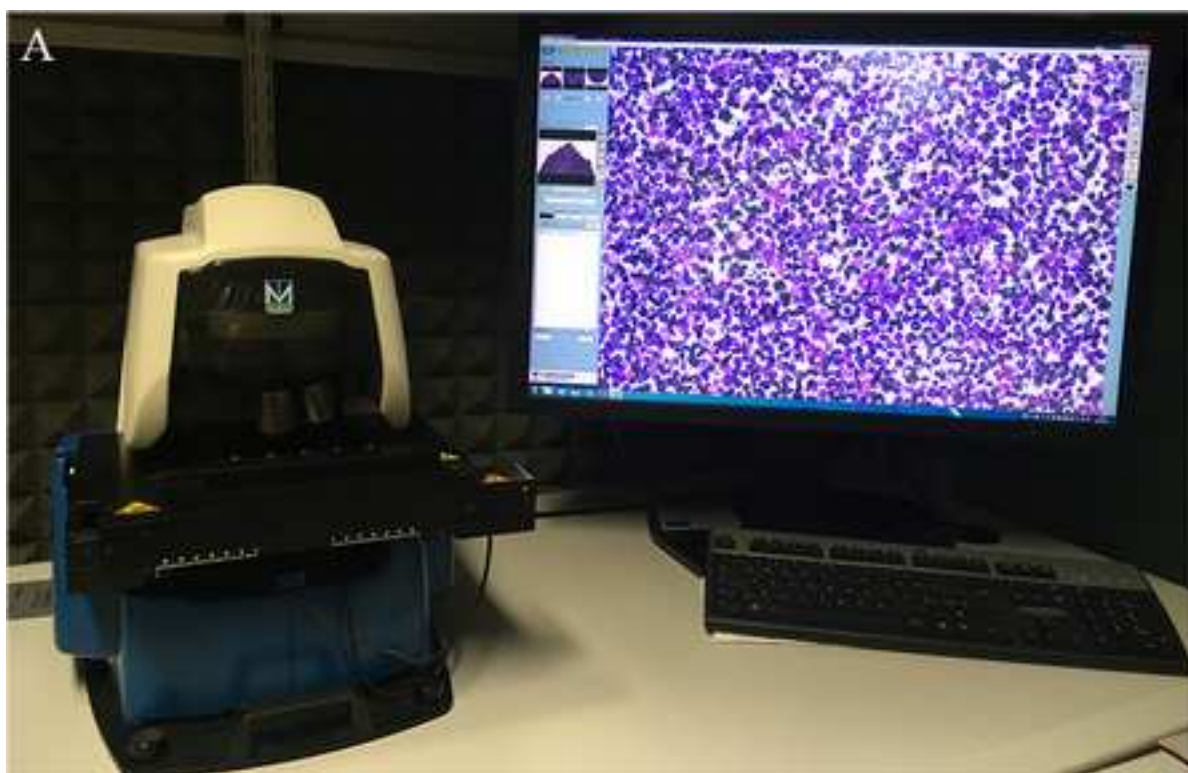
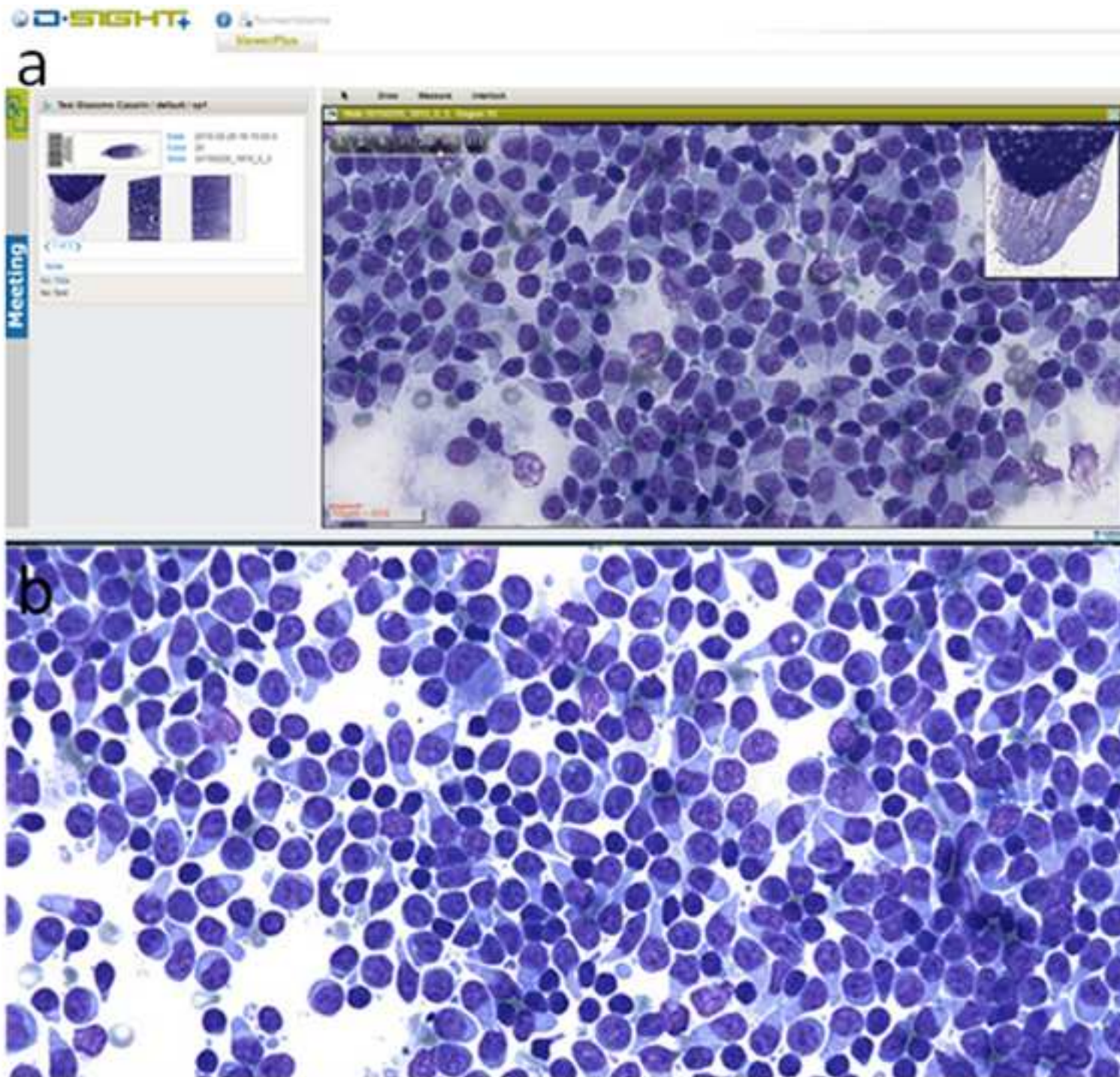


Figure2_R1

[Click here to download high resolution image](#)



English_editing_certificare_R2

[Click here to download Optional e-only supplementary files: Bonsembiante et al._English_editing_certificate_R2.pdf](#)

Highlights

- Whole slide imaging scanner is a robotic microscope capable to digitize a glass slide to create a composite digital image
- The cytomorphological capability of a whole slide imaging scanner is evaluated on 44 lymphoma samples
- There are some technical limitations that affected the diagnostic power of the instrument
- The release of new functions will be important to overcome the technical limitations
- This is the first time in which a whole slide imaging scanner is evaluated in Veterinary Medicine

Revision Note

Manuscript Number: YTVJL-D-17-00838R2

Article Title: Whole-slide imaging: cytomorphological descriptive capacity and intra-observer agreement in canine lymphoma samples

REVIEWERS' COMMENTS:

Reviewer #1:

Reviewer comment - Thanks for addressing most of the comments and concerns that were raised in the review process. I did note that the descriptive breakdown of agreement for morphological criteria were removed from the results in this version. I understand that the kappa values are listed in the tables, but I appreciated the information in the text of the previous version as well.

Author response – We added the requested information in the main manuscript (lines 182-194).

Reviewer comment - Regarding the impact of slide quality on whole slide imaging, I maintain that it would be valuable to have at least 1 sentence stating the percentage of samples that satisfactorily passed the QC process. According to the numbers provided in the rebuttal, only 27% of samples passed were of high enough quality for scanning. This is an important consideration for those that are interested in this technology.

Author response – We added this information in the main manuscript (lines 174-177).

Minor comments:

Reviewer comment - Page 10, Line 242: I'm sorry I didn't pick up on this with the first review, but is "server" the correct word here? Is the focusing an issue with the server or the interface?

Author response – We changed 'server' with 'online software interface' (line 251).

Reviewer comment - Page 12, Line 281: Wasn't the observer 2's IOA for phenotype substantial, not moderate?

Author response – We deleted all the information regarding the phenotype from the text, according to Reviewer 2 and Editor's comments.

Reviewer #2:

The authors have addressed many of my concerns and the paper is much improved. A few minor issues should still be addressed, in addition to some general editing for language to improve understanding.

Reviewer comment - Lines 73-75: Not all those tests are required to confirm lymphoma, therefore I would not say they are all fundamental. Consider rephrasing to "are fundamental tools that can be used to confirm and type lymphoma, etc." or something like that.

Author response – We added 'tool that can be used' in the main text (line 73).

Reviewer comment - Most instances of the word "telepathology" should be changed to "digital pathology" as no one was remotely controlling a microscope.

Author response – We changed 'telepathology' with 'digital pathology' in the main text (lines 43, 62, 217, 219, 229).

Reviewer comment - I remain in opposition to presumptively phenotyping lymphoma based on cytological morphology alone. I am concerned that this would give the impression that cytologic morphology is sufficient to type lymphoma when it is not. The publications used to justify classifying

immunophenotype based on cytological criteria did not actually use cytology as the gold standard for tumor classification. Ponce et al 2010 only examined cytology on 93/608 cases and did not use the cytology to classify the tumor types; the "cytological criteria" in their tables are the criteria used for examining histopathology slides not cytology slides. Similarly with Ponce 2004, the immunophenotype was determined by immunohistochemistry and immunocytochemistry, i.e. not based on cytological morphology. If this is kept, I would prefer to see a stronger emphasis in the discussion (and abstract) that cytological classification of lymphoma type is presumptive/preliminary and definitive methods (e.g. flow, IHC) are REQUIRED for true classification.

Author response – We agree with the reviewer about the needs to use immunological method to confirm the phenotype of lymphomas and we underlined it both in the text and in the revision note in the previous revision. We define the morphological evaluation only "an attempt" to determine the phenotype based on what is reported in literature (see Fournel-Fleury et al., 2002), being absolutely aware of the difficulty to correctly correlate morphological features and immunophenotype in these neoplasms. However, according to the revisions of the Reviewer 2 and of the Editor, we deleted the part regarding the determination of the phenotype using cytology from the main text.

Reviewer comment - In my opinion, comparing morphological criteria identified on DS and GS vs FC to classify lymphomas is not so much evaluation of the ability of cytologists to identify lymphoma types per se, as it is an evaluation of the correlation between the evaluated morphological features and lymphoma immunophenotypes. Please comment.

Author response – Undoubtedly, the first aim of the flow cytometry exam is the objective determination of the lymphoma's phenotype. However, the information derived from FC go far beyond the simple identification of cell origin: it allows the assessment of the percentage of neoplastic cells within FNA sample, their size, based on the mean FSC, and the pleomorphism, based on the standard deviation of the FSC; it's possible to evaluate the phenotype aberration (both qualitative and quantitative) which, in combination with morphological features (e.g size) allows to recognize some specific lymphoma subtypes (e.g small clear cell lymphoma). Taken together, all these data allow to make diagnosis and to identify some lymphoma subtypes. In our study, the lymphoma's grade determined by flow cytometry was compared to the lymphoma's grade obtained with DS and GS by the three observers. We added this information in the main text (lines 289-297).

Reviewer comment - Throughout the paper, I would suggest replacing observer number (1, 2, or 3) with experience level, e.g. "inexperienced", "mildly experienced" and "experienced" observer. This allows someone reading the paper to understand the context without referring back to the M&M to make that determination.

Author response – We replaced observer one with inexperienced observer, observer two with mildly experienced observer, and observer three with experienced observer in the main text.

I think the reasoning in the response to the following earlier reviewer comment is valid and should be included in the discussion:

Reviewer comment - Reviewer comment - Lines 106-107: "most representative slide" automatically creates bias. In a clinical situation, would a regular practitioner know how to choose the best slide? Also, based on reviewer experience, this information may not apply to a regular practitioner who often has less than the equivalent of 2 years cytology expertise.

Author response - It is our opinion that the WSI technology could be applied to cytological samples only for second opinion or for selected challenging cases in which the experience of a board-certified clinical-pathologist is required and, due to the long scanning time, not for the routine diagnostic procedures. For these reasons we included only cases with high cellularity and well preserved. The cellularity and preservation of a sample are characteristics that also a regular practitioner can recognize. We changed 'the most representative slide' with 'the slide with higher cellularity and better preservation' in the revised manuscript (lines 115-116).

Author response – We added this information in the discussion section (lines 312-315).

I also think the information below should be added to the M&M:

Reviewer comment - Reviewer comment - Lines 130-136: Did cytologists confer before the study to agree on the appearance of the morphological features for standardization within the study?

Author response - Yes, the cytologists conferred before the start of the study to agree on the appearance of the morphological features of the cells.

Author response – We added this information in the M&M section (line 153-154).

Reviewer comment - Lines 143-144: Variation in cell size is anisocytosis, not pleomorphism. Also please define the anisocytosis cut-off at which "pleomorphism" was considered present. Greater than 10% anisocytosis? Greater than 50%? Greater than 100%?

Author response – In the cytological evaluation of neoplastic lymph-nodes, the presence of cells with various size and shape is defined 'pleomorphism' (Fournel-Fleury et al., 2002), and the lymphomas are classified as pleomorphic (e.g. centroblastic polymorphic; small-, mixed-, or large-cell pleomorphic non-hodgkin lymphoma) when cells with different size are present (Ponce et al., 2010). In literature no cut-offs at which pleomorphism is considered present are reported.

Reviewer comment - Lines 145-148: Was perinuclear clearing considered in the distribution of the cytoplasm colour?

Author response – We did not consider the perinuclear halo in the distribution of the cytoplasm colour.

Reviewer comment - Line 152: Was variation in size or shape of nucleoli recorded?

Author response – We considered the presence/absence and the number of the nucleoli but not the variation in shape and size

Reviewer comment - Lines 153-164: What is the value of comparing the classification of low vs high grade lymphoma, when they are the exact same as comparing the classification of cell size (small vs. large and mixed)? Similarly, based on the descriptions provided B vs T cell phenotype is based on potentially dichotomous criteria (clear vs. colored cytoplasm, round vs. not-round nuclei), so why not simply compare the observers' abilities to detect those?

Author response – The cellular size is the only objective parameter that was also included in the main text as single morphological feature, but the lymphoma's grade is determined by an overall assessment of the cytological slides.

Reviewer comment - It would be interesting to consider, if the data is available, how the observer's subjective assessment of cell size (small, medium, large) correlated with the FC measurement of cell size?

Author response – Actually, this correlation is not one of the aim of our study, so we didn't record these data.

Reviewer comment - Lines 191-194: Are these changes statistically significant?

Author response – The changes are not statistically significant, we added this information in the main text (line 196).

Reviewer comment - Line 183/Table 3: What statistical test was used to determine if the differences between observers was statistically significant or not? Alternatively, what are the confidence intervals for these Kappas?

Author response – We added the 95% confidence interval for the Kappa values in tables 3 and 4.

ADDITIONAL EDITORIAL COMMENTS:

Reviewer comment - We agree with Reviewer 2 that (presumptive) phenotyping/immunophenotyping of lymphoma should not be done on cytomorphology alone; this section of the manuscript should be removed.

Author response – We deleted the phenotypical assessment based on the morphological evaluation of the neoplastic cells from the main text.

Reviewer comment - Please change "Declaration of interest" to "Conflict of interest statement".

Author response – Done (line 328).

In addition, one of the reviewers has made the following comments:

Reviewer comment - The Title is too long and should be reworded.

Author response – The Title has been changed and reduced (lines 3-4).

Reviewer comment - The current Abstract is not useful and needs to be rewritten.

Author response - We rewrote the abstract (lines 20-39).

Reviewer comment - Overall, the standard of English needs to be improved and requires major editing.

Author response – The manuscript has been edited by the Elsevier Language Editing Service. The certificate is uploaded together with the other files.

Reviewer comment - There is a need to provide an evaluation of the statistical significance of the differences between kappa values.

Author response – The K value is a measure of the agreement between two observers using two different techniques or between two techniques used by the same observer. Rarely the statistical significance for Cohen's K is reported, probably because even relatively low values of K can nonetheless be significantly different from zero but not sufficient magnitude to satisfy researchers (Bakeman and Gottman, 1997). Still, its standard error has been described (Fleiss et al., 1969). We added the 95% CI as requested by Reviewer 2.

Reviewer comment - The discussion is repetitive and needs to be streamlined.

Author response – We changed the discussion (lines 209-319).



DIPARTIMENTO DI BIOMEDICINA COMPARATA
E ALIMENTAZIONE



UNIVERSITÀ
DEGLI STUDI
DI PADOVA

VIALE DELL'UNIVERSITÀ, 16 - 35020 LEGNARO (PD) – TEL. 0498272601 FAX. 0498272604

Legnaro (PD), 06.04.2018

Dear Editor,

Please find enclosed herewith the revised version of the manuscript titled "Whole-slide imaging: cytomorphological descriptive capacity and intra-observer agreement in canine lymphoma samples (YTVJL-D-17-00838R2)".

We answered to all the revisions of the two Reviewers and of the Editor. The title's length was reduced, the abstract was changed, and all the data regarding the determination of phenotype using cytology exam were removed from the manuscript. The manuscript was revised by the Elsevier's Language Editing Service (the certificate is attached together with the other files). To add the 95% CI of the K values we changed the statistical program (from SPSS to MedCalc). With the new statistical the K value of some parameters is slightly changed. The manuscript was revised according to the new K values.

Feel free to contact me for any questions.

Thank you in advance.

Best regards.

Federico Bonsembiante

Federico Bonsembiante, DVM, Ph.D
Dept. Comparative Biomedicine and Food Science
University of Padua
AGRIPOLIS - Viale dell'Università 16
35020 Legnaro (PD) – Italy
Fax : + 39.049.8272973
e-mail : federico.bonsembiante@unipd.it