

Instructions to Contributors

Dear Contributor:

Enclosed in this document please find the page proofs and offprint order form for your article in *Joints*. Please complete and return the corrected proofs and offprint order form within 72 hours.

- 1) Please read proofs carefully for **typographical** and **factual** errors only; mark corrections in the margins of the proofs in blue or black pen, or use **Adobe Acrobat tools** to mark the changes in the PDF file directly. Please be sure to write as clearly as possible so no errors are introduced into your article. **Answer (on the proofs) all author queries marked in the margins of the proofs.** Check references for accuracy. **Please check on the 1st page of your article that your titles and affiliations are correct.** Avoid elective changes, because these are costly and time consuming and will be made at the publisher's discretion.
- 2) Please pay particular attention to the proper placement of figures, tables, and legends. Please provide copies of any formal letters of permission that you have obtained.
- 3) As a contributor to this journal you will receive a complimentary PDF file of the article after publication.
 - If you wish to order offprints, **please circle the quantity required** (left column) **and the number of pages in your article.** If you wish to order copies of the journal please enter the number of copies on the indicated line.
 - If you do not want to order offprints or journals simply put a slash through the form, **but please return the form.**

Please return all materials within 72 hours. E-mail is the easiest way to ensure your corrections are received in a timely manner. Please return the corrected proofs to:

Mitali Vyas, Project Manager
Thieme Medical and Scientific Publishers
Fax: +91-120-4556649
E-mail: mitali.vyas@thieme.in

Please do not return your materials to the editor or the typesetter.

Please note: Due to a tight schedule, if the publisher does not receive the return of your article proofs within 7 days of the date the e-mail was sent to you, the publisher reserves the right to proceed with publication without author changes. Such proofs will be proofread by the editor and the publisher.

Thank you for your contribution to this journal.

Order Form for Offprints and additional copies of *Joints*
(Effective January 2013)

Please circle the cost of the quantity/page count you require (orders must be in increments of 100)

Quantity	Pages in Article / Cost				
	1 to 4	5 to 8	9 to 12	13 to 16	17 to 20
100	\$298	\$497	\$746	\$968	\$1,158
200	\$397	\$646	\$970	\$1,258	\$1,495
300	\$496	\$798	\$1,198	\$1,568	\$1,869
400	\$549	\$886	\$1,330	\$1,735	\$2,075
500	\$598	\$966	\$1,450	\$1,886	\$2,262
1000	\$1,076	\$1,739	\$2,610	\$3,385	\$3,995

Volume/Issue #: _____ Page Range (of your article): _____

Article Title: _____

MC/Visa/AmEx No: _____ Exp. Date: _____

Signature: _____

Name: _____

Address: _____

City/State/Zip/Country: _____

Corresponding author will receive a complimentary PDF of the article after publication.

Number of **additional** copies of the journal, at the discounted rate of \$25.00 each: _____

Notes

1. The above costs are valid only for orders received before publication of the issue. **Reprints ordered after printing will be substantially more expensive.**

2. **A shipping charge will be added to the above costs.**

3. Reprints are printed on the same coated paper as the journal and saddle-stitched.

4. For larger quantities or late orders, please contact reprints department:

Phone: +1(212) 584-4662

Fax: +1(212) 947-1112

E-mail: reprints@thieme.com

Permission to Publish and Open Access Copyright Transfer Agreement

Manuscript Information:

Journal: _____

Manuscript Title: _____



Manuscript Number: _____

Authors: _____

Corresponding author's
contact data: _____

Corresponding author's
e-mail address: _____

Contact at the publishers: _____

E-mail address at
the publishers: _____

Assignment of Rights

The Thieme Publishing Group does not accept for publication in a journal any manuscript that has been published elsewhere. Your consent to the following assignments of rights, also on behalf of the other authors (if several authors contribute to the manuscript), and the signing of this Open Access Copyright Transfer Agreement is a necessary requirement for the publication of your manuscript.

Without prejudice to this assignment of rights, the moral rights in connection with the article shall remain with you and the other authors.

The article will be published under a CC-BY-NC-ND license (<https://creativecommons.org>). This license means that anyone may freely read, download, distribute and make the article available to the public (in printed and electronic form), provided that the author and the journal as the source are acknowledged, whereas no commercial use is allowed and the work may not be altered, transformed or serve as the basis for a derivative work.

Thieme will endeavor to ensure maximum dissemination of your manuscript and to protect your authors' rights against misuse, such as plagiarism.

For this reason upon acceptance of the manuscript by us you and your co-authors agree to hereby transfer on a non-exclusive basis copyright to Thieme. This includes (in addition to the publication under a CC-BY-NC-ND license), for the duration of the statutory term of copyright protection and throughout the world, the full rights to use the paper (including excerpts thereof) within the journal or separate to it, on a commercial or non-commercial basis, linked to other works or papers, audio-visual accompanying materials or interactive products or services, including the transfer to third parties (e.g., under license agreements, etc.), in particular the non-exclusive right to use all editions/updates for the following purposes:

— reproduction and distribution in printed form, in particular as a journal article, article in a medical textbook or other type of book directed towards a specific target group of readers, pocket book, special edition for secondary markets or special customers, brochure, supplement, anthology, etc.;

Please use the latest Adobe Reader version independently of your system software (Windows, Linux, Mac OS X).
To download Adobe Reader: [click here](#).

Dear Author,

Please

- *read this form carefully,*
- *check all manuscript information,*
- *sign this form with your digital signature and*
- *return to us by clicking on*



Thank you very much in advance.



<https://creativecommons.org>

Permission to Publish and Open Access Copyright Transfer Agreement

– reproduction and distribution in the form of electronic media (e.g., magnetic tape, CD-ROM, CDI, DVD, electronic paper or chips, e-book, RAM, hard disk, USB-based storage media, etc.), making available to the public (e.g., the Internet, intranets or other wired or wireless data networks), in particular by displaying such data on stationary or mobile visual display units, screens, personal digital assistants, mobile phones, smart phones or other receiver terminals by download (e.g., as an epub, app or PDF file) or retrieval in any other form;

– translation, transmission or adaptation of the paper into or in any other language, dialects or versions (in particular, as a podcast, audio book, or other image or sound carriers etc.), transmission through television, cable or satellite TV, radio or by means of other audio-visual media, renting or lending, storage in an electronic archive, including storage in connection with indexation, key word search or any other search and additional functions, usage for types of use not as yet known and for any other rights used by collecting societies as provided in their articles and allocation plans, provided that the transfer of such rights is permissible under the relevant provisions and applicable law; you also assign to Thieme all statutory royalty claims under §§ 44a et seq. Urheberrechtsgesetz (German Copyright Law) insofar Thieme mandates a collecting society to administer such rights jointly for authors and publishers.

Thieme is entitled, but not obliged, to use the rights specified in the aforesaid sections and may adapt the article for these uses. Thieme will take your and your co-authors' legitimate interests into account in this respect.

Authors' rights and Gold Open Access

The rights of use are assigned to us non-exclusively – subject to your rights in accordance with our Open Access (OA) Guidelines: Our OA Guidelines state that immediately after the publication of the article by us, you and the other authors are entitled to make the published version of the article available to the public. For further details please click the button "Authors' rights and Gold Open Access."

For more Information on our OA Program please visit <http://open.thieme.com>.

Article Publication Charge

Publication of the article is subject to an article publication charge of _____ (incl. VAT if any).
The article will be published upon receipt of the payment by Thieme.

Duties of care

Product liability laws set high standards for your duty of care as the author of a scientific manuscript. This is especially the case when you give therapeutic information and/or specify drug doses. Therefore please check this information carefully in the typeset page-proofs of your article. Your task will be much easier if you have the information counterchecked – depending on the sensitivity of the information within the article – by specialist colleagues. Only you, as the author, have the specialist knowledge to be able to assess the accuracy of the information. For further information on how to indicate corrections, please click the button "Correction markup symbols."

Author's Declaration

I have taken note of the information on the duties of care under product liability law; I agree to the assignments of rights in accordance with the foregoing sections "Assignment of Rights" and "Authors' Rights and Gold Open Access" also on behalf of the other authors (if several authors have contributed to the article). I declare that I am authorized by my co-authors to sign on their behalf.


I declare that no third party rights will be infringed through the publication. Any material contained in the manuscript (including illustrations, tables, or other material) from third-party sources will be identified as such through citation, indicating the source. If required, I have obtained the copyright permission from the publishers concerned.

I have read and understood the terms and conditions of the CC-BY-NC-ND license and I agree also on behalf of the other authors (if several authors have contributed to the article) **that the article will be published under such a license.**

I agree with the aforesaid article publication charge. Should one of the foregoing regulations be or become invalid in whole or in part this shall not affect the validity of the other provisions. Any invalid provision shall be replaced by a regulation that comes as close as possible to the purpose of the invalid provision in economic terms, insofar as legally permissible.

This article is ready to be published after the execution of the corrections indicated by me.

Date Digital Signature



Authors' rights and
Gold Open Access



Correction markup
symbols



Digital signature



Distance of Posterior Interosseous Nerve from Radial Head during Elbow Arthroscopy: An Anatomical Study

Paolo Arrigoni^{1,2,*} Davide Cucchi^{1,3,*} Enrico Guerra⁴ Alessandro Marinelli⁴ Alessandra Menon^{1,2}
Pietro Simone Randelli^{1,2} Luigi Adriano Pederzini⁵ SIGASCOT Upper Limb Committee

¹Dipartimento di Scienze Biomediche per la Salute, Università degli Studi di Milano, Milan, Italy

²U.O.C. 1ª Divisione, Azienda Socio Sanitaria Territoriale Centro Specialistico Ortopedico Traumatologico Gaetano Pini-CTO, Milan, Italy,

³Department of Orthopaedics and Trauma Surgery, University of Bonn, Bonn, Germany

⁴Shoulder and Elbow Unit, Ortopedico Rizzoli, Bologna, Italy

⁵Arthroscopic and Sport Medical ^{Q1}Center, Nuovo Ospedale di Sassuolo, Sassuolo, Italy

Address for correspondence Davide Cucchi, MD, Dipartimento di Scienze Biomediche per la Salute, Università degli Studi di Milano, Via Mangiagalli 31, Milan 20133, Italy (e-mail: d.cucchi@gmail.com).



Joints 2017;00:1–5.

Abstract

Purpose The aims of this study were to measure the distance of the posterior interosseous nerve (PIN) from the radial head (RH) and its variations with forearm movements.

Methods Five fresh frozen cadaver specimens were dissected under arthroscopy. An anterior capsulectomy extended to the entire lateral compartment was performed. The need of soft tissue dissection to isolate the nerve in the extracapsular space was recorded. The distance between the nerve and the anterior part of the RH was then measured with a graduated caliper inserted via the midlateral portal with the forearm in neutral position, full pronation, and full supination.

Results The PIN was identifiable in all the specimens. In four cases, it was surrounded by a thick layer of adipose tissue, and further dissection was necessary to isolate it. Damage of the PIN during dissection occurred in one case, in which the proximal part of the nerve was accidentally cut. In three of the remaining cases, an increased distance was measured with the forearm in supination, as compared with neutral and full pronation position.

Conclusion This anatomical study suggests that in most of the cases, the PIN does not lay just extracapsular at the level of the radiocapitellar joint, but is surrounded by a thick layer of adipose tissue. Furthermore, its distance from the RH appears to increase with forearm supination. This position could increase the safe working space between RH and PIN.

Clinical Relevance Knowledge of PIN position in relation to the anterior elbow capsule and its changes with forearm movements can help reduce the iatrogenic injuries during elbow arthroscopy.

Keywords

- ▶ elbow arthroscopy
- ▶ posterior interosseous nerve
- ▶ nerve injury
- ▶ cadaver

*P. Arrigoni and D. Cucchi contributed equally to this work.

Introduction

The posterior interosseous nerve (PIN) innervates the supinator muscle and the extensor muscles of the wrist and the digits. A lesion to this nerve can occur after trauma and during open or arthroscopic elbow surgery. It may have dramatic consequences on forearm function and hence negatively affects the surgical outcome of procedures to the anterior and lateral aspect of the elbow.¹⁻⁷

Although detailed measurements of PIN course have been provided from open surgical approaches, arthroscopic descriptions are lacking.⁸⁻¹¹ Moreover, because of the different surgical position and setup used, conclusions derived from open surgery cannot be directly transferred into arthroscopic practice. For instance, the position of the elbow (90 degrees flexion and hanging with gravity when operating in prone or modified lateral decubitus) and the presence of intra-articular irrigation may influence the nerve displacement to a more anterior-inferior direction.

The primary aim of this study was to measure the distance of the PIN from the radial head (RH) during arthroscopic cadaver dissection and assess if PIN-RH distance varied with the forearm in a fully pronated and fully supinated position. The hypothesis of the study was that forearm movements could affect PIN-RH distance.

Methods

Five fresh, frozen cadaver specimens were dissected under arthroscopy. Arthroscopy was performed with the elbow positioned at 90 degrees of flexion, with the hand and forearm hanging free with only gravity force. Standard posterior, posterolateral, and midlateral portals were first established to explore the posterior compartment, posteromedial gutter, and posterior aspect of the radiocapitellar joint. The anterior compartment of the elbow was then entered. A proximal anteromedial portal was created 2 cm proximal to the medial humeral epicondyle and 1 cm anterior to the intramuscular septum. Insertion of a 30-degree arthroscope into this portal allowed intra-articular diagnostic evaluation. An anterior capsulectomy extending into the lateral compartment was performed through a standard arthroscopic meniscal biter via the anteromedial approach while looking from the anterolateral portal. Particular attention was paid to identify the PIN immediately after anterior capsulectomy in the extracapsular space. If additional soft tissue dissection was necessary to isolate the radial nerve, the presence and quality of the interposed tissue was recorded.

After identification of the PIN, the distance between the nerve and the most anterior part of the radial head was measured with a graduated caliper inserted via the midlateral portal with the forearm in neutral position (PIN-RH_n) and expressed in centimeters (►Fig. 1). Subsequently, the forearm was moved first in full pronation and then in full supination; the same measurement was performed and recorded (PIN-RH_p and PIN-RH_s, respectively). Raw data were then normalized for the interepicondylar distance to account for anthropometric variations.

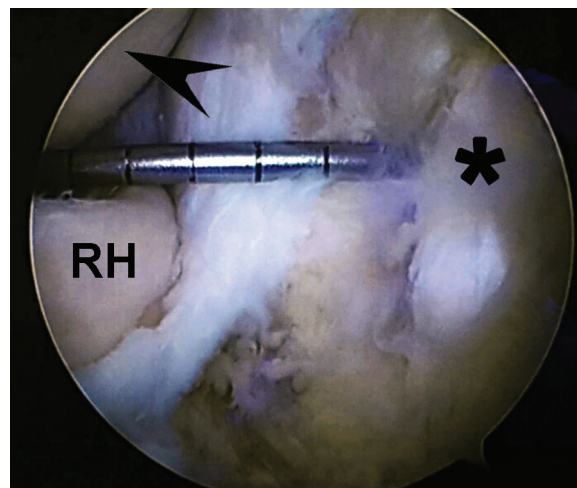


Fig. 1 ^{Q2} Arthroscopic measurement of the distance between the anterior part of the RH and the posterior interosseous nerve (asterisk) with a graduated caliper inserted through the midlateral portal. Arrowhead indicates capitellum. RH; radial head.

Q2

All dissections were conducted by a group of surgeons experienced both in open and arthroscopic elbow procedure. Statistical analysis was performed using GraphPad Prism v 6.0 software (GraphPad Software Inc.). The Shapiro-Wilk normality test was used to evaluate the normal distribution of the sample; nonparametric test (Friedman's test) was used to assess within-group differences and to compare measurements repeated in different conditions. Continuous variables were expressed as median and interquartile (IQ) range (first and third quartiles) and or as mean \pm standard deviation as appropriate.

Results

Five specimens (median age: 83 years; range: 77-84; left elbow: 60%) were evaluated. Mean interepicondylar distance was 7.26 ± 1.78 cm. The PIN was identifiable in all specimens. Damage of the PIN during dissection occurred in one case, in which the proximal part of the nerve was accidentally cut. In this case, the PIN-RH_p and PIN-RH_s distances could not be measured and were not included in further analysis. In all other cases, PIN-RH_n, PIN-RH_p, and PIN-RH_s could be measured successfully.

In three cases, an increased distance in PIN-RH_s as compared with PIN-RH_n and PIN-RH_p was noted, although no significant difference could be identified (►Table 1).

Only in one specimen, the identification occurred immediately after capsulectomy. In the other four cases, it was necessary to isolate the nerve by further dissection. The tissue separating the nerve from the anterior elbow capsule was adipose in the four mentioned specimens (►Fig. 2).

Discussion

This anatomical study showed that the distance of the PIN from the RH can vary with forearm movements and suggested that supination could increase the PIN-RH distance, when compared with pronation and neutral position. Moreover, this

Table 1 Absolute distance in centimeters of PIN-RH, normalized for interepicondylar distance with forearm in PIN-RH_n, PIN-RH_p, and PIN-RH_s

Specimen	PIN-RH _n	PIN-RH _p	PIN-RH _s
1	0.23	0.15	0.30
2	0.10	0.07	0.12
3	0.38	0.54	0.31
5	0.26	0.18	0.37
Mean ± SD	0.24 ± 0.12	0.23 ± 0.21	0.27 ± 0.11
Median (IQR)	0.25 (0.19–0.29)	0.16 (0.13–0.27)	0.31 (0.26–0.32)

Abbreviations: IQR, interquartile range; PIN, posterior interosseous nerve; RH, radial head; SD, standard deviation.

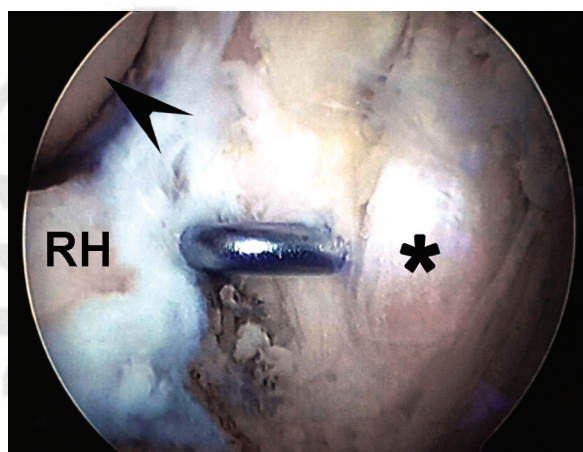


Fig. 2 The posterior interosseous nerve (asterisk) is separated from the anterolateral elbow capsule by a thick layer of adipose tissue, which is retracted by a probe inserted through the posterolateral portal. Arrowhead indicates capitellum. RH, radial head.

study suggested that at the level of the radiocapitellar joint, the PIN did not lay just extracapsular, as previously described, but was surrounded by a layer of adipose tissue. Due to the small sample size, no significant difference could be identified in the study population, and therefore, larger studies with adequate sample size are required to confirm these conclusions.

The PIN is a motor nerve, which originates from the radial nerve after it separates from its superficial, sensory branch distally in the arm.^{10,12,13} In its proximal region, the PIN is separated from the joint capsule by the brachialis muscle; distally, when crossing the level of the RH, no muscle bellies divide this structure from the joint, and only a thin layer of adipose tissue can be identified. Afterward, the PIN passes below the arcade of Frohse and continues its course toward the supinator muscle and the extensor muscles of the wrist and the digits, which are innervated by its fibers.^{10,14,15}

In open surgery, the nerve is most vulnerable when passing below the arcade of Frohse and between the fibers of the supinator muscle. Nerve injury can be avoided by maintaining the forearm in pronation and approaching the

RH by either stripping the supinator from the radius (without exposing the PIN) or dividing its superficial humeral head to expose the PIN.^{16–19}

Knowing the relative distance of the PIN to the RH and its variations with different forearm positions is a precious help in defining a safe working area in elbow arthroscopy. Previous studies on the variation of PIN position with forearm movements have only been performed in open surgery models with volar, dorsal, and lateral approaches. These studies demonstrated that a safe zone between the radiocapitellar joint to the point where the PIN crossed the lateral midline existed and its width decreased substantially with forearm movements from pronation to supination.^{8,13,15,20,21} No arthroscopic descriptions of the PIN position and its movements with respect to the most anterior part of the RH have been published yet.

The PIN is exposed to risk of injury during arthroscopy in two surgical steps: during portal establishment, since it passes close to the anterolateral portal, and during procedures on the RH. While in its most proximal region, it is protected by the brachialis muscle, at the level of the RH, the PIN is separated from the joint capsule just by a layer of adipose tissue.^{13,22} Injury to the PIN is a known complication in elbow arthroscopy;^{6,23} however, a recent survey among the American Society for Surgery of the Hand members on major nerve injuries after elbow arthroscopy indicated this complication as under reported in the current literature.²⁴ Our experience confirms that accidental lesion of the PIN may also happen easily to experienced surgeons. Therefore, we advise extreme care when performing elbow arthroscopy and suggest some tricks to reduce the risk of iatrogenic injury.

To prevent injuries in portal placement, we recommend to locate the anterolateral portal with an out-in technique, checking the needle entry point from the anteromedial portal, and to carefully incise the skin and subcutaneous tissues before inserting the arthroscope sheath and trocar or to locate this portal through an in-out technique.^{25,26} While establishing this portal, pronation displaces the nerve anteromedially, increasing safety on the chosen trajectory.^{21,27}

To avoid accidental injury during intra-articular procedures, it is recommended to inject fluid to distend the capsule and displace the neurovascular structures away from the joint and orient the shaver or burr posteriorly. Inserting a retractor from a proximal anterolateral portal aimed at the radiocapitellar joint is another protective solution.^{28,29} Although no statistical significance could be obtained due to the small sample size, the results of this study suggested that supination could increase the distance of the PIN from the RH. Therefore, we agree in recommending pronation of the forearm whenever performing lateral extra-articular procedures (open approaches or portal placement), but recommend to supinate the forearm when working intraarticularly to increase the safe working space between the most anterior part of the RH and the PIN.

Future imaging studies with ultrasound or magnetic resonance imaging could help in clarifying the static and dynamic behavior of this nerve with respect to the RH.

Open dissections indicate that while in its most proximal region, it is protected by the brachialis muscle, at the level of the RH, the PIN lays in a very extracapsular space in front of

the RH, separated from the capsule just by a layer of adipose tissue.^{8,9,13,16,20,22,30}

Assuming this statement, during standard arthroscopic surgery, precautions are taken considering the joint capsule to be the only protection from injuring the nerve in the space anterior to the RH.⁸⁻¹¹ This study demonstrated that a thick layer of adipose tissue could be frequently encountered between the joint capsule and the PIN. This means that the safe zone between capsule and PIN is wider than expected from open cadaveric dissections, and therefore inadvertent shaving beyond the capsule layer can be forgiving in some cases. Nonetheless, we recommend using extreme care whenever working on the anterolateral aspect of elbow joint, taking all aforementioned precautions to avoid iatrogenic PIN injury.

Some authors recommended isolating the nerve in preparation for intra-articular procedures; in this study, in one specimen, the arthroscopic dissection, aimed at nerve identification, led to unexpected nerve damage. As a layer of adipose tissue protects this nerve from inadvertent excessive capsular shaving and nerve isolation may damage it, we advise against a routine dissection of the PIN, unless specifically indicated for the surgical procedure.

Limitations of this study include small sample size; this does not allow differentiating between any anatomical variants and may amplify bias related to technical aspects of the dissection. To reduce these, all the arthroscopies were performed by surgeons experienced in the field of elbow surgery. The nature of the study did not allow investigating on local pathologies of the capsule or systemic diseases that may influence soft tissue quality. The age of the specimens examined differs from the age range of patients undergoing elective arthroscopic elbow surgery, suggesting care when translating this anatomical data to a younger population. However, we suppose the behavior of this structure not to be directly affected by age depending tissue changes. Finally, we did not evaluate the effect of fluid extravasation on changes in the structural quality of the adipose tissue; in particular, we suppose that the length of the surgical procedure, especially with prolonged forceful positions, could influence adipose tissue distension and softness.³¹

In conclusion, PIN injuries are a serious complication of elbow surgery, and the knowledge of the working space is critical in avoiding them during arthroscopy. Although no statistical significance could be obtained due to the small sample size, this study suggests that the PIN assumes variable positions with respect to the RH when the forearm is moved, with a tendency toward increasing its distance in supination. Moreover, this study suggests that in most of the cases, the PIN does not lay just extracapsular at the level of the radiocapitellar joint, but is surrounded by a thick layer of adipose tissue. Dissection aimed to isolate the nerve may create anyway further iatrogenic damage and is not indicated unless specifically needed for the surgical procedure.

References

- Daurka J, Chen A, Akhtar K, Kamineni S. Tardy posterior interosseous nerve palsy associated with radial head fracture: a case report. *Cases J* 2009;2(01):22
- Erra C, De Franco P, Granata G, et al. Secondary posterior interosseous nerve lesions associated with humeral fractures. *Muscle Nerve* 2016;53(03):375-378
- Van Geertruyden JP, Vico PG. Iatrogenic posterior interosseous nerve palsy following an elbow fracture. *Acta Orthop Belg* 1996; 62(04):222-224
- Saldua N, Carney J, Dewing C, Thompson M. The effect of drilling angle on posterior interosseous nerve safety during open and endoscopic anterior single-incision repair of the distal biceps tendon. *Arthroscopy* 2008;24(03):305-310
- Lo EY, Li CS, Van den Bogaerde JM. The effect of drill trajectory on proximity to the posterior interosseous nerve during cortical button distal biceps repair. *Arthroscopy* 2011;27(08):1048-1054
- Gupta A, Sunil Tm Tm. Complete division of the posterior interosseous nerve after elbow arthroscopy: a case report. *J Shoulder Elbow Surg* 2004;13(05):566-567
- Mercer DM, Baldwin ED, Moneim MS. Posterior interosseous nerve laceration following elbow arthroscopy. *J Hand Surg Am* 2015;40(03):624-626
- Diliberti T, Botte MJ, Abrams RA. Anatomical considerations regarding the posterior interosseous nerve during posterolateral approaches to the proximal part of the radius. *J Bone Joint Surg Am* 2000;82(06):809-813
- Tornetta P III, Hochwald N, Bono C, Grossman M. Anatomy of the posterior interosseous nerve in relation to fixation of the radial head. *Clin Orthop Relat Res* 1997;(345):215-218
- Ozkan M, Bacakoğlu AK, Gül O, Ekin A, Mağden O. Anatomic study of posterior interosseous nerve in the arcade of Frohse. *J Shoulder Elbow Surg* 1999;8(06):617-620
- Mazurek MT, Shin AY. Upper extremity peripheral nerve anatomy: current concepts and applications. *Clin Orthop Relat Res* 2001;(383):7-20
- Clavert P, Lutz JC, Adam P, Wolfram-Gabel R, Liverneaux P, Kahn JL. Frohse's arcade is not the exclusive compression site of the radial nerve in its tunnel. *Orthop Traumatol Surg Res* 2009;95(02): 114-118
- Lawton JN, Cameron-Donaldson M, Blazar PE, Moore JR. Anatomic considerations regarding the posterior interosseous nerve at the elbow. *J Shoulder Elbow Surg* 2007;16(04):502-507
- Thomas SJ, Yakin DE, Parry BR, Lubahn JD. The anatomical relationship between the posterior interosseous nerve and the supinator muscle. *J Hand Surg Am* 2000;25(05):936-941
- Spinner M. The arcade of Frohse and its relationship to posterior interosseous nerve paralysis. *J Bone Joint Surg Br* 1968;50(04): 809-812
- Kaplan E. Surgical approach to the proximal end of the radius and its use in fractures of the head and neck of the radius. *J Bone Joint Surg* 1941;23:86-92
- Heidari N, Kraus T, Weinberg AM, Weiglein AH, Grechenig W. The risk injury to the posterior interosseous nerve in standard approaches to the proximal radius: a cadaver study. *Surg Radiol Anat* 2011;33(04):353-357
- Strauch RJ, Rosenwasser MP, Glazer PA. Surgical exposure of the dorsal proximal third of the radius: how vulnerable is the posterior interosseous nerve? *J Shoulder Elbow Surg* 1996;5(05): 342-346
- Schimizzi A, MacLennan A, Meier KM, Chia B, Catalano LW III, Glickel SZ. Defining a safe zone of dissection during the extensor digitorum communis splitting approach to the proximal radius and forearm: an anatomic study. *J Hand Surg Am* 2009;34(07): 1252-1255
- Calfee RP, Wilson JM, Wong AH. Variations in the anatomic relations of the posterior interosseous nerve associated with proximal forearm trauma. *J Bone Joint Surg Am* 2011;93(01): 81-90
- Strachan JC, Ellis BW. Vulnerability of the posterior interosseous nerve during radial head resection. *J Bone Joint Surg Br* 1971; 53(02):320-323

- 22 Kelly EW, Morrey BF, O'Driscoll SW. Complications of elbow arthroscopy. *J Bone Joint Surg Am* 2001;83-A(01):25–34
- 23 Carofino BC, Bishop AT, Spinner RJ, Shin AY. Nerve injuries resulting from arthroscopic treatment of lateral epicondylitis: report of 2 cases. *J Hand Surg Am* 2012;37(06):1208–1210
- 24 Desai MJ, Mithani SK, Lodha SJ, Richard MJ, Leversedge FJ, Ruch DS. Major peripheral nerve injuries after elbow arthroscopy. *Arthroscopy* 2016;32(06):999–1002.e8
- 25 Chaware PN, Santoshi JA, Pakhare AP, Rathinam BA. Risk of nerve injury during arthroscopy portal placement in the elbow joint: a cadaveric study. *Indian J Orthop* 2016;50(01):74–79
- 26 Blonna D, Wolf JM, Fitzsimmons JS, O'Driscoll SW. Prevention of nerve injury during arthroscopic capsulectomy of the elbow utilizing a safety-driven strategy. *J Bone Joint Surg Am* 2013;95(15):1373–1381
- 27 Marshall PD, Fairclough JA, Johnson SR, Evans EJ. Avoiding nerve damage during elbow arthroscopy. *J Bone Joint Surg Br* 1993;75(01):129–131
- 28 Pederzini LA, Nicoletta F, Tosi M, Prandini M, Tripoli E, Cossio A. Elbow arthroscopy in stiff elbow. *Knee Surg Sports Traumatol Arthrosc* 2014;22(02):467–473
- 29 Savoie FH III. Guidelines to becoming an expert elbow arthroscopist. *Arthroscopy* 2007;23(11):1237–1240
- 30 Jackson RW, Chow JCY. (2012) *Advanced Arthroscopy*. New York: Springer
- 31 Links AC, Graunke KS, Wahl C, Green JR III, Matsen FA III. Pronation can increase the pressure on the posterior interosseous nerve under the arcade of Frohse: a possible mechanism of palsy after two-incision repair for distal biceps rupture—clinical experience and a cadaveric investigation. *J Shoulder Elbow Surg* 2009;18(01):64–68




THIEME

Author Query Form (JOINTS/1704)

Special Instructions: Author please write responses to queries directly on proofs and then return back.

Q1: AU: Please provide department/division name, if any. 

Q2: AU: Your article has two color figures. Please confirm if you would like to have figures in color in print or in color online  only. Please note that the cost for printing color figures is \$200 per colored typeset page (irrespective of the number of color figures on a page). In case you choose to go with black and white images in print, please amend the color indicators, if any, appropriately. Note that the figures shall be published online in color free of cost.



THIEME