

## QUIZ SECTION

## Vegetating Nodules Following Erosions on the Oral Cavity: A Quiz

Angelo V. Marzano, Sebastiano Recalcati, Claudia Menicanti, Carlo Crosti and Marco Cusini\*

U.O. Dermatologia, Fondazione IRCCS Ca' Granda – Ospedale Maggiore Policlinico – Dipartimento di Fisiopatologia Medico-Chirurgica e dei Trapianti Università degli Studi di Milano, via Pace 9, IT-20122 Milan, Italy. \*E-mail: m.cusini@policlinico.mi.it

A 68-year-old Italian man presented with a 7-month history of multiple erosions on the trunk as well as lips and oral cavity. Before admission to our department, he was treated in another institution with systemic corticosteroids (oral prednisone at the initial dose of 1 mg/kg/day, with progressively tapering dosages for 2 months) and other immunosuppressants, such as azathioprine (1.25 mg/kg/day for 2 months), intravenous immunoglobulins (one cycle consisting of one infusion of 400 mg/kg/day for 5 consecutive days), and rituximab (one cycle consisting of one infusion of 375 mg/m<sup>2</sup>/every week for 4 weeks), achieving resolution of the cutaneous manifestations but without control of the oral involvement. Upon admission,

he had multiple lip and oral erosions (Fig. 1a). In the following days, he developed erythematous-violaceous vegetating nodules that coalesced into ulcerated plaques on the lips and tongue (Fig. 1b). The patient's general condition was compromised; he was asthenic and, due to dysphagia, had lost about 15 kg in the last 3 months. Staging fibroscopy revealed nodules that induced marked stenosis of the larynx and pharynx (Fig. 1c). Within a few days, an emergency tracheotomy was required because of acute dyspnea. Biopsy specimens from a nodule were submitted for histology (Fig. 1d).

*What is your diagnosis? See next page for answer.*

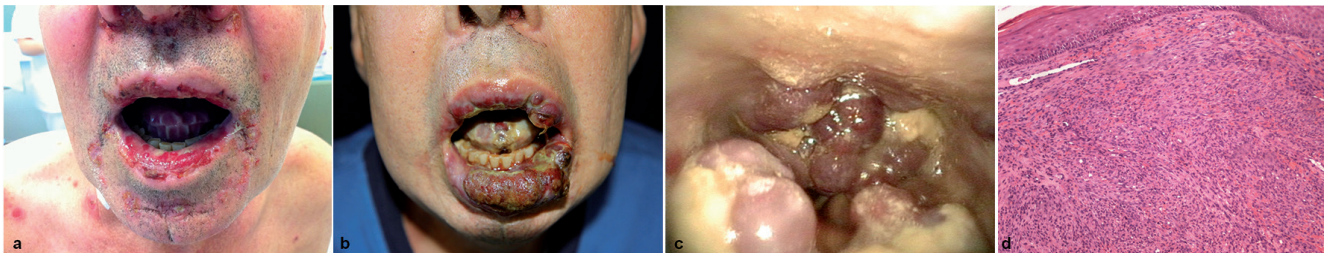


Fig. 1. (a) Clinical presentation at the onset: multiple lip and oral erosions. (b) Erythematous-violaceous vegetating nodules that coalesced into ulcerated plaques on the lips and tongue. (c) Fibroscopy revealed nodules that induced marked stenosis of the larynx and pharynx. (d) Histopathology: spindle cell fascicles, proliferation of irregular blood vessels, focal necrosis and extravasated erythrocytes with release of hemosiderin (H&E; ×25).

doi: 10.2340/00015555-1936

## ANSWERS TO QUIZ

**Vegetating Nodules Following Erosions on the Oral Cavity: A Comment**

Acta Derm Venereol

**Diagnosis: Iatrogenic Kaposi's sarcoma associated with pemphigus vulgaris**

On admission to our clinic, we confirmed the diagnosis of pemphigus vulgaris by means of typical histopathological and immunofluorescence features (1).

After few days, during immunosuppressive treatment, the oral lesions progressively worsened, and he developed erythematous-violaceous nodules.

Histopathologic examination revealed the presence of spindle cell fascicles, proliferation of irregular blood vessels, focal necrosis and extravasated erythrocytes with release of haemosiderin (Fig. 1d). These findings combined with strong and diffuse immunohistochemical positivity for human herpes virus 8 (HHV8) (Novocastra, UK) were consistent with the diagnosis of Kaposi sarcoma (KS).

Serology for HHV8 was positive, while HIV-1 serum antibodies were negative. Therapy based on bleomycin (15 IU i.m. every 3 weeks) was started in combination with corticosteroid tapering. This improved the KS lesions, but led to recurrence of pemphigus vulgaris blistering lesions; moreover, pancytopenia occurred (white blood cell count  $1,580 \times 10^9/l$  [4.8–10.8], platelet count  $33 \times 10^9/l$  [150–450]). The patient died one month later after developing pneumonia sustained by *Acinetobacter baumannii* and subsequent septic shock with multi-organ failure.

KS is an HHV8-associated angioproliferative disorder of low-grade malignant potential (2). Aetiopathogenesis is still debated, but it is well known that impaired immunity could favour the development of this disease. Four types of KS are recognised: classic, endemic, iatrogenic and AIDS-associated (3). Iatrogenic KS has been observed in patients who receive immunosuppressive therapy for malignant processes such as lymphomas and multiple myeloma, for renal and cardiac transplant recipients, and for autoimmune diseases (4–6). Concerning immune-mediated inflammatory skin conditions, a case of KS

arising in the context of atopic dermatitis treated with cyclosporine has recently been reported (7). KS associated with pemphigus is regarded as iatrogenic, and arises after the administration of immunosuppressive therapy. The clinical features are different from those of the classical KS but similar to the AIDS-associated KS: widespread lesions with a marked tendency to visceral involvement, particularly of the gastrointestinal tract, that often lead to death (7, 8). The overall prognosis in a published review of 10 cases was poor: 5 of the 10 reported cases died within 1 year from the diagnosis (8–10).

## REFERENCES

1. Marzano AV, Tedeschi A, Spinelli D, Fanoni D, Crosti C, Cugno M. Coagulation activation in autoimmune bullous diseases. *Clin Exp Immunol* 2009; 158: 31–36.
2. Grayson W, Pantanowitz L. Histological variants of cutaneous Kaposi sarcoma. *Diagn Pathol* 2008; 3: 31.
3. Tourlaki A, Recalcati S, Boneschi V, Gaiani F, Colombo A, Mancuso R, Brambilla L. Anaplastic Kaposi's sarcoma: a study of eight patients. *Eur J Dermatol* 2013; 23: 382–386.
4. Avalos-Peralta P, Herrera A, Ríos-Martín JJ, Pérez-Bernal AM, Moreno-Ramírez D, Camacho F. Localized Kaposi's sarcoma in a patient with pemphigus vulgaris. *J Eur Acad Dermatol Venereol* 2006; 20: 79–83.
5. Trattner A, Hodak E, David M, Sandbank M. The appearance of Kaposi sarcoma during corticosteroid therapy. *Cancer* 1993; 72: 1779–1783.
6. Cathomas G, Tamm M, McGandy CE, Itin PH, Gudat F, Thiel G, Mihatsch MJ. Transplantation-associated malignancies: restriction of human herpes virus 8 to Kaposi's sarcoma. *Transplantation* 1997; 64: 175–178.
7. Wall D, McMenamin M, O'Mahony D, Irvine AD. Kaposi sarcoma in an patient with atopic dermatitis treated with ciclosporin. *BMJ Case Rep* 2013; 2013. pii: bcr2013202171.
8. Kaplan RP, Israel SR, Ahmed AR. Pemphigus and Kaposi's sarcoma. *J Dermatol Surg Oncol* 1989; 15: 1116–1121.
9. Pantanowitz L, Dezube BJ. Kaposi's sarcoma and pemphigus. *J Eur Acad Dermatol Venereol* 2007; 21: 571–572.
10. Serdaroglu S, Antonov M, Demirkesen C, Tuzun Y. Iatrogenic Kaposi's sarcoma in a patient with pemphigus vulgaris. *Clin Exp Dermatol* 2009; 34: 839–840.