

Progressively invalidating orthostatic hypotension: A common symptom for a challenging diagnosis

Serena Pelusi, Rosa Lombardi, Lorena Airaghi, Larry Burdick, Mario Rango¹, Alessandra Penatti², Silvia Fargion

Departments of Internal Medicine and ¹Neurological Sciences, Fondazione IRCCS Ca' Granda Ospedale Maggiore Policlinico, ²Department of Physiatry and Rheumatology, Division of Rheumatology, Istituto Ortopedico Gaetano Pini, Milan, Italy

We discuss here an uncommon condition of neurogenic hypotension in the context of immunoglobulin light chain (amyloid light-chain) amyloidosis. The most serious feature was autonomic nervous system impairment, mainly characterized by severe refractory orthostatic hypotension, which became progressively invalidating, forcing the patient to bed. Moreover, since the systemic involvement of the disease, the patient presented also diarrhea, dysphagia, asthenia, peripheral edema because of gastrointestinal, and kidney dysfunction. Eventually, the massive myocardial depression and infiltration led to a fatal outcome.

Key words: Amyloidosis, multiple myeloma, refractory hypotension, restrictive cardiomyopathy, tilt test

How to cite this article: Pelusi S, Lombardi R, Airaghi L, Burdick L, Rango M, Penatti A, Fargion S. Progressively invalidating orthostatic hypotension: A common symptom for a challenging diagnosis. *J Res Med Sci* 2016;21:114.

INTRODUCTION

This report describes a case of systemic amyloidosis that began with severe refractory orthostatic hypotension, the most invalidating feature of autonomic nervous system involvement.

CASE REPORT

We describe a case of amyloid light-chain (AL) amyloidosis in a 73-year-old woman whose most invalidating feature was severe refractory orthostatic hypotension (OH), associated with dysphagia and diarrhea. After otorhinolaryngologist evaluation, gastroenteric endoscopic studies, abdomen ultrasound, and brain nuclear magnetic resonance imaging (MRI) scan, the diagnosis was unknown. Indeed, OH became progressively more even invalidating, determining syncope and hospitalizations. During one of them, cardiac junctional rhythm was detected, and a pacemaker was implanted.

On admission, clinical examination showed severe OH (systolic blood pressure [SBP] dropping down to 70 mmHg) with unmodified heart rate (HR). Furthermore, mild right ocular ptosis and labial commissure deviation were present, in addition to right leg hyposthenia. Blood tests depicted normocytic anemia (Hb 11 g/dL), a rise in cholestasis indexes (alkaline phosphatase 201 UI/L; gamma-glutamyl transferase 328 UI/L with normal bilirubin) and hypoalbuminemia (2.7 g/dL). A tilt table test demonstrated the absence of autonomic reflexes with severe blood pressure drop (SBP up to 55 mmHg and diastolic blood pressure [DBP] up to 28 mm Hg) without HR modification when reaching upright position [Figure 1]. An electromyography (EMG) identified a typical pattern of chronic bilateral L5-S1 radiculopathy, excluding any diagnostic abnormality for polyneuropathy. Because of the persistence of dysphagia, endoscopic evaluation was repeated, and the histological examination of a hyperemic gastric antrum pointed out perivascular deposits positive to Congo red staining, identified as amyloid at immunochemistry. A multisystemic disease became evident: renal involvement with proteinuria (2.5 g/24 h), autonomic nervous system involvement characterized

Access this article online

Quick Response Code:



Website:
www.jmsjournal.net

DOI:
10.4103/1735-1995.193508

This is an open access article distributed under the terms of the Creative Commons Attribution-NonCommercial-ShareAlike 3.0 License, which allows others to remix, tweak, and build upon the work non-commercially, as long as the author is credited and the new creations are licensed under the identical terms.

For reprints contact: reprints@medknow.com

Address for correspondence: Dr. Lorena Airaghi, Department of Internal Medicine, Fondazione IRCCS Ca' Granda Ospedale Maggiore Policlinico, Via Francesco Sforza 35, 20122 Milan, Italy. E-mail: lorena.airaghi@policlinico.mi.it

Received: 21-05-2016; **Revised:** 23-07-2016; **Accepted:** 30-08-2016

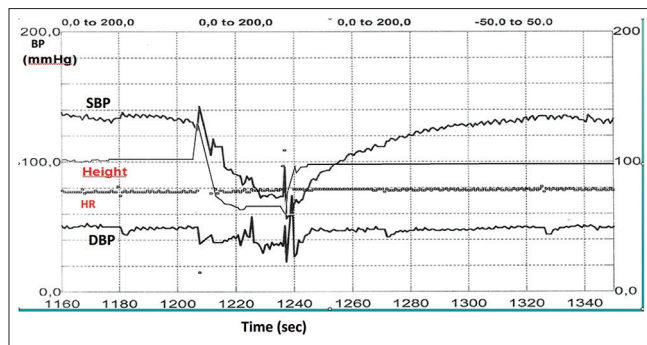


Figure 1: Tilt test registration. The figure shows the recording of systolic blood pressure, diastolic blood pressure, and heart rate in clinostatic and sitting position (passive orthostatic position not performable because of severe presyncopal symptoms) during a tilt test. In sitting position, an immediate reduction in systolic blood pressure to 55 mmHg and diastolic blood pressure to 28 mmHg is evident, without any change in the heart rate, which remains stable at 76 beats/min

by OH, gastrointestinal disease with malabsorption and dysphagia, bone femoral lytic lesions, and cardiovascular disease. In particular, an electrocardiogram showed the first-degree atrioventricular blockage and frequent supraventricular extrasystole [Figure 2a], and a cardiac ultrasound pointed out a thickness of the left ventricle wall, diffuse myocardial hyperechogenicity, and mild pericardial effusion [Figure 2b]. Finally, Bence Jones proteinuria together with small monoclonal component IgG kappa and monoclonal light chains lambda at serum protein electrophoresis were found. Bone marrow biopsy unveiled a plasma cellular infiltrate (5%–10%) and perivascular amyloid depositions. Brain involvement was excluded by lumbar puncture since amyloid was absent in cerebrospinal fluid. Unfortunately, in the presence of a pacemaker, brain MRI was not repeated. All these data allowed the diagnosis of AL amyloidosis, promptly treated with melphalan and dexamethasone. As for OH, fludrocortisone and midodrine were started but resulted ineffective. During hospitalization and even after discharge, the most invalidating symptom was severe refractory OH while the massive cardiac involvement was probably responsible for the sudden fatal outcome not long after discharge.

DISCUSSION

We describe an uncommon cause of neurogenic OH that urges to take amyloidosis into consideration in the differential diagnosis of autonomic disturbances.^[1] In fact, despite its low incidence (approximately 6–10 cases per million person-years), its consequences can be massive.^[2]

Systemic amyloidosis is characterized by the extracellular tissue deposition of insoluble fibrils as a result of protein misfolding. These tissue deposits may be responsible for progressive failure in several organs. In AL, amyloidosis mixed sensory and motor peripheral neuropathy and/or

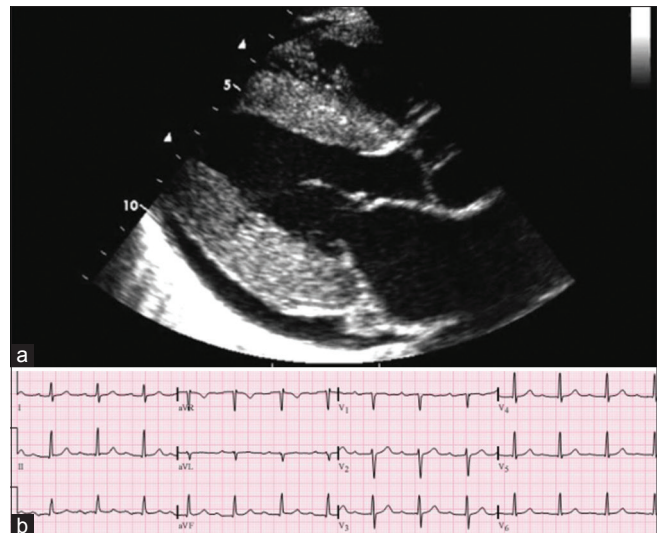


Figure 2: Electrocardiogram (a) and cardiac ultrasound, (b) The figure shows the 12-lead electrocardiogram pointing out the first-degree atrioventricular blockage (panel A). In panel B, cardiac ultrasound (parasternal long-axis view) depicts left ventricle wall thickness, diffuse myocardial hyperechogenicity, and mild pericardial effusion

autonomic neuropathy account for 20% and 15% of the cases, respectively. In fact, this process promotes nerve injury by direct compression or by accumulation of fibrils in vasa nervorum walls, leading to autonomic neuropathy and neurogenic OH.^[3,4] Autonomic dysfunction, including OH, is frequently associated with polyneuropathy at an advanced stage. On electrophysiological studies, motor conduction velocity and compound muscle action potential of either median or tibial nerves are significantly decreased in both patients with or without signs of neuropathy. In our patient, the autonomic involvement manifested with refractory OH was doubtless the most invalidating aspect, but also the only neurological symptom associated with a clear result of an instrumental investigation. In literature, a single case of pure autonomic failure without the involvement of peripheral nerves due to primary amyloidosis is described. In our case, despite the EMG was not suggestive of polyneuropathy, an involvement of the third and seventh cranial nerves cannot be excluded since neither a nerve biopsy nor a brain MRI has been performed.^[5]

Renal involvement is often present (70% occurrence), frequently as asymptomatic proteinuria or nephrotic syndrome. Restrictive cardiomyopathy is seen in 60% of cases, consequent to the thickening of the interventricular septum and ventricular wall because of light chain infiltration. Other cardiac manifestations include sudden death or syncope due to arrhythmia or heart block and rarely angina or infarction due to accumulation of amyloid in the coronary arteries.^[4] In our case, restrictive cardiomyopathy led to severe diastolic dysfunction and consequent heart failure while the recurrent syncope and junctional rhythm urged the implantation of a pacemaker.

Gastrointestinal disease is less common, being clinically evident in 1% of cases and having a histological documentation in 8%. Its manifestations include bleeding (due to vascular fragility), gastroparesis, bacterial overgrowth, malabsorption, and intestinal pseudo-obstruction resulting from dysmotility. Dysphagia and diarrhea were two important features for the final diagnosis in our patient that resulted from a gastrointestinal biopsy.

Approximately 10% of patients affected by AL amyloidosis have coexisting multiple myeloma, but in our case, bone marrow plasma cellular infiltration was only 5–10%; conversely, Bence Jones proteinuria, small monoclonal component IgG kappa, monoclonal light chains lambda, and femoral osteolytic lesions were found.

The management of AL amyloidosis varies, depending on whether the patient is eligible for high-dose melphalan, followed by autologous hematopoietic cell transplantation. In our case, the important cardiac involvement prevented us from this therapeutic choice. Alternatives are melphalan/dexamethasone combination therapy and bortezomib, the latter was avoided in our case due to its highly hypotensive effect.

AL amyloidosis median survival varies from 4 to 6 months, in presence of cardiac and hepatic failure, to 5 years in case of limited organ involvement.^[4] In the case, we describe the massive cardiac involvement was probably responsible of the sudden fatal outcome.

Financial support and sponsorship

Nil.

Conflicts of interest

There are no conflicts of interest.

AUTHORS' CONTRIBUTION

SP contributed in clinical data collection and discussion, conception of the work, revising the draft, approval of the

final version of the manuscript, and agreed for all aspects of the work.

RL contributed in clinical data collection and discussion, conception of the work, revising the draft, approval of the final version of the manuscript, and agreed for all aspects of the work.

LA contributed in clinical data collection and discussion, conception of the work, revising the draft, approval of the final version of the manuscript, and agreed for all aspects of the work.

LB contributed in clinical data discussion, conception of the work, revising the draft, approval of the final version of the manuscript, and agreed for all aspects of the work.

MR contributed in clinical data discussion, conception of the work, revising the draft, approval of the final version of the manuscript, and agreed for all aspects of the work.

AP contributed in clinical data collection and discussion, conception of the work, revising the draft, approval of the final version of the manuscript, and agreed for all aspects of the work.

SF contributed in clinical data discussion, conception of the work, revising the draft, approval of the final version of the manuscript, and agreed for all aspects of the work.

REFERENCES

1. Shibao C, Lipsitz LA, Biaggioni I. ASH position paper: Evaluation and treatment of orthostatic hypotension. *J Clin Hypertens (Greenwich)* 2013;15:147-53.
2. Kyle RA, Linos A, Beard CM, Linke RP, Gertz MA, O'Fallon WM, *et al.* Incidence and natural history of primary systemic amyloidosis in Olmsted County, Minnesota, 1950 through 1989. *Blood* 1992;79:1817-22.
3. Freeman R. Clinical practice. Neurogenic orthostatic hypotension. *N Engl J Med* 2008;358:615-24.
4. Merlini G, Seldin DC, Gertz MA. Amyloidosis: Pathogenesis and new therapeutic options. *J Clin Oncol* 2011;29:1924-33.
5. Pandit A, Gangurde S, Gupta SB. Autonomic failure in primary amyloidosis. *J Assoc Physicians India* 2008;56:995-6.