

Value of Analysis of ST Segment Changes During Tachycardia in Determining Type of Narrow QRS Complex Tachycardia

STEFANIA I. RIVA, MD, PAOLO DELLA BELLA, MD, GAETANO FASSINI, MD,
CORRADO CARBUCICCHIO, MD, CLAUDIO TONDO, MD

Milan, Italy

Objectives. Repolarization changes during narrow QRS complex tachycardia were analyzed to differentiate the tachycardia mechanism and to guide the preliminary location of the accessory pathway.

Background. Noninvasive determination of the mechanism of tachycardia is becoming increasingly important in view of the role of catheter ablation techniques for the cure of supraventricular tachycardia.

Methods. We analyzed 159 12-lead electrocardiograms during narrow QRS complex tachycardia to evaluate 1) the tachycardia cycle; and 2) ST segment depression or T wave inversion, or both. Each patient underwent a complete electrophysiologic evaluation.

Results. There were 13 atrial tachycardias, 57 atrioventricular (AV) node reentrant tachycardias and 89 AV reciprocating tachycardias. The mean RR cycle did not differ among types of tachycardia. ST segment depression >2 mm or T wave inversion,

or both, was present more often in AV reciprocating tachycardia (57%) than in AV node tachycardia (25%). The magnitude of ST segment depression was greater in AV reciprocating tachycardia than in AV node tachycardia (mean \pm SD 1.3 ± 1.6 vs. 0.7 ± 0.8 mm, $p < 0.005$). In AV reciprocating tachycardia distinct patterns of repolarization changes and P wave configuration were associated with different sites of the accessory pathway.

Conclusions. The presence of ST segment depression >2 mm or T wave inversion, or both, during narrow QRS complex tachycardia suggests that AV reentry using an accessory pathway is the mechanism of the tachycardia. The phenomenon may be the consequence of a distinct pattern of retrograde atrial activation. Analysis of repolarization changes can guide preliminary localization of the accessory pathway even in the absence of ventricular preexcitation.

(*J Am Coll Cardiol* 1996;27:1480-5)

In view of the increasing role of catheter ablation techniques for the treatment of supraventricular tachycardia (atrial tachycardia, atrioventricular [AV] node reentrant tachycardia and AV reciprocating tachycardia utilizing an accessory pathway), noninvasive determination of the tachycardia mechanism is becoming increasingly important.

In recent years, several electrocardiographic (ECG) criteria have been advanced to make this differentiation (1-8). Furthermore, various ECG criteria for preliminary location of the accessory pathway in patients with the Wolff-Parkinson-White syndrome during sinus rhythm have been reported (9-13). However, only a few studies have focused on the possible diagnostic value of the repolarization changes occurring during paroxysmal narrow QRS complex tachycardia (14-16).

In this study we analyzed repolarization changes during narrow QRS complex tachycardia to find 1) new ECG criteria useful in differentiating the tachycardia mechanism, and 2) a method for preliminary location of the accessory pathway in

the absence of ventricular preexcitation in the ECG during sinus rhythm (intermittent preexcitation, concealed accessory pathway).

Methods

We evaluated 159 12-lead ECGs recorded during paroxysmal supraventricular tachycardia at the time of an invasive electrophysiologic study; in all cases the ECG was also recorded during sinus rhythm. The inclusion criterion was the presence of a regular narrow QRS complex (<0.11 s) tachycardia with a 1:1 relation of AV activity. All episodes of atrial flutter or fibrillation were excluded from the study.

The 12-lead ECG was recorded at a paper speed of 25 mm/s, gain setting of 10 mm/mV and filter settings of 0.5 and 100 Hz. The limb and the precordial leads were recorded separately as two groups of six leads each. All six leads were recorded simultaneously for an average of 15 s and in no case for <10 s.

In each patient the mechanism of the tachycardia was determined during the electrophysiologic study by using standard techniques (17), including atrial extrastimulus testing and overdrive. The patients had a mean age \pm SD of 38 ± 13 years (range 13 to 72). Each patient underwent a noninvasive evaluation of myocardial perfusion (stress test or exercise

From the Istituto di Cardiologia dell'Università degli Studi, Centro Ricerche Cardiovascolari del Consiglio Nazionale delle Ricerche, Centro Cardiologico Fondazione Monzino, IRCCS, Milan, Italy. This study was supported in part by the National Research Council, Rome, Italy.

Manuscript received May 31, 1995; revised manuscript received December 14, 1995, accepted December 22, 1995.

Address for correspondence: Dr. Stefania Riva, Centro Cardiologico, via Parea 4, 20138 Milan, Italy.

Table 1. Analysis of Criteria for Differentiating Tachycardia Types

Criteria	AVRT (n = 89)	AVNRT (n = 57)	AT (n = 13)	p Value
Cycle (ms)	334 ± 66	355 ± 63	352 ± 58	NS
↓ ST ≥2 mm or ↓ T, or both	51 (57%)	14 (25%)	1	< 0.001
Magnitude of ↓ ST (mm)	1.3 ± 1.6	0.7 ± 0.8	NA	< 0.005
Interatrial activation time (ms)	80 ± 20	32 ± 12	NA	< 0.001

Data are expressed as number (%) of patients or mean value ± SD. AT = atrial tachycardia; AVNRT = atrioventricular node reentrant tachycardia; AVRT = atrioventricular reentrant tachycardia; NA = not available; ↓ ST = ST segment depression; ↓ T = T wave inversion.

scintigraphy, or both). Only patients without structural heart disease were included in the study.

ECG analysis criteria. Each ECG was analyzed for the following variables: 1) tachycardia cycle length (RR interval); 2) ST segment or T wave changes, or both, defined as horizontal or downsloping ST segment depression of ≥2 mm, persisting 80 ms after the J point, or inversion of a T wave that was positive in the same lead during sinus rhythm.

The duration of interatrial activation times during tachycardia was calculated as the difference (in ms) between the earliest and the latest atrial activation in the available intracavitary recording at a paper speed of 100 mm/s; this variable was obtained only when simultaneous recordings of atrial activation in the high right atrium, septum and coronary sinus were available (17,18).

All ECGs were initially analyzed by an observer who had no knowledge of the tachycardia type.

Statistical analysis. Data are expressed as mean value ± SD. When appropriate, the following tests were performed: Student unpaired t test; univariate one-way analysis of variance (ANOVA) of discrete variables, corrected for selected covariate in definite cases, by SPSS; univariate ANOVA using the Scheffé F test analysis of variance by SPSS; McNemar's chi-square test; and linear regression analysis. A p value < 0.05 was considered significant.

Results

Of the 159 narrow QRS complex tachycardias included in the study, 13 were atrial tachycardias, 57 AV node reentrant tachycardias and 89 AV reciprocating tachycardias. Of patients with the latter type of tachycardia, 55 had overt preexcitation during sinus rhythm and 34 had a concealed accessory pathway. No tachycardias of the Coumel type were included in the study.

The mean tachycardia cycle length in the study group was 343 ± 65 ms (range 220 to 650); no significant differences among the three tachycardia groups were observed (Table 1).

ST segment depression and different tachycardia mechanisms. ST segment depression ≥2 mm was present significantly more often in AV reciprocating tachycardia than in AV node reentrant or atrial tachycardia (Table 1). The magnitude of ST segment depression was greater in AV reciprocating than in AV node reentrant tachycardia (Table 1); this statisti-

cal difference was independent of the tachycardia rate but related to the duration of interatrial activation times during tachycardia. Plotting of the cycle length of tachycardia versus the degree of ST segment depression shows a different pattern for these two types of tachycardia. A weak inverse correlation exists only for AV reciprocating tachycardia (r = 0.43, p < 0.0001) and not for AV node reentrant tachycardia (r = 0.23, p = 0.06). In 37 (72%) of the 51 patients with ST segment depression >2 mm during AV reciprocating tachycardia, atrial pacing was performed at the same cycle length as that of the spontaneous tachycardia; in no case did the pacing result in ST segment changes similar to those of the spontaneous tachycardia. The magnitude of ST segment depression did not differ between patients with manifest and concealed accessory pathways (1 ± 1.4 vs. 1.7 ± 1.2 mm, p = NS). The specificity, sensitivity and positive predictive value of the aforementioned criteria are shown in Table 2.

Relation to retrograde atrial activation pattern. Interatrial activation times were longer in patients with an accessory pathway-mediated tachycardia than in those with AV node reentrant tachycardia (Table 1). This statistical difference was unaffected by location (e.g., free wall or septal) of the accessory pathway (Table 3) and was still present when interatrial activation times of AV node reentrant tachycardia were compared only with those of tachycardia due to a posteroseptal accessory pathway (32 ± 12 vs. 76 ± 14 ms, p < 0.001). The

Table 2. Sensitivity, Specificity and Positive Predictive Value of Selected Criteria for Tachycardia Types

	Sensitivity (%)	Specificity (%)	Positive Predictive Value (%)
Right P-PS AP			
↓ T (lead II, III or aVF)	63	84	67
Left lateral AP			
↓ ST (lead V ₁ to V ₆)	64	60	54
Anteroseptal AP			
ΔT (lead V ₂)	100	100	100
AVRT			
ΔST-T	57	78	77
AVNRT			
ΔST-T	24	49	53

AP = accessory pathway; P-PS = posterior or posteroseptal; ΔST-T = ST or T wave changes; ΔT = i wave changes; other abbreviations as in Table 1.

Table 3. Analysis of Electrocardiographic Criteria for Differentiating Accessory Pathway Location

Criteria	Right P-PS (n = 31)	Left P-PS (n = 13)	Left Lateral (n = 30)	Right AS (n = 6)	p Value
↓ ST (lead V ₃ to V ₆)	15	5	25	1	< 0.001
↓ T (lead II, III, aVF)	19	5	2	2	< 0.001
ΔT (lead V ₂)	0	0	0	6	< 0.001
interatrial activation time (ms)	74 ± 14	80 ± 14	82 ± 25	90	NS

Data are expressed as number of patients or mean value ± SD. AS = anteroseptal; other abbreviations as in Table 2.

duration of atrial activation was longer in tachycardias associated with ST segment depression >2 mm than in those without this association (67 ± 28 vs. 50 ± 28 ms, $p < 0.005$).

Repolarization changes and accessory pathway location. In the group with AV reciprocating tachycardia, ST segment depression in leads V₃ to V₆ was observed more frequently in patients with a left lateral accessory pathway; the presence of a negative T wave in leads II, III, aVF was indicative of a right posterior or posteroseptal accessory pathway; a negative or notched T wave in lead V₂ was specific for an anteroseptal accessory pathway (Table 3). No significant differences in the pattern of repolarization changes were observed between right posteroseptal and left posteroseptal accessory pathways. The specificity, sensitivity and positive predictive value of these criteria are listed in Table 2.

Discussion

Currently used criteria to differentiate AV reciprocating tachycardia from AV node reentrant tachycardia include analysis of the P-QRS relation, distinct patterns of the P wave (pseudo S wave in inferior leads and pseudo incomplete right bundle block in lead V₁ in AV node reentrant tachycardia) and the presence of QRS alternans (1-8).

The data of this study show that analysis of the repolariza-

tion changes occurring during narrow QRS complex tachycardia is a useful adjunct for determining the type of supraventricular tachycardia. Furthermore, in patients with AV reciprocating tachycardia, preliminary location of the accessory pathway can be achieved with good sensitivity and specificity even in the absence of ventricular preexcitation during sinus rhythm.

Tachycardia mechanism. Analysis of repolarization changes during narrow QRS complex tachycardia has been previously undertaken to rule out the presence of underlying coronary artery disease. Kim et al. (15) concluded from their study that ST segment depression >1 mm is a physiologic response, unrelated to myocardial ischemia but related to tachycardia rate, providing no independent diagnostic information regarding its mechanism.

Our data support the view that ST segment depression >2 mm or T wave inversion in one or more leads indicates AV reentry through an accessory pathway as the tachycardia mechanism (Fig. 1). The extent of ST segment depression is greater in AV reciprocating tachycardia than in AV node reentrant tachycardia, and the difference is still significant after correcting for heart rate. Thus, the predictive value of ST segment depression appears to be independent of the tachycardia rate. In fact, in our patients who underwent atrial pacing (72%), stimulation at the tachycardia cycle length did not

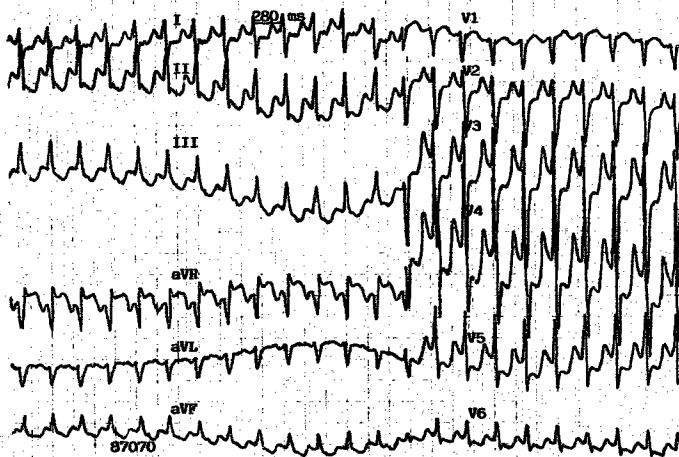
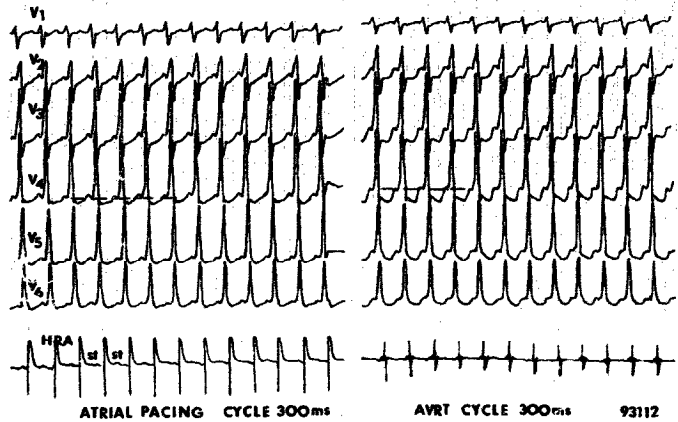


Figure 1. Twelve-lead electrocardiogram recorded during atrioventricular reentrant tachycardia in a patient with a left lateral accessory pathway. Downsloping ST segment depression (6 mm) can be appreciated in leads V₂ to V₆.

Figure 2. Simultaneous recording of six surface electrocardiographic leads and an intracavitary atrial electrogram in a patient with a left lateral accessory pathway, during (left) atrial pacing and (right) spontaneous atrioventricular reciprocating tachycardia (AVRT) at the same cycle length (300 ms). ST segment depression is significant (>2 mm) only during tachycardia. Paper speed = 25 mm/s. HRA = high right atrium; st = stimulus.



result in significant ST segment depression (Fig. 2). In our study, linear regression analysis of the cycle length of the tachycardia versus the degree of ST depression showed a weak correlation only for AV reciprocating tachycardia and not for AV node reentrant tachycardia (Fig. 3). This disagreement with the observations of Kim et al. (15) may be explained by the different cutoff value (>2 mm) we used for ST segment depression, thus indicating that only marked ST segment depression is of diagnostic value.

Mechanism of ST segment depression during tachycardia. Depression of the ST segment during AV reciprocating tachycardia in our patients was not related to the presence of ventricular preexcitation during sinus rhythm. This finding rules out the possibility of a "memory" effect, which is known to be responsible for transient repolarization changes during narrow QRS conduction in patients with intermittent ventricular preexcitation or after catheter ablation of the accessory pathway (19,20).

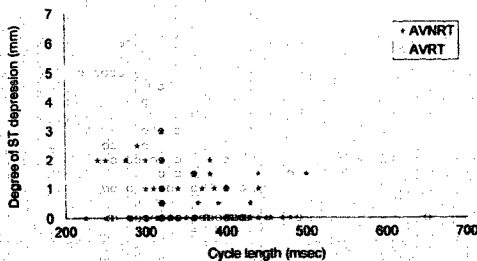
To investigate the origin of the repolarization changes

observed during tachycardia, we compared the patterns and duration of retrograde atrial activation during AV reciprocating and AV node reentrant tachycardia. The time difference of the earliest and the latest atrial activation measured at three atrial sites (high right atrium, septum and coronary sinus) was taken as an estimate of the total atrial activation time (17,18).

The location of the accessory pathway did not influence the duration of retrograde atrial activation (as demonstrated by the similar values found in patients with a free wall or septal accessory pathway). More specifically, the duration of retrograde activation was significantly longer in tachycardias due to a septally located accessory pathway than in AV node reentrant tachycardia. In the latter type of tachycardia, atrial retrograde activation starts in the middle of the heart (where the AV node is located), although in septally located accessory pathways in the AV ring. Furthermore, in AV node reentrant tachycardia it is likely that retrograde activation occurs from the AV node to the atria through the same functionally "preferential" conduction pathways that convey anterograde inputs to the AV node during sinus rhythm (17,21); hence, the typical intracavitary pattern of retrograde activation occurring almost simultaneously in the septum and right and left atria during AV node reentrant tachycardia and the narrow retrograde P wave observed during AV node tachycardia with 21:1 AV block (22). In contrast, during AV reciprocating tachycardia, retrograde activation of the atria occurs eccentrically from the accessory pathway insertion site and may be completed over a longer time because of the lower speed of combined longitudinal and transverse muscle fiber activation (23).

Correction of the extent of ST segment depression for the duration of interatrial activation suggests that the phenomena were related. We hypothesized that the frequently observed pattern of ST segment depression occurring during AV reciprocating tachycardia is due to the combination of a longer ventriculoatrial interval (than that in AV node reentrant

Figure 3. Plot of cycle length of tachycardia versus degree of ST segment depression in atrioventricular node reentrant tachycardia (AVNRT) and atrioventricular reciprocating tachycardia (AVRT). See text for explanation.



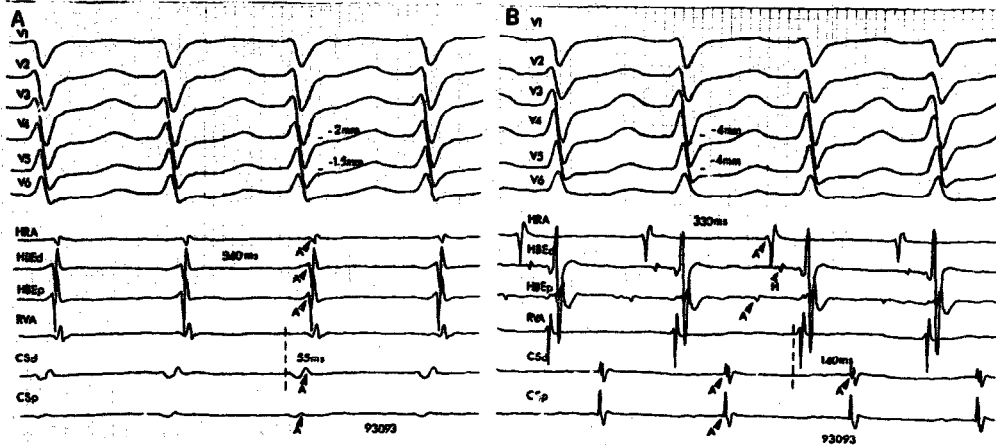


Figure 4. Simultaneous recording of six standard surface electrocardiographic leads and multiple intracavitary electrograms from the same patient during atrioventricular (AV) node reentrant tachycardia (A) and AV reentrant tachycardia with earliest retrograde atrial activation in the distal coronary sinus electrode (B). Both tachycardias occurred at the same cycle length (340 and 330 ms, respectively). ST segment depression in leads V_3 to V_6 is more marked during AV reciprocating tachycardia (-4 mm) than during AV node reentrant tachycardia. Interatrial activation times are significantly different (55 vs. 140 ms) in the two tachycardia types. Paper speed = 100 mm/s. A = atrial deflection; CS = coronary sinus; d and p = distal and proximal, respectively, electrode pairs of the catheter; H = His bundle deflection; HBF = His bundle electrogram; HRA = high right atrium; RVA = right ventricular apex.

tachycardia) and a retrograde P wave of longer duration that overlaps to the ST segment. The more frequent occurrence of ST segment depression or marked T wave inversion in AV reciprocating than in AV node reentrant tachycardia is therefore unrelated to the different reentrant circuit of the two tachycardia types; instead, it may be the consequence of a different pattern of retrograde atrial activation (Fig. 4). This hypothesis is further strengthened by our finding (discussed next) that ST segment depression is more marked in the leads where, according to accessory pathway location, a negative P wave could be expected.

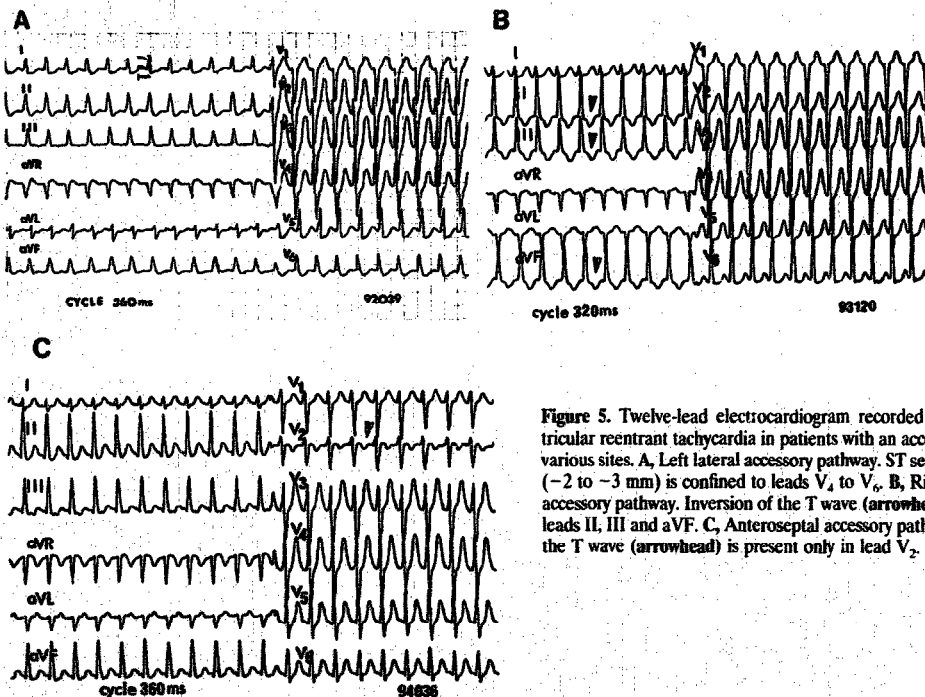


Figure 5. Twelve-lead electrocardiogram recorded during atrioventricular reentrant tachycardia in patients with an accessory pathway at various sites. A, Left lateral accessory pathway. ST segment depression (-2 to -3 mm) is confined to leads V_4 to V_6 . B, Right posteroseptal accessory pathway. Inversion of the T wave (arrowheads) is present in leads II, III and aVF. C, Anteroseptal accessory pathway. Inversion of the T wave (arrowhead) is present only in lead V_2 .

Preliminary localization of accessory pathway. Several patterns of repolarization changes were shown to be associated with a specific accessory pathway location: ST segment depression from lead V_3 to V_6 was almost invariably present in patients with a left lateral accessory pathway; ST segment depression and negative T wave in the inferior leads were frequent in patients with posteroseptal or posterior accessory pathway; a negative or peculiarly notched T wave was recorded only in orthodromic tachycardia in patients with an anteroseptal accessory pathway (Fig. 5). An additional ECG feature of orthodromic reciprocating tachycardia due to an anteroseptal accessory pathway is, according to Scheinman et al. (24), a positive retrograde P wave in at least two inferior leads. This finding may be explained by the superior position of the accessory pathway causing a craniocaudal pattern of retrograde atrial activation during orthodromic reciprocating tachycardia. We also observed this feature in our patients (Fig. 5C).

Analysis of repolarization changes during tachycardia is not useful in differentiating right from left posteroseptal accessory pathways, and by no means can our criteria define a precise location of the accessory pathway. However, analysis of these repolarization changes may be useful in preliminary localization of an accessory pathway, even when ventricular preexcitation is intermittent or a concealed accessory pathway is present. A prospective study is required to indicate the true value of these observations.

References

1. Wu D, Denes P, Amat-y-Leon F, et al. Clinical, electrocardiographic and electrophysiologic observation in patients with paroxysmal supraventricular tachycardia. *Am J Cardiol* 1978;41:1045-51.
2. Josephson ME. Paroxysmal supraventricular tachycardia: an electrophysiologic approach. *Am J Cardiol* 1978;41:1123-6.
3. Wellens HJJ, Durrer D. The role of an accessory atrioventricular pathway in reciprocal tachycardia. *Circulation* 1975;52:58-72.
4. Bär FW, Brugada P, Dassen WRM, Wellens HJJ. Differential diagnosis of tachycardia with narrow QRS complex (shorter than 0.12 second). *Am J Cardiol* 1984;54:555-60.
5. Kay GN, Pressley JC, Packer DL, Pritchett ELC, German LD, Gilbert MR. Value of the 12-lead electrocardiogram in discriminating atrioventricular nodal reciprocating tachycardia from circus movement atrioventricular tachycardia utilizing a retrograde accessory pathway. *Am J Cardiol* 1987;59:296-300.
6. Kalbfleisch SJ, El-Atassi R, Calkins H, Langberg JJ, Morady F. Differenti-

- ation of paroxysmal narrow QRS complex tachycardias using the 12-lead electrocardiogram. *J Am Coll Cardiol* 1993;21:85-9.
7. Morady F, DiCarlo L, Baerman JM, deBuitelir M, Kou WH. Determinants of QRS alternans during narrow QRS tachycardia. *J Am Coll Cardiol* 1987;9:489-99.
8. Green M, Heddle B, Dassen W, et al. Value of QRS alternation in determining the site of origin of narrow QRS supraventricular tachycardia. *Circulati* n 1983;68:368-73.
9. Gallagher JJ, Pritchett ELC, Sealy WC, Kasell J, Wallace AG. The pre-excitation syndromes. *Prog Cardiovasc Dis* 1978;20:285-327.
10. Milstein S, Sharma AD, Guiraudon GM, Klein GJ. An algorithm for the electrocardiographic localization of accessory pathways in the Wolff-Parkinson-White syndrome. *PACF* 1987;10:555-63.
11. Lindsay BD, Crossen KJ, Cain ME. Concordance in distinguishing electrocardiographic features during sinus rhythm with the location of accessory pathways in the Wolff-Parkinson-White syndrome. *Am J Cardiol* 1987;59:1093-102.
12. Cain ME, Luke RA, Lindsay BD. Diagnosis and localization of accessory pathways. *PACE* 1992;15:801-24.
13. Rodriguez LM, Smeets JLMR, de Chillou C, Metzger J, et al. The 12-lead electrocardiogram in midseptal, anteroseptal, posteroseptal and right free wall accessory pathways. *Am J Cardiol* 1993;72:1274-80.
14. Petsas AA, Anastassiades C, Antonopoulos AG. Exercise testing for assessment of the significance of ST segment depression observed during episodes of paroxysmal supraventricular tachycardia. *Eur Heart J* 1990;11:974-9.
15. Kim YN, Sousa J, El-Atassi R, Calkins H, Langberg JJ, Morady F. Magnitude of ST segment depression during paroxysmal supraventricular tachycardia. *Am Heart J* 1991;122:1486-7.
16. Nelson SD, Kou WH, Annesley T, De Buitelir M, Morady F. Significance of ST segment depression during paroxysmal supraventricular tachycardia. *J Am Coll Cardiol* 1988;12:383-7.
17. Josephson ME. *Clinical Cardiac Electrophysiology: Techniques and Interpretation*. Philadelphia: Lea & Febiger, 1993:5-70.
18. Josephson ME, Scharf DL, Kastor JA, Kitchen JG III. Atrial endocardial activation in man. Electrode catheter technique for endocardial mapping. *Am J Cardiol* 1977;39:972-81.
19. Poole JE, Bardy GH. Further evidence supporting the concept of the T-wave memory: observation in patients having undergone high-energy direct current catheter ablation of the Wolff-Parkinson-White syndrome. *Eur Heart J* 1992;13:213-22.
20. Nicolai P, Medvedawsky JL, Delaage M, Barnay C, Blache E, Pisapia A. Wolff-Parkinson-White syndrome: T wave abnormalities during normal pathway conduction. *J Electrocardiol* 1981;14:295-300.
21. Sherf L. The atrial conduction system: clinical implication. *Am J Cardiol* 1976;37:814-7.
22. Vanagt EJ, Wellens HJJ. The electrocardiogram in digitalis intoxication. In: Wellens HJJ, Kulbertus HE, editors. *What's New in Electrocardiography?* The Hague: Martinus Nijhoff, 1981:315-7.
23. Spach M, Josephson ME. The role of nonuniform anisotropy in small circuits. *J Cardiovasc Electrophysiol* 1994;5:182-209.
24. Scheinman MM, Wang YS, Van Hare GF, Lesh MD. Electrocardiographic and electrophysiologic characteristics of anterior, midseptal and right anterior free wall accessory pathways. *J Am Coll Cardiol* 1992;20:1220-9.