

# Diagnosis of symptomatic uncomplicated diverticular disease and the role of Rifaximin in management

*Giovanni Maconi*

Gastroenterology Unit, Department of Biomedical and Clinical Sciences, L. Sacco University Hospital, Milan, Italy

**Summary.** Patients with diverticulosis who develop persistent abdominal pain, bloating and changes in bowel habits not associated with overt inflammation may have symptomatic uncomplicated diverticular disease (SUDD). The severity and frequency of SUDD symptoms may have an impact on daily activities and severely affect quality of life. Effective management of SUDD should follow a three part strategy: divert, tackle and maintain. Divert to make the correct diagnosis: several symptoms of SUDD are common to other conditions that require different therapeutic approaches. However, several key differences should be used to diagnose SUDD. Pain in SUDD is normally in the iliac fossa, persistent, often lasting more than 24 hrs, and is not relieved by bowel movement, as is often the case with irritable bowel syndrome. Another difference is in the timing: the prevalence of SUDD increases with age, and patients under the age of 40 years are less likely to have diverticula. It is useful to establish whether a patient has diverticulosis, especially if the patient is relatively young; lack of diverticula excludes SUDD. Cross-sectional imaging is indicated; however, recent archival image data or ultrasonography may be useful alternatives. Laboratory tests should be ordered to exclude overt inflammation. Once the diagnosis of SUDD is made, the patient should receive effective therapy to tackle the condition. This should include dietary fibre supplementation and cyclic treatment with rifaximin 400 mg twice daily for 7 days per month. Once symptom control is achieved, it should be maintained by continuing therapy for at least 12 months. ([www.actabiomedica.it](http://www.actabiomedica.it))

**Key words:** symptomatic uncomplicated diverticular disease (SUDD), rifaximin, management of SUDD

## *Terminology*

**Diverticulosis:** the presence of diverticula

**Diverticular disease:** any symptomatic condition involving diverticula

**Diverticulitis:** diverticular macro inflammation with local pain symptoms

**Complicated diverticulitis:** abscesses, fistulae, obstructions or perforations

**Symptomatic uncomplicated diverticular disease:** diverticula with persistent localised pain and diarrhoea/constipation, without macroscopic inflammation.

## **Introduction**

Diagnosing the cause of abdominal pain can be challenging (1), especially due to the large number of conditions presenting with this symptom (2). Clinicians should be vigilant to the possibility of colorectal cancer in patients with this clinical scenario, due to its increasing incidence even among younger patients (3, 4). Abdominal pain can result from functional- or structural gastrointestinal (GI) disorders. Functional GI disorders include idiopathic bowel disorders thought to involve visceral hypersensitivity, visceral nociceptors and/or impaired gastrointestinal motility: Irritable bowel syndrome is the major entity in this group (5). In contrast,

structural GI disorders have an established physical cause such as an infection, neoplastic disease, autoimmune reaction or inflammation; they include various forms of colitis (e.g., infectious or ulcerative colitis, Crohn's disease) and diverticular diseases.

Diverticular disease (DD) is prevalent in western and industrialized societies, and appears to be associated with the low fibre content in the diet (6, 7). DD accounts for substantial part of burden of digestive diseases (8-11).

Diverticula are outpouchings of intestinal colonic mucosal and submucosal layers that protrude through weak points in the colon wall, typically at the points where the vasa rectae traverse. The incidence of this condition, known as diverticulosis, is high, increases with age, and in the great majority of cases remains asymptomatic (12). However, approximately 20% of patients will develop symptoms and complications (13). The term *diverticular disease* (DD) refers to any condition in which the presence of diverticula is associated with symptoms. Infection/macrosopic inflammation associated with a diverticulum occurs in approximately 15% of symptomatic patients and may progress to extra-colonic infection/inflammation (diverticulitis). Diverticulitis is usually associated with abdominal pain, fever, tachycardia, and elevated markers for inflammation. Diverticulitis can lead to the formation of abscesses, fistulae, obstructions, perforations, or peritonitis, at which point it is known as complicated diverticulitis (12). However, < 50% of patients with acute diverticulitis, also those complicated with

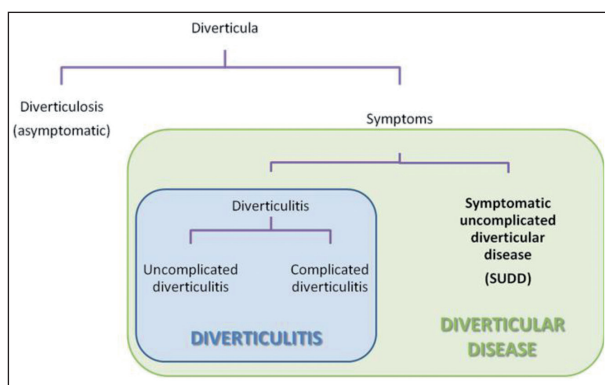
abscesses at CT scan, have the classical clinical triad of abdominal pain, fever and leucocytosis (14).

Patients with diverticulosis who develop a constellation of persistent abdominal symptoms that include pain and changes in bowel habits that are not, however, associated with macroscopic inflammation or elevated systemic markers of inflammation, may have a condition known as symptomatic uncomplicated diverticular disease (SUDD). The diagnosis of symptoms of SUDD is complicated by the fact that several of its symptoms are common to other conditions that respond to different therapeutic approaches. Therefore, correct diagnosis is critical to the management of SUDD (15).

## SUDD

SUDD is defined as the concomitant presence of diverticula and symptoms of abdominal pain and bloating, bowel habit changes that include diarrhoea and constipation or a mixed bowel habit, in the absence of macroscopic inflammation (16, 17). The severity and frequency of symptoms may have an impact on daily activities and severely affect quality of life (18); which can be assessed with the DD-specific DV-QoL survey (19).

Whereas the exact aetiology is not certain, a number of aspects of this condition have been investigated. Horgan et al. reported on a series of patients undergoing surgery for SUDD (n = 930), in which three-quarter of biopsies from patient who underwent resections showed signs of low-grade peridiverticular inflammation (20). It is suggested that chronic low-grade inflammation may provoke visceral hypersensitivity and changes in colonic motility. Patients with SUDD have a heightened sensitivity of isobaric distension (visceral hypersensitivity) compared to asymptomatic patients (21). Humes et al. assessed visceral sensitivity in patients with diverticular disease, reporting higher median mRNA levels of the neurokinin 1 receptor and TNF alpha in a group of 12 patients with symptomatic diverticular disease, compared to a group of 13 asymptomatic patients. There was a significant correlation between barostat pain scores and neurokinin 1 receptor expression (22). Simpson et al., sought to explain



**Figure 1.** Classification of diverticular disease and frequency of the various forms

the visceral hypersensitivity observed in patients with SUDD by assessing expression of neuropeptides in peridiverticular biopsies from 17 symptomatic and 15 asymptomatic patients (23). Although histology was normal in both groups, there was significantly higher expression of the neuropeptides substance P, neuropeptide K, pituitary adenylate cyclase activating polypeptide, vasoactive intestinal polypeptide and galanin in the symptomatic group. Changes in neuromuscular function may influence colonic motility, causing changes in bowel habits, and may also influence perception of abdominal pain (24). Bassotti et al. reported that patients with SUDD have abnormal motor activity and peristaltic action in the colon segments with diverticulosis, including a longer duration of rhythmic, low frequency contractile activity (25).

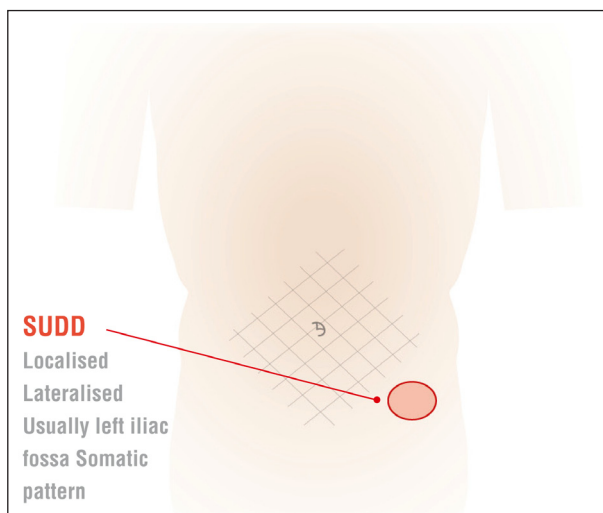
Another putative mechanism in SUDD is the effect on gut microbiota leading to chronic inflammation (26). The microbiota of patients with DD have reduced levels of bacterial with anti-inflammatory properties (e.g., *Clostridium* clusters IV and IX, *Fusobacterium*, and the *Lactobacillaceae*); these changes in microbiota are associated with mucosal immune activation (26).

Such modifications in intestinal microbiota could result from faecal stasis due to the colonic dysmotility. The overgrowth of intestinal bacteria and chronic dysbiosis could promote inflammation through the production of abnormal bacterial metabolites. A role for dysbiosis is also suggested by the efficacy of cyclic antibiotic treatment in controlling symptoms (27-31).

## Diagnosing SUDD

Diagnosing this condition is complicated by the fact that the symptoms may be difficult to distinguish from those of functional GI disorders such as irritable bowel syndrome (IBS) (17, 32) thus several key differences should be used to differentiate between these conditions.

First, the pain associated with SUDD is normally located in the iliac fossa (Figure 2), is more sustained, likely long-lasting or associated with history of pain lasting more than 24 hrs, and is not relieved by bowel movement, as is often the case with IBS (17, 33) (Table 1).



**Figure 2.** Most frequent location of abdominal pain associated with SUDD

**Table 1.** Important pain characteristics differentiating SUDD from IBS. (modified from 17)

Pain characteristics	SUDD	IBS
Diffuse/generalized	no	yes
Localised in left iliac fossa	yes	no
Relieved by passing stool or flatulence	no	yes
Wakes the patient at night	yes	no

The prevalence of SUDD increases with age (11), so that patients under the age of 40 years are less likely to have diverticula. Moreover, SUDD may follow a bout of acute diverticulitis (34).

## Imaging

Next, it is useful to establish whether the patient has diverticulosis, especially if the patient is relatively young. The lack of diverticula would exclude SUDD. Gold standard methods include Computed Tomographic Colonography (CTC) or Colonoscopy (35). Although colonoscopy is the most widely used imaging technique for assessing the colon, its accuracy in detecting colonic diverticula, in particular those located in the sigmoid colon, is not superior to that of barium enema and CT colonography (35), so that a

definite gold standard does not exist. The choice between these methods is therefore based on patient age, risk factors for polyps or cancer, clinical status, patient preference and local availability of the techniques (16). However, it is not practical to perform or repeat these examinations on all patients presenting with abdominal symptoms. Instead, we suggest that reference be made, where possible, to recent archival imaging data. When this is not available, recourse to ultrasonography is a useful alternative (36). Advantages of ultrasonography include that it is less invasive, has a lower cost and may be more readily available and repeatable than conventional colonoscopy and colonography. It also avoids unnecessary exposure to ionising radiation, which is increasing important as the age of incidence for diverticular disease is decreasing (37) and real time examination allows to directly assess the exact site of pain of patients correlating this with the presence of underlying diverticula. So far, the accuracy of US in detecting left-sided diverticulosis has been assessed in only one prospective study that enrolled 60 patients and used colonoscopy as reference standard, showing a sensitivity of 85% with only 2 false positive results (38).

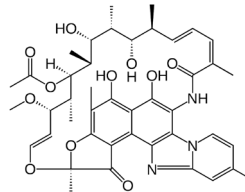
### Biochemical markers

CRP is a general marker of inflammation that is useful for distinguishing patients with diverticulitis, or other overtly inflammatory condition. It is not specific for diverticular disease. Faecal calprotectin is a surrogate marker for intestinal inflammation. Calprotectin is a protein produced by neutrophils. Elevated levels in the faeces are indicative of inflammation of the intestinal mucosa, including inflammation caused by IBD or bacterial infections. It is a relatively nonspecific test that can be positive not only for inflammatory bowel diseases, but also coeliac disease, infectious colitis, necrotizing enterocolitis, intestinal cystic fibrosis and colorectal cancer. Whereas, non-inflammatory conditions like FAPS and IBS are negative. Reference ranges have been established, with cut-offs indicative of various conditions. The test can be used to measure disease activity status and response to therapy in IBD (39). It can inform differential diagnosis, as levels are

only mildly elevated in patients with SUDD, but not in patients with IBS (40). Also in SUDD, levels correlate with symptom severity (41).

### Treatment with Rifaximin

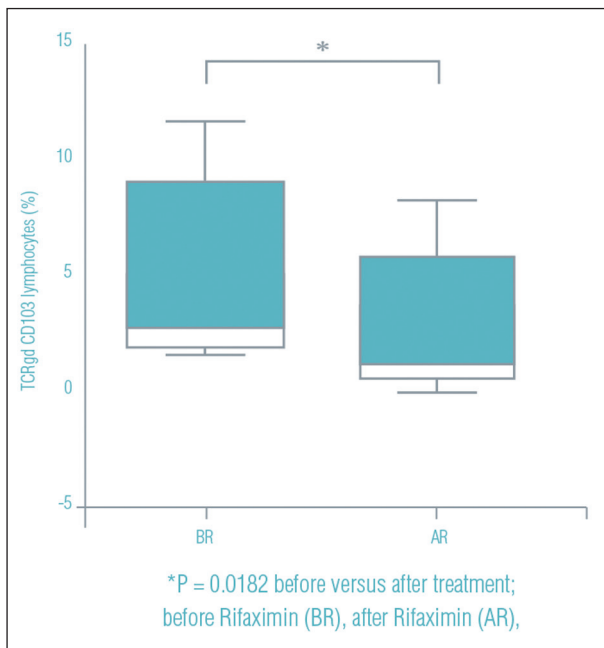
#### *Introduction of Rifaximin*



#### *Background on pharmacology and mechanism*

Rifaximin is a hydrophobic rifampicin derivative with negligible GI absorption. This property avoids systemic side effects and at the same time provides high faecal antibiotic concentrations (42). It inhibits gene transcription in both gram positive and gram negative bacterial by binding to the  $\beta$ -subunit of bacterial DNA-dependent RNA polymerase. Cyclic administration of rifaximin combined with soluble fibre supplementation, is useful for treating SUDD. Cyclic treatment with rifaximin consists of administering 400 mg twice daily for 7 days per month for at least 12 months which alleviates symptoms, reduces the risk of recurrence or complications, and improves quality of life. (27-31, 43)

SUDD associated with dysbiosis and reduced level of beneficial bacteria (26). Rifaximin has a eubiotic effect on the intestinal microbiota (44) that may be accomplished through modulation of both the composition of gut microbiota and bacterial metabolism (45). Ponziani et al. conducted a molecular survey of intestinal bacteria before and after 10 days of rifaximin administration in 20 patients with a variety of conditions. The main finding was the increase in beneficial Lactobacilli (45). Meanwhile, in a study of 15 patients with IBS not accompanied by constipation, rifaximin increased the presence of beneficial *Faecalibacterium prausnitzii* after 2 weeks of treatment (46). To date, the effect of rifaximin on the gut microbiota has not been assessed in large studies.



**Figure 3.** Rifaximin reduced mucosal CD103+ gamma-delta T cells, supporting the anti-inflammatory activity of rifaximin (figure from 48 modified)

Another potential mechanism is through anti-inflammatory effects in the gut mucosa (47). Rifaximin treatment is associated with a reduction in innate immune effector cells in the colonic mucosa (Figure 3)

Moreover, bacteria are known to induce inflammation by interacting with toll-like receptors that influence innate immunity and T-cell recruitment. Cianci et al. randomly assigned 40 consecutive asymptomatic patients with uncomplicated DD to receive either rifaximin or placebo. Expression of Toll-like receptors 2 and 4, and intestinal homing of innate immune cells were assessed in colonic mucosal biopsies at baseline and after 2 months of treatment. Rifaximin treatment normalised the distribution or toll-like receptor expression that is altered in patients with diverticular disease (47).

Putative additional mechanisms that may explain the observed clinical activity of rifaximin include decreasing bacterial adherence to epithelial cells, inhibiting their translocation across the GI epithelium, as well as activating the pregnane X receptor and thereby reducing levels of the proinflammatory transcription factor nuclear factor  $\kappa$ B.

Thus, rifaximin may work directly on gut bacteria and indirectly through host factors that may modify bacterial interactions with the intestinal mucosa and reduce inflammation (44).

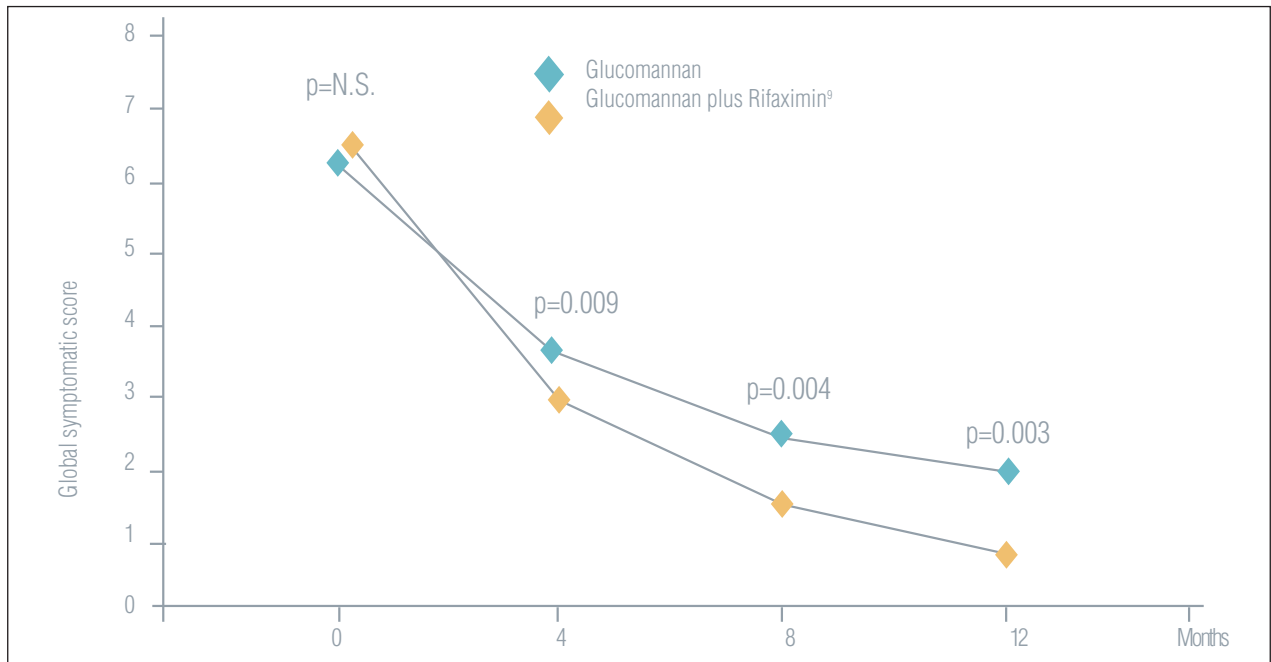
### *Efficacy*

Five randomized controlled studies have compared rifaximin with placebo or fibre supplementation (27-31). A meta-analysis of these trials (n = 1660) revealed a 29.0% improvement in complete symptom resolution with rifaximin (Rifaximin vs. control; 95% CI 24.5-33.6;  $P < 0.0001$ ) (49), corresponding to a number needed to treat of 3 patients, in order to see a benefit in terms of complete resolution of symptoms.

The largest trial was a prospective 12-month study in 968 patients with SUDD randomized to receive fibre supplementation (glucomannan 4 g/day) alone (n=346) or glucomannan plus daily rifaximin 400 mg/day for 7 days every month (n=558) (29). The primary outcome was symptomatic relief at 12 months, evaluated by symptom frequency and a global symptom score comprising upper and lower abdominal pain, bloating, tenesmus, diarrhoea, and abdominal tenderness. The secondary outcome was the incidence of complications, defined as development of diverticulitis or rectal bleeding. Adding rifaximin resulted in fewer individual symptoms and a lower global symptom score (Figure 4). After 12 months, 56.5% of patients receiving glucomannan plus rifaximin were asymptomatic, compared to 29.2% with glucomannan alone ( $P < 0.001$ ). Incidence of AD or rectal bleeding was lower in the group receiving rifaximin (1.34% with rifaximin plus glucomannan vs. 3.22% with glucomannan alone ( $P < 0.05$ )).

### *Tolerability of cyclic administration in patients with SUDD*

Several long term studies have provided evidence that rifaximin is well tolerated, with adverse events with cyclic administration not significantly different from those in the control groups (49-51). Lanas et al. have reported potentially treatment-related adverse events during a 48-week study of 165 patients with recent diverticulitis randomized to receive 3.5 g of fibre



G+R (mean+SD)	6.7 ± 0.9	3.1 ± 1.0	1.5 ± 1.2	1.0 ± 0.9
G (mean+SD)	6.4 ± 0.8	3.6 ± 1.1	2.4 ± 1.2	2.0 ± 1.1

**Figure 4.** Global symptomatic score is the sum of scores for six clinical variables: upper abdominal pain/discomfort, lower abdominal pain/discomfort, bloating, tenesmus, diarrhea, and abdominal tenderness, graded from 0 (no symptoms) to 3 (severe, incapacitating) (image adapted from 29)

**Table 2.**

	Controls (n = 88)	Treated (n = 77)
Patients with events*	6	8
Articular pain/discomfort	3	2
Increased hypercholesterolemia	2	0
Increased weight	1	1
Increased uricaemia	1	0
Increased glycemia	1	0
Cold/pulmonary phlegm	1	1
Itching	0	2
Anxiety	0	2
Diarrhoea at each administration	0	1
Increased triglycerides	0	1
Epididymitis	0	1

\* Patients could report more than one event. (Adapted from 50)

supplementation, with/without one week per month of rifaximin 400 mg twice daily (50).

Stallinger et al. conducted a non-interventional study of 1,054 adult patients with Sudd treated as

outpatients with cyclic administration of rifaximin (51). Clinical visits were held at baseline and monthly thereafter for three months. During the study, 24 adverse events were reported by 20 patients; six of these were related to the use of rifaximin, corresponding to an adverse event rate of 0.6%. Five events were GI adverse events (flatulence/1 patient; abdominal pain/1 patient; nausea/3 patients) and 1 was a skin rash. One reason for the low frequency of adverse events is that the alpha polymorphic form of rifaximin has negligible gut absorption and systemic availability (52).

## Conclusions

Sudd is a multifactorial condition for which the correct diagnosis, although often difficult to obtain, provides the highest probability of successful management. To achieve this, we suggest combining a careful assessment of the pain characteristics, with cross-sectional

imaging to ascertain diverticulosis status and laboratory tests to exclude overt inflammation. The presence of a moderate level of faecal calprotectin may help to distinguish SUDD from non-inflammatory conditions such as IBS, which are completely negative, and inflammatory conditions such as Crohn's disease, ulcerative colitis, and diverticulitis, which are clearly positive.

Once correctly diagnosed, it is important to address the condition with effective therapy. Fibre supplementation plus cyclic treatment with rifaximin is well-tolerated in patients with SUDD and effective at controlling symptoms. Once symptom control has been achieved, it is important to consolidate and maintain these advances through cyclic administration of daily rifaximin for one week each month.

On the basis of this we can conclude that the best approach for managing SUDD involves three basic steps: - **Divert**, that means approaching patients with abdominal pain in a different way, to make the correct diagnosis of SUDD; - **Tackle** the condition by providing the appropriate treatment, able to improve symptoms by acting on causes, and - **Maintain**, engaging patients to let them understand the importance of cyclic treatment, to insure long-term recovery.

## References

1. Locke GR 3rd, Zinsmeister AR, Fett SL, Melton LJ 3rd, Talley NJ. Overlap of gastrointestinal symptom complexes in a US community. *Neurogastroenterol Motil* 2005; 17: 29-34.
2. Penner RM, Fishman MB, Sumit R, Majumdar SR. Causes of abdominal pain in adults. Available at: <http://www.uptodate.com/contents/causes-of-abdominal-pain-in-adults>.
3. European Colorectal Cancer Screening Guidelines Working Group. European guidelines for quality assurance in colorectal cancer screening and diagnosis: Overview and introduction to the full Supplement publication. *Endoscopy* 2013; 45: 51-59.
4. Bailey CE, Hu CY, You YN, et al. Increasing disparities in the age-related incidences of colon and rectal cancers in the United States, 1975-2010. *JAMA Surg* 2015; 150: 17-22.
5. Kovacic K. Current concepts in functional gastrointestinal disorders. *Curr Opin Pediatr* 2015; 27: 619-24.
6. Hobson KG, Roberts PL. Etiology and pathophysiology of diverticular disease. *Clin Colon Rectal Surg* 2004; 17: 147-53.
7. Martel J, Raskin JB; NDSG. History, incidence, and epidemiology of diverticulosis. *J Clin Gastroenterol* 2008; 42: 1125-7.
8. Sandler RS, Everhart JE, Donowitz M, et al. The burden of selected digestive diseases in the United States. *Gastroenterology* 2002; 122: 1500-11
9. Delvaux M. Diverticular disease of the colon in Europe: epidemiology, impact on citizen health and prevention. *Aliment Pharmacol Ther* 2003; 18 Suppl 3: 71-4.
10. Shaheen NJ, Hansen RA, Morgan DR, et al. The burden of gastrointestinal and liver diseases, 2006. *Am J Gastroenterol* 2006; 101: 2128-38.
11. Everhart JE, Ruhl CE. Burden of digestive diseases in the United States part II: lower gastrointestinal diseases. *Gastroenterology* 2009; 136: 741-54.
12. Janes SE, Meagher A, Frizelle FA. Management of diverticulitis. *BMJ* 2006; 332: 271-5.
13. Almy TP, Howell DA. Diverticular disease of the colon. *N Engl J Med* 1980; 302: 324-31.
14. Longstreth GF, Iyer RL, Chu LH, Chen W, Yen LS, Hodgkins P, Kawatkar AA. Acute diverticulitis: demographic, clinical and laboratory features associated with computed tomography findings in 741 patients. *Aliment Pharmacol Ther*. 2012 ;36: 886-94.
15. Tursi A. Diverticular disease of the colon and irritable bowel syndrome: it is time to differentiate. *Am J Gastroenterol* 2015; 110: 774-5.
16. Cuomo R, Barbara G, Pace F, et al. Italian consensus conference for colonic diverticulosis and diverticular disease. *United European Gastroenterol J* 2014; 2: 413-42.
17. Spiller R. Diverticular Disease and IBS: Overlapping or Misunderstanding? *J Clin Gastroenterol* 2016; 50 Suppl 1: S29-32.
18. Comparato G, Fanigliulo L, Aragona G, et al. Quality of life in uncomplicated symptomatic diverticular disease: is it another good reason for treatment? *Dig Dis* 2007; 25: 252-9.
19. Spiegel BM, Reid MW, Bolus R, et al. Development and validation of a disease-targeted quality of life instrument for chronic diverticular disease: the DV-QOL. *Qual Life Res*. 2015; 24: 163-79.
20. Horgan AF, McConnell EJ, Wolff BG, The S, Paterson C. Atypical diverticular disease: surgical results. *Dis Colon Rectum* 2001; 44: 1315-8.
21. Clemens CH, Samsom M, Roelofs J, van Berge Henegouwen GP, Smout AJ. Colorectal visceral perception in diverticular disease. *Gut* 2004; 53: 717-22.
22. Humes DJ, Simpson J, Smith J, et al. Visceral hypersensitivity in symptomatic diverticular disease and the role of neuropeptides and low grade inflammation. *Neurogastroenterol Motil* 2012; 24: 318-e163.
23. Simpson J, Sundler F, Humes DJ, Jenkins D, Scholefield JH, Spiller RC. Postinflammatory damage to the enteric nervous system in diverticular disease and its relationship to symptoms. *Neurogastroenterol Motil* 2009; 21: 847-e58.
24. Bassotti G, Villanacci V, Bernardini N, Dore MP. Diverticular Disease of the Colon: Neuromuscular Function Abnormalities. *J Clin Gastroenterol* 2016; 50 Suppl 1: S6-8.
25. Bassotti G, Sietchiping-Nzepa F, De Roberto G, Chistolini F, Morelli A. Colonic regular contractile frequency patterns

- in irritable bowel syndrome: the 'spastic colon' revisited. *Eur J Gastroenterol Hepatol* 2004; 16: 613-7.
26. Barbara G, Scaioli E, Barbaro MR, et al. Gut microbiota, metabolome and immune signatures in patients with uncomplicated diverticular disease. *Gut* 2016 Sep 12. pii: gutjnl-2016-312377.
  27. Papi C, Ciaco A, Koch M, Capurso L. Efficacy of rifaximin on symptoms of uncomplicated diverticular disease of the colon. A pilot multicentre open trial. *Diverticular Disease Study Group. Ital J Gastroenterol* 1992; 24: 452-6.
  28. Papi C, Ciaco A, Koch M, Capurso L. Efficacy of rifaximin in the treatment of symptomatic diverticular disease of the colon. A multicentre double-blind placebo-controlled trial. *Aliment Pharmacol Ther* 1995; 9: 33-9.
  29. Latella G, Pimpo MT, Sottili S, et al. Rifaximin improves symptoms of acquired uncomplicated diverticular disease of the colon. *Int J Colorectal Dis* 2003; 18: 55-62.
  30. Colecchia A, Vestito A, Pasqui F, et al. Efficacy of long term cyclic administration of the poorly absorbed antibiotic Rifaximin in symptomatic, uncomplicated colonic diverticular disease. *World J Gastroenterol* 2007; 13: 264-9.
  31. D'Inca R, Pomerri F, Vettorato MG, et al. Interaction between rifaximin and dietary fibre in patients with diverticular disease. *Aliment Pharmacol Ther* 2007; 25: 771-9.
  32. Cremon C, Bellacosa L, Barbaro MR, Cogliandro RF, Stanghellini V, Barbara G. The diagnostic challenge of symptomatic uncomplicated diverticular disease. *Minerva Gastroenterol Dietol* 2017 Jan 12. doi: 10.23736/S1121-421X.17.02370-4.
  33. Cuomo R, Barbara G, Andreozzi P, et al. Symptom patterns can distinguish diverticular disease from irritable bowel syndrome. *Eur J Clin Invest* 2013; 43: 1147-55.
  34. Cohen E, Fuller G, Bolus R, et al. Increased risk for irritable bowel syndrome after acute diverticulitis. *Clin Gastroenterol Hepatol* 2013; 11: 1614-9.
  35. Flor N, Maconi G, Cornalba G, Pickhardt PJ. The Current Role of Radiologic and Endoscopic Imaging in the Diagnosis and Follow-Up of Colonic Diverticular Disease. *AJR Am J Roentgenol* 2016; 207:15-24.
  36. Maconi G, Carmagnola S, Guzowski T. Intestinal Ultrasonography in the Diagnosis and Management of Colonic Diverticular Disease. *J Clin Gastroenterol* 2016; 50 Suppl 1: S20-2.
  37. Nguyen GC, Sam J, Anand N. Epidemiological trends and geographic variation in hospital admissions for diverticulitis in the United States. *World J Gastroenterol* 2011; 17 (12): 1600-5.
  38. Hollerweger A, Macheiner P, Hübner E, Brunner W, Gritzmann N. [Colonic diverticulosis: A comparison between sonography and endoscopy]. *Ultraschall Med.* 2002; 23:41-6.
  39. Sands BE. Biomarkers of Inflammation in Inflammatory Bowel Disease. *Gastroenterology* 2015; 149: 1275-85.e2.
  40. Tursi A, Brandimarte G, Elisei W, Giorgetti GM, Inchin-golo CD, Aiello F. Faecal calprotectin in colonic diverticular disease: a case-control study. *Int J Colorectal Dis* 2009; 24: 49-55.
  41. Tursi A, Elisei W, Picchio M, Giorgetti GM, Brandimarte G. Moderate to severe and prolonged left lower-abdominal pain is the best symptom characterizing symptomatic uncomplicated diverticular disease of the colon: a comparison with fecal calprotectin in clinical setting. *J Clin Gastroenterol* 2015; 49: 218-21.
  42. Scarpignato C, Pelosini I. Rifaximin, a poorly absorbed antibiotic: pharmacology and clinical potential. *Chemotherapy* 2005; 51 Suppl 1: 36-66.
  43. Pietrzak A, Bartnik W, Szczepkowski M, et al. Polish interdisciplinary consensus on diagnostics and treatment of colonic diverticulosis (2015). *Pol Przegl Chir* 2015; 87: 203-20.
  44. DuPont HL. Review article: the antimicrobial effects of rifaximin on the gut microbiota. *Aliment Pharmacol Ther* 2016; 43 Suppl 1: 3-10.
  45. Ponziani FR, Scaldaferrri F, Petito V, et al. The Role of Antibiotics in Gut Microbiota Modulation: The Eubiotic Effects of Rifaximin *Dig Dis* 2016; 34: 269-78.
  46. Soldi S, Vasileiadis S, Uggeri F, et al. Modulation of the gut microbiota composition by rifaximin in non-constipated irritable bowel syndrome patients: a molecular approach. *Clin Exp Gastroenterol* 2015; 8: 309-25.
  47. Cianci R, Frosali S, Pagliari D, et al. Uncomplicated diverticular disease: innate and adaptive immunity in human gut mucosa before and after rifaximin. *J Immunol Res* 2014; 2014:696812.
  48. Cianci R, Iacopini F, Petruzzello L, Cammarota G, Pandolfi F, Costamagna G. Involvement of central immunity in uncomplicated diverticular disease. *Scand J Gastroenterol* 2009; 44: 108-15.
  49. Bianchi M, Festa V, Moretti A, et al. Meta-analysis: long-term therapy with rifaximin in the management of uncomplicated diverticular disease. *Aliment Pharmacol Ther* 2011; 33: 902-10.
  50. Lanas A, Ponce J, Bignamini A, Mearin F. One year intermittent rifaximin plus fibre supplementation vs. fibre supplementation alone to prevent diverticulitis recurrence: a proof-of-concept study. *Dig Liver Dis* 2013; 45: 104-9.
  51. Stallinger S, Eller N, Hogenauer C. Non-interventional study evaluation efficacy and tolerability of rifaximin for treatment of uncomplicated diverticular disease. *Wien Klin Wochenschr* 2014; 126: 9-14.
  52. Koo HL, DuPont HL. Rifaximin: a unique gastrointestinal-selective antibiotic for enteric diseases. *Curr Opin Gastroenterol* 2010; 26: 17-25.

Received: 28 December 2016

Accepted: 3 March 2017

Correspondence:

Giovanni Maconi

Gastroenterology Unit, Department of Biomedical and

Clinical Sciences, L. Sacco University Hospital, Milan, Italy

E-mail: giovanni.maconi@unimi.it