

Article Navigation

CORRECTED PROOF

Do not throw the baby out with the bathwater: SELECT a personalized, de-escalated lenvatinib schedule allows response in locally advanced DTC while controlling major drug-related bleeding

C. Resteghini; L. D. Locati; P. Bossi; C. Bergamini; M. Guzzo; L. Licitra 

Annals of Oncology, mdx251, <https://doi.org/10.1093/annonc/mdx251>

Published: 19 July 2017 **Article history** ▼

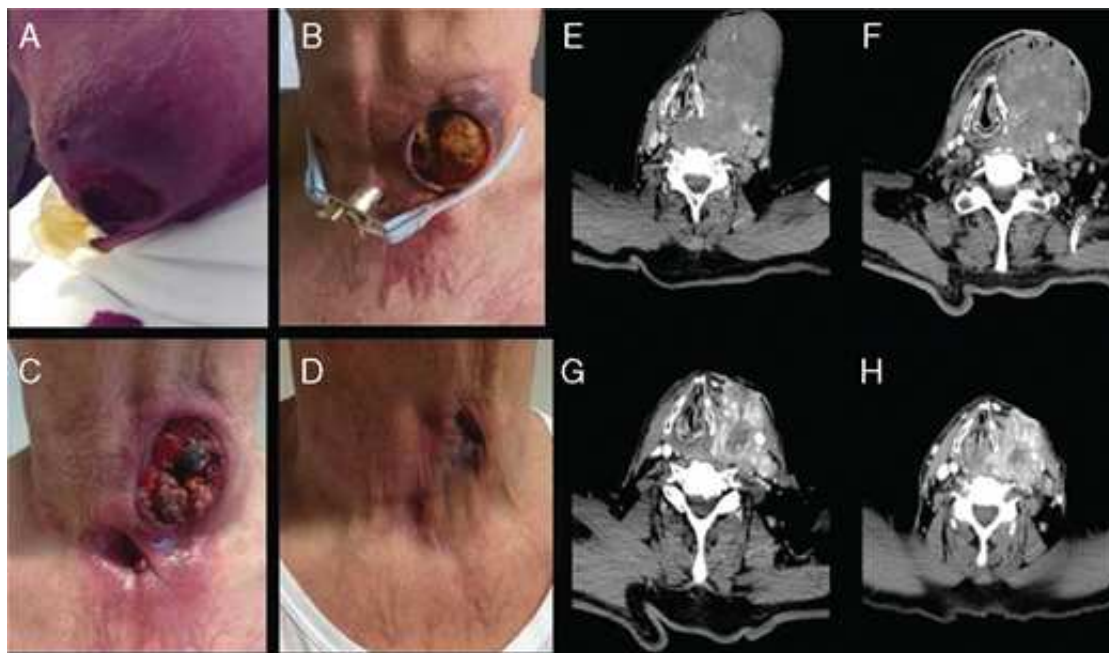
Views ▼ PDF Cite Permissions Share ▼

Lenvatinib has proved to be an effective but quite toxic therapeutic tool for differentiated thyroid carcinomas (DTCs), with two third of pts needing dose reduction and 14.2% discontinuing treatment in the SELECT trial [1]. Severe bleeding has been reported as one of the main cause of death in DTC pts treated with multi-target TKI [2].

We report the case of a 77-year-old man affected by locally advanced DTC who took advantage of a personalized drug schedule. He presented with a bulky, unresectable thyroid mass with carotid encasement and tracheo-esophageal infiltration. The inability to perform radioactive iodine (RAI)

drove the decision to start TKI treatment in a naïve patient without other therapeutic option. First-line treatment with sorafenib was rapidly discontinued due to severe skin toxicities. Subsequently, lenvatinib was administered at standard dose of 24 mg q.d.s. continuously for 4 weeks with evidence of dramatic response and partial necrotic evolution of the mass on CT scan. Nevertheless, treatment caused severe morbidity, as the pt experienced tumor excavation due to mass ulceration, major endo-tracheal bleeding causing dispnea, eventually leading to tracheotomy carried out through cancer tissue (Figure 1A). Superimposed local infection by multiple drug resistant microorganisms (*MRSA* and *ESBL Escherichiacoli*) further complicated the scenario (Figure 1B). Wound care required multiple medication each day; it was obtained with anti-hemorrhagic gauze and both local and systemic antibiotic therapy.

Figure 1.



[View large](#)

[Download slide](#)

Timeline of clinical (A–D) and radiological (E–H) aspects of thyroid lesion.

Given the remarkable activity of lenvatinib and the lack of valuable option, lenvatinib was resumed after a 3 week interval from the last dose, adopting a personalized schedule. Treatment dosing and local bleeding control was obtained by progressively tapering down lenvatinib to 14 mg every 3 days. Interestingly, increased local bleeding was always observed the day after drug administration. This is consistent with lenvatinib's half-life time of 28 h. Attempts to increase dose density failed due to intolerable bleeding. Ten months later, he still remain on treatment with the same schedule without any adverse event other than G1 fatigue. He is experiencing major clinical and radiological response that progressively allowed us to remove tracheotomy and obtained an optimal wound healing with

complete re-epithelialization (Figure 1C and D).

We observed a near-lethal toxicity from lenvatinib that if managed according to research protocol would have required discontinuation of an active treatment. This is typically occurring in case of a complicated response. Unfortunately studies do not always report tumor response-related complication. However, these dramatic events, which are mentioned in lenvatinib's summary of product characteristics, should be foreseen. An accurate risk/benefit evaluation is recommended. We successfully managed this event by individualizing the drug schedule in terms of dose and timing with a significant dose intensity reduction.

An ongoing phase II trial (E7080-G000-211) is investigating whether daily starting dose of 20 or 14 mg will provide comparable efficacy and safety benefits to a standard 24 mg starting dose. These doses were selected based on the clear dose–response antitumor activity observed in previous phase I study, particularly at doses ≥ 12 mg q.d.s. Therefore, doses below 14 mg, such as the one we are currently delivering to our pt, were not considered.

Luckily, in clinical practice individualized treatment with dose escalation approach is an important resource to fully exploit the potential of active but also toxic drug such as lenvatinib, also in a RAI-naïve population with unresectable masses.

Funding

None declared.

Disclosure

LL is a consultant for Eisai and received funds for clinical studies and research activities. All the other authors have declared no conflicts of interest.

References

1

Schlumberger NM, Tahara M, Wirth LJ et al. Lenvatinib versus placebo in radioiodine-refractory thyroid cancer. *N Engl J Med* 2015; 372: 621–630.

[Google Scholar](#) [CrossRef](#) [PubMed](#)

2

Ye X, Zhu Y, Cai J. Relationship between toxicities and clinical benefits of newly approved tyrosine kinase inhibitors in thyroid cancer: a meta-analysis of literature. *J Can Res Ther* 2015; 11: 185–190.

[Google Scholar](#) [CrossRef](#)

Issue Section: [Letter to the Editor](#)

© The Author 2017. Published by Oxford University Press on behalf of the European Society for Medical Oncology. All rights reserved. For Permissions, please email: journals.permissions@oup.com.

[View Metrics](#)

Email alerts

[New issue alert](#)

[Advance article alerts](#)

[Article activity alert](#)

[Receive exclusive offers and updates
from Oxford Academic](#)

More on this topic

Clinical outcomes of melanoma brain metastases treated with stereotactic radiation and anti-PD-1 therapy

Incidence and risk of hemorrhagic events with vascular endothelial growth factor receptor tyrosine-kinase inhibitors: an up-to-date meta-analysis of 27 randomized controlled trials

Cancer effect on periprocedural thromboembolism and bleeding in anticoagulated patients

Incidental versus symptomatic venous thrombosis in cancer: a prospective observational study of 340 consecutive patients

Related articles in

[Google Scholar](#)

Citing articles via

[Google Scholar](#)

[CrossRef](#)

[Latest](#) | [Most Read](#) | [Most Cited](#)

Tumor- and class-specific patterns of immune-related adverse events of immune checkpoint inhibitors: a systematic review.

RAS testing of liquid biopsy correlates with the outcome of metastatic colorectal cancer patients treated with first-line FOLFIRI plus cetuximab in the CAPRI-GOIM trial

Comprehensive genomic profiles of metastatic and relapsed salivary gland carcinomas are associated with tumor type and reveal new routes to targeted therapies

Changes in the use of endpoints in clinical trials for elderly cancer patients over time

A phase III trial comparing oral S-1/cisplatin and intravenous 5-fluorouracil/cisplatin in patients with untreated diffuse gastric cancer

[About Annals of Oncology](#)

[Editorial Board](#)

[Author Guidelines](#)

[Twitter](#)

[Purchase](#)

[Recommend to your Library](#)

[Advertising and Corporate Services](#)

[Journals Career Network](#)



Online ISSN 1569-8041

Print ISSN 0923-7534

Copyright © 2017 European Society for Medical Oncology

[About Us](#)

[Contact Us](#)

[Careers](#)

[Help](#)

[Access & Purchase](#)

[Rights & Permissions](#)

[Open Access](#)

Resources

[Authors](#)

[Librarians](#)

[Societies](#)

[Sponsors & Advertisers](#)

[Press & Media](#)

[Agents](#)

Connect

[Join Our Mailing List](#)

[OUPblog](#)

[Twitter](#)

[Facebook](#)

[YouTube](#)

[Tumblr](#)

Explore

[Shop OUP Academic](#)

[Oxford Dictionaries](#)

[Oxford Index](#)

[Epigeum](#)

[OUP Worldwide](#)

[University of Oxford](#)

Oxford University Press is a department of the University of Oxford. It furthers the University's objective of excellence in research, scholarship, and education by publishing worldwide

OXFORD
UNIVERSITY PRESS

Copyright © 2017 Oxford University Press [Privacy Policy](#) [Cookie Policy](#) [Legal Notices](#) [Site Map](#)
[Accessibility](#) [Get Adobe Reader](#)