

Midterm Results of Proximal Aneurysm Sealing With the Ovation Stent-Graft According to On- vs Off-Label Use

Journal of Endovascular Therapy
2017, Vol. 24(2) 191–197
© The Author(s) 2017
Reprints and permissions:
sagepub.com/journalsPermissions.nav
DOI: 10.1177/1526602816685581
www.jevt.org
SAGE

Gianmarco de Donato, MD¹, Francesco Setacci, MD², Luciano Bresadola, MD³, Patrizio Castelli, MD⁴, Roberto Chiesa, MD⁵, Nicola Mangialardi, MD⁶, Giovanni Nano, MD⁷, and Carlo Setacci, MD¹, on behalf of the TriVascular Ovation Italian Study (TOIS) Collaborators*

Abstract

Purpose: To compare the use of the Ovation stent-graft according to the ≥ 7 -mm neck length specified by the original instructions for use (IFU) vs those treated off-label (OL) for necks < 7 mm long. **Methods:** A multicenter retrospective registry (TriVascular Ovation Italian Study) database of all patients who underwent endovascular aneurysm repair with the Ovation endograft at 13 centers in Italy was interrogated to identify patients with a minimum computed tomography (CT) follow-up of 24 months, retrieving records on 89 patients (mean age 76.4 ± 2.4 years; 84 men) with a mean follow-up of 32 months (range 24–50). Standard CT scans (preoperative, 1-month postoperative, and latest follow-up) were reviewed by an independent core laboratory for morphological changes. For analysis, patients were stratified into 2 groups based on proximal neck length ≥ 7 mm (IFU group, $n=57$) or < 7 mm (OL group, $n=32$). Outcome measures included freedom from type Ia endoleak, any device-related reintervention, migration, and neck enlargement (> 2 mm). **Results:** At 3 years, there was no aneurysm-related death, rupture, stent-graft migration, or neck enlargement. There were no differences in terms of freedom from type Ia endoleak (98.2% IFU vs 96.8% OL, $p=0.6$; hazard ratio [HR] 0.55, 95% CI 0.02 to 9.71) or freedom from any device-related reintervention (92.8% IFU vs 96.4% OL, $p=0.4$; HR 2.42, 95% CI 0.34 to 12.99). In the sealing zone, the mean change in diameters was -0.05 ± 0.8 mm in the IFU group and -0.1 ± 0.5 mm in the OL group. **Conclusion:** Use of the Ovation stent-graft in patients with neck length < 7 mm achieved midterm outcomes similar to patients with ≥ 7 -mm-long necks. These midterm data show that the use of the Ovation system for the treatment of infrarenal abdominal aortic aneurysm is not restricted by the conventional measurement of aortic neck length, affirming the recent Food and Drug Administration–approved changes to the IFU.

Keywords

abdominal aortic aneurysm, aneurysm neck, endograft, endoleak, endovascular aneurysm repair, instructions for use, off-label use, proximal sealing, sealing ring, stent-graft

Introduction

Traditional self-expanding stent-grafts require an infrarenal nonaneurysmal aortic neck to adequately seal the abdominal aortic aneurysm (AAA) sac from chronic circulatory pressures. Sealing is obtained by oversizing the stent-graft (from 10% to 30%) at that level, on the assumption that the chronic radial force exerted longitudinally against the aortic wall will circumferentially avert any leakage. Since the first endovascular aneurysm repair (EVAR) experiences, this sealing concept has restricted the application of stent-grafts to patients with a proximal aortic neck generally longer than 15 mm.¹ In patients with complex aortic necks, proximal graft sealing remains a challenge with traditional self-expanding stent-grafts.^{2–5} In particular, a recent systematic

review and meta-analysis reported that short neck and AAA diameter are strongly associated with migration, subsequent proximal type Ia endoleak, and poor early and late outcomes after EVAR.⁶

The Ovation endograft (Endologix, Irvine, CA, USA), with its new concept of sealing by nonexpansive circumferential apposition of polymer-filled rings to the aortic wall, generates no chronic outward force at the infrarenal aortic level.⁷ In August 2010, the Ovation endograft received Conformité Européenne approval and was commercially accessible in Europe. At that time, the device-specific instructions for use (IFU) allowed the treatment of aneurysms with a proximal aortic neck of only 7 mm, the first device ever approved for necks shorter than 10 mm.

The circumferential sealing of the Ovation endograft based on the polymer-filled ring theoretically allows the treatment of a range of aortic neck diameters independent of neck length. This means that even in the presence of an aortic neck length <7 mm, some patients can be treated provided that the aortic neck diameter is compatible with the Ovation ring sizes. This study compared the outcomes of the Ovation stent-graft applied according to the neck length required by the original IFU vs off-label (OL) use (neck length <7 mm).

Methods

Study Registry and Patient Sample

A multicenter registry (TriVascular Ovation Italian Study) database was established to retrospectively gather data on all patients who underwent EVAR with an Endologix Ovation endograft at 13 centers in Italy from 2010 onward (see the appendix for a list of collaborators). The initial manufacturer's IFU recommended a nonaneurysmal proximal aortic neck with (1) a length of at least 7 mm proximal to the aneurysm, (2) an inner diameter between 16 and 30 mm, and (3) an aortic angle $\leq 60^\circ$ for a proximal neck ≥ 10 mm long or $\leq 45^\circ$ for a proximal neck <10 mm in length.

For this analysis, the database was searched to identify patients with a minimum computed tomography (CT) follow-up of 24 months, which retrieved 89 patients (mean age 76.4 ± 2.4 years; 84 men) treated from December 2010 to November 2012 who met the inclusion criterion. Mean follow-up was 32 months (range 24–50). Patients were stratified into 2 groups based on proximal neck length ≥ 7 mm (IFU group, $n=57$) or <7 mm (OL group, $n=32$).

Image Analysis and Measurements

Full datasets and cross-sectional images of the contrast-enhanced CT scans performed before EVAR, at the first postoperative month, and at the latest follow-up were reviewed centrally by a vascular surgeon (GdD) using dedicated software with multiplanar and volume reconstructions

(OsiriX MD v.6.5.1 64-bit; Pixmeo SARL, Bernex, Switzerland). All vessel measurements (outer wall to outer wall) were performed using a central line lumen created by manual segmentation of the aorta on each axial slice. In addition to the dimensions of the aorta, the presence of thrombus, graft migration, stent-graft patency and integrity, evidence of endoleak, barb detachment, and ventral, lateral, and posterior neck bulging were assessed. The proximal aortic neck on scans after EVAR was evaluated in 2 distinct zones: (1) the collar zone from a tangential horizontal plane passing through the most distal point of the circumference of the lowermost renal artery ostium to a horizontal plane passing through the most cranial point of the first polymer-filled ring and (2) the sealing zone at the level of the first polymer-filled ring. These 2 zones were examined separately and then compared between pre- and postoperative images, with the distance from the lower renal artery as reference for the analysis of morphological changes of each single zone. The same imaging data were sent to a centralized core laboratory for independent review of morphological changes.

Definitions

The AAA neck was defined as the longitudinal distance between the first transverse CT slice directly distal to the lowermost renal artery and the first transverse CT slice that showed at least a 10% larger outer aortic wall diameter vs the diameter measured directly below the lowermost renal artery. Aortic neck dilatation referred to a diameter increase >2 mm between the preoperative and latest follow-up CT scan. Stent-graft migration was defined as a ≥ 3 -mm increase in the distance between the lower renal artery and the proximal end of the stent-graft between the first and latest CT scan.

Primary technical success (intention-to-treat basis) referred to successful introduction and deployment of the device in the absence of surgical conversion, death, type I or III endoleaks, or graft limb obstruction. Assisted primary or secondary technical success referred to the use of unplanned endovascular or surgical procedures, respectively, to achieve a successful procedure.

¹Division of Vascular Surgery, University of Siena, Italy

²Department of Vascular Surgery, Casa di Cura Giovanni XXIII, Monastier di Treviso, Italy

³Department of Interventional Radiology, Sapienza University of Rome, Italy

⁴Department of Vascular Surgery, University of Varese, Italy

⁵Department of Vascular Surgery, Vita-Salute San Raffaele University, Milan, Italy

⁶Department of Vascular Surgery, Hospital San Filippo Neri, Rome, Italy

⁷Department of Vascular Surgery, University of Milan, Italy

*The list of collaborators is given in the appendix.

Corresponding Author:

Gianmarco de Donato, Department of Medicine, Surgery and Neuroscience, Division of Vascular Surgery, University of Siena, Viale Bracci, Siena 53100, Italy.

Email: dedonato@unisi.it

Clinical success was defined as satisfactory deployment of the endovascular device at the intended location without death as a result of aneurysm-related treatment, type I or III endoleak, graft infection or thrombosis, aneurysm expansion (diameter >5 mm or volume >5%), aneurysm rupture, or conversion to open repair. Assisted primary and secondary clinical success referred to re-establishment of patency or resolution of a complication by endovascular or surgical means, respectively. Secondary interventions included both endovascular and surgical procedures.

AAA-related adverse events referred to a composite of direct (type I or III) or undetermined type endoleaks, aneurysm sac growth, migration, device integrity failure, AAA-related death, late post-implantation AAA rupture, or any AAA-related secondary intervention.

Outcome Measures

The primary study outcome was freedom from type Ia endoleak; secondary outcomes were primary clinical success, freedom from any device-related reintervention, freedom from rupture, freedom from migration, and freedom from neck dilatation (>2 mm) in the collar and sealing zones.

Statistical Analysis

The data were expressed as mean \pm standard deviations or as median and interquartile range (IQR), depending on the type of distribution. Intraobserver variability was assessed using Cohen's kappa (κ) test of concordance based on the observer measuring each of 20 randomly selected CT scans twice at least 2 weeks apart. The mean changes in the diameters at the collar and sealing zones are presented with the standard error of the mean (SEM). The Spearman rank correlation coefficient (ρ) was used to test for any relationship between these changes at the collar and sealing zones. The Kaplan-Meier method was used to analyze the outcome measures; competing risk analysis was used for all complications.⁸⁻¹⁰ Curves for the 2 groups were compared with the log-rank test. The estimates are given along with the hazard ratio (HR) and the 95% confidence intervals (CI). All statistical analyses were performed using GraphPad Prism statistical software (GraphPad, San Diego, CA, USA).

Results

Primary technical success was 96.5% (1 type Ia endoleak and 1 iliac graft occlusion) in the IFU group and 96.9% (1 type Ia endoleak) in the OL group ($p=0.8$). In the IFU group, the iliac graft occlusion was treated with a femorofemoral bypass (98.3% secondary technical success) and the endoleak was lessened after intraoperative balloon angioplasty; the leak had disappeared at the 1-month CT scan.

The endoleak in the OL group was treated with a balloon-expandable stent (100% assisted primary technical success). The perioperative mortality was 0%.

At 2 years, primary clinical success was 94.8% and 96.9%, respectively, in the IFU and OL groups ($p=0.6$). There was no aneurysm-related death, rupture, stent-graft migration, or neck enlargement. Each group had 1 late type Ia endoleak. The IFU group also had 2 graft thromboses. Reintervention was performed in 4 (7.0%) IFU patients for the late endoleak (coil and glue embolization), the 2 iliac limb occlusions (bypass in one and surgical thrombectomy in the other), and a type II endoleak (coil embolization). In the OL group, the only reintervention (3.1%) was for the late Ia endoleak (aortic cuff). Kaplan-Meier analysis at 3 years (Figure 1) found no differences in terms of freedom from type Ia endoleak (98.2% IFU vs 96.8% OL, $p=0.6$; HR 0.55, 95% CI 0.0 to 9.71) or freedom from any device-related reintervention (92.8% IFU vs 96.4% OL, $p=0.4$; HR 2.42, 95% CI 0.34 to 12.99).

In the CT image analysis, intraobserver agreement was excellent (Cohen's $\kappa=0.91$). The sizes of the stent-graft body ranged from 23 to 34 mm; mean oversizing was not different in the 2 study groups (17% \pm 4% IFU vs 19% \pm 3% OL, $p=0.3$). The mean stent-graft landing distance to the lower renal artery was 3.13 \pm 4.25 mm (median 2 mm, IQR 0,6) and did not vary between groups (3.4 \pm 4.1 IFU vs 2.9 \pm 3.3 OL, $p=0.2$). In particular, landing distance (Figure 2A) was \leq 5 mm in 68.4% (39/57) of IFU patients and 81.1% (26/32) of OL patients ($p=0.02$).

Changes in the collar and sealing zones were analyzed in both groups. At the last follow-up scan, the mean change in the diameters at the collar zone (Figure 2B) was -0.3 ± 0.7 mm (SEM 0.07) in the IFU group and -0.2 ± 0.8 mm (SEM 0.08) in the OL group; the majority of cases had an absolute decrease in the diameter (median 0.0 mm, IQR 0, -0.6). In the sealing zone (Figure 2C), the mean alterations in diameters were -0.05 ± 0.8 mm (SEM 0.08) in the IFU group and -0.1 ± 0.5 mm (SEM 0.1) in the OL group (median 0.0 mm, IQR $+0.4, -0.3$). Changes at the collar zone correlated significantly (Figure 3) with modifications at the sealing zone in both groups equally (IFU group: $\rho=0.13$; OL group: $\rho=0.19$).

Discussion

The beginning of the EVAR era was characterized by endografts that consisted of a tubular graft attached at both ends to a large balloon-expandable stent, such as the homemade Parodi endograft or the Montefiore Endograft System. Not surprisingly, because these early devices lacked chronic outward force at the level of the proximal neck, they were not associated with neck dilatation over time, even though stent migration and endograft collapse into the sac were possible complications.¹¹⁻¹³ With the advent of self-expanding

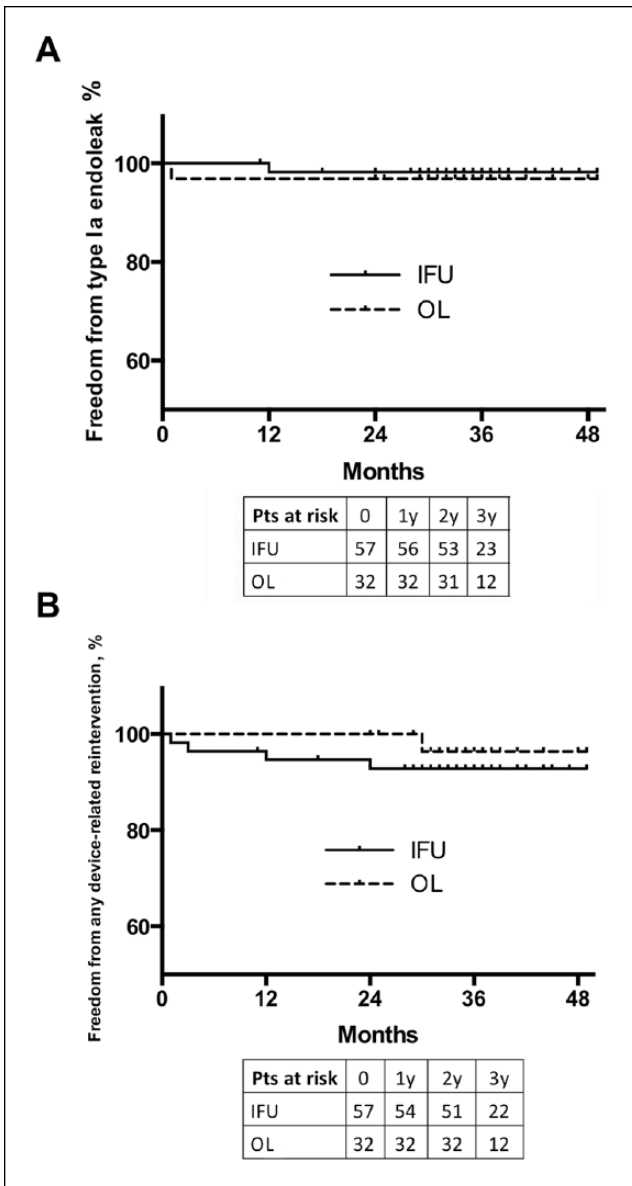


Figure 1. Kaplan-Meier estimates of (A) freedom from type Ia endoleak and (B) freedom from reintervention in the instructions for use (IFU) and off-label (OL) groups.

stent-grafts, the balloon-expandable models have been rapidly disappearing from the market for several years.

For a long time, the only available technology for sealing was based on the application of self-expanding forces to a portion of healthy proximal aortic neck. The recent appearance of the Ovation endograft, with its unique circumferential inflatable sealing rings, represents a valid alternative to chronic outward forces for appropriate sealing, avoiding neck dilatation as previously reported for patients in our registry.¹⁴

Typically, the feasibility of EVAR for infrarenal AAA has been mainly related to the aortic morphology, with the majority of manufacturers' IFU originally requiring an

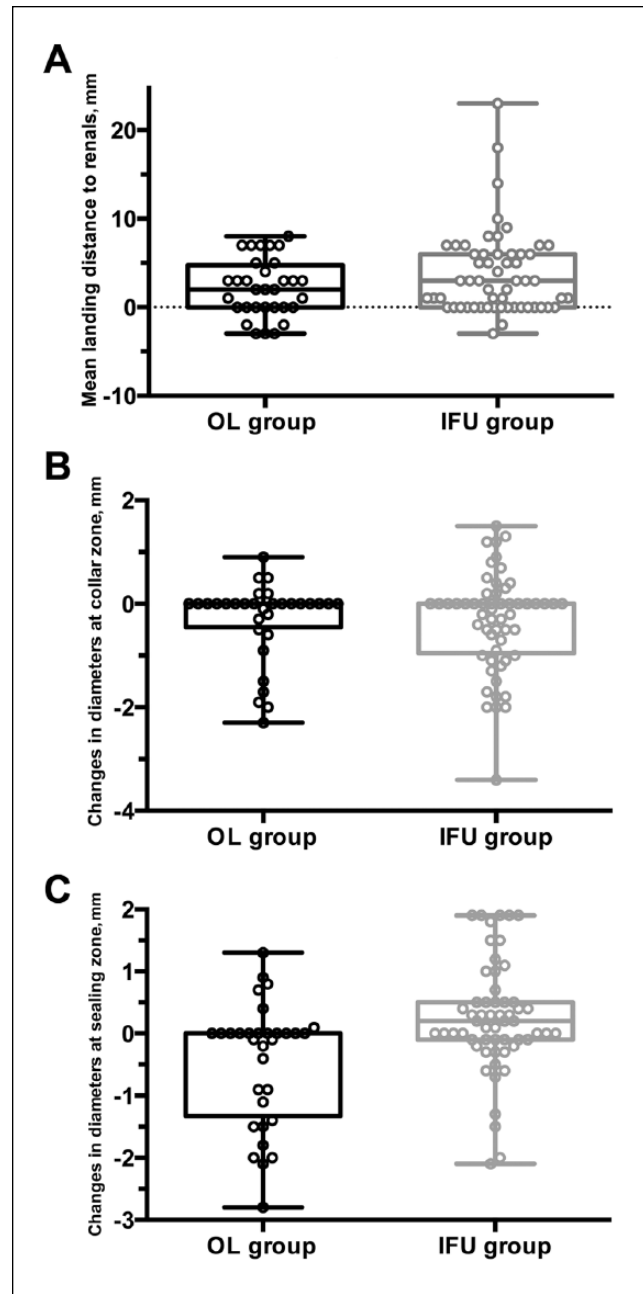


Figure 2. (A) Stent-graft landing distance to the lowest renal artery. (B) Changes in diameters over time at the level of the collar zone. The horizontal line in the middle of the box indicates the median; the top and the bottom borders of the box mark the 75th and 25th percentiles, respectively. (C) Changes in diameters over time at the level of the sealing zone. The horizontal line in the middle of the box indicates the median; the top and the bottom borders of the box mark the 75th and 25th percentiles, respectively. IFU, instructions for use; OL, off-label.

adequate nonaneurysmal proximal neck of 10 to 15 mm, an aortic diameter <30 mm, with infrarenal angulation <60°. As expected, implantations outside of the anatomical criteria specified in the IFU have an incremental negative effect

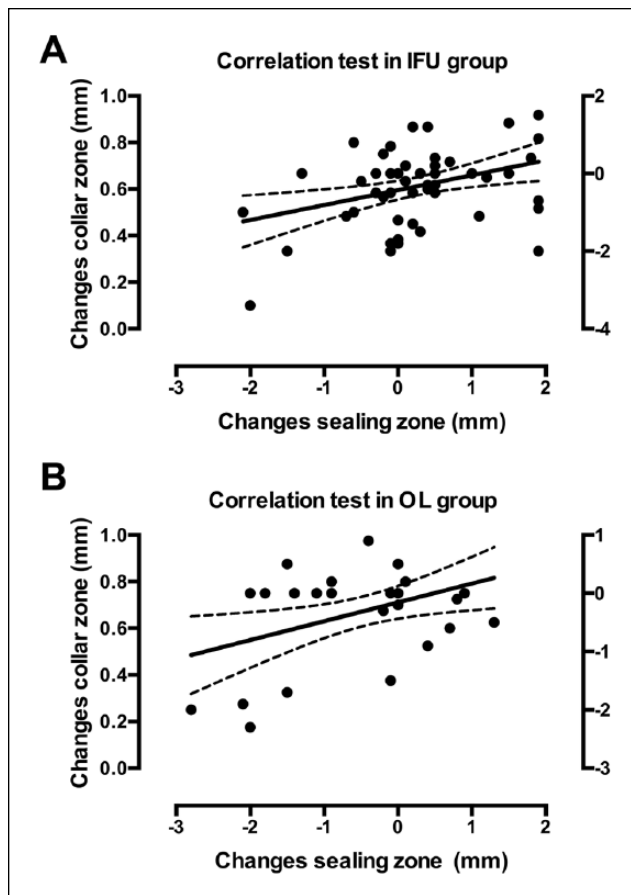


Figure 3. The Spearman correlation test between changes at the collar zone and changes at the sealing zone in (A) the instructions for use (IFU) group vs (B) the off-label (OL) group.

on late results.^{15,16} In a systematic review and meta-analysis of the literature, Spanos et al⁶ identified patients with large AAAs and short necks as those at highest risk of graft migration after EVAR with old-generation stent-grafts. Of note, neck diameter and neck angulation did not have any important influence on stent-graft migration.

With the availability of new generation devices, an increasing number of EVARs have been performed outside the IFU.¹⁷ Violations of the IFU are particularly focused on unfavorable proximal aortic neck anatomy. Out of 10,228 patients undergoing EVAR between January 1, 1999, and December 31, 2008, only 42% of patients had anatomy that met the most conservative definition of the IFU, while 69% met the most liberal interpretation of the IFU.¹⁸

A systematic review and meta-analysis of outcomes following EVAR in patients with hostile neck anatomy (neck length <15 mm, diameter >28 mm, or angulation >60° alone or in combination) revealed a significant increase in 30-day (odds ratio 2.92) and late (odds ratio 1.71) type I endoleaks in comparison with patients with favorable neck anatomy.²

The first endograft to be approved for proximal necks <10 mm when it came to market, the Ovation recently became the only Food and Drug Administration (FDA)–approved abdominal aortic stent-graft to have no restriction on the aortic neck length in its labeling.¹⁹ Neck length is considered only in assessing angulation: patients with a proximal neck length <10 mm are eligible with an aortic angle $\leq 45^\circ$; otherwise, angles up to 60° are indicated.¹⁹

In accord with the expanded IFU, the use of the Ovation stent-graft in the absence of a 7-mm neck length was not dissimilar from midterm outcomes of the IFU group. Thus, the Ovation system does not require a minimum length of parallel vessel walls to achieve durable aneurysm seal. This is particularly important, since there has been no evidence until now that positive outcomes could be achieved based on the expanded IFU.

Admittedly, the good results in our registry were strictly related to the high familiarity of the operators with the device, which guaranteed a mean graft landing distance to the lower renal artery of only 3.13 mm. As part of a successful Ovation endograft implantation, landing the first ring in a conical and short neck has to be exactly at a pre-identified level of the aorta (typically 13 mm below the lower renal artery). A less precise deployment, even of only a couple of millimeters, may result in poor apposition of the sealing ring to the aortic wall. As revealed by the core laboratory evaluation, such a marginal and unplanned mistake in the endograft landing was responsible for the intraoperative and late type Ia endoleaks in the 2 OL patients.

Data on neck stability, both in the collar and sealing zones, emphasize how the aortic neck can definitely maintain its diameter with a sealing technology that does not apply chronic outward force. In particular, the permanence of the diameters at the level of the collar zone in the OL patients and correlation with the positive remodeling occurring at the level of the sealing zone seem to confirm that both areas are protected by blood pressure and do not expand as a result of the absence of any chronic radial force. Finally, our data clearly support the rationale of the investigational Ovation Alto endograft, in which the zone between the suprarenal stent and the first ring is totally omitted, as proposed previously by Nano et al.²⁰

Reports on anatomical suitability for EVAR^{21,22} vary between 25% and 66%, most often referring to the most liberal anatomical restrictions for each device. The minimum neck length requirement for conventional self-expanding stent-grafts and their ≥ 18 -F outer diameter system profile are still the major exclusion criteria for standard EVAR. The present IFU for the Ovation system, with no proximal neck length requirement and vascular access compatible with a 14-F device, might increase the patient population suitable for EVAR substantially, without elevating the complication rate, as demonstrated by our data.

Limitations

This was a retrospective study partially limited by the small size of the study cohort. Only patients with a completed CT follow-up were included, which may have created a bias since it is more likely that patients who did not receive CT control were those with more favorable outcomes (ie, patients with complete sac exclusion and significant aneurysm shrinkage at ultrasound follow-up). A further limitation was that a single observer performed all the CT analyses.

Conclusion

Use of the Ovation stent-graft in patients with neck length <7 mm achieved midterm outcomes no different from patients with ≥ 7 -mm-long necks, proving that the Ovation sealing ring creates uniform, continuous wall apposition with a circumferential nonexpansive seal independent of aortic neck length. Thus, the Ovation system may be used in aneurysm necks with an inner wall diameter compatible with the 16- to 30-mm size range of the polymer-filled rings. These data affirm the recent FDA-approved elimination of any neck length restriction in the Ovation's IFU.

Appendix

TriVascular Ovation Italian Study (TOIS) Collaborators: Carlo Setacci, Gianmarco de Donato, Carmelo Ricci (Siena); Daniele Gasparini, Gianluca Piccoli (Udine); Roberto Chiesa, Andrea Kahlberg (Milano); Giovanni Nano, Silvia Stegheer (Milano); Patrizio Castelli, Gianpaolo Carrafiello, Nicola Rivolta (Varese); Claudio Novali, Carlo Rivellini (Cuneo); Massimo Lenti, Giacomo Isernia (Perugia); Nicola Mangialardi, Sonia Ronkey (Roma); Rocco Giudice (Roma); Francesco Speziale, Pasqualino Sirignano, Luciano Bresadola (Roma); Giustino Marcucci, Federico Accrocca (Civitavecchia); Pietro Volpe (Reggio Calabria); Francesco Talarico, Gaetano La Barbera (Palermo).

Authors' Note

This material was presented as a poster display at the Society for Vascular Surgery Annual Meeting; National Harbor, MD, USA; June 10, 2016.

Declaration of Conflicting Interests

The author(s) declared no potential conflicts of interest with respect to the research, authorship, and/or publication of this article.

Funding

The author(s) received no financial support for the research, authorship, and/or publication of this article.

References

- Leurs LJ, Kievit J, Dagnelie PC, et al. Influence of infrarenal neck length on outcome of endovascular abdominal aortic aneurysm repair. *J Endovasc Ther.* 2006;13:640–648.
- Stather PW, Wild JB, Sayers RD, et al. Endovascular aortic aneurysm repair in patients with hostile neck anatomy. *J Endovasc Ther.* 2013;20:623–637.
- Jordan WD Jr, Ouriel K, Mehta M, et al. Aneurysm Treatment using the Heli-FX Aortic Securement System Global Registry ANCHOR. Outcome-based anatomic criteria for defining the hostile aortic neck. *J Vasc Surg.* 2015;61:1383–1390.
- AbuRahma AF, Campbell JE, Mousa AY, et al. Clinical outcomes for hostile versus favorable aortic neck anatomy in endovascular aortic aneurysm repair using modular devices. *J Vasc Surg.* 2011;54:13–21.
- Stather PW, Sayers RD, Cheah A, et al. Outcomes of endovascular aneurysm repair in patients with hostile neck anatomy. *Eur J Vasc Endovasc Surg.* 2012;44:556–561.
- Spanos K, Karathanos C, Saleptsis V, et al. Systematic review and meta-analysis of migration after endovascular abdominal aortic aneurysm repair. *Vascular.* 2016;24:323–336.
- Georgakarakos E, Ioannou CV, Georgiadis GS, et al. The Ovation abdominal stent graft for the treatment of abdominal aortic aneurysms: current evidence and future perspectives. *Expert Rev Med Devices.* 2016;13:253–262.
- Pepe MS, Mori M. Kaplan-Meier, marginal or conditional probability curves in summarizing competing risks failure time data? *Stat Med.* 1993;12:737–751.
- Pintilie M. Analysing and interpreting competing risk data. *Stat Med.* 2007;26:1360–1367.
- Putter H, Fiocco M, Geskus RB. Tutorial in biostatistics: competing risks and multi-state models. *Stat Med.* 2007;26:2389–2430.
- Parodi JC, Ferreira LM. Ten-year experience with endovascular therapy in aortic aneurysms. *J Am Coll Surg.* 2002;194(1 Suppl):S58–S66.
- Dalainas I, Nano G, Bianchi P, et al. Aortic neck dilatation and endograft migration are correlated with self-expanding endografts. *J Endovasc Ther.* 2007;14:318–323.
- Malas MB, Ohki T, Veith FJ, et al. Absence of proximal neck dilatation and graft migration after endovascular aneurysm repair with balloon-expandable stent-based endografts. *J Vasc Surg.* 2005;42:639–644.
- de Donato G, Setacci F, Bresadola L, et al, on behalf of the TriVascular Ovation Italian Study. Aortic neck evolution after endovascular repair with TriVascular Ovation stent graft. *J Vasc Surg.* 2016;63:8–15.
- Abbruzzese TA, Kwolek CJ, Brewster DC, et al. Outcomes following endovascular abdominal aortic aneurysm repair (EVAR): an anatomic and device-specific analysis. *J Vasc Surg.* 2008;48:19–28.
- Hobo R, Kievit J, Leurs LJ, et al. Influence of severe infrarenal aortic neck angulation on complications at the proximal neck following endovascular AAA repair: a EUROSTAR study. *J Endovasc Ther.* 2007;14:1–11.

17. Antoniou GA, Georgiadis GS, Antoniou SA, et al. A meta-analysis of outcomes of endovascular abdominal aortic aneurysm repair in patients with hostile and friendly neck anatomy. *J Vasc Surg.* 2013;57:527–538.
18. Schanzer A, Greenberg RK, Hevelone N, et al. Predictors of abdominal aortic aneurysm sac enlargement after endovascular repair. *Circulation.* 2011;123:2848–2855.
19. Mehta M. Rethink the neck. How the Ovation Prime System is revolutionizing the way we approach EVAR. *Endovascular Today.* 2014;Sept(Suppl):3–6.
20. Nano G, Mazzaccaro D, Stegher S, et al. Early experience with Ovation endograft system in abdominal aortic disease. *J Cardiothorac Surg.* 2014;9:48.
21. Carpenter JP, Baum RA, Barker CF, et al. Impact of exclusion criteria on patient selection for endovascular abdominal aortic aneurysm repair. *J Vasc Surg.* 2001;34:1050–1054.
22. Kristmundsson T, Sonesson B, Dias N, et al. Anatomic suitability for endovascular repair of abdominal aortic aneurysms and possible benefits of low profile delivery systems. *Vascular.* 2014;22:112–115.