

Acute hemifacial ischemia as a late complication of carotid stenting

Maurizio Domanin, MD,^{a,b} Maurizio Isalberti, MD,^c Silvia Romagnoli, MD,^b Antonio Rolli, MD,^b and Simona Sommaruga, MD,^b Milan, Italy

Concerns about carotid artery stenting (CAS) center primarily on procedural complications like acute occlusion, stroke, and long-term intrastent restenosis. External carotid artery (ECA) thrombosis is observed during CAS follow-up, but it often remains asymptomatic or, at worst, results in jaw claudication. We report here a case of late occlusion of the ECA after CAS with symptoms of acute homolateral facial ischemia as well as pain, cyanosis, tongue numbness, and skin coldness. The patient was submitted to local thrombolysis and balloon angioplasty with regression of symptoms after recanalization. With this report, we add a caveat about blockage of the ECA ostium during CAS. (*J Vasc Surg Cases* 2017;3:83-6.)

Because of the steady pace of advances in stent technology and the increasing experience of vascular specialists, carotid artery stenting (CAS) is challenging carotid endarterectomy (CEA) as a therapy option for stenosis. Major concerns about CAS include periprocedural stroke, secondary to embolization or stent thrombosis, and late development of intrastent restenosis. In contrast to surgery, CAS ensures the artery's patency by crushing and stabilizing, as a scaffolding, the flattened plaque, but it does not enable a decrease in the bulk of the atheromatous plaque. Consequently, the external carotid artery (ECA), which represents the main collateral branch for ipsilateral cerebral perfusion, is often covered by the metal struts of the stent. This contributes to a worsening of ECA perfusion that can evolve into thrombosis and cause unexpected complications, such as jaw claudication¹ or facial ischemia, as in the case presented here. Signed informed consent for publication was obtained.

CASE REPORT

A 64-year-old man arrived at the emergency department of our institution at 6:00 PM. Symptoms started at 3:00 PM with increasing pain localized in the lingual and masseter regions. Pain rapidly worsened and extended to the zygomatic and temporal areas with development of tongue numbness and

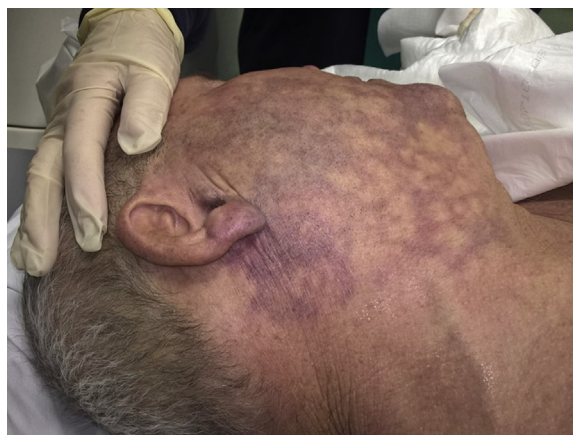

Fig 1. Cyanosis and patchy discoloration of the skin of the right hemiface secondary to external carotid artery (ECA) thrombosis.

cyanosis, coldness, and paresthesias of the right hemiface (Fig 1). His medical history was significant for smoking, hypercholesterolemia, essential hypertension, and diabetes. He had undergone left CEA in another hospital in 2008 for left asymptomatic carotid stenosis >70%. He refused CEA of a severe contralateral carotid stenosis in 2010 because of his distressing experience relative to locoregional anesthesia during the first intervention. He was submitted to right CAS with a 7.0- to 10.0-mm-diameter/40-mm-long self-expanding nitinol stent (Cristallo; Medtronic, Fridley, Minn), consequently to dual antiplatelet therapy for 30 days, and thereafter to aspirin 100 mg once a day according to guidelines for antiplatelet therapy after CAS.² The procedure went well, and the patient underwent Doppler ultrasound (DUS) follow-up regularly, with no detection of post-CEA restenosis on the left or intrastent restenosis on the right. At the time of the last follow-up, 4 months before facial ischemia, peak systolic velocities (PSVs) were, respectively, 90 and 100 cm/s; both of the ECAs, as often happens after CAS, were just described as "patent" without any supplemental information about velocities or ultrasound waveform.

He was taking aspirin 100 mg once daily, rosuvastatin 20 mg daily, atenolol 50 mg daily, valsartan/hydrochlorothiazide 160/

From the Department of Clinical Science and Community Health, University of Milan^a; and the Operative Unit of Vascular Surgery^b and Operative Unit of Neuroradiology,^c I.R.C.C.S. Fondazione Cà Granda Ospedale Maggiore Policlinico.

Author conflict of interest: none.

Correspondence: Maurizio Domanin, MD, Department of Clinical Science and Community Health, University of Milan, Via Francesco Sforza 25, Milan 20122, Italy (e-mail: maurizio.domanin@unimi.it).

The editors and reviewers of this article have no relevant financial relationships to disclose per the Journal policy that requires reviewers to decline review of any manuscript for which they may have a conflict of interest.

2468-4287

© 2017 The Author(s). Published by Elsevier Inc. on behalf of Society for Vascular Surgery. This is an open access article under the CC BY-NC-ND license (<http://creativecommons.org/licenses/by-nc-nd/4.0/>).

<http://dx.doi.org/10.1016/j.jvscit.2016.12.004>

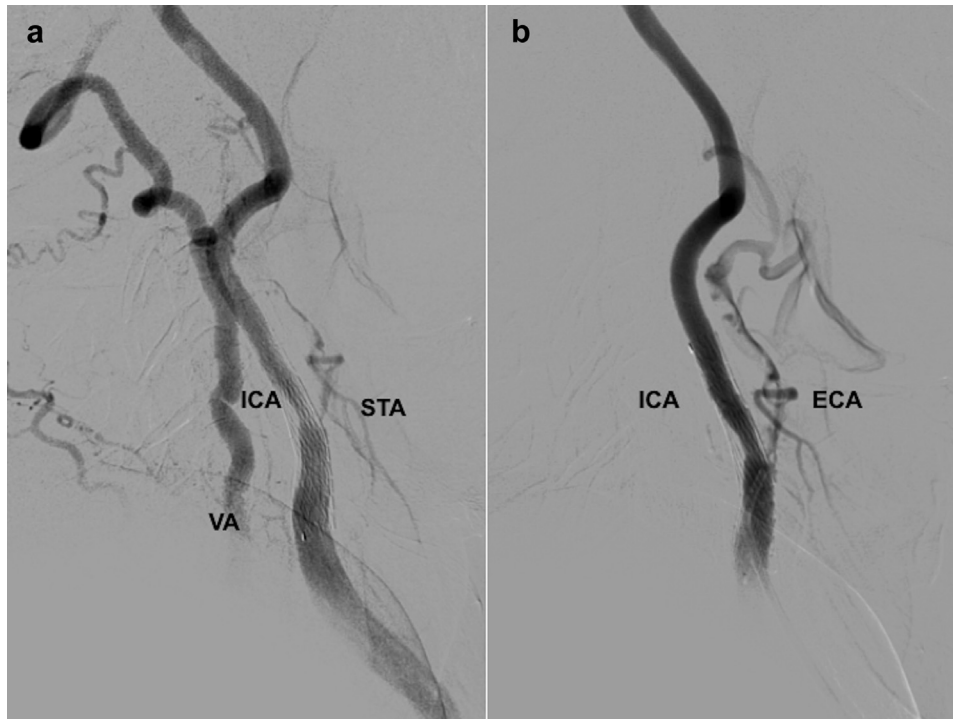


Fig 2. **a**, Selective right carotid arteriography. Complete occlusion of the right external carotid artery (ECA) with conserved patency of the superior thyroidal artery (STA) and partial intrastent restenosis of the internal carotid artery (ICA). VA, Vertebral artery. **b**, Initial partial recanalization of the ECA after local thrombolysis and passage of the 0.035-inch hydrophilic guidewire and diagnostic catheter across the stent cells.

12.5 mg daily, repaglinide three times a day, and acarbose 50 mg twice a day. On examination, blood pressure was 140/80 mm Hg, heart rate was 110 beats/min, and oxygen saturation was 98% on room air. DUS showed the patency of the right carotid axis with a mild intrastent restenosis and occlusion of the ECA. No absolute or relative contraindications to thrombolytic therapy were found.

Throughout femoral access, the right common carotid artery (CCA) was catheterized with a 5F diagnostic catheter; angiography confirmed occlusion of the ECA with a weak supply flow inversion, through the occipital artery by the homolateral vertebral artery (Fig 2, a). After some attempts to cross the ECA occlusion with microcatheters, the blockage was reopened by moving the diagnostic catheter and guidewire across the stent cells. A 6F guiding catheter (Neuron; Penumbra, Alameda, Calif) was then positioned close to the ECA's ostium, and by means of a 1.7F microcatheter (Excelsior SL-10; Stryker Neurovascular, Fremont, Calif), a bolus of 200,000 units of urokinase was injected (Fig 2, b). Angioplasty was then performed using a 2-mm-diameter × 20-mm-long microballoon catheter (Ultra-soft SV; Boston Scientific, Maple Grove, Minn), obtaining almost immediate relief from symptoms. The microcatheter was left in the ECA to allow continuous infusion of 50,000 IU/h urokinase and heparin 4000 IU for 12 hours and for final angiographic control (Fig 3, a). No complications occurred, and the postoperative course was uneventful. The patient was discharged fully asymptomatic (Fig 3, b) after 2 days of double antiplatelet therapy (aspirin 100 mg and clopidogrel 75 mg daily). At discharge and during quarterly DUS follow-up, we have reported right CCA

PSV of 80 cm/s, right internal carotid artery (ICA) PSV of 90 cm/s, right ICA/CCA PSV ratio of 1.12, and right ECA PSV of 150 cm/s with a residual thin layer of thrombus at its origin.

DISCUSSION

The ECA mainly supplies blood to the face, neck, tongue, maxilla, and scalp through a rich collateral network of side and terminating branches that together may ensure the half-face's blood supply when ECA occlusion occurs.³

Furthermore, the ECA is a fundamental contributor to the cerebral flow supply of the ipsilateral hemisphere in case of ICA steno-occlusion.⁴ ECA collateral circulation reduces or even cancels symptoms of cerebral ischemia, and guidelines have suggested that surgeons should also meticulously remove the plaque from the ECA's ostium, avoiding its occlusion.⁵

Stents are rapidly evolving, and CAS today competes with CEA as a treatment option for patients with carotid stenosis, considering the worldwide increase in the number of procedures performed. Nevertheless, the best management of carotid stenosis is still under discussion. Major concerns about CAS revolve around perioperative stent thrombosis and plaque embolization and intrastent restenosis as late complications.⁶

The fate of the ECA in CAS has always been considered a less important issue, notwithstanding its fundamental role in cerebral flow supply to the ipsilateral hemisphere.^{7,8}

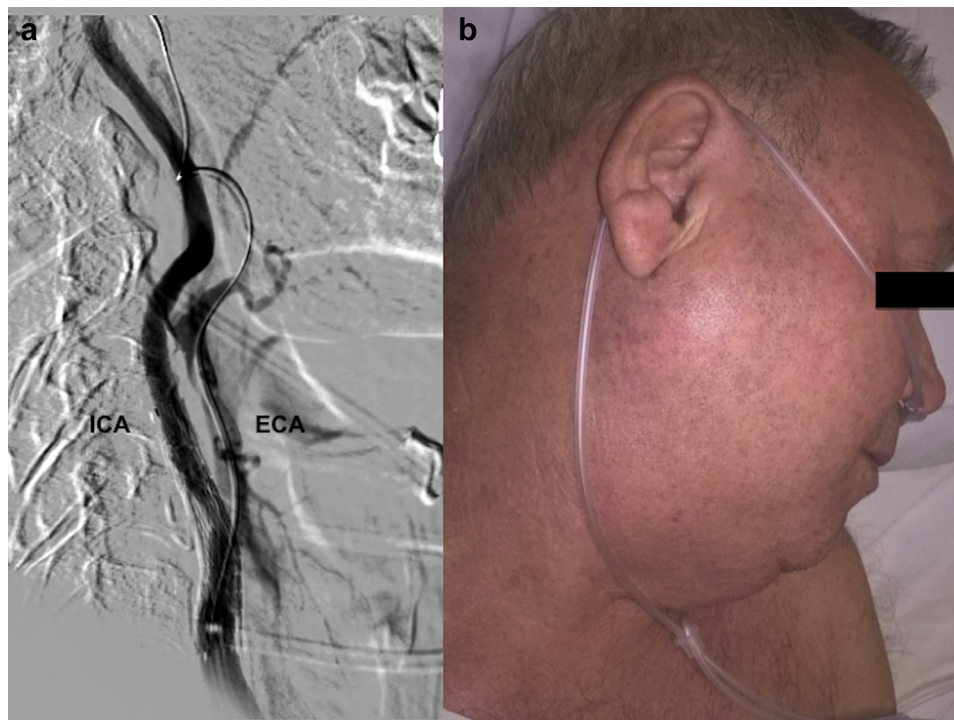


Fig 3. a, Final result after local thrombolysis and angioplasty of the external carotid artery (ECA). ICA, Internal carotid artery. **b,** Recovery from hemiface ischemia obtained after revascularization.

ECA thrombosis is most commonly observed when the plaque starts from the distal CCA and hence the stent needs to “jail” its origin, thereby reducing flow in the ECA, inducing conditions of low wall shear stress and promoting myointimal hyperplasia.^{9,10} Faster progression of atherosclerotic disease in the ipsilateral ECA after CAS compared with the contralateral one has been reported.¹¹ Other issues could be the lack of plaque debulking from the ECA’s ostium or pressure of atheromatous materials in the ECA during the stent’s deployment.^{12,13}

Thrombosis of the ECA usually develops asymptotically. Symptoms of the ECA’s occlusion typically are the masseter’s intermittent claudication after a few minutes of chewing food.¹³ Cold-triggered neck pain, facial pain, and cyanosis and necrosis of ear, preauricular region, and tongue have also been described.¹³⁻¹⁵

Late clinical complications of CAS related to ECA thrombosis have already been reported. Chen et al described a case of secondary severe malnutrition secondary to jaw claudication, treated by means of eversion CEA.¹ A few cases of iatrogenic facial ischemia after ECA thrombosis have been observed after procedures of arteriovenous malformation embolization,¹⁶ intra-arterial hyaluronic acid injection,¹⁷ or endodontic calcium hydroxide injection,¹⁸ but those complications always involved distal terminal branches of the ECA.

In the case reported here, the whole ECA, from its origin extending to all the collateral branches, was affected by thrombosis. Postoperative care has been free from complications for 5 years; the patient received appropriate aspirin

therapy, and no coagulopathies were observed. Moreover, collateral circulation had to be optimal, considering previous and still patent contralateral CEA. We opted for prompt ECA recanalization with local thrombolysis and angioplasty because of the fear of unpredictable outcomes, ranging from spontaneous recovery from ischemia, thanks to the uncertain collateral network’s development, to the prevented and more probable evolution toward tongue, hard palate, or hemifacial skin ischemia and necrosis. We preferred to keep the ECA’s endarterectomy with, at worst, “en bloc” stent removal, considered an alternative option in case of failure of thrombolysis or recurrences, given the high risk of arterial wall damage.

This report should be considered a caveat to all vascular specialists, in planning for CAS intervention and during follow-up, to perform a more careful analysis of preoperative localization of carotid plaque and the condition of the ECA. The current use of antiplatelet therapy after CAS is heterogeneous.^{19,20} It may be reasonable to suggest restarting of clopidogrel or even double antiplatelet therapy protection if thrombus growth or residual stenosis is observed in the ECA during DUS follow-up.

The authors acknowledge Edward Kiegle for his revision of English grammar.

REFERENCES

1. Chen H, Kougiyas P, Lin PH, Bechara CF. Jaw claudication in the era of carotid stenting. *J Vasc Surg* 2011;54:526-8.

2. Brott TG, Halperin JL, Abbara S, Bacharach JM, Barr JD, Bush RL, et al. 2011 ASA/ACCF/AHA/AANN/AANS/ACR/ASNR/CNS/SAIP/SCAI/SIR/SNIS/SVM/SVS guideline on the management of patients with extracranial carotid and vertebral artery disease: executive summary. *Stroke* 2011;42:420-63.
3. Lewis RR, Beasley MG, MacLean KS. Occlusion of external carotid artery causing intermittent claudication of the masseter. *Br Med J* 1978;2:1611.
4. Fearn SJ, Picton AJ, Mortimer AJ, Parry AD, McCollum CN. The contribution of the external carotid artery to cerebral perfusion in carotid disease. *J Vasc Surg* 2000;31:989-93.
5. Ricotta JJ, AbuRahma A, Ascher E, Eskandari M, Faries P, Lal BK. Updated Society for Vascular Surgery guidelines for management of extracranial carotid disease. *J Vasc Surg* 2011;54:1-31.
6. Roubin GS, New G, Iyer SS, Vitek JJ, Al-Mubarak N, Liu MW, et al. Immediate and late clinical outcomes of carotid artery stenting in patients with symptomatic and asymptomatic carotid artery stenosis: a 5-year prospective analysis. *Circulation* 2001;103:532-7.
7. CAVATAS Investigators. Endovascular versus surgical treatment in patients with carotid stenosis in the Carotid and Vertebral Artery Transluminal Angioplasty Study (CAVATAS): a randomised trial. *Lancet* 2001;357:1729-37.
8. Mantese VA, Timaran CH, Chiu D, Begg RJ, Brott TG. The carotid revascularization endarterectomy versus stenting trial (CREST): stenting versus carotid endarterectomy for carotid disease. *Stroke* 2010;41:S31-4.
9. Woo EY, Karmacharya J, Velazquez OC, Carpenter JP, Skelly CL, Fairman RM. Differential effects of carotid artery stenting versus carotid endarterectomy on external carotid artery patency. *J Endovasc Ther* 2007;14:208-13.
10. Hyun S, Kleinstreuer C, Archie JP Jr. Computational analysis of effects of external carotid artery flow and occlusion on adverse carotid bifurcation hemodynamics. *J Vasc Surg* 2003;37:1248-54.
11. Willfort-Ehringer A, Ahmadi R, Gruber D. Effect of stenting on the external carotid artery. *J Vasc Surg* 2003;38:1039-44.
12. De Borst GJ, Vos JA, Reichmann B, Hellings WE, De Vries JP, Suttorp MJ, et al. The fate of the external carotid artery after carotid artery stenting. A follow-up study with duplex ultrasonography. *Eur J Vasc Endovasc Surg* 2007;33:657-63.
13. Schiller A, Schwarz U, Schuknecht B, Mayer D, Hess K, Baumgartner RW. Successful treatment of cold-induced neck pain and jaw claudication with revascularization of severe atherosclerotic external carotid artery stenoses. *J Endovasc Ther* 2007;14:304-6.
14. Herishanu Y, Bendheim P, Dolberg M. External carotid occlusive disease as a cause of facial pain. *J Neurol Neurosurg Psychiatry* 1974;37:963-5.
15. Bjordahl PM, Ammar AD. Tongue necrosis as an unusual presentation of carotid artery stenosis. *J Vasc Surg* 2011;54:837-9.
16. Tarkan O, Sürmelioglu O, Tuncer U, Akgül E. Face skin necrosis following embolization for arteriovenous malformations: a case report. *Oral Maxillofac Surg* 2010;14:49-52.
17. Banh K. Facial ischemia after hyaluronic acid injection. *J Emerg Med* 2013;44:169-70.
18. Sharma S, Hackett R, Webb R, Macpherson D, Wilson A. Severe tissue necrosis following intra-arterial injection of endodontic calcium hydroxide: a case series. *Oral Surg Oral Med Oral Pathol Oral Radiol Endod* 2008;105:666-9.
19. Faught RW, Satti SR, Hurst RW, Pukenas BA, Smith MJ. Heterogeneous practice patterns regarding antiplatelet medications for neuroendovascular stenting in the USA: a multicenter survey. *J Neurointerv Surg* 2014;6:774-9.
20. Huibers A, Halliday A, Bulbulia B, Coppi G, de Borst GJ; ACST Collaborative Group. Antiplatelet therapy in carotid artery stenting and carotid endarterectomy in the Asymptomatic Carotid Surgery Trial-2. *Eur J Vasc Endovasc Surg* 2016;51:336-42.

Submitted Sep 28, 2016; accepted Dec 5, 2016.