

Tyrosine Kinase Receptor Expression in Canine Liposarcoma

Veterinary Pathology
2017, Vol. 54(2) 212-217
© The Author(s) 2016
Reprints and permission:
sagepub.com/journalsPermissions.nav
DOI: 10.1177/0300985816671379
journals.sagepub.com/home/vet



G. Avallone¹, V. Pellegrino¹, P. Roccabianca², E. Lepri³, L. Crippa⁴,
G. Beha¹, L. De Tolla⁵, and G. Sarli¹

Abstract

The expression of tyrosine kinase receptors is attracting major interest in human and veterinary oncological pathology because of their role as targets for adjuvant therapies. Little is known about tyrosine kinase receptor (TKR) expression in canine liposarcoma (LP), a soft tissue sarcoma. The aim of this study was to evaluate the immunohistochemical expression of the TKRs fibroblast growth factor receptor 1 (FGFR1) and platelet-derived growth factor receptor- β (PDGFR β); their ligands, fibroblast growth factor 2 (FGF2) and platelet-derived growth factor B (PDGFB); and c-kit in canine LP. Immunohistochemical labeling was categorized as high or low expression and compared with the mitotic count and MIB-1–based proliferation index. Fifty canine LPs were examined, classified, and graded. Fourteen cases were classified as well differentiated, 7 as myxoid, 25 as pleomorphic, and 4 as dedifferentiated. Seventeen cases were grade 1, 26 were grade 2, and 7 were grade 3. A high expression of FGF2, FGFR1, PDGFB, and PDGFR β was identified in 62% (31/50), 68% (34/50), 81.6% (40/49), and 70.8% (34/48) of the cases, respectively. c-kit was expressed in 12.5% (6/48) of the cases. Mitotic count negatively correlated with FGF2 ($R = -0.41$; $P < .01$), being lower in cases with high FGF2 expression, and positively correlated with PDGFR β ($R = 0.33$; $P < .01$), being higher in cases with high PDGFR β expression. No other statistically significant correlations were identified. These results suggest that the PDGFR β -mediated pathway may have a role in the progression of canine LP and may thus represent a promising target for adjuvant cancer therapies.

Keywords

canine, FGF2, liposarcoma, PDGFR β , soft tissue sarcoma, tyrosine kinase receptor

Canine liposarcoma (LP) is an uncommon soft tissue sarcoma that usually arises in the subcutis and of which several histological variants have been described: atypical lipoma, well-differentiated LP, myxoid LP, pleomorphic LP, and dedifferentiated LP.^{4,21,24} LP recurrence has been reported in up to 28% of cases, but metastases are rare.^{6,21} As for other soft tissue sarcomas (STSs), the main therapeutic option is surgical excision,³³ and the principal prognostic factors are completeness of surgical excision and histological grade.¹³

The expression of growth factors and growth factor receptors has been evaluated with a particular focus on tyrosine kinase–type receptors in several canine STSs to assess these molecules or the corresponding receptors as potential targets for adjunctive tumor therapy to reduce the recurrence rate.^{1,5,11,14,28}

The growth factors with tyrosine kinase receptors most commonly investigated in both human and veterinary medicine include vascular endothelial growth factor (VEGF), platelet-derived growth factor B (PDGFB), and fibroblast growth factor 2 (FGF2).^{1,5,9,11,14,28,36,42,47} In vitro studies have demonstrated that inhibition of the FGF2–fibroblast growth factor receptor 1 (FGFR1) pathway leads to a reduction of cell growth^{53,54} and inhibition of angiogenesis.³² Similarly, the inhibition of PDGF

receptors reduces proliferation, angiogenesis, and expression of antiapoptotic molecules.⁵¹ Human patients with STS have higher serum levels of FGF2 and VEGF compared with controls,^{20,45,46} while VEGF serum levels decrease in dogs with STS after STS resection.¹¹

The expression of FGF2, PDGFB, and the corresponding receptors FGFR1 and PDGF receptor- β (PDGFR β) has been described in several canine mesenchymal neoplasms, including vascular tumors,^{3,48,55} *Spirocerca lupi*–associated sarcoma,¹⁴ fibrosarcoma,⁴⁸ and perivascular wall tumors (PWTs).⁵

¹Department of Veterinary Medical Sciences (DIMEVET), University di Bologna, Ozzano dell'Emilia, Italy

²Department of Veterinary Medicine (DIMEVET), University of Milan, Milan, Italy

³Department of Veterinary Medicine, University of Perugia, Perugia, Italy

⁴Istovet, Besana Brianza, Italy

⁵Department of Pathology, School of Medicine, University of Maryland, Baltimore, MD, USA

Corresponding Author:

G. Avallone, via Tolara di Sopra 50, 40064, Ozzano dell'Emilia (BO), Italy.
Email: giancarlo.avallone@unibo.it

Table 1. List of Source, Type, and Dilution of Antibodies Applied to Canine Liposarcoma.

Antigen	Antibody	Type	Dilution	Source
FGF2	FGF2 (147): sc-79	Rabbit polyclonal	1:200	Santa Cruz Biotech
FGFR1	Flg (C-15): sc-121	Rabbit polyclonal	1:400	Santa Cruz Biotech
PDGFB	PDGF-B (N-30): sc-127	Rabbit polyclonal	1:200	Santa Cruz Biotech
PDGFR β	PDGFR β (958): sc-432	Rabbit polyclonal	1:100	Santa Cruz Biotech
Ki-67	MIB-1	Mouse monoclonal	1:600	Dako
c-kit	A4502	Rabbit polyclonal	1:200	Dako

FGF2, fibroblast growth factor 2; FGFR1, fibroblast growth factor receptor 1; PDGFB, platelet-derived growth factor B; PDGFR β , platelet-derived growth factor receptor- β .

Nevertheless, studies evaluating the expression of these molecules in canine LPs are lacking.

Another tyrosine kinase receptor whose expression has been investigated in both human and veterinary medicine is c-kit, which is the target for therapies in canine cancers such as mast cell tumors and is expressed in a small percentage of liposarcomas in humans.^{22,27}

The aim of this study was to evaluate the immunohistochemical expression of FGF2, FGFR1, PDGFB, PDGFR β , and c-kit in canine LP and to compare expression levels with the mitotic count and proliferation index to identify a putative role of these pathways in LP growth.

Materials and Methods

Case Selection and Diagnosis

Canine liposarcoma cases were selected from the caseload of a previous retrospective study⁴ and were classified according to a recent histological and immunohistochemical classification based on the following criteria:

- Atypical lipoma: a neoplasm composed of well-differentiated adipocytes and containing scattered atypical lipoblasts.²¹
- Well-differentiated LP: a neoplasm composed of round to polygonal cells arranged in solid sheets with little or no stromal collagen, in which most cells contain easily recognizable intracytoplasmic lipid droplets.^{19,24} Cases with intermediate histological appearance with pleomorphic LP were classified as well differentiated when positive for MDM2 by immunohistochemistry.⁴
- Pleomorphic LP: a neoplasm characterized by marked cellular pleomorphism, variable numbers of multinucleated neoplastic cells, and scarce to absent intracellular lipids.^{6,19,21,24} Cases with intermediate histological appearance with well-differentiated LP were classified as pleomorphic when negative for MDM2 by immunohistochemistry.⁴
- Myxoid LP: a neoplasm characterized by abundant background mucin resembling myxosarcoma, from which it is differentiated by the presence of cytoplasmic lipid-laden vacuoles and frequently containing a delicate anastomosing capillary vasculature.^{19,21,24}

- Dedifferentiated LP: a neoplasm characterized by areas of well-differentiated LP juxtaposed to areas of nonlipogenic sarcoma usually resembling a fibrosarcoma or undifferentiated pleomorphic sarcoma.^{4,16,18}

Cases were graded according to the standard grading system applied to canine STS.¹³ Mitotic count was evaluated in 10 high-power fields equating the standard area of 2.37 mm².³⁸

Immunohistochemistry

Three-micrometer-thick sections were dewaxed and rehydrated. Endogenous peroxidase was blocked by immersion in H₂O₂ 3% in methanol for 30 minutes. For antigen retrieval, sections were immersed in 200 ml citrate buffer (pH 6.0); heated in a microwave oven at 750 W for two 5-minute cycles for c-kit (Dako, Glostrup, Denmark), FGF2, FGFR1, PDGFB, and PDGFR β (Santa Cruz Biotech, Santa Cruz, CA) and 4 cycles for Ki-67 (Dako); and cooled at room temperature for approximately 20 minutes. Source, type, and dilution of antibodies applied to canine LP are listed in Table 1.

The reaction was amplified by the avidin-biotin method (ABC kit elite; Vector, Burlingame, CA) and visualized with 3,3'-diaminobenzidine (0.04% for 4 minutes). Sections were counterstained with Papanicolaou hematoxylin, rinsed in tap water, dehydrated, and coverslipped. Sections of granulation tissue were used as positive controls for FGF2, FGFR1, PDGFB, and PDGFR β , and sections of canine hyperplastic lymph node were used as positive controls for Ki-67. Negative controls comprised slides incubated with omission of the primary antibody. Expression of FGF2, FGFR1, PDGFB, and PDGFR β was scored in a semiquantitative manner, examining the entire sample at intermediate magnification (200 \times), and assessing the percentage of positive neoplastic cells. FGF2, FGFR1, PDGFB, and PDGFR β were considered highly expressed if labeling was present in more than 70% of neoplastic cells as previously reported.⁵ Variation of the intensity of the labeling within a sample and labeling of stroma were recorded but not included in the scoring system. Expression of c-kit was classified as positive or negative as previously reported.^{23,27} Ki-67 expression was evaluated as previously reported.⁴

Statistical Analysis

Data were analyzed with Shapiro and Wilk's *W* test for normality. Because data did not fit a normal distribution, the Spearman test was used to compare the grade, mitotic count, and Ki-67 labeling index of the group with high expression versus low expression of FGF2, FGFR1, PDGFB, and PDGFR β and of the group of c-kit positive and negative. A conventional 5% level was used to define statistical significance.

Results

Fifty canine liposarcomas were collected. No atypical lipoma was diagnosed, 14 cases were classified as well differentiated LP, 7 as myxoid LP, 25 as pleomorphic LP, and 4 as dedifferentiated LP. All dedifferentiated liposarcomas were characterized by dedifferentiated areas resembling high-grade fibrosarcoma. Seventeen cases were grade 1, 26 were grade 2, and 7 were grade 3. Mitotic count ranged between 1 and 56 (median, 5), and Ki-67 labeling index ranged between 1.1% and 76.8% (median, 14.9%).

High expression of FGF2 and FGFR1 was identified in 31 cases (62%) (Fig. 1) and 34 cases (68%) (Fig. 2), respectively, and FGF2 low expression in 38% of cases (Fig. 3). PDGFB, PDGFR β , and c-kit expression was not evaluated in 1, 2, and 2 cases, respectively, because of insufficient material in the original blocks. Therefore, PDGFB expression was assessed in 49 cases and PDGFR β and c-kit expression in 48 cases. High PDGFB and PDGFR β expression was identified in 40 cases (82%) (Fig. 4) and 34 cases (71%) (Fig. 5), respectively, and PDGFR β low expression in 38% of cases (Fig. 6). Six cases (13%) were c-kit positive and 42 (87%) were negative. The data regarding the expression of FGF2, FGFR1, PDGFB, PDGFR β , and c-kit in canine liposarcomas are listed in Table 2.

For all markers evaluated, the labeling of neoplastic cells was cytoplasmic in all cases. Occasionally, labeling intensity varied among cells within the same tumor (Fig. 5). Stromal tissue was negative for all markers in all cases (Fig. 1).

Mitotic count negatively correlated with FGF2 ($R = -0.41$; $P < .01$), being lower in cases with high FGF2 expression, and positively correlated with PDGFR β ($R = 0.33$; $P < .01$), being higher in cases with high PDGFR β expression. No other statistically significant correlations were identified.

Discussion

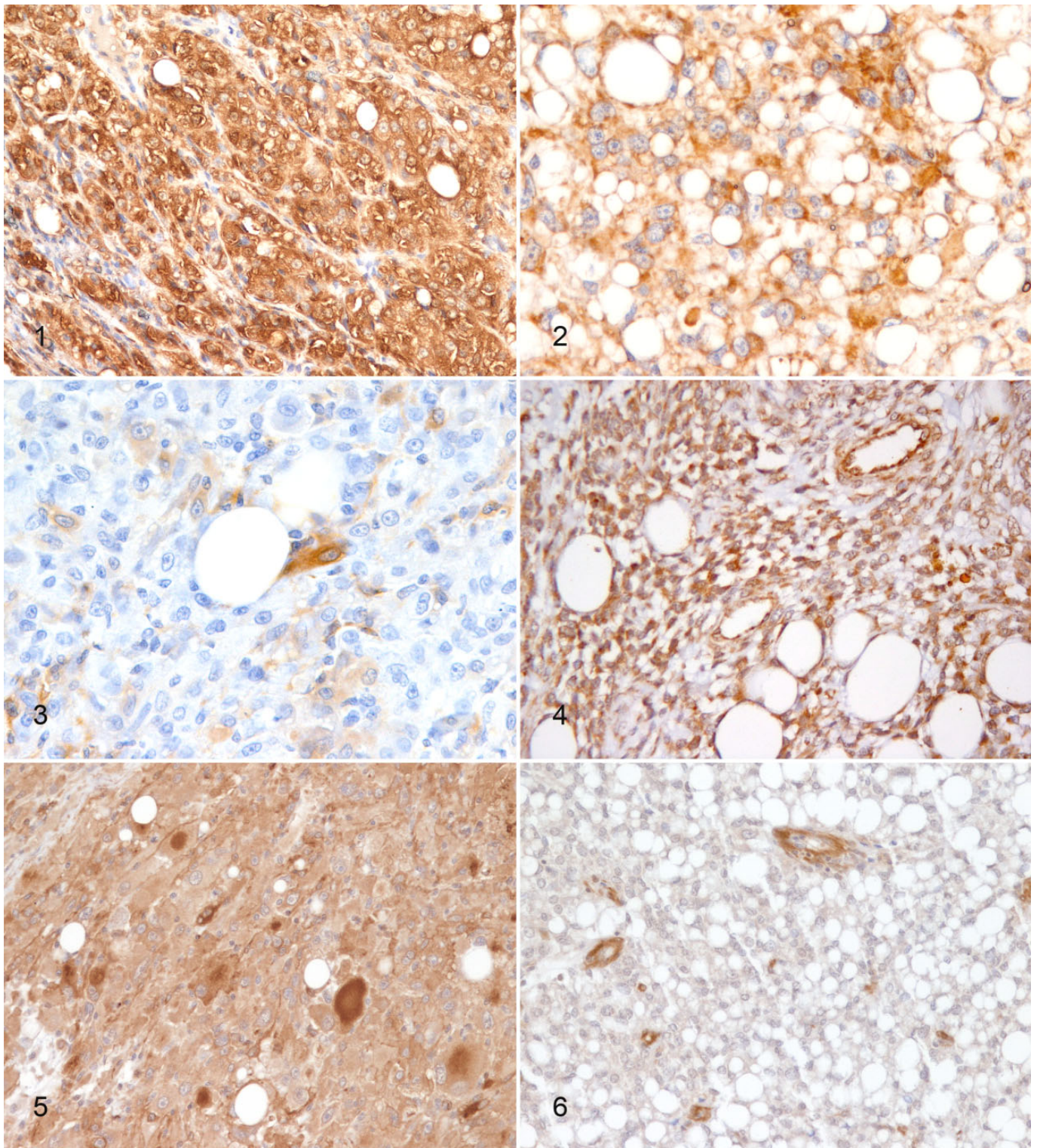
This study detected expression of tyrosine kinase receptors FGFR1 and PDGFR β and their ligands FGF2 and PDGFB in canine LPs. Most LPs examined were characterized by high FGF2 expression, chiefly in well-differentiated and pleomorphic LP histotypes. FGF2 expression has been reported in several canine neoplasms, including epithelial tumors such as prostatic carcinoma,⁴¹ endocrine and thyroid carcinoma,⁴³ and mesenchymal neoplasms such as hemangiosarcoma⁵⁵ and fibrosarcoma.¹⁴ FGF2 expression has also been investigated

in human STS where FGF2 plasma levels were higher than in healthy controls.^{20,45,46} All these data suggest that FGF2 may have a role in the occurrence and progression of several tumor types in both humans and dogs. Interest in FGF2 expression in cancer is linked to its putative target role for therapies using thalidomide, which has been demonstrated to inhibit FGF2-induced angiogenesis¹⁰ and to be effective in the treatment of multiple myeloma^{7,44,50} and has been tested in other solid tumors in humans.³¹

Nevertheless, studies evaluating the prognostic impact of FGF2 have been contradictory: some studies report high FGF2 expression in neoplastic cells associated with a high proliferation rate and negative prognosis,^{8,30,39} whereas others have identified a correlation between high FGF2 plasma levels and a low risk of recurrence.^{20,45} These inconsistent findings have been explained hypothesizing that tumors using the FGF2 pathway might intrinsically have a less aggressive behavior⁵⁶ and that other more efficient pathways may induce cell proliferation in cases with a low FGF2 expression.³⁰ The same hypotheses may also explain the negative correlation observed in this work for canine LPs between high FGF2 expression and a lower mitotic count. This finding suggests that this pathway may be less efficient in inducing the proliferation of canine LP neoplastic cells, thus leading to a lower mitotic count in cases where FGF2 is highly expressed.

Most cases also highly expressed FGFR1, paralleling previous studies that identified expression of this receptor in canine mesenchymal tumors such as hemangiosarcoma⁵⁵ and PWTs,⁵ as well as in canine liposarcoma and fibrosarcoma cell lines.⁴⁸ Nevertheless, FGFR1 was not correlated with mitotic count or the proliferation index in our study. This additional finding suggests that the FGF2-FGFR1 pathway is not relevant in the pathogenesis of canine LP. Likewise, c-kit does not seem to be primarily involved in stimulating cell proliferation since it was expressed in only a minority of canine liposarcomas, paralleling data reported in humans,²⁷ and a correlation with mitotic count and/or with Ki-67 labeling index was not evidenced.

By contrast, the PDGFB-PDGFR β pathway seems to have a central role in canine LP progression. Both these molecules had greater expression than FGF2 and FGFR1, with high expression in more than 70% of the canine LPs tested. PDGF-PDGFR β pathway expression has been demonstrated in several types of neoplasms, both in humans and dogs,³ as it occurs in thyroid carcinoma,³⁴ glioma,⁵⁷ and renal cell carcinoma⁴⁹ in humans and in cutaneous and subcutaneous mast cell tumor⁵² and lymphoma² in dogs. PDGFB and PDGFR β expression has also been described in mesenchymal neoplasms in several species, including canine hemangiosarcoma³ and PWTs,⁵ feline injection site sarcoma,²⁹ and several STSs in humans, including dermatofibrosarcoma protuberans,³⁶ malignant peripheral nerve sheath tumor,⁴² solitary fibrous tumor,¹² smooth muscle cell tumors,⁴⁰ and liposarcoma.^{25,40} Interestingly, in most of the cases examined in this study, neoplastic cells expressed both PDGFB and PDGFR β while stromal tissue was consistently negative, thus suggesting an autocrine rather than



Figures 1–6. Liposarcomas, dog, subcutis; immunohistochemistry. **Figure 1.** High fibroblast growth factor 2 (FGF2) expression in a canine pleomorphic liposarcoma characterized by a diffuse and intense cytoplasmic labeling. Stromal tissue is negative. **Figure 2.** High fibroblast growth factor receptor 1 (FGFR1) expression in a canine well-differentiated liposarcoma characterized by a diffuse and intense cytoplasmic labeling. **Figure 3.** Low FGF2 expression in a canine pleomorphic liposarcoma. Only a small number of neoplastic cells express FGF2. **Figure 4.** High platelet-derived growth factor B (PDGFB) expression in a canine dedifferentiated liposarcoma characterized by a diffuse and intense cytoplasmic labeling evident also in the endothelium of intraneoplastic blood vessels (positive internal control). **Figure 5.** High platelet-derived growth factor receptor- β (PDGFR β) expression in a canine pleomorphic liposarcoma characterized by a diffuse and intense cytoplasmic labeling. The intensity of the labeling is variable among the neoplastic cells. **Figure 6.** Low PDGFR β expression in a canine well-differentiated liposarcoma. Note the positively stained mural cells in intraneoplastic blood vessels (positive internal control).

Table 2. Immunohistochemical Expression of FGF2, FGFR1, PDGFB, PDGFR β , and c-kit in Canine Liposarcoma.

	FGF2, n (%)		FGFR1, n (%)		PDGFB, n (%)		PDGFR β , n (%)		c-kit, n (%)	
	High	Low	High	Low	High	Low	High	Low	Positive	Negative
Total (n = 50) ^a	31 (62)	19 (38)	34 (68)	16 (32)	40 (82)	9 (18)	34 (71)	14 (29)	6 (13)	42 (87)
WDL (n = 14)	10 (71)	4 (29)	11 (79)	3 (21)	12 (86)	2 (14)	8 (57)	6 (43)	1 (7)	13 (93)
ML (n = 7)	2 (29)	5 (71)	4 (57)	3 (43)	5 (71)	2 (29)	6 (86)	1 (14)	2 (29)	5 (71)
PL (n = 25) ^a	19 (76)	6 (24)	16 (64)	9 (36)	21 (84)	4 (16)	17 (71)	7 (29)	2 (8)	22 (92)
DDL (n = 4) ^a	0 (0)	4 (100)	3 (75)	1 (25)	2 (67)	1 (33)	3 (100)	0 (0)	1 (33)	2 (67)

DDL, dedifferentiated liposarcoma; FGF2, fibroblast growth factor 2; FGFR1, fibroblast growth factor receptor 1; ML, myxoid liposarcoma; PDGFB, platelet-derived growth factor B; PDGFR β , platelet-derived growth factor receptor- β ; PL, pleomorphic liposarcoma; WDL, well-differentiated liposarcoma.

^aTotal, n = 49 for PDGFB and 48 for PDGFR β and c-kit; PL, n = 24 for PDGFR β and c-kit; DDL, n = 3 for PDGFB, PDGFR β , and c-kit.

paracrine pathway for canine LP. Furthermore, our results suggest that the PDGF-PDGFR β pathway may play a central role in the progression of canine LP, since the cases with high PDGFR β expression had a significantly higher mitotic count. This finding is particularly interesting as PDGFR β is a target for therapies in canine mast cell tumors,²² osteosarcoma,^{15,35} and epitheliotropic lymphoma.²⁶

Furthermore, the application of a multitargeted tyrosine kinase receptor inhibitor has been demonstrated to reduce STS growth in a murine model by reducing both the proliferation of neoplastic cells and angiogenesis.⁵⁶ Therefore, these therapies might provide a further option for the treatment of STSs after marginal/incomplete resection, a circumstance leading to a high risk of recurrence¹³ that is usually managed with radiation therapy.^{17,37} Further studies are needed to confirm the role of the PDGF-PDGFR β pathway in the growth or progression of canine LP and to assess the efficacy of anti-tyrosine kinase therapy.

Surprisingly, the positive correlation between mitotic count and PDGFR β and the negative correlation between mitotic count and FGF2 were not paralleled by similar correlations with the Ki-67 labeling index. These data should be confirmed by the evaluation of a larger caseload.

Summarizing, we have identified the expression of 2 tyrosine kinase receptor-mediated pathways in canine LP: FGF2-FGFR1 and PDGFB-PDGFR β . PDGFB-PDGFR β expression seems to be strictly involved in neoplastic cell proliferation and therefore represents the most promising target for specific therapies.

Acknowledgements

We thank A. Collins for editing the English text.

Declaration of Conflicting Interests

The author(s) declared no potential conflicts of interest with respect to the research, authorship, and/or publication of this article.

Funding

The author(s) received no financial support for the research, authorship, and/or publication of this article.

References

1. Al-Dissi AN, Haines DM, Singh B, et al. Immunohistochemical expression of vascular endothelial growth factor and vascular endothelial growth factor receptor in canine cutaneous fibrosarcomas. *J Comp Pathol.* 2009;**141**:229–236.
2. Aricò A, Guadagnin E, Ferraresso S, et al. Platelet-derived growth factors and receptors in canine lymphoma. *J Comp Pathol.* 2014;**151**(4):322–328.
3. Asa SA, Murai A, Murakami M, et al. Expression of platelet-derived growth factor and its receptors in spontaneous canine hemangiosarcoma and cutaneous hemangioma. *Histol Histopathol.* 2012;**27**(5):601–607.
4. Avallone G, Roccabianca P, Crippa L, et al. Histological classification and immunohistochemical evaluation of MDM2 and CDK4 expression in canine liposarcoma. *Vet Pathol.* 2016;**53**(4):773–780.
5. Avallone G, Stefanello D, Boracchi P, et al. Growth factors and COX2 expression in canine perivascular wall tumors. *Vet Pathol.* 2015;**52**(6):1034–1040.
6. Baez JL, Hendrick MJ, Shofer FS, et al. Liposarcomas in dogs: 56 cases (1989–2000). *J Am Vet Med Assoc.* 2004;**224**:887–891.
7. Barlogie B, Desikan R, Eddlemon P, et al. Extended survival in advanced and refractory multiple myeloma after single-agent thalidomide: identification of prognostic factors in a phase 2 study of 169 patients. *Blood.* 2001;**98**:492–494.
8. Brattström D, Bergqvist M, Larsson A, et al. Basic fibroblast growth factor and vascular endothelial growth factor in sera from non-small cell lung cancer patients. *Anticancer Res.* 1998;**18**(2A):1123–1127.
9. Cheng X, Yang G, Schmeler KM, et al. Recurrence patterns and prognosis of endometrial stromal sarcoma and the potential of tyrosine kinase-inhibiting therapy. *Gynecol Oncol.* 2011;**121**(2):323–327.
10. D'Amato RJ, Loughnan MS, Flynn E, et al. Thalidomide is an inhibitor of angiogenesis. *Proc Natl Acad Sci U S A.* 1994;**91**(9):4082–4085.
11. de Queiroz GF, Dagli ML, Fukumasu H, et al. Vascular endothelial growth factor expression and microvascular density in soft tissue sarcomas in dogs. *J Vet Diagn Invest.* 2010;**22**(1):105–108.
12. Demicco EG, Wani K, Fox PS, et al. Histologic variability in solitary fibrous tumors reflects angiogenic and growth factor signaling pathway alterations. *Hum Pathol.* 2015;**46**(7):1015–1026.
13. Dennis MM, McSpornan KD, Bacon NJ, et al. Prognostic factors for cutaneous and subcutaneous soft tissue sarcomas in dogs. *Vet Pathol.* 2011;**48**:73–84.
14. Dvir E, Clift SJ. Evaluation of selected growth factor expression in canine spirocercosis (*Spirocerca lupi*)-associated non-neoplastic nodules and sarcomas. *Vet Parasitol.* 2010;**174**(3–4):257–266.
15. Fahey CE, Milner RJ, Kow K, et al. Apoptotic effects of the tyrosine kinase inhibitor, masitinib mesylate, on canine osteosarcoma cells. *Anticancer Drugs.* 2013;**24**(5):519–526.
16. Fletcher CDM, Bridge JA, Hogendoorn PCW, et al. *WHO Classification of Tumours of Soft Tissue and Bone: Pathology and Genetics of Tumours of Soft Tissue and Bone.* 4th ed. Lyon, France: IARC Press; 2013.
17. Forrest LJ, Chun R, Adams WM, et al. Postoperative radiotherapy for canine soft tissue sarcoma. *J Vet Intern Med.* 2000;**14**:578–582.

18. Goldblum JR, Folpe AL, Weiss SW. Liposarcoma. In: Goldblum JR, Folpe AL, Weiss SW, eds. *Enzinger and Weiss's Soft Tissue Tumors*. 6th ed. Philadelphia, PA: Elsevier Saunders; 2014:484–522.
19. Goldschmidt MH, Hendrick MJ. Tumors of the skin and soft tissues. In: Meuten DJ, ed. *Tumors in Domestic Animals*. 4th ed. Ames: Iowa State Press; 2002:84–102.
20. Graeven U, Andre N, Achilles E, et al. Serum levels of vascular endothelial growth factor and basic fibroblast growth factor in patients with soft-tissue sarcoma. *J Cancer Res Clin Oncol*. 1999;**125**(10):577–581.
21. Gross TL, Ihrke PJ, Walder EJ, et al. Lipocytic tumors. In: Gross TL, Ihrke PJ, Walder EJ, et al, eds. *Skin Diseases of the Dog and Cat: Clinical and Histopathologic Diagnosis*. 2nd ed. Oxford, UK: Blackwell Science; 2005:766–777.
22. Hahn KA, Ogilvie G, Rusk T, et al. Masitinib is safe and effective for the treatment of canine mast cell tumors. *J Vet Intern Med*. 2008;**22**(6):1301–1309.
23. Hayes S, Yuzbasiyan-Gurkan V, Gregory-Bryson E, et al. Classification of canine nonangiogenic, nonlymphogenic, gastrointestinal sarcomas based on microscopic, immunohistochemical, and molecular characteristics. *Vet Pathol*. 2013;**50**(5):779–788.
24. Hendrick MJ, Mahaffey EA, Moore FM, et al. *Histological Classification of Mesenchymal Tumors of Skin and Soft Tissues of Domestic Animals*. 2nd series, Vol II. Washington, DC: Armed Forces Institute of Pathology; 1998.
25. Hoffman A, Ghadimi MP, Demicco EG, et al. Localized and metastatic myxoid/round cell liposarcoma: clinical and molecular observations. *Cancer*. 2013;**119**(10):1868–1877.
26. Holtermann N, Kiupel M, Kessler M, et al. Masitinib monotherapy in canine epitheliotropic lymphoma. *Vet Comp Oncol*. 2016;**14**(suppl 1):127–135.
27. Jung I, Gurzu S, Turdean S, et al. Relationship of endothelial area with VEGF-A, COX-2, maspin, c-KIT, and DOG-1 immunoreactivity in liposarcomas versus non-lipomatous soft tissue tumors. *Int J Clin Exp Pathol*. 2015;**8**(2):1776–1782.
28. Kamstock D, Elmslie R, Thamm D, et al. Evaluation of a xenogeneic VEGF vaccine in dogs with soft tissue sarcoma. *Cancer Immunol Immunother*. 2007;**56**(8):1299–1309.
29. Katayama R, Huelsmeyer MK, Marr AK, et al. Imatinib mesylate inhibits platelet-derived growth factor activity and increases chemosensitivity in feline vaccine-associated sarcoma. *Cancer Chemother Pharmacol*. 2004;**54**(1):25–33.
30. Kilvaer TK, Valkov A, Sorbye SW, et al. Fibroblast growth factor 2 orchestrates angiogenic networking in non-GIST STS patients. *J Transl Med*. 2011;**9**:104.
31. Kumar S, Witzig TE, Rajkumar SV. Thalidomid: current role in the treatment of non-plasma cell malignancies. *J Clin Oncol*. 2004;**22**(12):2477–2488.
32. Lee HJ, Kim SA, Lee HJ, et al. Paeonol oxime inhibits bFGF-induced angiogenesis and reduces VEGF levels in fibrosarcoma cells. *PLoS One*. 2010;**5**(8):e12358.
33. Liptak JM, Forrest LJ. Soft tissue sarcomas. In: Withrow SJ, Vail DM, Page RL, eds. *Withrow and MacEwen's Small Animal Clinical Oncology*. 5th ed. St Louis, MO: Elsevier Sanders; 2013:356–380.
34. Mancikova V, Inglada-Pérez L, Curras-Freixes M, et al. VEGF, VEGFR3, and PDGFRB protein expression is influenced by RAS mutations in medullary thyroid carcinoma. *Thyroid*. 2014;**24**(8):1251–1255.
35. Maniscalco L, Iussich S, Morello E, et al. PDGFs and PDGFRs in canine osteosarcoma: new targets for innovative therapeutic strategies in comparative oncology. *Vet J*. 2013;**195**(1):41–47.
36. McCarthy CJ, O'Brien GC, Cummins RJ, et al. GIST with a twist-upregulation of PDGF-B resulting in metachronous gastrointestinal stromal tumor and dermatofibrosarcoma protuberans. *J Gastrointest Surg*. 2009;**14**(2):398–403.
37. McKnight JA, Mauldin GN, McEntee MC, et al. Radiation treatment for incompletely resected soft-tissue sarcomas in dogs. *J Am Vet Med Assoc*. 2000;**217**:205–210.
38. Meuten DJ, Moore FM, George JW. Mitotic count and the field of view area: time to standardize. *Vet Pathol*. 2016;**53**(1):7–9.
39. Obermair A, Speiser P, Reisenberger K, et al. Influence of intratumoral basic fibroblast growth factor concentration on survival in ovarian cancer patients. *Cancer Lett*. 1998;**130**(1–2):69–76.
40. Palman C, Bowen-Pope DF, Brooks JJ. Platelet-derived growth factor receptor (beta-subunit) immunoreactivity in soft tissue tumors. *Lab Invest*. 1992;**66**(1):108–115.
41. Palmieri C. Immunohistochemical expression of angiogenic factors by neoplastic epithelial cells is associated with canine prostatic carcinogenesis. *Vet Pathol*. 2015;**52**(4):607–613.
42. Perrone F, Da Riva L, Orsenigo M, et al. PDGFRA, PDGFRB, EGFR, and downstream signaling activation in malignant peripheral nerve sheath tumor. *Neuro Oncol*. 2009;**11**(6):725–736.
43. Pessina P, Castillo V, Sartore V, et al. Semiquantitative immunohistochemical marker staining and localization in canine thyroid carcinoma and normal thyroid gland. *Vet Comp Oncol*. 2016;**14**(3):e102–e112.
44. Rajkumar SV, Fonseca R, Dispenzieri A, et al. Thalidomide in the treatment of relapsed multiple myeloma. *Mayo Clin Proc*. 2000;**75**:897–902.
45. Ruka W, Rutkowski P, Kaminska J, et al. Alterations of routine blood tests in adult patients with soft tissue sarcomas: relationships to cytokine serum levels and prognostic significance. *Ann Oncol*. 2001;**12**(10):1423–1432.
46. Rutkowski P, Kaminska J, Kowalska M, et al. Cytokine serum levels in soft tissue sarcoma patients: correlations with clinico-pathological features and prognosis. *Int J Cancer*. 2002;**100**(4):463–471.
47. Sancu M, Dikis C, Inan S, et al. Immunolocalization of VEGF, VEGF receptors, EGF-R and Ki-67 in leiomyoma, cellular leiomyoma and leiomyosarcoma. *Acta Histochem*. 2011;**113**(3):317–325.
48. Schweiger N, Hauck M, Steinhoff H, et al. Canine and human sarcomas exhibit predominant FGFR1 expression and impaired viability after inhibition of signaling. *Mol Carcinog*. 2014;**54**(9):841–852.
49. Shim M, Song C, Park S, et al. Prognostic significance of platelet-derived growth factor receptor- β expression in localized clear cell renal cell carcinoma. *J Cancer Res Clin Oncol*. 2015;**141**(12):2213–2220.
50. Singhal S, Mehta J, Desikan R, et al. Antitumor activity of thalidomide in refractory multiple myeloma. *N Engl J Med*. 1999;**341**:1565–1571.
51. Taeger J, Moser C, Hellerbrand C, et al. Targeting FGFR/PDGFR/VEGFR impairs tumor growth, angiogenesis, and metastasis by effects on tumor cells, endothelial cells, and pericytes in pancreatic cancer. *Mol Cancer Ther*. 2011;**10**(11):2157–2167.
52. Thompson JJ, Morrison JA, Pearl DL, et al. Receptor tyrosine kinase expression profiles in canine cutaneous and subcutaneous mast cell tumors. *Vet Pathol*. 2016;**53**(3):545–558.
53. Valesky M, Spang AJ, Fisher GW, et al. Noninvasive dynamic fluorescence imaging of human melanomas reveals that targeted inhibition of bFGF or FGFR-1 in melanoma cells blocks tumor growth by apoptosis. *Mol Med*. 2002;**8**(2):103–112.
54. Wang LL, Li JJ, Zheng ZB, et al. Antitumor activities of a novel indolin-2-ketone compound, Z24: more potent inhibition on bFGF-induced angiogenesis and bcl-2 over-expressing cancer cells. *Eur J Pharmacol*. 2004;**502**(1–2):1–10.
55. Yonemaru K, Sakai H, Murakami M, et al. Expression of vascular endothelial growth factor, basic fibroblast growth factor, and their receptors (Flt-1, Flk-1, and Flg-1) in canine vascular tumors. *Vet Pathol*. 2006;**43**:971–980.
56. Yoon SS, Stangenberg L, Lee YJ, et al. Efficacy of sunitinib and radiotherapy in genetically engineered mouse model of soft-tissue sarcoma. *Int J Radiat Oncol Biol Phys*. 2009;**74**(4):1207–1216.
57. Zhang J, Chen T, Mao Q, et al. PDGFR- β -activated ACK1-AKT signaling promotes glioma tumorigenesis. *Int J Cancer*. 2015;**136**(8):1769–1780.