

Autofluorescence bronchoscopy in lung transplantation.

Mario Nosotti*, Rosaria Carrinola*, Lorenzo Rosso*, Alessandro Palleschi*, Valeria Rossetti°, Letizia Morlacchi°
 *Thoracic Surgery and Lung Transplantation Unit, °Respiratory Medicine Unit
 Fondazione Cà Granda Ospedale Maggiore Policlinico, Milano, Italy

Background 1

Despite little is known about airway perfusion in the early period after lung transplantation, central bronchial stenosis is attributed to poor vascularization.

Background 2

Autofluorescence bronchoscopy was developed to discover preinvasive lesions, based on the fact that dysplasia shows less fluorescence than normal tissue when excited by blue light. Despite some questions about the origin of autofluorescence are left, the presence of good vascularization seems to be crucial.

Study aim

The aim of the present study was to evaluate the bronchial mucosa modification after lung transplantation by autofluorescence bronchoscopy.

Methods 1

- Consecutive patients receiving single or double lung transplantations were included.
- Patients requiring separate lung ventilation, long stay in the intensive care unit and/or in rehabilitation centers were excluded.
- The autofluorescence procedures, conducted with EVIS Lucera Spectrum AFI Olympus bronchoscope, were associated with planned bronchoscopic surveillance and transbronchial biopsies.
- Typical schedule included a bronchoscopy every seven days up to the 30th postoperative day followed by a procedure every three months to reach the twelve month follow-up

Methods 2

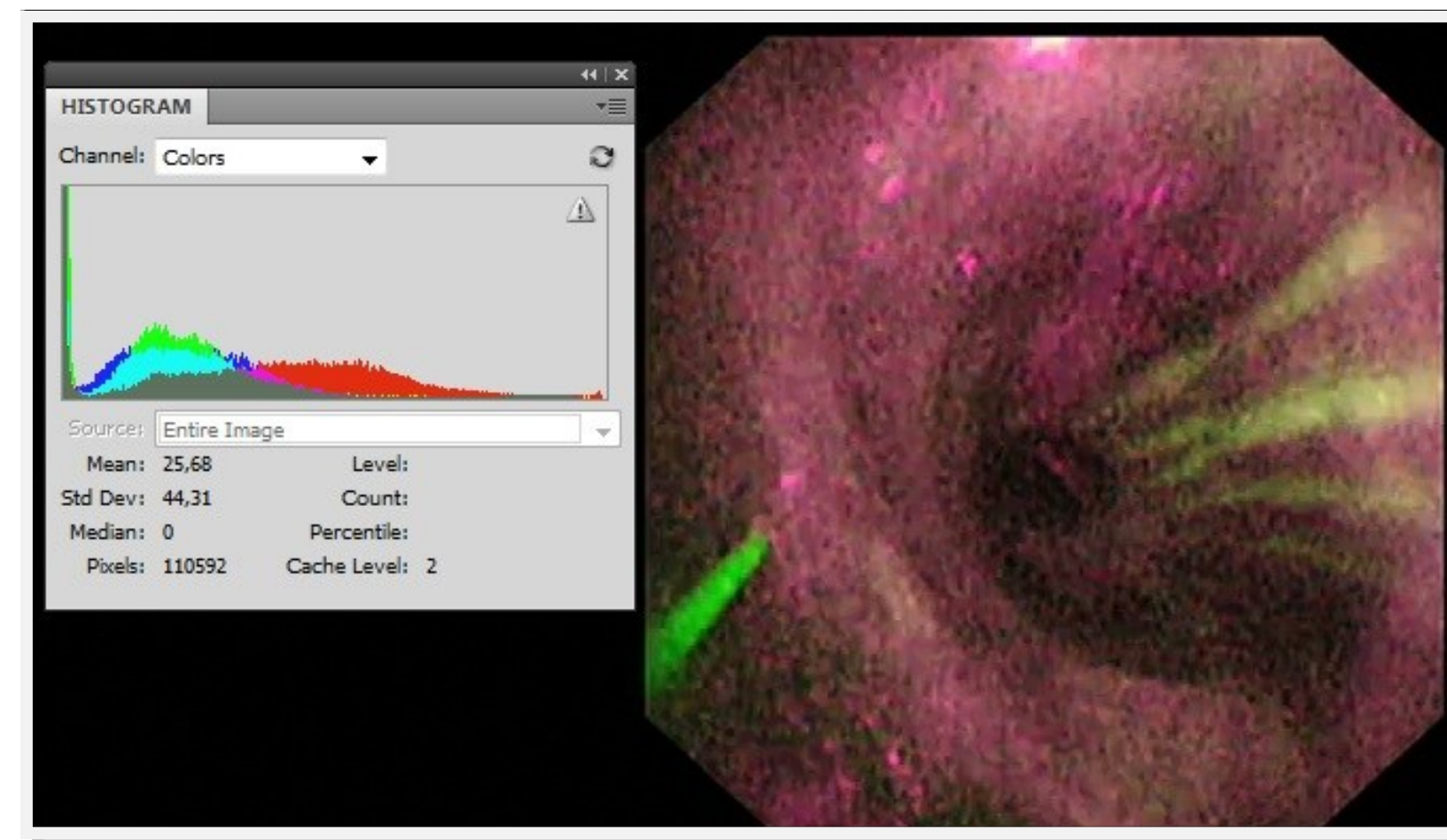
- The autofluorescence bronchoscopies were recorded and pictures of the first bronchial bifurcations were analyzed with color histograms.
- Bright pink color was typical of ischemic mucosa
- Deep green was characteristic for normal mucosa
- The red and green intensity ratio (R/G) was used to grade the pictures.
- Total graft ischemic time and bronchial complication were correlated with the autofluorescence grading.

Results

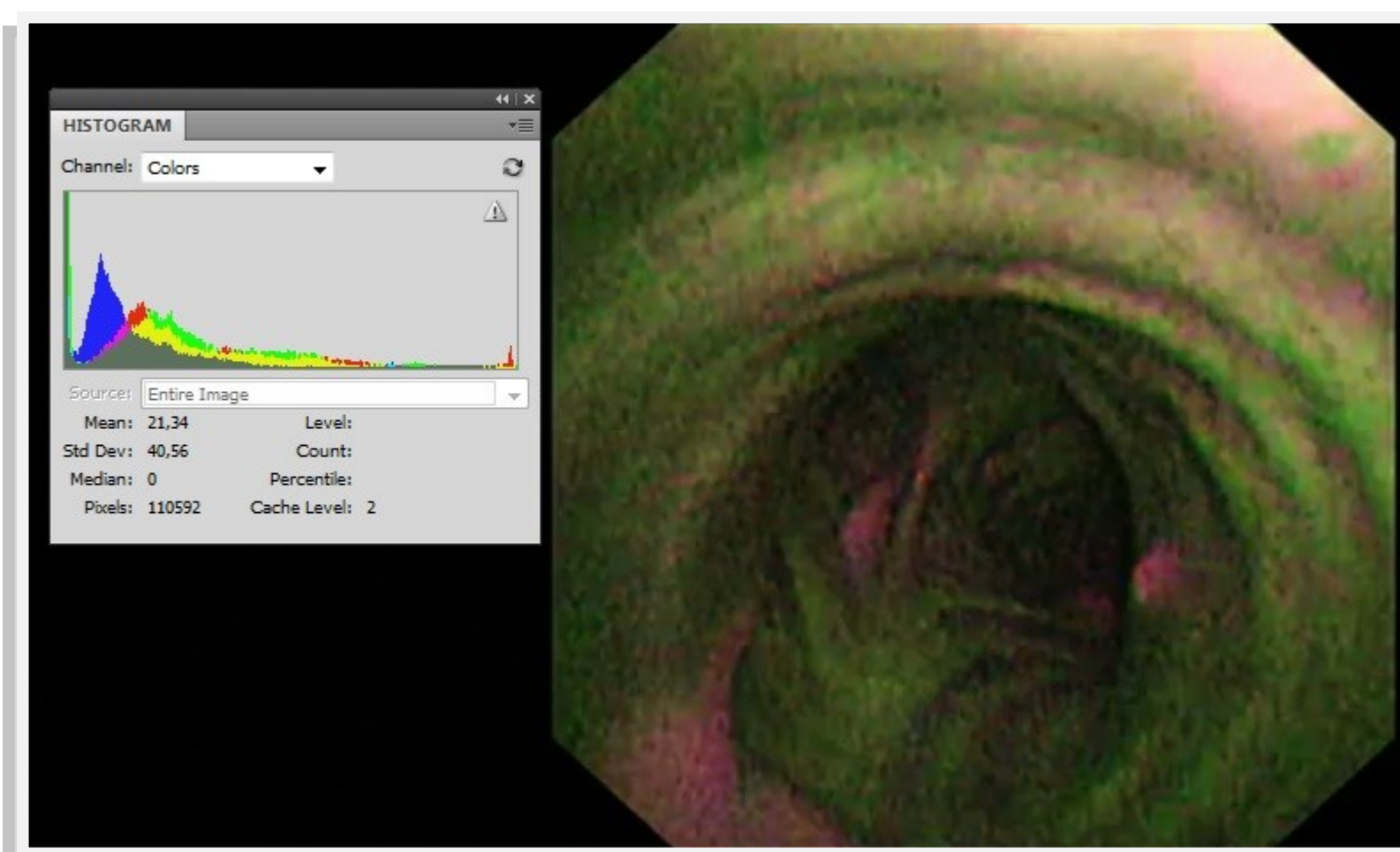
- Thirty patients were included in the study.
- The immediate postoperative controls recorded the higher red intensity.
- The mucosa regained the normal green autofluorescence generally at the 30th day control.
- A correlation between higher graft ischemic time and low autofluorescence was noted.
- Graft infection determined a delay in regaining normal autofluorescence.
- Patients with a delayed color change to green developed bronchial stenosis.

AUTOFLUORESCENCE

EVIS Lucera bronchoscope produces enhanced images by irradiating target sites with excitation light (390–470 nm) and light at a wavelength readily absorbed by circulating haemoglobin (540-560nm). The technology takes advantage of the fact that when pathological tissue is irradiated with blue excitation light, the auto fluorescence produced by collagen and other fluorescent substances is weaker than that produced by normal tissue. This attenuation of the auto fluorescence results from (1) the absorption and scattering of light in the epithelium of mucosal membranes in pathological tissue, and (2) from the absorption of light by circulating haemoglobin. The combination of an auto fluorescence image with the image of green reflected light determined that normal tissue appears pale green, blood vessels dark green and ischemic (or tumorous) tissue magenta.

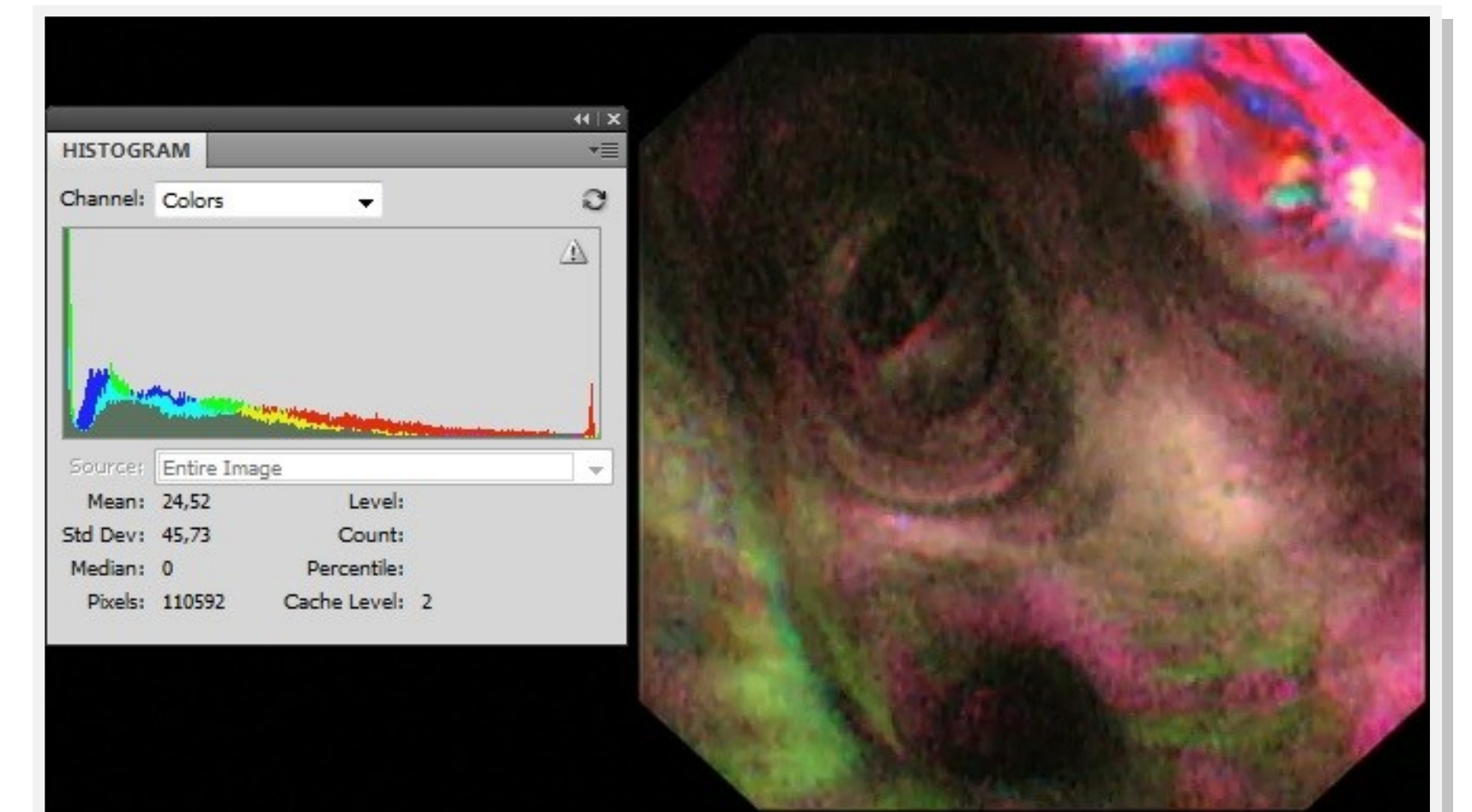


Post-transplantation day: 0
(R/G: 1,85)

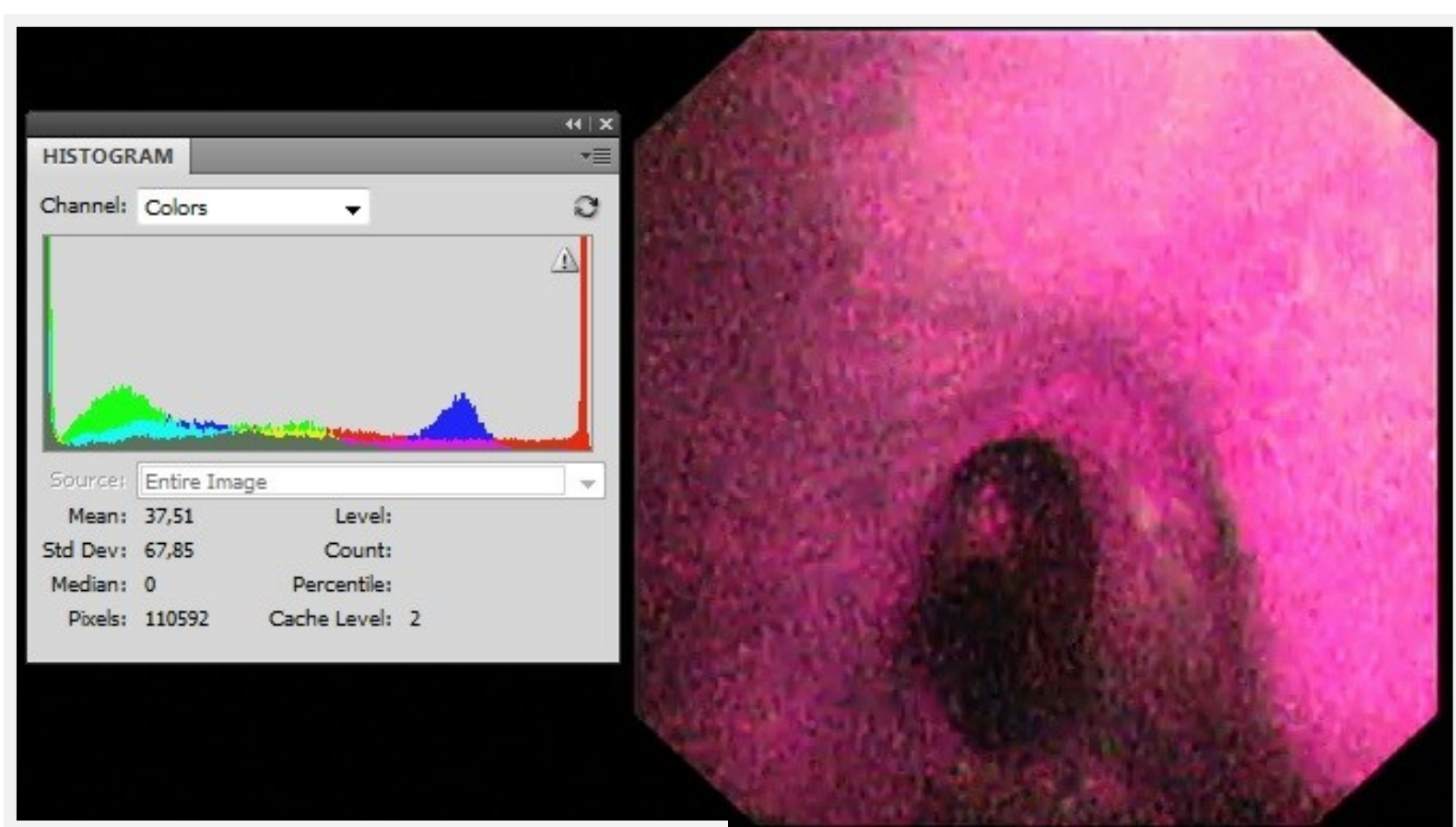
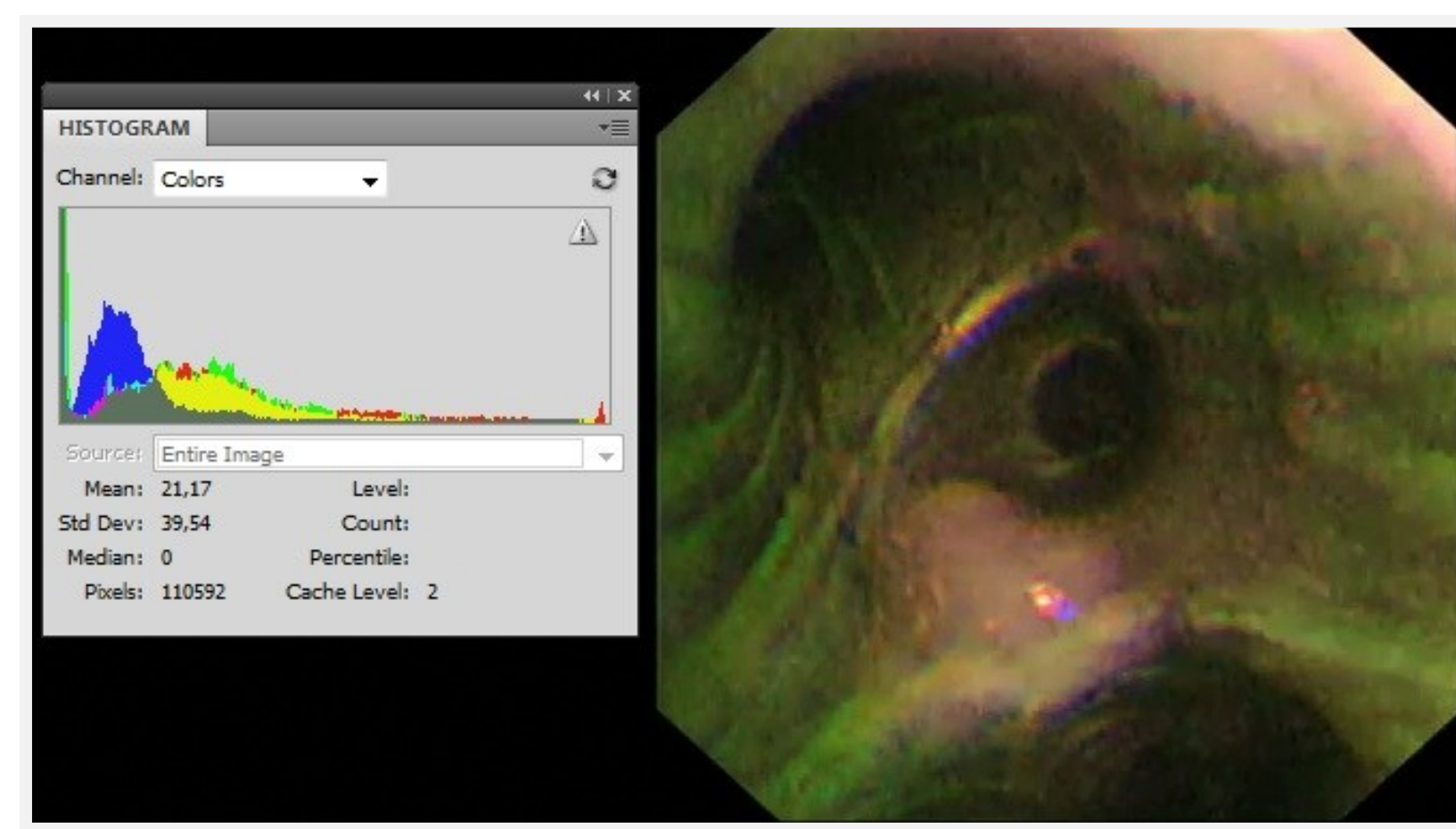


Normal mucosa (R/G: 0,87)

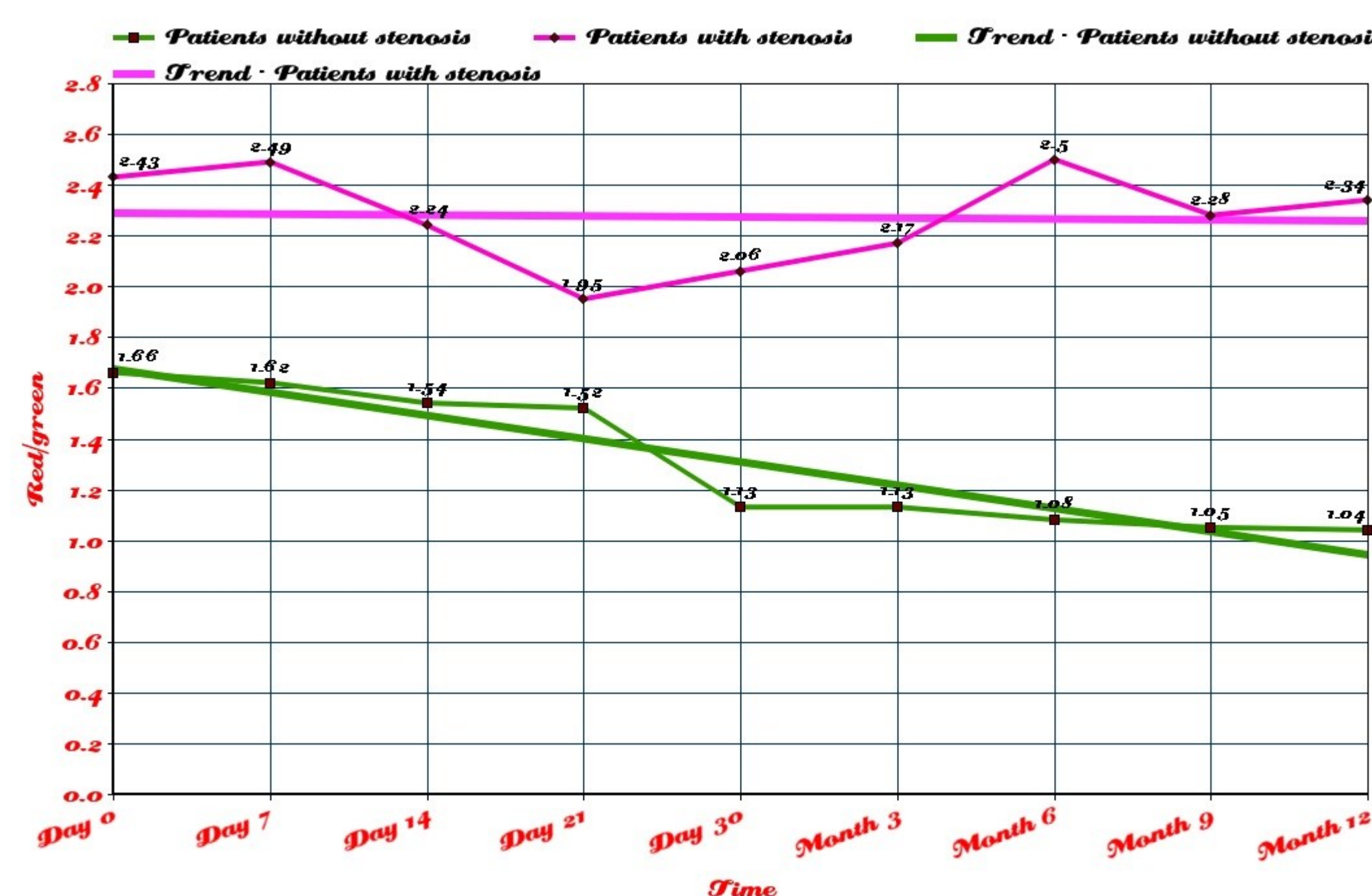
Post-transplantation day: 14
(R/G: 1,47)



Post-transplantation day: 30
(R/G: 1,00)



12 months after transplantation: bronchus intermedius stenosis.
(R/G: 2,53)



Conclusions

- Autofluorescence bronchoscopy may control the airway revascularization after lung transplantation.
- Autofluorescence bronchoscopy may detect latent ischemic mucosa and predict stenosis formation.