

[PA2232] Regional specific gas volume as an early marker of chronic lung allograft dysfunction (CLAD)

Caterina Salito,¹ Andrea Aliverti,¹ Alessandro Paleschi,² Rosaria Carrinola,² Letizia Morlacchi,³ Valeria Rossetti,³ Paolo Tarsia,³ Mario Nosotti.² ¹Dipartimento di Elettronica, Informazione e Bioingegneria, Politecnico di Milano, Milano, Italy ²Unità Operativa di Chirurgia Toracica, Fondazione IRCCS Ca' Granda-Ospedale Maggiore Policlinico di Milano, Milano, Italy ³Unità Operativa di Broncopneumologia, Fondazione IRCCS Ca' Granda-Ospedale Maggiore Policlinico di Milano, Milano, Italy

After lung transplantation, CLAD develops in its distinct subtypes of bronchiolitis obliterans syndrome (BOS) and restrictive allograft syndrome (RAS).

Our aim was to investigate if quantitative analysis of specific gas volume, SV_g, obtained from multivolume CT scans of transplanted lung allografts, can be helpful for an early detection of BOS and RAS.

CT scans at end-expiration (EXP) and full-inspiration (INSP) of 9 patients (6 cystic and 3 pulmonary fibrosis; 3M/6F, 43±10yrs, FEV1%pred 68±23, FEV1/FVC 84±18%) within 1 year from double-lung transplantation were analyzed. For each patient, mean SV_g was calculated within 40 corresponding circular regions of interest at EXP and INSP.

Average SV_g values were 5.10±1.29 and 3.46±1.36 ml/g at INSP and EXP, respectively. Compared to emphysema (E), they were significantly different both at INSP and EXP (27.2±12.7; 23.4±11.9, P<0.001), whereas, compared to healthy (H) only at INSP (12.48±2.48; 3.33±0.93, P<0.001).

Figure 1 shows the distribution of all SV_g values in the diagram SV_g^{INSP} vs SV_g^{EXP}. Although in this cohort of patients a high degree of variability was present, a prevalent restrictive pattern was found, with evidence of regions of mild air trapping present in some cases, with SV_g values approaching the zone of severe E.

Our results suggest that regional assessment of SV_g is a useful tool to evaluate lung function in transplanted patients and to follow-up development of RAS and BOS.

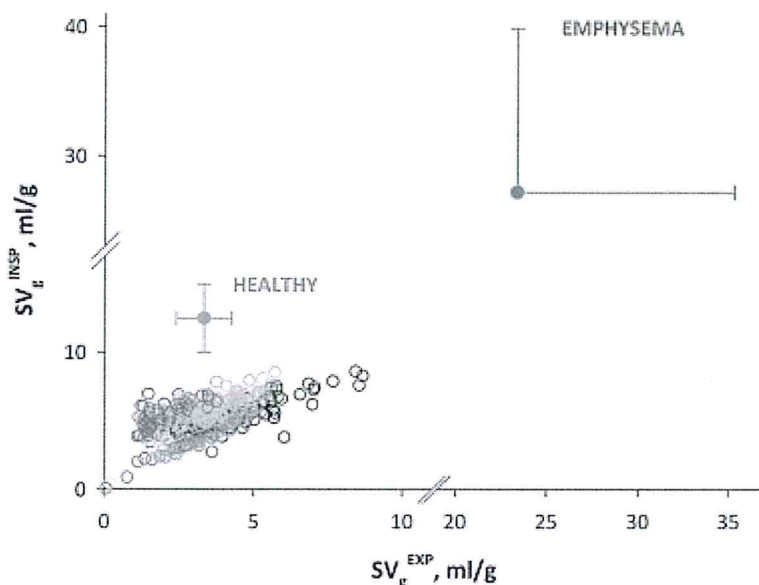



Figure 1. Diagram of SV_g^{INSP} vs SV_g^{EXP} values in lung transplanted patients (open circles) compared to healthy and severe emphysema (grey and red closed circles, respectively, Salito et al., Chest 2014). Different colours refer to different patients.

Session: Thematic Poster: Lung function and imaging: new findings and new approaches

Date/Time: Monday, September 5, 2016 - 12:50 pm

Room: T-06

[Close Window](#)



ERS 2016

EUROPEAN RESPIRATORY SOCIETY
INTERNATIONAL CONGRESS 2016

LONDON united kingdom, 3–7 september

ERSCONGRESS.ORG

