

# Pedicated buccal fat pad graft for root coverage in severe gingival recession defect

Saurav Panda, Massimo Del Fabbro,<sup>1</sup> Anurag Satpathy, Abhaya Chandra Das

Department of  
Periodontics and  
Oral Implantology,  
Institute of Dental  
Sciences, Siksha 'O'  
Anusandhan University,  
Khandagiri Square,  
Bhubaneswar, Odisha,  
India, <sup>1</sup>Department of  
Medicine, Surgery and  
Dentistry, University of  
Milan, Milano, Italy

## Abstract:

Gingival recession (GR) is a condition resulting in root exposure which leads to root sensitivity, pain, root caries, plaque retention, poor esthetics, and tooth loss. Sites exhibiting Miller Class III and IV GR are not suitable for treatment with surgical root coverage techniques, and their prognosis are very poor with current techniques. In this case report, pedicled buccal fat pad (PBFP) was employed as subepithelial graft technique for root coverage of maxillary tooth with Class III GR defect along with furcation involvement and the absence of keratinized gingiva. PBFP as the subepithelial graft is likely to increase the predictability and outcome of root coverage procedures in the treatment of cases with poor prognosis, owing to its pedicled vascularity. PBFP may be considered as a reliable modality for root coverage of such severe maxillary posterior GR defects, as reported, that could not be repaired by other conventional procedures.

## Key words:

Gingival recession, periodontal disease, transplant

## INTRODUCTION

Gingival recession (GR) refers to the apical displacement of marginal gingival tissue from cement-enamel junction (CEJ) resulting in exposure of the root surface to the oral environment. It leads to root sensitivity, pain, root caries, plaque retention, poor esthetics, and tooth loss. The extent of GR increases with age and in males, smokers, and buccal sites and in sites with supra- and sub-gingival calculus.<sup>[1]</sup> GR is most common in buccal surfaces as a result of vigorous tooth brushing and can also affect other tooth surfaces in population with poor oral hygiene. However, the etiology of recession is multifactorial, being associated with anatomic factors, physiologic (aging), and pathologic factors such as smoking associated periodontal disease.

Several surgical procedures have been proposed to manage such GR defects such as free soft tissue grafts, pedicle soft tissue grafts, guided tissue regeneration, or bilaminar techniques, with varied clinical effectiveness.<sup>[2]</sup> The goal of any root coverage procedure should be to restore the gingival margin to the CEJ. The prognosis for Miller's Class I and II GR defects is usually good, predicting almost 100% root coverage, whereas only partial root coverage can be expected for Class III and almost none for Class IV GR defects with the current root coverage techniques. However, it has been reported that pedicle grafts result in predictable root coverage.<sup>[3]</sup>

In severe GR, a more predictable method can be applied for root coverage using pedicled buccal fat pad (PBFP). The buccal fat pad (BFP) was first described by Heister in 1732 and the PBFP by Egyedi in 1977 for the closure of oroantral communications.

BFP is a specially organized and encapsulated fatty tissue confined to the masticatory space between the buccinator muscle medially and masseter muscle laterally. It has three lobes (anterior, intermediate, and posterior), and the posterior lobe has four extensions (buccal, pterygoid, pterygopalatine, and temporal). Its volume is ~10 cm<sup>3</sup>, with a length of ~60 mm, a width of 50 mm, and a thickness of 6 mm. Vascular supply is provided by superficial temporal, infraorbital, transverse facial, and internal maxillary artery. Several nutritional vessels exist in each lobe and together form a subcapsular plexus.<sup>[4]</sup>

PBFP has been used in root coverage procedures in upper molar teeth because of several

This is an open access article distributed under the terms of the Creative Commons Attribution-NonCommercial-ShareAlike 3.0 License, which allows others to remix, tweak, and build upon the work non-commercially, as long as the author is credited and the new creations are licensed under the identical terms.

For reprints contact: reprints@medknow.com

How to cite this article: \*\*\*

Access this article online	
Website:	www.jisponline.com
DOI:	***
Quick Response Code:	

**Address for correspondence:**  
Dr. Saurav Panda,  
Department of Periodontics  
and Oral Implantology,  
Institute of Dental  
Sciences, Siksha 'O'  
Anusandhan University,  
Khandagiri Square,  
Bhubaneswar - 751 003,  
Odisha, India.  
E-mail: drsaurav87@  
gmail.com

Submission: 03-08-2015

Accepted: 05-10-2015

advantages, which include its favorable anatomical location, easy harvesting and mobilization, excellent blood supply, and minimal donor site morbidity.<sup>[5,6]</sup>

This case report highlights the use of PBFP as a subepithelial graft for root coverage in severe GR defect.

### CASE REPORT

A 36-year-old healthy male presented to the Department of Periodontology, Faculty of Dental Sciences, Siksha 'O' Anusandhan University, for the treatment of severe GR in relation to the upper left first molar. On clinical examination, the patient had Miller Class III GR with the absence of keratinized gingiva of the offending tooth. The tooth presented with an attachment loss of 7 mm with no pocket. Grade III furcation involvement was present on mesial and the buccal aspect of the tooth [Figure 1]. The tooth was vital and nonmobile. Considering the tooth being nonmobile vital, with acceptable amount of bone support, and patient's willingness to save the tooth, it was decided to cover the GR in relation to left first maxillary molar using PBFP graft.

Patient-signed informed consent was taken prior to the procedure. The phase I initial therapy of plaque control was carried out including proper oral hygiene instructions. The use of PBFP was planned to cover the tooth root and augment the final width of the keratinized mucosa coronal to the recession.

#### Surgical procedure

After administering local anesthesia (2% lignocaine HCL with 1:200,000 epinephrine), a 2 cm horizontal incision was made at the highest point of the vestibule extending backward from above the upper left second molar tooth [Figure 2]. Blunt dissection was carried out through the buccinators and loose surrounding fascia by an artery forceps, which allowed the PBFP to be exposed into the mouth [Figure 3].

A full-thickness envelope flap was raised using a sulcular incision in the recipient site extending anteriorly up to canine tooth region. The recipient site was prepared, including thorough debridement of the teeth roots and furcation defect.

The body of the PBFP and the buccal extension were gently mobilized by blunt dissection, ensuring not to disrupt the delicate capsule and vascular plexus and to preserve the base as wide as possible. The PBFP was made to easily spread over the maxillary roots as far anteriorly as the premolar tooth region. The PBFP was adapted and secured tightly against the maxillary roots by use of resorbable vicryl sling sutures [Figure 4].

The vascularized flap was advanced, secured, and immobilized to the buccal surface of the upper first molar and premolar teeth with the help of interrupted silk sutures ensuring the flap being free of tension [Figure 5]. The patient was given antibiotics and analgesics and was instructed to be on a soft diet. The patient was advised to refrain from toothbrushing in the treated area for 6 weeks and was instructed to rinse with chlorhexidine (0.12%) mouthwash twice daily for 2 weeks.

Postoperative healing was uneventful. Loose ends of the sutures were removed after 14 days in order to speed up the healing process. Clinical healing was normal with neither infectious episodes nor untoward clinical symptoms. The patient was followed up till the end of the 6<sup>th</sup> month. In week 1, the color of PBFP changed to reddish pink. At the end of the 4<sup>th</sup> week, shrinkage of PBFP and discrete areas of epithelialization were seen on its surface.

An attachment gain of 6 mm was observed at the end of the 6<sup>th</sup> month with increased width of keratinized gingiva [Figure 6].

### DISCUSSION

Increase in demand for esthetics and functional treatment has led to the need of root coverage in the treatment of severe GR defects. These root coverage procedures are aimed to achieve complete root coverage and restore esthetics. Several methods are employed for root coverage. However, there exists some restraint with the use of these techniques. Subepithelial connective tissue graft and free gingival graft requires a secondary donor site, and their survival depends on the circulation of recipient site. Coronally positioned flap also requires adequate keratinized gingiva and is used to cover only shallow recessions. However, pedicle grafts offers a predictable clinical outcome, pertaining to its vascularity and high survival rate, but are limited by their length and thickness in the donor site, with chances of recession at the donor site.<sup>[7]</sup> Moreover, these surgical techniques were not suitable for the sites with severe GR, especially in posterior maxillary region. Therefore, the PBFP was employed for the treatment of severe GR in this case.

The PBFP is a specially organized adipose tissue, composed of a specialized type of fat termed syssarcosis, a fat that enhances intermuscular motion and not subjected to lipolysis. The use of PBFP offers advantages in the root coverage of such defects. The proximity of the donor site to the recipient bed and the accessibility can prove advantageous. Moreover, it has also been reported with minimal donor site morbidity and patient discomfort. The PBFP has a rich plexus of blood vessels forming an internal microvascular network that ensures the survival of the flap after relocation with no need for anastomosis.<sup>[8]</sup>

Many researchers have used PBFP with clinical success in the closure of oroantral and oronasal fistulae, in the reconstruction of oral cavity defects, for temporomandibular joint (TMJ) reconstruction after TMJ ankylosis, to cover the buccal mucosa in cases of oral submucous fibrosis, and in esthetic facial surgery.<sup>[9]</sup> Pedicled fat pad provides an axial graft pattern when removed from its usual place and results in accelerated wound healing because of rich vascular supply. The rich vascularity of the PBFP ensures its vitality and resistance to infections. Interestingly, it has also been found that the stem cells are present in the PBFP that help in periodontal regeneration.<sup>[10]</sup>

Based on the literature, the PBFP has been used in root coverage in case of severe GR of maxillary tooth. In this case report, an attachment gain of 4 mm with formation of keratinized gingiva was observed which was in accordance with previous case reports.<sup>[5,6]</sup> In this case, the PBFP was used as subepithelial

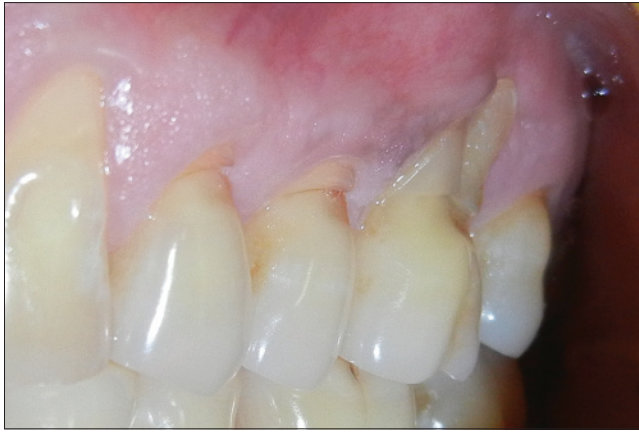

Figure 1: Preoperative photograph

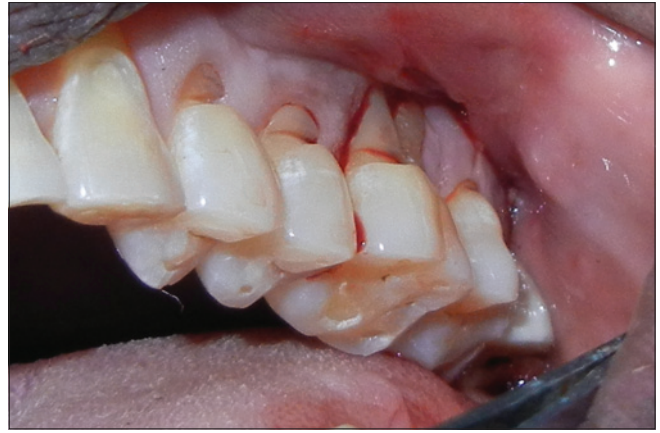

Figure 2: Horizontal incision placed in vestibule

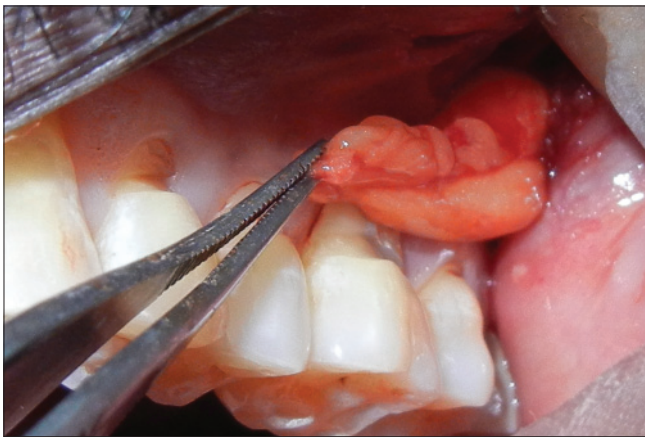


Figure 3: Buccal fat pad immobilized into oral cavity

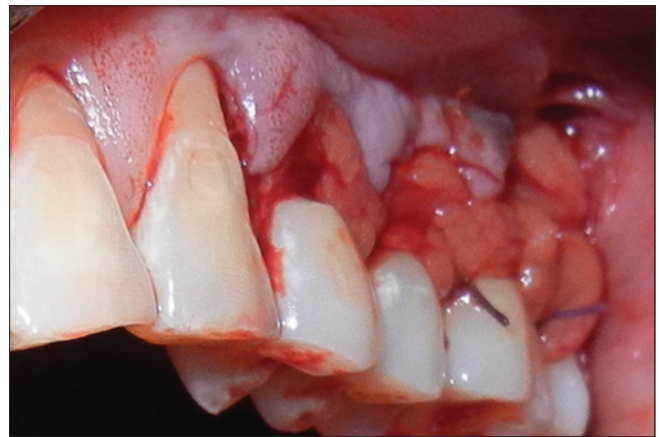

Figure 4: Buccal fat pad secured against root surface of recipient site

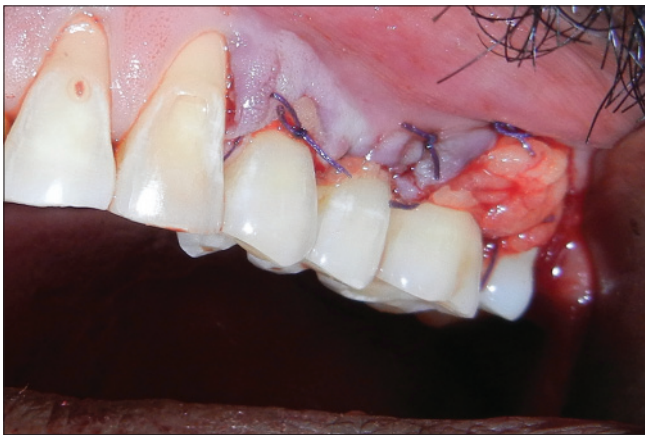

Figure 5: Buccal fat pad covered with flap and sutured

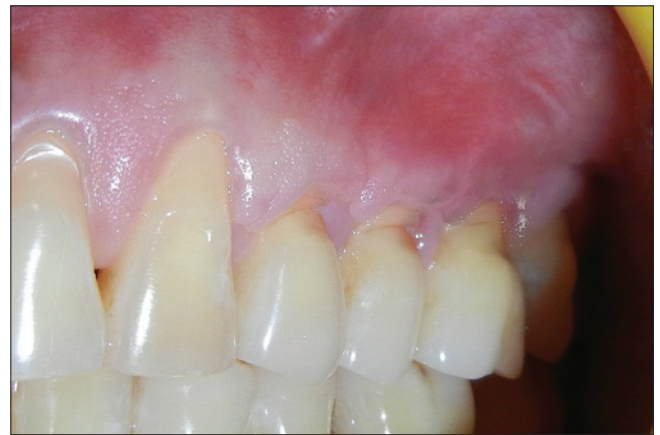

Figure 6: Postoperative photograph

graft with buccal flap advancement. Covering the PBFP with buccal flap was beneficial as it may secure it tightly and protect it against perforations and infections.

Histologically, the PBFP epithelialize within 4–6 weeks, and it has been documented that the fat cells are completely replaced with relatively acellular fibrous tissue and covered by stratified squamous epithelium.<sup>[11]</sup> The disadvantages of using PBFP in root coverage seem to be related to the limited stretching of

the PBFP to preserve its vascularity. It may not be suitable for anterior teeth or lower jaw.

PBFP as the subepithelial graft is likely to increase the predictability and outcome of root coverage procedures in the treatment of cases with poor prognosis, owing to its less donor site morbidity, pedicled vascularity, and favorable outcome. However, long-term clinical trials have to be carried out to prove its predictability. The rich vascular supply of the BFP and

its easy mobilization and fewer complications make it an ideal flap. The use of BFP as subepithelial graft has been shown to be an easy, well-tolerated, and uncomplicated technique for the reconstruction of severe GR defects. Because of these features of the BFP, it can be considered as a reliable modality for root coverage of such severe maxillary posterior GR defects that could not be repaired by other conventional procedures.

#### Financial support and sponsorship

Nil.

#### Conflicts of interest

There are no conflicts of interest.

### REFERENCES

- Kassab MM, Cohen RE. The etiology and prevalence of gingival recession. *J Am Dent Assoc* 2003;134:220-5.
- Wennström JL. Mucogingival therapy. *Ann Periodontol* 1996;1:671-701.
- Wennstrom JL. Mucogingival surgery. In: Lang NP, Karring T, editors. *Proceedings of the 1<sup>st</sup> European Workshop on Periodontology*. London: Quintessence Publishing; 1994. p. 193-209.
- Zhang HM, Yan YP, Qi KM, Wang JQ, Liu ZF. Anatomical structure of the buccal fat pad and its clinical adaptations. *Plast Reconstr Surg* 2002;109:2509-18.
- Kumari BN, Thiagarajan R, Narayanan V, Devadoss P, Mammen B, Emmadi P. A new technique for root coverage using buccal fat pad – A short case report. *Quintessence Int* 2010;41:547-9.
- El Haddad SA, Abd El Razzak MY, El Shall M. Use of pedicled buccal fat pad in root coverage of severe gingival recession defect. *J Periodontol* 2008;79:1271-9.
- Caffesse RG, Kon S, Castelli WA, Nasjleti CE. Revascularization following the lateral sliding flap procedure. *J Periodontol* 1984;55:352-8.
- Fan L, Chen G, Zhao S, Hu J. Clinical application and histological observation of pedicled buccal fat pad grafting. *Chin Med J (Engl)* 2002;115:1556-9.
- Hao SP. Reconstruction of oral defects with the pedicled buccal fat pad flap. *Otolaryngol Head Neck Surg* 2000;122:863-7.
- Pyo SW, Park JW, Lee IK, Kim CH. Differentiation of adult stem cell derived from buccal fat pad into osteoblasts. *J Korean Assoc Oral Maxillofac Surg* 2006;32:524-9.
- Samman N, Cheung LK, Tideman H. The buccal fat pad in oral reconstruction. *Int J Oral Maxillofac Surg* 1993;22:2-6.