

Calcific tendinitis of the shoulder

Introduction

Calcium deposits within the tendons of the rotator cuff are a common shoulder disorder¹. The incidence in the healthy population is 2.7%, rising to 6.8% in patients with shoulder pain.² The predominant age is 30–60 years and women are affected slightly more often than men. Bilateral involvement is not uncommon (in 10% to 25% of patients). Calcifications occur commonly in the supraspinatus tendon (51%–90%) and least commonly in the subscapularis tendon (3%)³. Up to 50% of cases are asymptomatic and run a self-limiting course.⁴⁻⁵ Two different etiological processes have been proposed. The first is degenerative calcification, in which Codman⁶ proposed that degeneration within the tendon fibers precedes calcification. This was later adopted by Moseley and Goldie,⁷ who defined the tendon-bone insertion area as the “critical zone”. The second cause proposed is reactive calcification within a healthy tendon.⁸ Other theories have been introduced in recent years involving chemical factors causing the deposit of calcium, cell proliferation and production of inflammatory agents, metabolic factors and genetic predisposition to the formation of calcific deposits.

Classification

There are numerous classifications that have been proposed by various authors

Anatomical⁹: small (< 0.5 cm) medium (da 0.5 a 1.5 cm) and large (>1.5 cm). Patte and Goutallier¹⁰ have distinguished themselves in localized and diffuse.

Clinical: depending on the symptomatology can be divided into acute, subacute and chronic

Pathological: Uthoff⁸ proposes that the evolution of the disease can be divided into three distinct stages: 1) precalcific, 2) calcific, and 3) postcalcific.

1) precalcific stage: fibrocartilaginous transformation begins within the tendon at the site of predilection for calcification. This metaplasia of tenocytes into chondrocytes is accompanied by metachromasia, indicating the elaboration of proteoglycan

2) calcific stage that follows is subdivided into three phases: a) formative, b) resting, and c) resorptive (Gosens et al.¹¹) .

a) Formative phase: separated by chondrocytes and fibrocartilaginous tissue septae, calcium crystals are deposited primarily in matrix vesicles that coalesce to form large foci of calcification. In this formative phase, the deposits exhibit a chalk-like consistency.

b) Resting phase: occurs when fibrocollagenous tissue borders the foci of calcification without evidence of inflammation, thereby indicating termination of deposition.

c) Resorptive phase: is marked by the appearance of thin-walled vascular channels at the periphery of the deposit. Macrophages and multinucleated giant cells then surround the deposit and phagocytose debris with calcium removal. In this phase the deposit exhibits a thick, creamy, or tooth- paste-like material that is often under pressure.

3) postcalcific stage: As the tissue undergoes healing during the post-calcific stage, new vascular channels promote fibro- blasts to form type III collagen that becomes replaced by type I collagen. The tendon is healed subsequently with fiber realignment and resolution of the calcium deposit.

Clinical presentation

The onset of symptoms is chronic, with very low noise and discomfort content.. The initial state of formation of the deposits has no vascular neoformation, cellular reaction and there is no change in tension of the tendon tissue. The clinical presentation becomes very painful, however, in the phase of resorption because the vascular neoformation, together with the exudative state, can bring a substantial increase in the volume of tissue with consequent increase of intratendinous pressure. The pain typically exacerbates overnight, radiates to the outside face of the ipsilateral arm, with the forearm extension. In some cases, this is also reflected radiation to the cervical region. Calcification of the subscapularis tendon and those located near to the tendon of the long head of the biceps can cause intense pain even at the level of the front face of the arm. Symptoms accompanied by functional impotence of variable degree in relation to pain. The painful crisis may last from a few days to a few weeks. It can be associated with stiffness, typical of frozen shoulder. After this time, even if the disease is not treated, the pain usually decreases suddenly, leaving a less debilitating disease.

We distinguish three symptomatic forms:

1) the acute form may occur in 1 to 5-6 weeks. Very important causes painful discomfort and functional impotence.

2) the chronic form that can occur for many months; has a continuous pain, dull, of fixed intensity. This pain is significantly lower than the acute form.

3) Chronic incoming characterized by periods of pain and periods of complete well-being. Its minimum duration of 1-2 months can last for more than 6 months.

Imaging

Actually X-ray represents the gold standard as diagnostic tool in calcific tendinitis.

Calcium deposits can be seen on plain radiographs with a full series of shoulder films that include

AP, (Fig. 1), internal and external rotation, scapular Y, and axillary lateral views. These views help to localize the deposit to a specific tendon and show signs of possible impingement.

For the recognition of calcifications is also very useful ultrasound.

Hartig and Huth¹² have shown that ultrasound allows to detect totality of calcifications while radiography permits only in 90% of cases. Magnetic resonance imaging (MRI) evaluation is not indicated routinely.

Treatment

Natural course

The choice of treatment should be evaluated and placed in relation to each other the medical history, symptoms and radiographic findings. In some cases, calcifications will resorb during the natural progression of disease.

Gärtner¹³ followed the natural evolution of calcific deposits, finding that radiologically dense deposits disappeared in 33% compared with 85% of fluffy deposits over 3 year.

Unfortunately we know that up to 38% of the calcification do not disappear with time⁵.

In particular, medial and anterior localization of the calcification is a negative prognostic factor for self-reabsorption of the deposit¹⁴.

The persistence of the calcification is detrimental to the tendon biology and resistance.

Thus is mandatory to follow-up the calcification and to treat it in case it would not reabsorb spontaneously.

Several methods of treatment are listed in the literature. Among the most known are Medication and Physiotherapy, Shockwaves, US lavage, Needleing and Arthroscopy (fig.2).

Medication and Physiotherapy

Throughout the years, rest (immobilization), heat, nonsteroidal medication, and physical therapy have been used to decrease pain. There have been varying reports over the success of these measures. Nonsteroidal anti-inflammatory drugs are the initial treatment line, and subacromial steroid injection may be helpful if some of the symptoms come from impingement¹⁵. A formal physical therapy program or gentle exercises may help maintain range of motion. There is mixed evidence that active therapeutic ultrasound is more effective than placebo ultrasound¹⁶. In a well-designed, randomized, double-blind comparison study of ultrasonography and insonation in patients with symptomatic calcific tendinitis, ultrasound treatment resulted in greater decreases in pain and

greater improvements in quality of life in addition to radiographic decrease in calcium deposit size¹⁷.

Extracorporeal shock wave therapy

In the last two decades, several studies have demonstrated the effectiveness of extracorporeal shockwave therapy (ESWT) in treatment of calcifying tendinitis of the rotator cuff¹⁸⁻²¹. One study even stated that ESWT should be preferred to arthroscopy due to its non-invasiveness at equivalent outcome. A single high-level middle-energetic ESWT was found as effective as two applications of a lower-dosed middle- energetic ESWT for calcifying tendinitis of the rotator cuff after failure of other conservative treatment options (physiotherapy, infiltrations or NSAIDs)²². A literature review²³ suggests that ESWT is moderately effective in reducing pain and improving function in individuals with chronic shoulder calcific tendinitis, for up to a year after its application. Although satisfaction results are been associated to this treatment there is no clear evidence regarding the optimal dosage in energy level, intervals between sessions, and number of sessions required for optimal recovery from the condition. Clinicians should also record the intervention parameters because these provide important clinical audit information that will inform future research. Future research of level 1 of evidence are needed to dry definitive conclusions on ESWT treatment for shoulder calcific tendinitis

Needling

Needle lavage has been described as an effective treatment that can be performed either in the operating room or in the radiology suite. This technique is best used in patients with an acutely painful shoulder in the resorptive phase, and it can help decrease the intratendinous pressure. Clinical studies that have analyzed the US-guided percutaneous treatment of calcific tendonitis have reported generally satisfactory results. Serafini et al.²⁴ compare short- and long-term outcomes of patients with rotator cuff calcific tendonitis who did and did not undergo ultrasonographically (US)-guided percutaneous treatment. Of patients referred for US-guided treatment of rotator cuff calcific tendonitis, 219; 68 patients refused treatment and served as control subjects. At baseline, no significant difference in age or sex distribu- tion, Constant score, or VAS score was detected between treated and nontreated (control) patients. Compared with control subjects, treated patients reported a significant decrease in symptoms at 1 month, 3 months and 1 year. Symptom scores were not significantly different between the groups at 5 years and 10 years. The authors conclude that US-guided percutaneous treatment facilitated prompt shoulder function recovery and pain relief. Treated pa- tients had better outcomes than did nontreated patients at 1 year.

Another study²⁵ compare 2 regularly applied calcific rotator cuff tears treatments: ultrasound (US)-guided needling and lavage combined with a US-guided corticosteroid injection in the subacromial bursa (group 1) versus an isolated subacromial bursa injection (group 2). Patients were randomly assigned to the 2 groups. Shoulder function was assessed before treatment and at regular follow-up intervals (6 weeks and 3, 6, and 12 months) using the Constant shoulder score, the Western Ontario Rotator Cuff Index, and the Disabilities of the Arm, Shoulder and Hand questionnaire (DASH). Additionally, calcification location, size, and Gärtner classification were assessed on radiographs. On average, there was improvement at 1-year follow-up in both treatment groups, but clinical and radiographic results were significantly better in the barbotage group. This is the first study comparing the clinical and radiographic results of barbotage (combined with corticosteroid subacromial bursa injection) and corticosteroid subacromial bursa injection for the treatment of calcific tendinitis in a double-blinded randomized controlled trial. The authors conclude that both treatments give clinical improvement in patients who fail more conservative treatments. Nevertheless, the results of barbotage in combination with subacromial bursa injection are superior to those of injection alone, specifically in case of type II or III Gärtner calcifications.

Platelet-rich plasma therapy

Platelet-rich plasma therapy (PRPT) has been advocated for the treatment of muscle, tendon as well as joint pathologies²⁶. Seijas et al.²⁷ reported the use of PRPT in a 44-year-old female with chronic calcific tendinopathy of the supraspinatus that was nonresponsive to traditional conservative therapy. The patient received three treatments at 2-week intervals. After 6 weeks, the patient was reportedly asymptomatic. Follow-up at 1 year confirmed the patient remained pain-free and was able to return to unrestricted activities. This isolated case study (level V) suggests PRPT may be of value for intractable cases of calcific tendinopathy. However evidence from clinical studies of Level 1 are required.

Surgery

Surgery is indicated for patients who have progression of their symptoms, constant pain that interferes with activities of daily living, and absence of improvement after conservative therapy²⁸.

Surgery is helpful for the chronic formative phase patients and especially those with impingement symptoms (is indicated in cases of radiologically dense calcification and sharp edges)

Harrington and Codman performed the first operative procedure for removal of calcific deposit in 1902⁶. Since the 1930s many investigators have supported this procedure²⁹⁻³¹.

Rochwerger et al.³² reported on 22 patients who underwent open removal of a calcific deposit and acromionplasty and found the Constant-Murley assessment score was increased 23 months after the treatment. They concluded that the most favorable results are obtained in patients with the longest

interval between onset of the disease and intervention (more than 1 year) and with a progressive course of the disease.

Arthroscopic treatment has been shown to have outcomes that are equivalent to those of open procedures, and it has the added benefits of improved cosmesis and possibly a shorter hospital stay, which leads to decreased cost. (Fig. 2)

Rehabilitation consists of a simple home exercise program to regain muscle tone and to prevent adhesive capsulitis.

In 1987 Ellman³³ first described his arthroscopic technique, involving blind needle aspiration to locate the deposit, followed by excision, and the acromionplasty. Weber [] augmented the technique with the addition of intraoperative fluoroscopic guidance for needle localization of deposit with excellent results.

Jerosch et al.³⁴ evaluated 48 patients treated arthroscopically with deposit removal, resection of the coracoacromial ligament and acromionplasty, if there was radiographic evidence of subacromial stenosis. Results showed patients with post-operative radiographic elimination or reduction of the deposits had significantly better outcomes than those without radiographic change and that acromionplasty did not improve the results.

Even more recent studies support the arthroscopic technique in patients with persistence or progression of symptoms and constant pain. Seil et al.³⁵ have analyzed the outcome of arthroscopic removal of calcifying tendinitis of the rotator cuff on 58 patients. Every patient has been evaluated by using the Constant score, pre- and post-operative radiographs and ultrasonography to assess integrity of rotator cuff. Shoulder function improved according to Constant score, and ultrasonography revealed minor structural changes of the supraspinatus in 66% patients. 92% of the patients were very satisfied. The study confirmed previously reported successful result of arthroscopic treatment of calcifying tendinitis of the rotator cuff.

El Shewy³⁶ studied the results of arthroscopic removal of the calcium deposits within the rotator cuff, without rotator cuff repair after a minimum follow-up of 7 years. On 56 patients everyone improved their shoulder's activity (measured by ASES, UCLA and Costant). Only 3.7% of cases developed rotator cuff tears over the period of follow-up. The author concludes that arthroscopic removal of as much as possible of symptomatic calcium deposits of the rotator cuff is a safe and effective treatment when nonoperative methods fail.

Yoo et al.³⁷ substantiated that complete removal of calcium deposits in tendon cuff provides good clinical results and earlier pain relief when it was compared to previous literature of minimal removal technique

Porcellini et al.³⁸ demonstrated results of arthroscopic removal of calcifications and an

acromioplasty only when the coracoacromial ligament was rough and the acromion was exposed. They concluded that a successful outcome seemed strongly related only to the absence of calcium deposits in the tendon cuff³⁹.

Other studies have advocated the surgical removal of deposits, either by an open or arthroscopic procedure. Balke et al.⁴⁰ reported the results on 70 shoulders of 62 patients with a mean age of 54 years, after arthroscopic removal of calcium deposits of the supraspinatus tendon. In 44 shoulders, additional subacromial decompression was performed. After a mean follow-up of 6 years, patients were clinically investigated, and function was statistically evaluated using Constant and ASES scores. Affected and contralateral shoulders were examined by ultrasound in 48 shoulders, and rotator cuff tears were documented. The mean Constant scores of the operated shoulders were significantly lower than those of the healthy shoulders. The ASES scores significantly increased after surgery but were still lower than the ASES scores of the healthy shoulders. About pain it was significantly better in patients with the subacromial decompression. Ultrasound examination at last follow-up showed a partial supraspinatus tendon tear in 11 operated and 3 contralateral shoulders. The results of this study indicate that although the good clinical results after arthroscopic treatment of calcifying tendinitis of the shoulder persist midterm, the affected shoulders present significantly lower clinical scores than healthy shoulders. The rate of partial supraspinatus tendon tears seems to be higher after calcium removal. Additional subacromial decompression seems to reduce postoperative pain. Tillander and Norlin⁴¹, however, compared two groups with an impingement syndrome, one group showing deposits in the rotator cuff and the other not showing such deposits. Both groups performed arthroscopic acromioplasty, with no difference in results or calcification dissolution. They suggested that calcifications may not cause pain and are an insignificant observation on radiographic evaluation regarding treatment indication.

Hofstee and colleagues evaluated two groups of patients after 3 years. The first group treated with acromioplasty and removal of calcification, the second only with acromioplasty.

His study shows that there is no difference in patient outcome between surgical subacromial decompression with or without removal of the calcifications. Most studies concerning surgical treatment of rotator cuff calcifications are uncontrolled and provide good long-term results for calcification removal. Moreover, most studies focus on symptom disappearance, more than calcification disappearance, after conservative or operative therapy. Therefore, although symptoms may improve, the pathology (ie, the intratendinous degeneration and calcification) remains.

Treatment Algorithm

Calcific Tendinitis represent a treatment challenge since there is no consensus on its treatment.

Patients compliance is the key in the treatment algorithm for this disease. As a matter of fact shockwaves are not well tolerated by patients, as like as the surgical treatment is not well perceived. Recently US guided lavage offers an easy way of treatment of the tendinitis, washing out the entire deposit. Unfortunately US lavage is suitable only in acute calcific tendinitis when the deposit is pretty fluid. On the other hand the arthroscopic treatment allows to repair a cuff tear related to a chronic calcific tendinitis.

A practical Treatment Algorithm has been developed following the main concepts of: 1) reduce the pain 2) treat the tendon avoiding a subsequent cuff tear

1. In case of acute onset of calcific tendonitis diagnosed by X-Rays, the patients are sent to the radiology dept for US lavage. The lavage is performed in local anesthesia and in an outpatient way.
2. Two days after the treatment the patients start physical therapy, for passive range of motion (ROM) exercises, with a full ROM recovery at 7 days after treatment. Active ROM exercises will start only 15-20 days after treatment depending on the residual pain.
3. The patients will repeat an X-rays at 2 months after treatment plus an MRI in case of persistent pain. If the tendon is torn the patients are scheduled for surgery, if not they continue follow-up surveillance.
4. In case of Chronic calcific tendonitis we suggest an arthroscopic treatment with/out rotator cuff repair.

Conclusions

The calcific tendonitis is a cell-mediated pathology, multiphasic, which creates a calcium deposit particularly in the supraspinatus tendon, or subacromial bursa, and a subsequent resorption.

Most cases resolve spontaneously.

In the literature, several conservative treatments have been reported with varying levels of evidence on their effectiveness.

A very well accepted and successful technique is the US lavage.

The arthroscopic surgery is the last option available to the orthopedic specialist; should be noted that the post-surgical pain may be present for several weeks after surgery (Arthroscopic treatment should be reserved for chronic cases or for cuff ruptures due to the deposit).

References

- 1) Lippmann RK. Observations concerning the calcific cuff deposit. *Clin Orthop*. 1961;20:49-60.
- 2) Bosworth BM. Calcium deposits in the shoulder and subacromial bursitis; a survey of 12122 shoulders. *JAMA* 1941;116:2477-82.
- 3) Editorial. Calcific tendonitis of the shoulder. *New Engl J Med* 1999;340:1582-4.
- 4) Hedtmann A, Fett H. So-called humero-scapular periarthropathy: classification and analysis based on 1,266 cases. *Z Orthop Ihre Grenzgeb*. 1989;127:643-649.
- 5) Uhthoff HK, Loehr JF. Calcifying tendinitis. In: Rockwood CA, Matsen FA, eds. *The Shoulder*. Philadelphia: Saunders; 1998:989-1008.
- 6) Codman EA. On stiff and painful shoulders. *Boston Med Surg J*. 1906;154:613-620.
- 7) Moseley HF, Goldie I. The arterial pattern of the rotator cuff of the shoulder. *J Bone Joint Surg Br*. 1963;45:780-789.
- 8) Uhthoff HK, Loehr JW. Calcific tendinopathy of the rotator cuff. *J Am Acad Orthop Surg*. 1997;5(4):183-191.
- 9) Bosworth BM : Calcium deposits in the shoulder and subacromial bursitis: A survey of 12122 shoulders *JAMA* 116: 2477-2482, 1941.
- 10) Patte and Goutalier D: Calcifications. *Rev Chir Orthop* 74: 277-278, 1988.
- 11) Gosens T, Hofstee DJ. Calcifying tendinitis of the shoulder: advances in imaging and management. *Curr Rheumatol Rep*. 2009 Apr;11(2):129-34. Review
- 12) Hartig A and Huth F: Neue Aspekte zur Morphologie und Therapie der Tendinosis calcarea der Schultergelenke. *Arroskopie* 8: 117-122, 1995)
- 13) Gärtner J: Is tendinosis calcarea associated with HLA-A1? [in German]. *Z Orthop Ihre Grenzgeb* 1993, 31:461-469.
- 14) Ogon P, Suedkamp NP, Jaeger M, Izadpanah K, Koestler W, Maier D (2009) Prognostic factors in nonoperative therapy for chronic symptomatic calcific tendinitis of the shoulder. *Arthritis Rheum* 60(10):2978-2984,
- 15) Wolf WB (1992) Shoulder tendinoses. *Clin Sports Med* 11(4):871-890
- 16) Robertson VJ, Baker KG (2001) A review of therapeutic ultrasound: effectiveness studies. *Phys Ther* 81(7):1339-1350
- 17) Ebenbichler GR, Erdogmus CB, Resch KL, Funovics MA, Kainberger F, Barisani G et al (1999) Ultrasound therapy for calcific tendinitis of the shoulder. *N Engl J Med* 340(20):1533-1538

- 18) Loew M, Daecke W, Kusnierczak D, Rahmanzadeh M, Ewerbeck V (1999) Shock-wave therapy is effective for chronic calcifying tendinitis of the shoulder. *J Bone Joint Surg Br* 81(5):863–867
- 19) Gerdesmeyer L, Wagenpfeil S, Haake MM, Loew M, Wörtler K, Lampe R, Seil R et al (2003) Extracorporeal shock wave therapy for the treatment of chronic calcifying tendonitis of the rotator cuff. *JAMA* 290(19):2573–2580
- 20) Ogden JA, Toth-Kischkat A, Schultheiss R (2001) Principles of shock wave therapy. *Clin Orthop Relat Res* 1(387):8–17
- 21) Speed CA, Richards C, Nichols D, Burnet S, Weiss JT, Humphreys H, Hazleman BL (2002) Extracorporeal shock wave therapy for tendonitis of rotator cuff. *J Bone Joint Surg Br* 84-B(4):509–512
- 22) Farr S, Sevelde F, Mader P, Graf A, Petje G, Sabeti-Aschraf M. Extracorporeal shockwave therapy in calcifying tendinitis of the shoulder. *Knee Surg Sports Traumatol Arthrosc.* 2011 Dec;19(12):2085-9.
- 23) Lee SY, Cheng B, Grimmer-Somers K. The midterm effectiveness of extracorporeal shockwave therapy in the management of chronic calcific shoulder tendinitis. *J Shoulder Elbow Surg.* 2011 Jul;20(5):845-54. doi: 10.1016/j.jse.2010.10.024. Epub 2011 Jan 13
- 24) Serafini G, Sconfienza LM, Lacelli F, Silvestri E, Aliprandi A, Sardanelli F. Rotator cuff calcific tendonitis: short-term and 10-year outcomes after two-needle US-guided percutaneous treatment. Nonrandomized controlled trial. *Radiology.* 2009;252(1):157-164.
- 25) de Witte PB, Selten JW, Navas A, Nagels J, Visser CP, Nelissen RG, Reijnen M. Calcific tendinitis of the rotator cuff: a randomized controlled trial of ultrasound-guided needling and lavage versus subacromial corticosteroids. *Am J Sports Med.* 2013 Jul;41(7):1665-73. doi: 10.1177/0363546513487066. Epub 2013 May 21.
- 26) Podd D. Platelet-rich plasma therapy: origins and applications investigated. *JAAPA* 2012; 25:44 – 49.
- 27) Seijas R, Ares O, Alvarez P, et al. Platelet-rich plasma for calcific tendinitis of the shoulder: a case report. *J Orthop Surg* 2012; 20:126 – 130.
- 28) Gschwend N, Scherer M, Lohr J. Die Tendinitis calcarea des Schultergelenks (T. c.). *Orthopade* 1981;10: 196 – 205
- 29) Bosworth BM. Examination of the shoulder for calcium deposits. *Technique of fluoroscopy*

and spot film roentgenography. *J Bone Joint Surg* 1941;23:567 – 77.

- 30) Harmon PH. Methods and results in the treatment of 2580 painful shoulders with special reference to calcific tendinitis and the frozen shoulder. *Am J Surg* 1958; 95:527 – 44.
- 31) McLaughlin HL. The selection of calcium deposits for operation: the technique and resultant operations. *Surg Clin N Am* 1963;43:1501 – 4.
- 32) Rochwerger A, Franceschi JP, Viton JM, Roux H, Mattei JP. Surgical management of calcific tendinitis of the shoulder: an analysis of 26 cases. *Clin Rheumatol* 1999;18(4):313 – 6.
- 33) Ellman H. Arthroscopic subacromial decompression. Analysis of one- to three-year results. *Arthroscopy* 1987;3(3):173 – 81.
- 34) Jerosch J, Strauss JM, Schmiel S. Arthroscopic treatment of calcific tendinitis of the shoulder. *J Shoulder Elbow Surg* 1998;7(1):30 – 7.
- 35) Seil R, Litzemberger H, Kohn D, Rupp S. Arthroscopic treatment of chronically painful calcifying tendinitis of the supraspinatus tendon. *Arthroscopy*. 2006 May;22(5):521-7.
- 36) El Shewy MT. Arthroscopic removal of calcium deposits of the rotator cuff: a 7-year follow-up. *Am J Sports Med*. 2011 Jun;39(6):1302-5.
- 37) Yoo JC, Park WH, Koh KH, Kim SM. Arthroscopic treatment of chronic calcific tendinitis with complete removal and rotator cuff tendon repair. *Knee Surg Sports Traumatol Arthrosc*. 2010 Dec;18(12):1694-9.
- 38) Porcellini G, Paladini P, Campi F, Paganelli M: Arthroscopic treatment of calcifying tendonitis of the shoulder: clinical and ultrasonographic follow-up findings at two to five years. *J Shoulder Elbow Surg* 2004, 13:503–508.
- 39) Randelli P, Arrigoni P, Cabitza P, et al.: Autologous platelet rich plasma for arthroscopic rotator cuff repair. A pilot study. *Disabil Rehabil* 2008, 30:1584–1589.
- 40) Balke M, Bielefeld R, Schmidt C, Dedy N, Liem D. Calcifying tendinitis of the shoulder: midterm results after arthroscopic treatment. *Am J Sports Med*. 2012 Mar;40(3):657-61
- 41) Tillander BM, Norlin RO: Change of calcifications after arthroscopic subacromial decompression. *J Shoulder Elbow Surg* 1998, 7:213–217.
- 42) Hofstee DJ, Gosens T, Bonnet M, De Waal Malefijt J. Calcifications in the cuff: take it or leave it? *Br J Sports Med*. 2007 Nov;41(11):832-5.

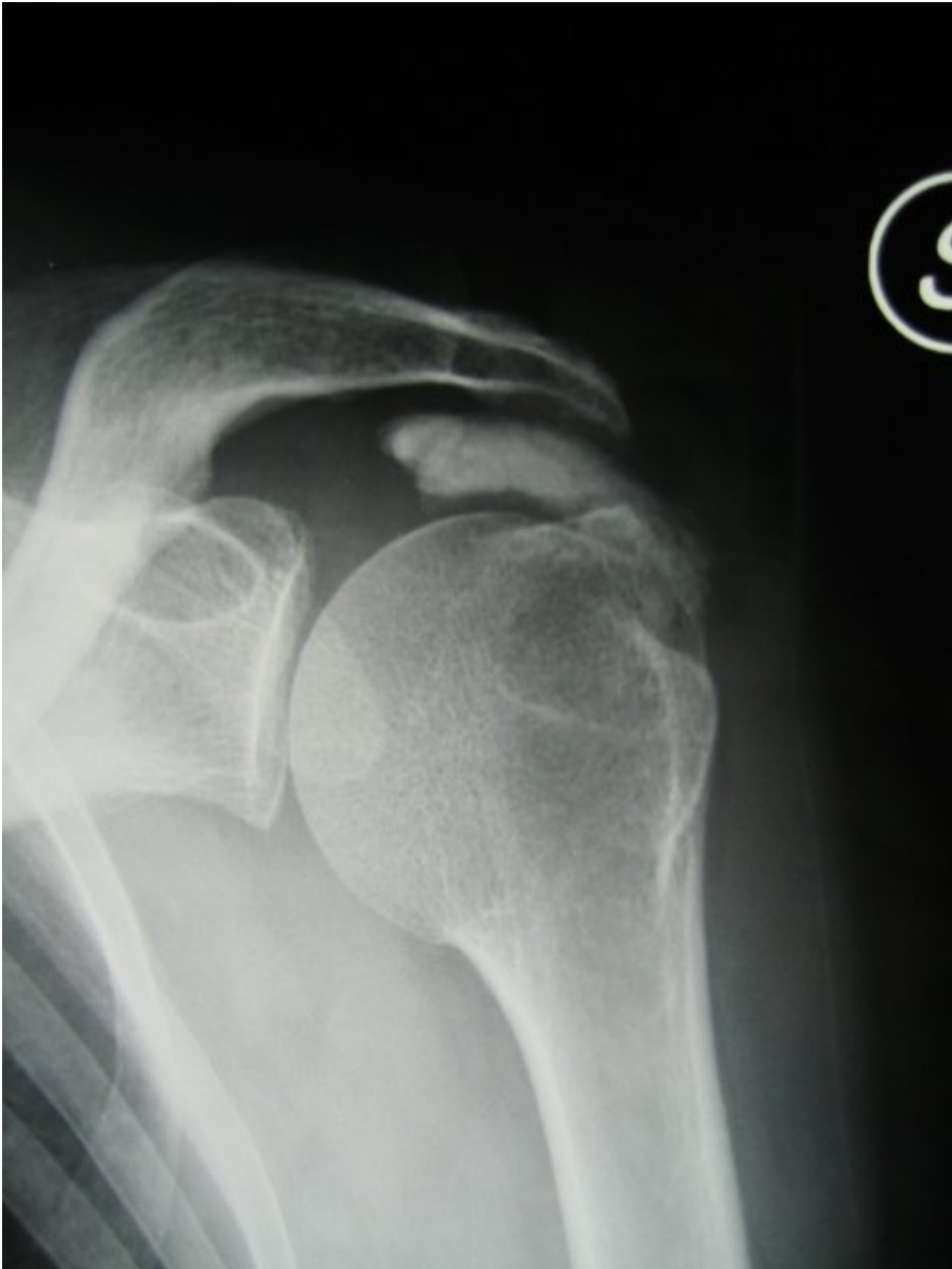

Fig.1 Rx anterior-posterior left shoulder. Clearly visible calcification in the context of the supraspinatus tendon.

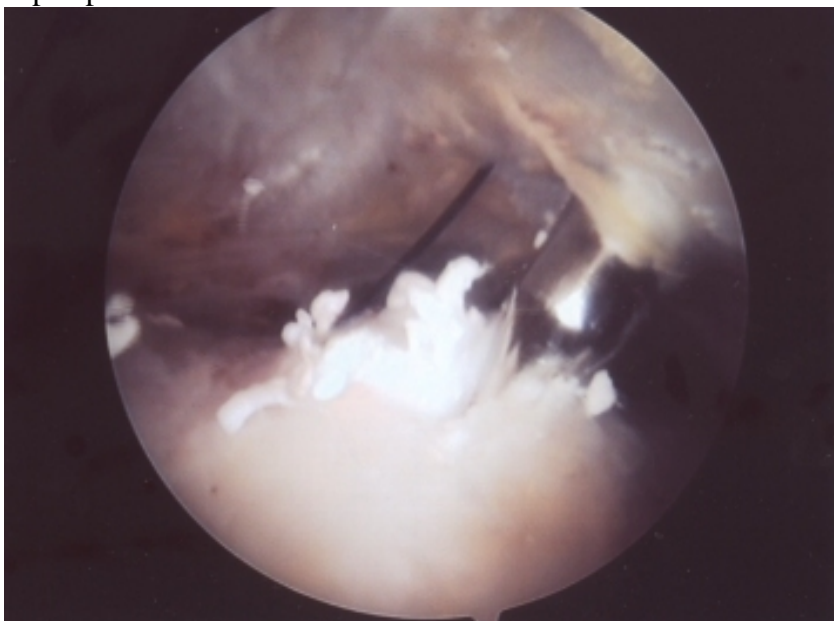


Fig.2 Arthroscopic image. Removal of calcification of the supraspinatus tendon.