

Available online at www.sciencedirect.com

ScienceDirect

Biomedical Journal

journal homepage: www.elsevier.com/locate/bj

Original Article

The occlusal imaging and analysis system by T-scan III in tinnitus patients



Federica Di Berardino ^{a,*}, Eliana Filipponi ^b, Massimo Schiappadori ^a,
Stella Forti ^a, Diego Zanetti ^a, Antonio Cesarani ^a

^a Department of Clinical Sciences and Community, Audiology Unit, IRCCS Fondazione Policlinico, Mangiagalli e Regina Elena, University of Milan, Milan, Italy

^b S.I.T.R.A. Fondazione IRCCS Ca' Granda Ospedale Maggiore Policlinico, Milan, Italy

ARTICLE INFO

Article history:

Received 28 March 2015

Accepted 5 October 2015

Available online 1 June 2016

Keywords:

Dental occlusion

Idiopathic tinnitus

Ménière disease

T-scan

ABSTRACT

Background: Several studies have demonstrated that the prevalence of temporomandibular disorders (TMDs) in tinnitus patients ranges from 7% to 95%, and it is reported in literature that idiopathic tinnitus patients should be referred to a dentist to define whether or not the tinnitus is associated with TMD. However, the possible pathophysiological relation between TMDs and tinnitus is not generally investigated in clinical practice.

Methods: The patterns and forces of occlusal contacts have been studied by means of T-scan III in 47 tinnitus patients (23 suffering from idiopathic tinnitus and 24 affected by Ménière disease [MD]) and 13 healthy subjects.

Results: The center of force target was offset in the opposite direction in 15/23 idiopathic tinnitus and in 7/24 MD patients ($p = 0.026$). No significant variation was found in the occlusal force.

Conclusions: Our data suggest that a diagnostic screening method for occlusal stability in the intercuspidal position might be clinically useful in idiopathic tinnitus patients.

* Corresponding author. Department of Clinical Sciences and Community Health (DISCCO), Audiology Unit, IRCCS Fondazione Policlinico, Mangiagalli e Regina Elena, University of Milan, Via Pace 9, Milan 20122, Italy. Tel.: +39 02 55033922; fax: +39 02 50320756.

E-mail address: federica.diberardino@unimi.it (F. Di Berardino).

Peer review under responsibility of Chang Gung University.

<http://dx.doi.org/10.1016/j.bj.2016.04.001>

2319-4170/© 2016 Chang Gung University. Publishing services by Elsevier B.V. This is an open access article under the CC BY-NC-ND license (<http://creativecommons.org/licenses/by-nc-nd/4.0/>).

At a glance commentary

Scientific background on the subject

A disharmony of the occlusal contacts in the intercuspal position (ICP) is an important etiologic factor in temporomandibular disease that might be underwhelmed during the standard otological evaluation of tinnitus patients.

What this study adds to the field

The study of occlusal stability using the T-scan III system seems to be a valuable additional tool in the clinical evaluation of tinnitus patients. In particular, this diagnostic screening method was able to discriminate a typical (COT) distribution in idiopathic tinnitus patients.

Tinnitus is a subjective auditory perception; although it is really perceived by patients, it cannot be measured objectively. Several theories have been proposed to explain the mechanisms underlying tinnitus involving central and peripheral generators located in the auditory pathway [1]. In particular, a hyperactivation of the dorsal cochlear nucleus mediated by the somatosensory system, among which the temporomandibular region, has been related with tinnitus symptom [2].

From the clinical practice, it is well-known that tinnitus may be influenced by disorders of the masticatory system [3]. Several studies have demonstrated that the prevalence of temporomandibular disorders (TMD) in tinnitus patients ranges from 7% to 95%. Indeed, the high prevalence of signs and symptoms of TMD in tinnitus patients reported by Levine et al. [4,5] and the pathophysiological connection between the two conditions seem to support a somatosensory origin in some tinnitus cases [6]. For this reason, in addition to the standard neuro-otologic examination, the inspection of the teeth has been proposed as an integral part of the audiologic examination in patients with tinnitus together with palpation of the craniocervical musculature for trigger points, and probing whether the tinnitus percept can be modulated with somatic testing [7].

In 2011, Pihut et al. first published that both structural and functional disorders of the stomatognathic system are associated with unspecific auricular–vestibular symptoms more frequently than expected [8]. Furthermore, a recent publication has shown that patients with TMD have 3.22-fold significantly higher relative risk of developing tinnitus within 3 years of follow-up [9].

Therefore, regarding tinnitus, there is evidence in literature that, if a clinical diagnosis of TMD is supported by history, symptoms, and clinical evidence, the patient should be referred in a timely manner to a dentist who is competent to manage the patient [10,11]. Furthermore, a coordinated treatment of temporomandibular and cervical spine disorders in patients with Meniere's disease (MD) has been proved to be an effective therapy for the relief from the typical symptoms of this disease, which are dizziness as episodic spinning or

whirling vertigo, fluctuating low-frequency sensorineural hearing loss, tinnitus, and a sensation of fullness in the ear [12].

However, the TMD disorder may be subclinical [13] or may involve only a mandibular motor problem rather than a joint problem. Therefore, these patients, complaining of evident otological symptoms, are more likely to seek advice from an Otolaryngologist than a Dentist/Orthodontist [8].

The T-scan III occlusal imaging and analysis system could prove clinically useful as a diagnostic screening method for occlusal stability in the intercuspal position (ICP) [14,15]. A disharmony of the occlusal contacts in the ICP is, in fact, an important etiologic factor in TMD [16] that might not be detected, during the standard otological evaluation.

We, therefore, decided to investigate the patterns and forces of occlusal contacts with the T-scan III occlusal imaging and analysis system in patients affected by tinnitus to perform an objective analysis of the occlusal balance in the ICP and to try to correlate it with the otological disturbance.

Materials and methods

We studied the occlusal contacts in the ICP in 23 patients affected by idiopathic tinnitus (mean age 50.9 ± 17.12 years; 12 females, 11 males), and in 24 patients affected by MD (mean age 58.0 ± 14.5 years; 16 females, 8 males).

The inclusion criteria comprised:

- Willingness to participate
- A subjective, idiopathic, troublesome, unilateral, non-pulsatile tinnitus of more than 6 months' duration.

The exclusion criteria comprised:

- External, middle, or internal acute or chronic ear pathologies such as tympanosclerosis, otosclerosis, and noise-induced hearing loss and definite MD for the first group
- Retrocochlear lesions
- Other known anatomic/structural lesions of the ear
- Temporal bone or head trauma
- Active alcohol and/or drug dependence, or history of alcohol and/or drug dependence within the last year
- Psychological illness such as major depressive disorder; subjects taking over-the-counter, or prescribed medication administered for the treatment of any psychiatric, or neurologic disorder, or any other known central nervous system active drugs, including herbal, over-the-counter, and homeopathic medications
- Coexistence of systemic diseases causing tinnitus
- Objective tinnitus
- Hyperacusis
- Dental problems or known TMD
- Neck complaints (in particular, no whiplash injury)
- A positive history for vestibular complaints or dizziness in the idiopathic tinnitus group.

In addition, 13 normal-hearing subjects without tinnitus were recruited (mean age 34.7 ± 16.2 years; 11 females, 2 males) as controls.

Basic audiological clinical assessment included otomicroscopy to check the condition of the external auditory canal and the tympanic membrane (in particular its color, redness, transparency, mobility, and presence of postinflammatory scars), four-frequencies pure-tone threshold audiometry from 0.5 to 4 KHz pure-tone average (PTA4), and Feldman test for tinnitus pitch evaluation using an audiometer (Amplaid A321, Milan, Italy) with TDH-49 headphones (TDH, Telephonics, New York, USA) in a soundproof booth. Immittance audiometry (Amplaid 720, Milan, Italy) was used to acquire tympanograms and reflex thresholds (Metz test). The bithermal caloric test (Hallpike technique) and electronystagmography (ENG) Nicolet Nystar Plus system with light bar and software version 2.02 (Nicolet Instruments, Warwick, UK) were also performed.

The diagnosis of MD was obtained made according to the guidelines of the American Academy of Otolaryngology – Head and Neck Surgery [17]. A history of at least two definite spontaneous episodes of vertigo lasting 20 min or longer, tinnitus or aural fullness, and an audiometrically documented sensorineural hearing loss of at least 60 dB or more on at least one occasion. Other pathologies were excluded. In MD subjects, peripheral vestibular lesions were defined by canal paresis (calculated using Jongkees' formula), by a bithermal caloric test result above 25% according to the Hallpike technique, and/or asymmetric vestibulo-ocular reflexes at rotatory stimulation recorded by ENG.

When the ENG returned symmetric responses both to the bithermal caloric test and to the rotatory stimuli, the patients were assigned to the idiopathic tinnitus group.

Patients' data about their subjective tinnitus were collected; in particular, they were asked to complete a questionnaire (the Tinnitus Handicap Inventory [THI] [18]), to indicate the subjective disturbance level (visual analog scale [VAS] determination [19]) and the characters of the perceived tinnitus.

The study was approved by the Ethics Committee of Fondazione IRCCS Ca' Granda Ospedale Maggiore Policlinico. The experiments were undertaken with the understanding and written consent of each subject.

Dental evaluation

As stated in the exclusion criteria, only those patients who, on medical examination and history collection, did not suffer from severe dental problems or known TMD were included in the study. Most patients had several dental prostheses on both natural teeth and dental implants. The type of occlusal support was not used as an inclusion/exclusion criterion, as long as the subject did not complain of significant problems with his/her teeth and supporting structures.

Evaluation of occlusal stability in the intercuspal position

The functional masticatory balance in the ICP was assessed using the T-scan III system (Tekscan, Inc., South Boston, MA, USA). Patients were asked to sit upright in the dental chair and bite on the sensor in maximum intercuspation with normal pressure.

Several practice closures were performed until a repeatable pattern of contact was seen on the video monitor, and at this time, three closures were recorded in the time mode. Subjects

were invited to clench as hard as possible with their teeth in the maximal ICP, maintaining the same level of contraction for 5 s. None of the patients reported muscular/joint pain provoked by clenching. For each patient, the three periods were automatically selected by the software. The test-retest results indicated high T-scan system reliability (90%).

The size of the center of force target (COT) in the ICP is calculated from the standard deviation of the anterior–posterior and mediolateral measure of the distribution of occlusal contacts described by Maness [20]. These dimensions describe an ellipse with a radius represented by one or two standard deviations, which account for 68% (N1) and 95% (N2) of normal subjects, respectively [20]. The COT anterior–posterior center (distal to the incisors plane, on the mid-sagittal axis) and the occlusal force were also assessed.

Statistical analysis

Mean and standard deviation were reported. Fisher's exact test and Mann–Whitney tests were performed, according to the data type, in order to evaluate the differences between the groups. Spearman's rank correlation was used to evaluate the correlation between the occlusal force and age. All statistics were calculated using the Statistical Package for the Social Sciences 17.0 for Windows Software Package (SPSS Inc., Chicago, IL, USA).

Results

For the right ear, the PTA4 threshold at 0.5, 1.0, 2.0, and 4.0 kHz was 19.70 ± 8.08 dB in the idiopathic tinnitus group, 28.92 ± 23.96 dB in the MD patients, and 12.88 ± 8.33 in healthy controls. The only significant difference was between MD patients and controls ($p = 0.026$); for the left ear, it was 19.29 ± 8.98 dB in tinnitus subjects, 33.84 ± 18.90 in MD patients, and 11.83 ± 5.51 dB in controls. MD patients reported a higher hearing loss than tinnitus subjects ($p = 0.006$) and controls ($p < 0.001$).

Fourteen patients with idiopathic tinnitus reported it in the right ear and nine in the left; in the MD group, 12 patients reported tinnitus in the right ear and 12 in the left; the distribution was similar in the two groups ($p = 0.57$). The average pitch of subjective tinnitus was 5384.62 ± 1502.14 Hz in the idiopathic group and 4909.09 ± 1044.47 Hz in the MD group ($p = 0.54$). Fifteen idiopathic tinnitus subjects reported a whistle sound, three a buzz, and five a whirl. Nine MD subjects reported a whistle sound, five a buzz, and 10 a whirl. The subjective disturbance level on a VAS was 6.29 ± 1.90 in the idiopathic tinnitus group and 6.87 ± 1.64 in the MD group ($p = 0.68$). The THI score was 40.48 ± 17.67 in the idiopathic tinnitus group and 50.29 ± 16.11 in the MD group ($p = 0.07$). The pitch frequency of tinnitus, the THI, and the VAS scores were not related to the COT data in both groups (pitch $p = 0.06$ and 0.07 ; THI $p = 0.19$ and 0.14 ; VAS $p = 0.05$ and 0.07 , respectively).

The COT was offset toward the same side as the tinnitus perception in 8/23 (34.78%) idiopathic tinnitus and 17/24 (70.83%) MD patients while it was offset in the opposite direction in 15/23 (65.21%) idiopathic tinnitus and 7/24 (29.17%) MD patients, respectively [Fig. 1]. The two distributions are

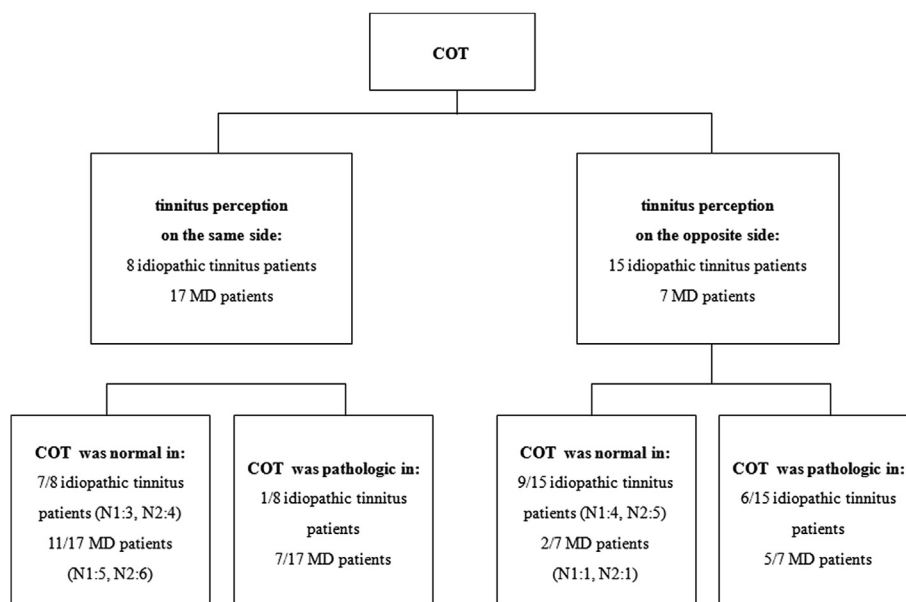


Fig. 1 – Distribution of the occlusal contacts in the patients with idiopathic tinnitus and patients with Ménière's disease. The two distributions are significantly different ($p = 0.026$). In particular, the center of force target position was significantly offset toward the opposite side from the tinnitus perception in 15/23 (65.21%) of the idiopathic tinnitus patients and was pathological in 10/15 (66.67%).

significantly different ($p = 0.026$). In the control group, COT data were normal in 11/13 subjects (84.61%). Normal subjects did not have asymmetrical ear condition to compare the offset with. The COT was normal in 16 idiopathic tinnitus, in 13 MD patients, and in 11 controls (N1: Seven idiopathic tinnitus, 6 MD, three controls; N2: Nine idiopathic tinnitus, 7 MD, eight controls); it was pathologic in seven idiopathic tinnitus, in 11 MD patients, and in two controls; the COT distribution were similar ($p = 0.37$, idiopathic tinnitus vs. MD subjects; $p = 0.44$, idiopathic tinnitus patients vs. controls; $p = 0.08$, MD patients vs. controls). Detailed data are reported in Table 1. When the COT was offset in the opposite direction from the tinnitus

perception, it was pathological in 11/22 patients, in particular, in 6/15 idiopathic tinnitus subjects. An example of pathological COT pattern in idiopathic tinnitus subjects is reported in Fig. 2.

The COT anterior–posterior center (distal to the incisors plane, on the mid-sagittal axis) was 20.45 ± 7.55 mm in the idiopathic tinnitus group and 22.75 ± 8.80 mm in the MD patients when compared with 27.46 ± 7.40 in normal subjects. The occlusal force was $96.90\% \pm 5.22\%$ in idiopathic tinnitus patients, $96.45\% \pm 4.68\%$ in MD, and $96.36\% \pm 2.84\%$ in normal subjects; no significant difference was found among the three groups ($p = 0.81$, idiopathic tinnitus vs. MD subjects; $p = 0.29$ idiopathic tinnitus vs. controls; $p = 0.54$, MD patients vs. controls) Moreover, the occlusal force not correlated with age ($r = -0.056$, $p = 0.34$).

Table 1 – The COT data distribution.

COT data	Group	Mean \pm SD	Range
COT distance to the incisors plane (mm)	Healthy control	27.46 ± 7.40	15.00–39.00
	Idiopathic tinnitus	20.45 ± 7.55	9.00–38.00
	Ménière disease	22.75 ± 8.80	8.00–39.00
COT distribution (N1–N2 – P)	Healthy control	11 (3–8); 2	
	Idiopathic tinnitus	16 (7–9); 7	
	Ménière disease	13 (6–7); 11	
Left (%)	Healthy control	55.66 ± 9.88	42.00–71.60
	Idiopathic tinnitus	55.88 ± 12.65	27.80–83.90
	Ménière disease	43.49 ± 15.50	23.80–88.40
Right (%)	Healthy control	44.42 ± 9.92	28.40–58.00
	Idiopathic tinnitus	44.12 ± 12.65	16,110–72.20
	Ménière disease	56.53 ± 15.52	11.60–76.20
Occlusal force (%)	Healthy control	96.36 ± 2.84	89.40–100.00
	Idiopathic tinnitus	96.90 ± 5.22	75.90–100.00
	Ménière disease	96.45 ± 4.68	78.10–100.00

Abbreviations: SD: Standard deviation; COT: Center of force target.

Discussion

The COT position was significantly offset toward the side opposite to the tinnitus perception; our findings would suggest a possible correlation between the side affected by tinnitus and the mandibular position.

The relationship between inner ear, jaw, and neck disturbances has several anatomical bases. Connections between neck and masticatory muscles, and peripheral and central vestibular and acoustic pathways have been demonstrated in the humans and mammals [21–24].

Many authors treating patients with functional dysfunctions of the masticatory apparatus have reported aspecific audiological symptoms such as hearing impairment, dizziness, and tinnitus [25–28]. Pihut et al. have underlined the role

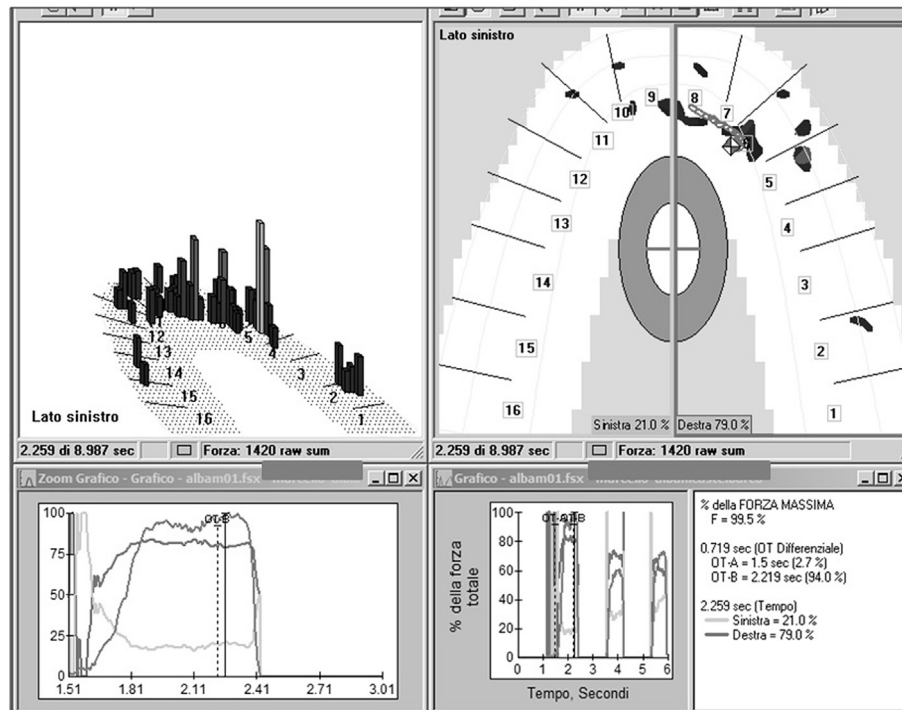


Fig. 2 – An example of pathological center of force target pattern in a left-side idiopathic tinnitus subject. The center of force target was offset in the right direction, opposite from the tinnitus perception (left).

of the stomatognathic system in the auricular–vestibular symptoms [8]. However, they also studied a specific characteristics such as plugged ears sensation, hearing impairment, and burning in the throat that are not specific symptoms of well defined audiological diseases; therefore, they could only conclude that a multi-disciplinary approach is mandatory.

In a previous work, our group studied the electromyographic activity of the sternocleidomastoid and masticatory muscles in patients with vestibular lesions due to unilateral MD and demonstrated that, during maximum voluntary clenching, patients with peripheral vestibular lesions had a higher degree of concurrent contraction of the sternocleidomastoid muscle than normal subjects [29]. We had observed that the vestibular impairment in MD did not cause an asymmetry of muscle activity during intercuspal maximal clenching that might have affected the outcomes of the occlusal stability study in the ICP [30]. Hence, we were able to distinguish MD from idiopathic tinnitus on the basis of the T-scan. During ideal physiologic occlusion in the ICP, all molars occlude simultaneously, and each occlusal contact evenly transmits similar pressure. A disharmony of ICP occlusal contacts is considered an important etiologic factor in TMD [16].

Analysis of COT in the ICP using the T-scan III system gave interesting insights into idiopathic tinnitus patients. The COT position was significantly offset toward the opposite side from the tinnitus perception and pathological in 10/15 patients. Among the T-scan III parameters, in literature, the measurements of the location of the occlusal center has been already reported to appear more repeatable and less affected by additional factors [31]. However, a limit of this study is the

small sample size, which in turn could jeopardize the interpretation of our findings. Further studies should be carried out in order to verify this correlation between the side affected by tinnitus and the position of the jaw.

These preliminary findings support the results of Pihut et al. [8] who found an abnormal configuration of occlusal contacts in the central occlusion in 8/10 patients with a clinically manifest increased tone of the masticatory muscles and asymmetrical electromyographic activity (masseter right-side and temporal left-side muscle activity dominance).

Conclusion

Our data suggest that a diagnostic screening method for occlusal stability in the ICP might be clinically useful in idiopathic tinnitus patients and is as an additional tool in understanding whether or not patients should be referred to a dentist.

The clinical role of the analysis of COT in the ICP using the T-scan III system might be useful to decide a possible and verify the effects of specially designed occlusal devices that recently have been proved to reduce the entity of tinnitus [32].

Further studies might also include a posturographic analysis of the static balance, given the known relationship between mandibular position and body posture [33].

Source of support

Nil.

Conflicts of interest

None declared.

Acknowledgments

Federica Di Berardino MD and Antonio Cesarani MD collected the patients and wrote the manuscript, Eliana Filipponi AuD performed all the tests, Massimo Schiappadori DMD performed all the dental evaluations and helped in the interpretation of the data and Diego Zanetti MD supports the decision to submit it for publication, supervised and reviewed the manuscript.

REFERENCES

- [1] Han BI, Lee HW, Kim TY, Lim JS, Shin KS. Tinnitus: characteristics, causes, mechanisms, and treatments. *J Clin Neurol* 2009;5:11–9.
- [2] Levine RA. Somatic (craniocervical) tinnitus and the dorsal cochlear nucleus hypothesis. *Am J Otolaryngol* 1999;20:351–62.
- [3] Behr M. Tinnitus and masticatory system. In: Moller AR, Langguth B, De Ridder D, Kleinjung T, editors. *Textbook of Tinnitus*. New York: Springer Science + Business Media; 2011. p. 369–74.
- [4] Levine RA, Nam EC, Oron Y, Melcher JR. Evidence for a tinnitus subgroup responsive to somatosensory based treatment modalities. *Prog Brain Res* 2007;166:195–207.
- [5] Ramirez LM, Ballesteros LE, Sandoval GP. Topical review: temporomandibular disorders in an integral otic symptom model. *Int J Audiol* 2008;47:215–27.
- [6] Shore SE. Plasticity of somatosensory inputs to the cochlear nucleus – implications for tinnitus. *Hear Res* 2011;281:38–46.
- [7] Levine RA, Oron Y. Tinnitus *Handb Clin Neurol* 2015;129:409–31.
- [8] Pihut M, Majewski P, Wisniewska G, Reron E. Auriculo-vestibular symptoms related to structural and functional disorders of stomatognathic system. *J Physiol Pharmacol* 2011;62:251–6.
- [9] Lee CF, Lin MC, Lin HT, Lin CL, Wang TC, Kao CH. Increased risk of tinnitus in patients with temporomandibular disorder: a retrospective population-based cohort study. *Eur Arch Otorhinolaryngol* 2016;273:203–8.
- [10] Cooper BC. Recognition of craniomandibular disorders. *Otolaryngol Clin North Am* 1992;25:867–87.
- [11] Bernhardt O, Gesch D, Schwahn C, Bitter K, Mundt T, Mack F, et al. Signs of temporomandibular disorders in tinnitus patients and in a population-based group of volunteers: results of the Study of Health in Pomerania. *J Oral Rehabil* 2004;31:311–9.
- [12] Bjorne A, Agerberg G. Symptom relief after treatment of temporomandibular and cervical spine disorders in patients with Meniere's disease: a three-year follow-up. *Cranio* 2003;21:50–60.
- [13] Weinberg LA. Temporomandibular joint function and its effect on concepts of occlusion. *J Prosthet Dent* 1976;35:553–66.
- [14] Varga S, Spalj S, Lapter Varga M, Anic Milosevic S, Mestrovic S, Slaj M. Maximum voluntary molar bite force in subjects with normal occlusion. *Eur J Orthod* 2011;33:427–33.
- [15] Ikebe K, Matsuda K, Murai S, Maeda Y, Nokubi T. Validation of the Eichner index in relation to occlusal force and masticatory performance. *Int J Prosthodont* 2010;23:521–4.
- [16] Mizui M, Nabeshima F, Tosa J, Tanaka M, Kawazoe T. Quantitative analysis of occlusal balance in intercuspal position using the T-scan system. *Int J Prosthodont* 1994;7:62–71.
- [17] Committee on Hearing and Equilibrium guidelines for the diagnosis and evaluation of therapy in Meniere's disease. American Academy of otology-Head and Neck Foundation, Inc. *Otolaryngol Head Neck Surg* 1995;113:181–5.
- [18] Newman CW, Sandridge SA, Jacobson GP. Psychometric adequacy of the tinnitus handicap inventory (THI) for evaluating treatment outcome. *J Am Acad Audiol* 1998;9:153–60.
- [19] Jastreboff MM, Jastreboff PJ. Questionnaires for assessment of the patients and treatment outcome. In: Hazell J, editor. *6th International Tinnitus Seminar*. Cambridge, London: The Tinnitus and Hyperacusis Centre; 1999. p. 487–90.
- [20] Maness WL, Podoloff R. Distribution of occlusal contacts in maximum intercuspation. *J Prosthet Dent* 1989;62:238–42.
- [21] Deriu F, Tolu E, Rothwell JC. A short latency vestibulomasseteric reflex evoked by electrical stimulation over the mastoid in healthy humans. *J Physiol* 2003;553:267–79.
- [22] Giaconi E, Deriu F, Tolu E, Cuccurazzu B, Yates BJ, Billig I. Transneuronal tracing of vestibulo-trigeminal pathways innervating the masseter muscle in the rat. *Exp Brain Res* 2006;171:330–9.
- [23] Shore SE, Zhou J. Somatosensory influence on the cochlear nucleus and beyond. *Hear Res* 2006;216–217:90–9.
- [24] Wu CH, Young YH, Murofushi T. Tone burst-evoked myogenic potentials in human neck flexor and extensor. *Acta Otolaryngol* 1999;119:741–4.
- [25] Chan SW, Reade PC. Tinnitus and temporomandibular pain-dysfunction disorder. *Clin Otolaryngol Allied Sci* 1994;19:370–80.
- [26] Türp JC. Correlation between myoarthropathies of the masticatory system and ear symptoms (otalgia, tinnitus). *HNO* 1998;46:303–10.
- [27] Salvinelli F, Casale M, Paparo F, Persico AM, Zini C. Subjective tinnitus, temporomandibular joint dysfunction, and serotonin modulation of neural plasticity: causal or casual triad? *Med Hypotheses* 2003;61:446–8.
- [28] Chole RA, Parker WS. Tinnitus and vertigo in patients with temporomandibular disorder. *Arch Otolaryngol Head Neck Surg* 1992;118:817–21.
- [29] Tartaglia GM, Barozzi S, Marin F, Cesarani A, Ferrario VF. Electromyographic activity of sternocleidomastoid and masticatory muscles in patients with vestibular lesions. *J Appl Oral Sci* 2008;16:391–6.
- [30] Abekura H, Kotani H, Tokuyama H, Hamada T. Asymmetry of masticatory muscle activity during intercuspal maximal clenching in healthy subjects and subjects with stomatognathic dysfunction syndrome. *J Oral Rehabil* 1995;22:699–704.
- [31] Liu CW, Chang YM, Shen YF, Hong HH. Using the T-scan III system to analyze occlusal function in mandibular reconstruction patients: a pilot study. *Biomed J* 2015;38:52–7.
- [32] Sletten WO, Taylor LP, Goodacre CJ, Dumont TD. The effect of specially designed and managed occlusal devices on patient symptoms and pain: a cohort study. *Gen Dent* 2015;63:46–52.
- [33] Sakaguchi K, Mehta NR, Abdallah EF, Forgione AG, Hirayama H, Kawasaki T, et al. Examination of the relationship between mandibular position and body posture. *Cranio* 2007;25:237–49.