

OPEN

Cytokine and Chemokine Profile in Amicrobial Pustulosis of the Folds

Evidence for Autoinflammation

Angelo V. Marzano, MD, Simona Tavecchio, MD, Emilio Berti, MD,
Carlo Gelmetti, MD, and Massimo Cugno, MD

Abstract: Autoinflammation has recently been suggested in the pathogenesis of neutrophilic dermatoses but systematic studies on their cytokine profile are lacking. Notably, amicrobial pustulosis of the folds (APF), classified among neutrophilic dermatoses, has been studied only in small case series.

In our University Hospital, we conducted an observational study on 15 APF patients, analyzing their clinical and laboratory features with a follow-up of 9 months to 20 years. Skin cytokine pattern of 9 of them was compared to that of 6 normal controls.

In all patients, primary lesions were pustules symmetrically involving the skin folds and anogenital region with a chronic-relapsing course and responding to corticosteroids. Dapsone, cyclosporine, and tumor necrosis factor blockers were effective in refractory cases. In skin samples, the expressions of interleukin (IL)-1 β , pivotal cytokine in autoinflammation, and its receptors I and II were significantly higher in APF ($P=0.005$, 0.018 , and 0.034 , respectively) than in controls. Chemokines responsible for neutrophil recruitment such as IL-8 ($P=0.003$), CXCL 1/2/3 (C-X-C motif ligand 1/2/3) ($P=0.010$), CXCL 16 ($P=0.045$), and RANTES (regulated on activation, normal T cell expressed and secreted) ($P=0.034$) were overexpressed. Molecules involved in tissue damage like matrix metalloproteinase-2 (MMP-2) ($P=0.010$) and MMP-9 ($P=0.003$) were increased.

APF is a pustular neutrophilic dermatosis with a typical distribution in all patients. The disorder may coexist with an underlying autoimmune/dysimmune disease but is often associated only with a few autoantibodies without a clear autoimmunity. The overexpression of cytokines/chemokines and molecules amplifying the inflammatory network supports the view that APF has an important autoinflammatory component.

Editor: Patrick Wall.

Received: October 2, 2015; revised and accepted: November 20, 2015.

From the Dipartimento di Fisiopatologia Medico-Chirurgica e dei Trapianti, Università degli Studi di Milano, Unità Operativa di Dermatologia, IRCCS Fondazione Ca' Granda, Ospedale Maggiore Policlinico, Milano, Italy (AVM, ST, EB, CG) and Dipartimento di Fisiopatologia Medico-Chirurgica e dei Trapianti, Università degli Studi di Milano, Medicina Interna, IRCCS Fondazione Ca' Granda, Ospedale Maggiore Policlinico, Milano, Italy (MC).

Correspondence: Angelo V. Marzano, Dipartimento di Fisiopatologia Medico-Chirurgica e dei Trapianti, Università degli Studi di Milano, Unità Operativa di Dermatologia, IRCCS Fondazione Ca' Granda, Ospedale Maggiore Policlinico, Via Pace 9, 20122 Milano, Italy (e-mail: angelovalerio.marzano@policlinico.mi.it)

This work was supported by "Ricerca corrente," Fondazione IRCCS Ca' Granda, Ospedale Maggiore Policlinico, Milano, Italy.

The authors have no conflicts of interest to disclose.

Copyright © 2015 Wolters Kluwer Health, Inc. All rights reserved.

This is an open access article distributed under the Creative Commons Attribution-NonCommercial License, where it is permissible to download, share and reproduce the work in any medium, provided it is properly cited. The work cannot be used commercially.

ISSN: 0025-7974

DOI: 10.1097/MD.0000000000002301

(*Medicine* 94(50):e2301)

Abbreviations: ANA = antinuclear antibodies, APF = amicrobial pustulosis of the folds, BCA = bichinchonic acid, CXCL = C-X-C motif ligand, IBD = inflammatory bowel diseases, IL = interleukin, IL-1R = interleukin 1 receptor, MMP = matrix metalloproteinase, PG = pyoderma gangrenosum, RANTES = regulated on activation, normal T cell expressed and secreted, RIPA = radioimmunoprecipitation assay, Siglec = sialic acid-binding immunoglobulin-type lectin, SS = Sweet syndrome, TIMP = tissue inhibitor of metalloproteinase, TNF = tumor necrosis factor, TNFR = tumor necrosis factor receptor.

INTRODUCTION

Amicrobial pustulosis of the folds (APF) is a rare chronic-relapsing neutrophilic dermatosis that affects almost exclusively young women with sudden onset of sterile pustular lesions involving the major cutaneous folds, anogenital area and scalp as well as minor skin folds, particularly the area around the nostrils, retroauricular regions, and external auditory canals.¹⁻⁴ Its histological picture is characterized by subcorneal pustules associated with a predominantly neutrophilic infiltrate in the dermis, which lead to include APF within the spectrum of neutrophilic dermatoses.^{4,5} Neutrophilic dermatoses represent a clinically heterogeneous group of disorders hallmarked by an accumulation of neutrophils in the skin and rarely internal organs.⁶ Recently, pyoderma gangrenosum (PG) and Sweet syndrome (SS), the 2 prototypic neutrophilic dermatoses, have been included among the autoinflammatory diseases,⁷ which are characterized by recurrent episodes of sterile inflammation in the affected organs, including the skin, without circulating autoantibodies and autoreactive T cells.⁸ In PG and SS, we recently demonstrated an overexpression of cytokines/chemokines and molecules amplifying the inflammatory network, supporting the view that these disorders are autoinflammatory in origin.⁹ Here, we analyze the clinical picture, histopathological aspects, course, and treatment of the largest series of APF patients to date. Moreover, to support the inclusion of APF within the spectrum of autoinflammatory diseases, we conducted the first systematic study evaluating the cytokine expression profile in the lesional skin of APF by means of a protein array method.

PATIENTS AND METHODS

Patients

Fifteen patients seen in our University Department from 1995 to 2015 for APF were studied clinicopathologically and immunologically. The patients were followed-up for a period ranging from 9 months to 20 years. The diagnosis of APF was

established on the basis of criteria previously suggested by some of us³ and slightly modified considering the presence of 3 major criteria and at least 1 minor criterion. Briefly, major criteria include: pustulosis involving 1 or more major folds, 1 or more minor folds and the anogenital area; histological pattern consisting of intraepidermal spongiform pustules and a mainly neutrophilic dermal infiltrate; negative culture from unopened pustule. Minor criteria include: association with 1 or more autoimmune or autoinflammatory disorders; positive antinuclear antibodies (ANA) at a titer of 1/160 or higher; presence of 1 or more serum autoantibodies. To conduct the immunological study, lesional skin biopsies, taken from 9 out of 15 patients, were evaluated by means of a cytokine array method. All the 9 patients were not receiving any treatment; in particular, previous systemic antibiotic therapies had been discontinued due to their inefficacy.

As controls, we used normal skin tissue specimens adjacent to benign skin tumors, namely melanocytic nevi localized to the trunk (periflexural areas), taken from 6 subjects (5 women and 1 man; age range: 20–38 years) who underwent excision of the benign lesion. These control subjects were otherwise healthy and in particular were not suffering from any immune-mediated disorder.

Blood and tissue samples were collected during routine diagnostic procedures and all patients gave oral informed consent that remaining samples could be used for research purposes. The protocol was approved by the Institutional Review Board of IRCCS Fondazione Ca' Granda, Ospedale Maggiore Policlinico, Milano, Italy.

METHODS

Cytokine Array

Cytokine array was performed on frozen skin specimens as previously described.⁹ Briefly, frozen skin tissue samples were reduced into thin slices and then thawed in RIPA (radioimmunoprecipitation assay) buffer (3 mL of buffer per gram of tissue). The samples were centrifuged twice at 4°C and the supernatant of each sample, representing the total cell lysate, was collected. Total protein content in each sample was measured, and, for each sample, a volume containing 100 µg of proteins was loaded in a glass-slide format of cytokine antibody array (RayBio[®], Norcross, GA). The results were expressed as numerical data obtained by the conversion of fluorescent signals using a data extraction software. The molecules tested were the following: interleukin 1 beta (IL-1 beta); interleukin 1 receptor I (IL-1RI), and IL-1RII; tumor necrosis factor alpha (TNF-alpha); tumor necrosis factor receptor I (TNFR1) and TNFR2; interleukin 17 (IL-17); interleukin 17 receptor (IL-17R); leukocyte selectin (L-selectin); interleukin 8 (IL-8); regulated on activation, normal T cell expressed and secreted (RANTES); CXCL 1,2,3 ([C-X-C motif] chemokine ligand 1,2,3; [C = cysteine, X = any amino acid]); CXCL 16 ([C-X-C motif] chemokine ligand 16); matrix metalloproteinase-2 (MMP-2) and MMP-9; tissue inhibitor of metalloproteinase 1 (TIMP-1) and TIMP-2; sialic acid-binding immunoglobulin-type lectin 5 (Siglec 5) and Siglec 9.

Statistics

The data are shown as median values and interquartile ranges (25th and 75th percentiles). The between-group differences were analyzed using Mann-Whitney nonparametric tests for independent samples. The significance level was set at

$P < 0.05$. The data were analyzed using the SPSS PC statistical package, version 22.00 (IBM SPSS Inc., Chicago, IL).

RESULTS

Clinical Features

Clinical features are reported in Table 1. All but 2 patients were female with an age ranging from 11 to 43 years (median 28 years) and a duration of disease ranging from 9 months to 30 years (median 5 years). In 8 patients, APF presented with an associated autoimmune/autoinflammatory condition, namely systemic lupus erythematosus (1 patient), subacute cutaneous lupus erythematosus (1 patient), systemic lupus erythematosus/scleroderma overlap syndrome (1 patient), celiac disease (1 patient), antiphospholipid syndrome (1 patient), and inflammatory bowel diseases (3 patients); these last 3 cases were triggered by tumor necrosis factor-alpha blockers. The other 7 cases were idiopathic and 1 of them, at disease onset, had a pulmonary infiltrate which was unresponsive to systemic antibiotics and resolved only after systemic corticosteroids.

In all the patients, the skin lesions were multiple-erythematous pustules coalescing in macerated erosive areas (Figure 1), symmetrically involving the major skin folds, such as groins (Figure 1A) and axillae (Figure 1C), and the anogenital region (Figure 1A and B) as well as minor folds such as the angle of the mouth (Figure 1D), external auditory canals, retroauricular flexures (Figure 1E), and the area around the nostrils; the lesions were associated with intense oozing and accompanied by burning.

Laboratory Findings

On admission to our department, all patients showed an increase in the erythrocyte sedimentation (ranging from 60 mm/1st h to 100 mm/1st h) and in serum levels of C reactive protein (ranging from 1.25 to 6.2 mg/dL; normal values < 0.5 mg/dL). Case 7 showed also mild anemia (hemoglobin: 11.4 g/dL). ANA and various other serum autoantibodies were present in 13 patients (Table 1). Repeated bacteriological cultures from closed pustules were negative, while cultures from erosive areas demonstrated the presence of *Staphylococcus aureus* in all patients. Fungal cultures were negative in all patients.

Histopathological Aspects and Direct/Indirect Immunofluorescence Findings

In all patients, biopsy specimens of lesional skin showed a very similar pattern characterized by spongiform pustules in the epidermis with slight acanthosis and dermal edema with a mixed neutrophilic and lymphocytic inflammatory infiltrate.

Direct immunofluorescence, performed on peripustular normal skin, was negative in all patients.

Treatment and Course

The first 6 patients were initially treated with cimetidine in combination with ascorbic acid, achieving improvement of the clinical picture. Short cycles of both topical and systemic corticosteroids (clobetasole dipropionate and intravenous methylprednisolone 1 mg/kg per d, respectively) were subsequently used for relapses. The other 9 patients were treated with both topical and systemic corticosteroids (Table 1). Dapsone was added as immunomodulating agent in highly relapsing cases (patients no. 10 and no. 11); in patient no. 10, an immunosuppressant like cyclosporine and then a biologic like infliximab were necessary to control disease activity. In the 3

TABLE 1. Clinical Features, Associated Disorders, Laboratory Findings, Treatment, and Course in the 15 Patients With Microbial Pustulosis of the Folds (APF)

Patient	Sex/Age at Diagnosis, y	Duration of Disease, y	Associated Disorders	Autoantibodies	Treatment	Course
1	F/30	24	SLE occurred after the onset of APF	ANA 1/160 homogeneous pattern; SSA-Ro; anti-dsDNA; anti-smooth-muscle	Cimetidine 400 mg bid + ascorbic acid 3 g/d followed by corticosteroids for SLE	PR
2	F/43	30	SLE	ANA 1/160 homogeneous pattern; SSA-Ro; anti-smooth-muscle; anti-gastric-parietal cell; antimitochondrial	Cimetidine 400 mg bid + ascorbic acid 3 g/d followed by short cycles of corticosteroids for relapses	PR
3	F/28	22	Celiac disease	IgA antitransglutaminase; IgG anti gliadin; IgA antientomysial	Cimetidine 400 mg bid + ascorbic acid 3 g/d followed by short cycles of corticosteroids for relapses	PR
4	F/28	19	None	ANA 1/320 fine speckled pattern	Cimetidine 400 mg bid + ascorbic acid 3 g/d followed by short cycles of corticosteroids for relapses	PR
5	F/27	9	None	ANA 1/320 fine speckled pattern	Cimetidine 400 mg bid + ascorbic acid 3 g/d followed by short cycles of corticosteroids for relapses	PR
6	F/41	9	SLE-scleroderma overlap syndrome	Anti-RNP	Cimetidine 400 mg bid + ascorbic acid 3 g/d followed by short cycles of corticosteroids for relapses	PR
7*	F/35	1	CD	ANA 1/320 homogeneous pattern	Clobetasole dipropionate and intravenous methylprednisolone 1 mg/kg per d; switch from adalimumab to ustekinumab	CR
8†	M/38	9 mo	UC	None	Intravenous methylprednisolone 250 mg/d for 3 d (then oral prednisone); switch from infliximab to sulfasalazine	CR
9†	F/26	9 mo	CD	None	Clobetasole dipropionate and intravenous methylprednisolone 1 mg/kg per d; switch from infliximab to sulfasalazine	CR
10	F/13	13	None	ANA 1/160 fine speckled pattern	Clobetasole dipropionate and intravenous methylprednisolone 1 mg/kg per d; dapsone 1.5 mg/kg per d; cyclosporine 3.5 mg/kg per d; infliximab 5 mg/kg; 1 infusion at time 0 and after 2 and 6 wk followed by 1 infusion every 2 mo	PR
11‡	F/29	3	None	ANA 1/640 fine speckled pattern; SSA-Ro; SSB-La; anticardiolipin	Clobetasole dipropionate and intravenous methylprednisolone 1 mg/kg per d; dapsone 1.5 mg/kg per d	PR
12	M/43	5	APS	Anticardiolipin; anti-β ₂ -glycoprotein I; LAC	Clobetasole dipropionate and intravenous methylprednisolone 0.5 mg/kg per d	PR
13	F/12	5	None	ANA 1/640 fine speckled pattern	Clobetasole dipropionate and intravenous methylprednisolone 0.5 mg/kg per d	PR
14	F/26	3	None	ANA 1/320 fine speckled pattern	Clobetasole dipropionate and intravenous methylprednisolone 0.5 mg/kg per d	PR
15	F/11	4	None	ANA 1/160 fine speckled pattern	Clobetasole dipropionate and intravenous methylprednisolone 0.5 mg/kg per d	PR

ANA = antinuclear antibodies, anti-dsDNA = anti-double strand DNA, anti-RNP = anti-ribonucleoprotein, APS = antiphospholipid syndrome, CD = Chron disease, CR = complete remission, F = female, LAC = lupus anticoagulant, M = male, PR = partial remission, SLE = systemic lupus erythematosus, SSA-Ro = Sjogren syndrome associated-Ro, SSB-La = Sjogren syndrome type B-La, UC = ulcerative colitis.

* APF triggered by adalimumab.

† APF triggered by infliximab.

‡ APF with lung involvement.

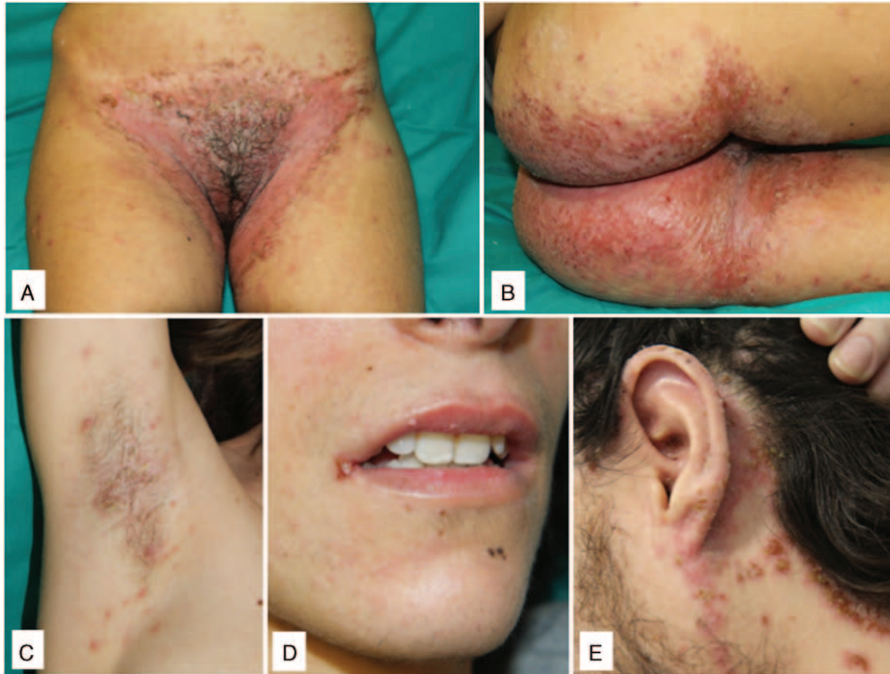

FIGURE 1. Clinical features of amicrobial pustulosis of the folds. Erythematous-erosive lesions, sometimes covered by crusts, involving the groins (A) and the anogenital region (B) in patient 11. Erythematous pustules of the axilla (C) in patient 7. Erosions with crusts involving the angle of the mouth (D) in patient 9 and the retroauricular flexures (E) in patient 8.

patients with APF triggered by TNF blockers, systemic corticosteroids in combination with switching over to other drugs for inflammatory bowel diseases (IBD) induced a complete remission of APF, defined as complete absence of the typical pustular lesions. In the 12 patients in which APF was not triggered by drugs, only partial remission was achieved, defined as significant reduction of the pustular lesions without a complete clinical healing.

In all patients, systemic antibiotic therapy (amoxicillin plus clavulanic acid) in combination with antiseptic baths was given to treat the *S aureus* superinfection.

Expression Analysis of Cytokines, Chemokines, and Effector Molecules in Skin Specimens

Cytokine Expression

In lesional skin of the 9 patients with APF compared to 6 normal skin controls, we observed a significant overexpression of IL-1-beta (median and [interquartile range], 14.35 [7.07–98.96] vs 3.90 [2.04–5.06]; $P=0.005$) and of its receptors IL-1RI (3.25 [2.47–6.03] vs 2.08 [1.68–2.54]; $P=0.018$) and IL-1RII (8.83 [6.01–10.67] vs 4.11 [3.51–6.64]; $P=0.034$; Figure 2). The proinflammatory cytokine TNF-alpha was also overexpressed (3.24 [3.03–4.01] vs 2.56 [2.14–2.76]; $P=0.007$) as well as its receptors TNFRI (12.26 [8.67–16.19] vs 4.24 [3.39–7.09]; $P=0.010$) and TNFRII (12.26 [8.02–18.95] vs 7.15 [4.64–9.15]; $P=0.034$; Figure 2). Finally, we observed an overproduction of IL-17 (3.22 [2.37–5.83] vs 2.20 [1.92–2.51]; $P=0.045$) and its receptor IL-17R (6.29 [4.65–7.51] vs 4.47 [3.47–5.11]; $P=0.034$; Figure 2).

L-Selectin Expression

The expression of L-selectin was significantly higher in lesional skin of the 9 patients with APF than in normal skin (6.91 [5.47–11.34] vs 1.85 [1.58–3.61]; $P=0.001$; Figure 2).

Chemokine Expression

As compared to controls, lesional skin of APF patients showed overexpression of chemokines promoting neutrophil transendothelial migration into inflamed tissues, such as IL-8 (5.63 [4.81–25.58] vs 2.48 [2.02–4.05]; $P=0.003$), CXCL 1/2/3 (51.98 [11.78–103.21] vs 6.43 [4.43–14.56]; $P=0.001$), CXCL 16 (3.76 [2.65–4.73] vs 2.67 [2.06–3.09]; $P=0.045$) and RANTES (8.70 [5.14–23.24] vs 3.41 [2.23–5.40]; $P=0.034$; Figure 3).

MMP and TIMP Expression

In lesional skin of APF patients, we observed a significant overexpression of molecules involved in tissue damage like MMP-2 (4.61 [3.65–8.79] vs 2.61 [1.81–3.36]; $P=0.010$) and MMP-9 (341.56 [193.16–422.67] vs 17.24 [11.89–70.08]; $P=0.003$; Figure 4). Overproduction of molecules responsible for inhibitory signals aimed at attenuating MMP-mediated inflammation, was also demonstrated: TIMP-1 (54.88 [26.65–203.03] vs 4.07 [3.33–6.26]; $P=0.001$) and TIMP-2 (116.56 [65.39–170.25] vs 62.89 [25.92–75.09]; $P=0.025$; Figure 4).

Siglec 5 and 9 Expression

Siglec 5 (66.70 [20.27–162.20]; $P=0.001$) and Siglec 9 (54.93 [17.92–75.80]; $P=0.001$), which carry inhibitory signals dampening inflammation, were more expressed in APF than in normal skin (4.50 [2.91–8.07] and 8.25 [5.62–10.25], respectively; Figure 4).

DISCUSSION

Here, we reported a large series (15 cases) of patients with APF, a very rare pustular neutrophilic dermatosis that typically

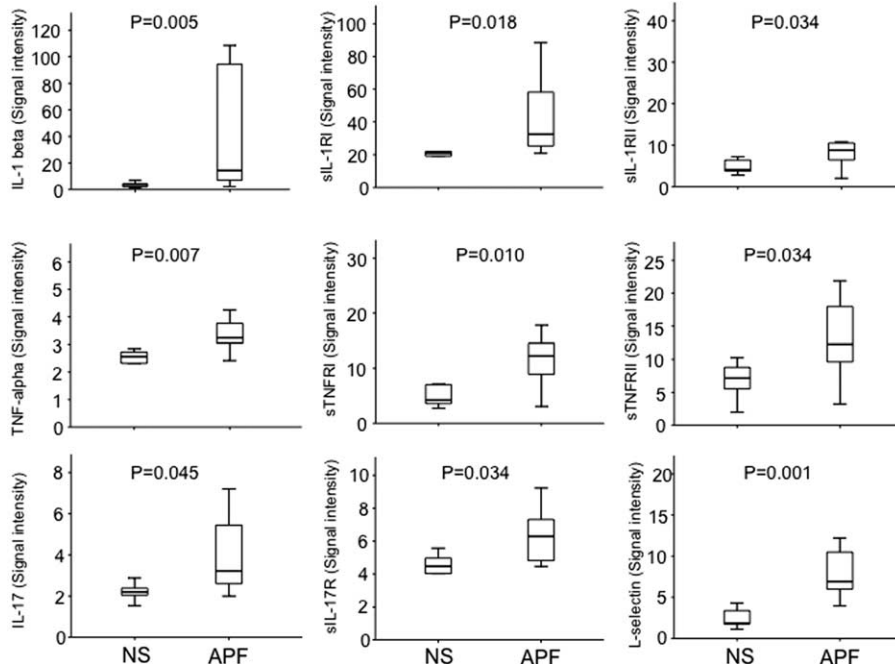


FIGURE 2. Expression of interleukin-1 (IL-1) beta and its soluble receptors I and II (sIL-1RI and sIL-1RII), tumor necrosis factor (TNF)-alpha and its soluble receptors I and II (sTNFRI and sTNFRII), interleukin-17 (IL-17) and its soluble receptor (sIL17R), and leukocyte selectin (L-selectin) in omogenate samples of lesional skin from 9 patients with amicrobial pustulosis of the folds (APF). Six normal subjects (NS) served as controls. Numerical values represent signal intensity in a cytokine array assay. Median values, interquartile ranges (boxes), and 5th and 95th percentiles (whiskers).

involves major and minor skin folds, anogenital area, and scalp, and has been sometimes reported in association with autoimmune diseases.^{2-4,10-15} Interestingly, 3 patients of our series had IBD and developed a skin reaction manifesting as APF after treatment with anti-TNF agents given for the intestinal disease.

In all 3 patients, APF resolved upon TNF blocker withdrawal combined with a corticosteroid cycle, strongly suggesting a triggering role of these drugs. The observation of 3 APF cases following anti-TNF therapy for IBD, together with a similar 1 reported by Lee et al,¹⁶ expands both the clinical context during which APF may occur and the spectrum of cutaneous complications related to anti-TNF biologics. It is well known that neutrophilic dermatoses, particularly PG and SS, are among the better-recognized extraintestinal manifestations of IBD,¹⁷⁻²⁰ and these 2 groups of disorders have also close pathophysiological links that consists of sharing an important autoinflammatory component.^{7,9,21,22} Pustular reactions represent a paradoxical event since TNF antagonists are commonly used in the treatment of psoriasis, including its pustular variant, which is nowadays considered an autoinflammatory condition^{23,24} like PG and SS. In our study, another interesting finding that suggests autoinflammation for APF is that, in 7 patients of our series, although ANA were present in their serum, there was not an underlying autoimmune/dysimmune disease. Considering that APF has been reported almost exclusively in women, another noteworthy finding is that 2 patients of our series were men; in these 2 male patients, the disease presented with the same clinical picture of female patients. In 1 patient, extracutaneous involvement, namely lung consolidation resistant to antibiotics but responsive to corticosteroids, was evident, supporting the view of “neutrophilic disease.”¹⁶ Concerning APF treatment, we have treated our first 6 patients (Table 1) with cimetidine in combination with ascorbic acid, achieving a good response but with a high rate of relapses. Subsequently, we adopted a regimen consisting of topical and systemic corticosteroids, obtaining not only clinical remission but also a longer disease-free period. As maintenance therapy,

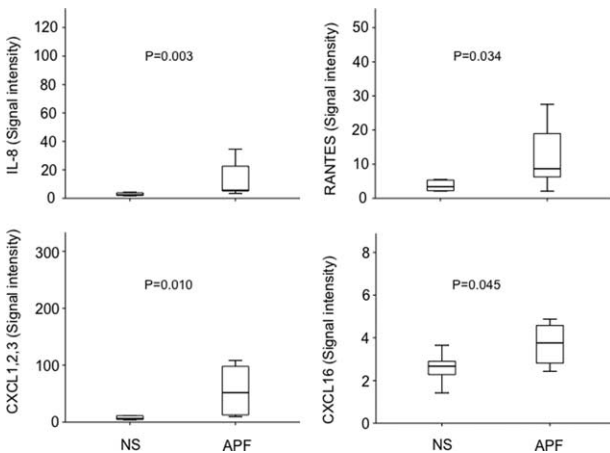


FIGURE 3. Expression of IL-8 (interleukin 8), RANTES (regulated on activation, normal T cell expressed and secreted), CXCL 1,2,3 (Chemokine [C-X-C motif] ligand 1,2,3; [C = cysteine, X = any amino acid]) and CXCL 16 (Chemokine [C-X-C motif] ligand 16) in omogenate samples of lesional skin from 9 patients with amicrobial pustulosis of the folds (APF). Six normal subjects (NS) served as controls. Numerical values represent signal intensity in a cytokine array assay. Median values, interquartile ranges (boxes), and 5th and 95th percentiles (whiskers).

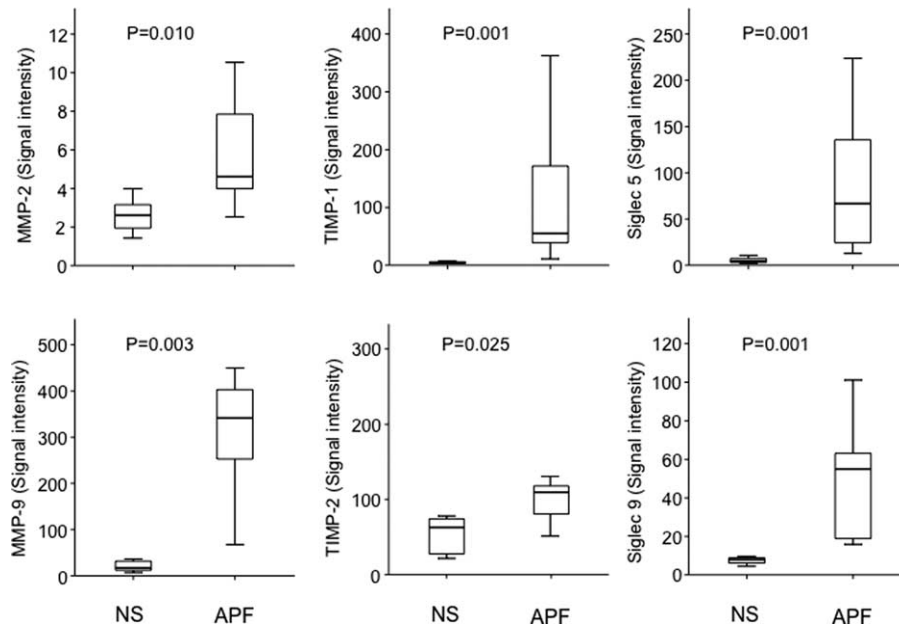


FIGURE 4. Expression of MMP-2 (matrix metalloproteinase-2), MMP-9, TIMP-1 (tissue inhibitor of metalloproteinase 1), TIMP-2, sialic acid-binding immunoglobulin-type lectin 5 (Siglec 5), and Siglec 9 in omogenate samples of lesional skin from 9 patients with amicrobial pustulosis of the folds (APF). Six normal subjects (NS) served as controls. Numerical values represent signal intensity in a cytokine array assay. Median values, interquartile ranges (boxes), and 5th and 95th percentiles (whiskers).

we used in 2 patients the immunomodulating agent dapsone, observing a good efficacy and safety profile. Later, 1 of these 2 patients became refractory and was treated initially with the immunosuppressant cyclosporine and then with the TNF blocker infliximab with a satisfactory disease control.

In our study, we found an overexpression of IL-1 beta and its receptors in all the 9 patients evaluated. This could be linked to a dysregulation of the inflammasome, which is a molecular platform inducing the activation of caspase 1, an enzyme that proteolytically cleaves the inactive pro-IL-1 beta to its functionally active isoform, IL-1 beta. IL-1 induces the formation and release of other proinflammatory cytokines, notably TNF-alpha and interferon (IFN)-gamma, and chemokines, including IL-8 and RANTES.²⁵ TNF-alpha, another crucial cytokine in the inflammatory scenario,²⁶ was overexpressed in our patients with APF. We also found an upregulation of chemokines, including IL-8, CXCL 1/2/3, CXCL16, and RANTES, which, in combination with L-selectin overexpression, are responsible for neutrophil recruitment and activation. In all patients with APF, an overexpression of IL-17 was found as well as for its receptor, supporting the role of this proinflammatory cytokine in the pathogenesis of neutrophilic dermatoses, as reported in other immune-mediated disorders.^{27–29} IL-17 contributes to neutrophil and monocyte chemotaxis by stimulating the tissue production of chemokines³⁰ and acting in combination with other proinflammatory cytokines.³¹ In addition, IL-17, synergizing with IL-1 and TNF-alpha, increases the production of MMP-2 and MMP-9.³² The excessive production of MMPs mainly by neutrophils contributes to tissue damage by destroying the extracellular matrix and inducing the release of chemokines.³³ In our study, MMP-9 and to a lesser extent MMP-2 were overexpressed in APF lesional skin, supporting the role of these gelatinases in the induction of tissue damage. Intriguingly, we observed an upregulation of TIMP-1 and TIMP-2, which are

known to inhibit the MMP-mediated inflammation. Also the inhibitory receptors SIGLEC 5 and SIGLEC 9,²⁹ which were overexpressed in our APF patients, are likely to carry inhibitory signals dampening inflammation.

The main limitation of our study is the small number of patients, due to the rarity of APF, which may be, however, counterbalanced by the wide panel of molecules investigated and by the clear-cut differences observed. Moreover, 1 could argue that the ideal controls to evaluate the role of proinflammatory cytokines in the pathogenesis of APF would be normal skin from healthy subjects and normal skin of APF patients. However, we have decided to choose normal skin adjacent to noninflammatory lesions of subjects without any immune-mediated disorder as control to avoid the possible finding of an overexpression of inflammatory molecules. Another source of bias could be the location of the biopsy because the skin of areas different from major and minor folds is not involved in APF. Testing the normal skin of major and minor folds in APF patients before the development of the typical pustular lesions would be very interesting and could be the matter for future studies aimed at identifying early molecular changes preceding the onset of the cutaneous manifestations.

As a whole, our data show high values of proinflammatory cytokines, chemokines, and tissue damage effector molecules, sometimes associated with a few autoantibodies but without a clear underlying autoimmune/dysimmune disease, supporting the autoinflammatory origin of APF. This is in line with an increasing evidence that indicates clinical and immunological similarities between autoinflammatory and autoimmune diseases, giving rise to consider them as a single group of diseases with a large spectrum of immunologic and clinical abnormalities. The spectrum includes at one end pure autoinflammatory diseases and at the other end pure autoimmune diseases.^{34,35}

REFERENCES

- Oberlin P, Bagot M, Perrussel M, et al. Amicrobial pustulosis and systemic lupus erythematosus. *Ann Dermatol Venereol*. 1991;118:824–825.
- Marzano AV, Capsoni F, Berti E, et al. Amicrobial pustular dermatosis of cutaneous folds associated with autoimmune disorders: a new entity? *Dermatology*. 1996;193:88–93.
- Lagrange S, Chowsidow O, Piette JC, et al. A peculiar form of amicrobial pustulosis of the folds associated with systemic lupus erythematosus and other auto-immune diseases. *Lupus*. 1997;6:514–520.
- Marzano AV, Ramoni S, Caputo R. Amicrobial pustulosis of the folds. *Dermatology*. 2008;216:305–311.
- Marzano AV, Menicanti C, Crosti C, et al. Neutrophilic dermatoses and inflammatory bowel diseases. *G Ital Dermatol Venereol*. 2013;148:185–196.
- Wallach D, Vignon-Pennamen MD. From acute febrile neutrophilic dermatosis to neutrophilic disease: forty years of clinical research. *J Am Acad Dermatol*. 2006;55:1066–1071.
- Marzano AV, Ishak RS, Saibeni S, et al. Autoinflammatory skin disorders in inflammatory bowel diseases, pyoderma gangrenosum and Sweet's syndrome: a comprehensive review and disease classification criteria. *Clinic Rev Allerg Immunol*. 2013;45:202–210.
- de Jesus AA, Canna SW, Liu Y, et al. Molecular mechanisms in genetically defined autoinflammatory diseases: disorders of amplified danger signaling. *Annu Rev Immunol*. 2015;33:823–874.
- Marzano AV, Fanoni D, Antiga E, et al. Expression of cytokines, chemokines and other effector molecules in two prototypic autoinflammatory skin diseases, pyoderma gangrenosum and Sweet's syndrome. *Clin Exp Immunol*. 2014;178:48–56.
- Kerl K, Masouyé I, Lesarve P, et al. A case of amicrobial pustulosis of the folds associated with neutrophilic gastrointestinal involvement with systemic lupus erythematosus. *Dermatology*. 2005;211:356–359.
- Antille C, Frei M, Sorg O, et al. Amicrobial pustulosis of the folds associated with auto-immune disorders. A case report with an analysis of cytokine expression profile in skin lesions of cutaneous neutrophilic lupus. *Dermatology*. 2008;216:324–329.
- Saiag P, Blanc F, Marinho E, et al. Amicrobial pustulosis and systemic lupus erythematosus: a case. *Ann Dermatol Venereol*. 1993;120:779–781.
- Stefanidou MP, Kanavros PE, Stefanaki KS, et al. Amicrobial pustulosis of the folds: a cutaneous manifestation associated with connective tissue disease. *Dermatology*. 1998;197:394–396.
- Kuyama M, Fujimoto W, Kambara H, et al. Amicrobial pustular dermatosis in two patients with immunological abnormalities. *Clin Exp Dermatol*. 2002;27:286–289.
- Lopez-Navarro, Alcaide A, Gallego E, et al. Amicrobial pustulosis of the folds associated with Hashimoto's thyroiditis. *Clin Exp Dermatol*. 2009;34:e561–e563.
- Lee HY, Pelivani N, Beltraminelli H, et al. Amicrobial pustulosis-like rash in a patient with Crohn's disease under anti-TNF-alpha blocker. *Dermatology*. 2011;222:304–310.
- Marzano AV, Borghi A, Stadnicki A, et al. Cutaneous manifestations in patients with inflammatory bowel diseases: pathophysiology, clinical features, and therapy. *Inflamm Bowel Dis*. 2014;20:213–227.
- Weizman A, Huang B, Berel D, et al. Clinical, serologic, and genetic factors associated with pyoderma gangrenosum and erythema nodosum in inflammatory bowel disease patients. *Inflamm Bowel Dis*. 2014;20:525–533.
- Ott C, Schölmerich J. Extraintestinal manifestations and complications in IBD. *Nat Rev Gastroenterol Hepatol*. 2013;10:585–595.
- Vavricka SR, Schoepfer A, Scharl M, et al. Extraintestinal manifestations of inflammatory bowel disease. *Inflamm Bowel Dis*. 2015;21:1982–1992.
- Geremia A, Biancheri P, Allan P, et al. Innate and adaptive immunity in inflammatory bowel disease. *Autoimmun Rev*. 2014;13:3–10.
- Vanhove W, Peeters PM, Staelens D, et al. Strong upregulation of AIM2 and IFI16 inflammasomes in the mucosa of patients with active inflammatory bowel disease. *Inflamm Bowel Dis*. 2015;21:2673–2682.
- Aksentijevich I, Masters SL, Ferguson PJ, et al. An autoinflammatory disease with deficiency of the interleukin-1-receptor antagonist. *N Engl J Med*. 2009;360:2426–2437.
- Marrakchi S, Guigue P, Renshaw BR, et al. Interleukin-36-receptor antagonist deficiency and generalized pustular psoriasis. *N Engl J Med*. 2011;365:620–628.
- Dinarello CA. A clinical perspective of IL-1β as the gatekeeper of inflammation. *Eur J Immunol*. 2011;41:1203–1217.
- Oppenheim JJ, Zachariae CO, Mukaida N, et al. Properties of the novel proinflammatory supergene "intercrine" cytokine family. *Ann Rev Immunol*. 1991;9:617–648.
- Marzano AV, Cugno M, Trevisan V, et al. Role of inflammatory cells, cytokines and matrix metalloproteinases in neutrophil-mediated skin diseases. *Clin Exp Immunol*. 2010;162:100–107.
- Pene J, Chevalier S, Preisser L, et al. Chronically inflamed human tissues are infiltrated by highly differentiated Th17 lymphocytes. *J Immunol*. 2008;180:7423–7430.
- Dardalhon V, Korn T, Kuchroo VK, et al. Role of Th1 and Th17 cells in organ-specific autoimmunity. *J Autoimmun*. 2008;31:252–256.
- Nalbandian A, Crispin JC, Tsokos GC. Interleukin-17 and systemic lupus erythematosus: current concepts. *Clin Exp Immunol*. 2009;157:209–215.
- Ruddy MJ, Wong GC, Liu XK, et al. Functional cooperation between interleukin-17 and tumor necrosis factor-alpha is mediated by CCAAT/enhancer-binding protein family members. *J Biol Chem*. 2004;279:2559–2567.
- Agarwal S, Misra R, Aggarwal A. Interleukin 17 levels are increased in juvenile idiopathic arthritis synovial fluid and induce synovial fibroblasts to produce proinflammatory cytokines and matrix metalloproteinases. *J Rheumatol*. 2008;35:515–519.
- Delclaux C, Delacourt C, D'Ortho MP, et al. Role of gelatinase B and elastase in human polymorphonuclear neutrophil migration across basement membrane. *Am J Respir Cell Mol Biol*. 1996;14:288–295.
- Doria A, Zen M, Bettio S, et al. Autoinflammation and autoimmunity: bridging the divide. *Autoimmun Rev*. 2012;12:22–30.
- Lipsker D, Saurat JH. Neutrophilic cutaneous lupus erythematosus. At the edge between innate and acquired immunity? *Dermatology*. 2008;216:283–286.