

Endovascular Stenting of the Ascending Aorta for Type A Aortic Dissections in Patients at High Risk for Open Surgery

S. Ronchey^a, E. Serrao^a, V. Alberti^a, S. Fazzini^a, S. Trimarchi^b, J.L. Tolenaar^b, N. Mangialardi^{a,*}

^aDepartment of Vascular Surgery, San Filippo Neri Hospital, Via Martinotti 20, 00135 Rome, Italy

^bThoracic Aortic Research Center, Policlinico San Donato IRCCS, Milan, Italy

WHAT THIS PAPER ADDS

Endovascular treatment seems to be a potential option in patients with type A dissection at prohibitive risk for open surgery. At the moment there are only few reports in the literature and the technique is not standardised. This article underlines a preoperative study method and an operative technique. We hope it may be useful for surgeons approaching this new endovascular frontier.

Background: Open repair is the gold standard for type A aortic dissection (TAAD). Endovascular option has been proposed in very limited and selected TAAD patients. We report our experience with endovascular TAAD repair.

Methods: Inclusion criteria were: (1) entry tear in the ascending aorta; (2) proximal landing zone of at least 2 cm; (3) distance between entry tear and brachio-cephalic trunk of at least 0.5 cm; (4) no signs of cardiac tamponade or severe aortic regurgitation and (5) no signs of aortic branches ischaemia. Patients with cardiac revascularisation from ascending aorta were excluded.

Results: From April 2009 to June 2012, 37 patients with TAAD were admitted to our hospital. As many as 28 underwent surgical repair and 9 were considered at high surgical risk in a multidisciplinary meeting. Four met our inclusion criteria for an endovascular approach. Two of them had previous ascending aortic repair for TAAD and one had aortic valve replacement. Technical success was achieved in 100% of the patients. No mortality was registered during a median follow-up of 15 months (range 4–39 months), no migration of the graft and complete false lumen thrombosis of the ascending aorta in three patients.

Conclusion: Endovascular treatment of TAAD is challenging but feasible in a selected subset of patients. Further research remains mandatory.

© 2013 European Society for Vascular Surgery. Published by Elsevier Ltd. All rights reserved.

Article history: Received 13 September 2012, Accepted 23 January 2013, Available online 5 March 2013

Keywords: ascending aorta, dissection, endovascular repair

Type A aortic dissection (TAAD) is a cardiovascular catastrophe associated with high mortality. Medical treatment is associated to poor outcome with a mortality rate around 60%.^{1,2} Open surgical repair is the standard treatment for TAAD despite a high mortality/morbidity rate especially in high-risk patients, reported up to 60%.^{3,4} Because mortality is strongly related to both preoperative conditions of these patients and the invasiveness of the interventions, a less invasive approach would be highly beneficial.

Over the last decades endovascular therapies have emerged as the therapy of choice in patients with descending thoracic and abdominal aortic diseases.⁵ The introduction of new techniques and extensive experiences

have broadened the indications for these interventions, and even diseases affecting the ascending aorta can be treated. Primary reports focussed on retrograde type A dissections affecting the aortic arch in which the primary entry tear was located in the descending segment. These patients were treated by stent graft placement in the descending aorta.⁶ Currently, stent graft placement in the ascending aorta for the treatment of aneurysms, pseudoaneurysms, penetrating ulcers, intramural haematoma and even type A dissections has been described in anecdotal reports.^{7–9} Computed tomographic (CT) scan imaging studies show that endovascular repair is anatomically feasible in about 30% of patients with type A dissection with a proximal entry tear in the ascending aorta. This percentage of patients may increase up to 39% with the use of extra-anatomic bypass, like a left to right carotid–carotid bypass, in order to obtain an adequate distal landing zone.^{10,11}

In this study we present our initial experience with endovascular repair for TAAD patients by placement of a stent graft in the ascending aorta.

* Corresponding author. Tel.: +39 06 3306 3938; fax: +39 06 3306 2337.

E-mail addresses: s.ronchey@tiscali.it (S. Ronchey), n.mangialardi@sanfilippo.roma.it (N. Mangialardi).

1078-5884/\$ — see front matter © 2013 European Society for Vascular Surgery. Published by Elsevier Ltd. All rights reserved.

<http://dx.doi.org/10.1016/j.jvs.2013.01.033>

METHODS

Patient selection

Patients admitted to our institution with TAAD were evaluated by cardiac surgeons. Those considered at high risk for open ascending aortic repair and suitable for endovascular repair underwent a stent graft placement in the ascending aorta through an open femoral artery access. Inclusion criteria were: (1) entry tear in the ascending aorta; (2) distance between sinotubular junction and entry tear of at least 2 cm; (3) distance between entry tear and brachiocephalic trunk of at least 0.5 cm; (4) no signs of cardiac tamponade or severe aortic regurgitation; (5) no signs of ischaemia of aortic branches and (6) adequate femoral and iliac arteries. Patients with cardiac revascularisation from ascending aorta were excluded.

The option of stent graft placement was discussed with the patient, too. The patient agreed to undergo this procedure and written informed consent was obtained.

Imaging

Computed tomography angiography (CTA) images were acquired on multislice CT scan with a 0.625-mm detector configuration (manufacturer GE VCT 64 MD light speed, General Electric, Little Chalfont, Buckinghamshire, UK). Non-contrast images were first obtained and followed by acquisition of 1.25-mm axial images and retro-reconstruction at 0.625 mm from the origin of carotid arteries to the femoral arteries after intravenous injection of 80–90 ml of non-ionic contrast (400 mg ml^{-1}). Subsequently, the acquired CTA data sets were transferred to a workstation (OsiriX 3.9.4 – 64 bit) for analysis. A central lumen line was generated and the distance between the entry tear and the sinotubular junction and innominate artery were measured (Fig. 1). Stent graft selection was based on the aortic diameter measured at the level of the entry tear, with at least 10% oversizing in respect to the true lumen, but not exceeding the original aortic diameter. We performed a 20% of oversizing in case of previous ascending aortic graft replacement (20% of oversizing with respect to the graft diameter). The presence of pericardial effusion and aortic regurgitation was investigated with the use of trans-oesophageal echocardiography (TEE).

Procedure

All the procedures were performed under general anaesthesia, with a surgical femoral access. A guide wire was introduced in three cases through a percutaneous right brachial access into the arch and descending aorta as a rescue for supra-aortic vessels. In one case a reversed left common carotid (LCC) to right common carotid (RCC) and right subclavian artery (RSA) bypass was performed to obtain an adequate distal landing zone; an Amplatzer vascular plug II – 22 mm (St. Jude Medical, Plymouth, Minnesota, USA) was used to occlude the origin of the brachio-cephalic trunk. Through the femoral artery a Landrequist stiff guide wire (COOK, Inc., Bloomington, IN, USA)

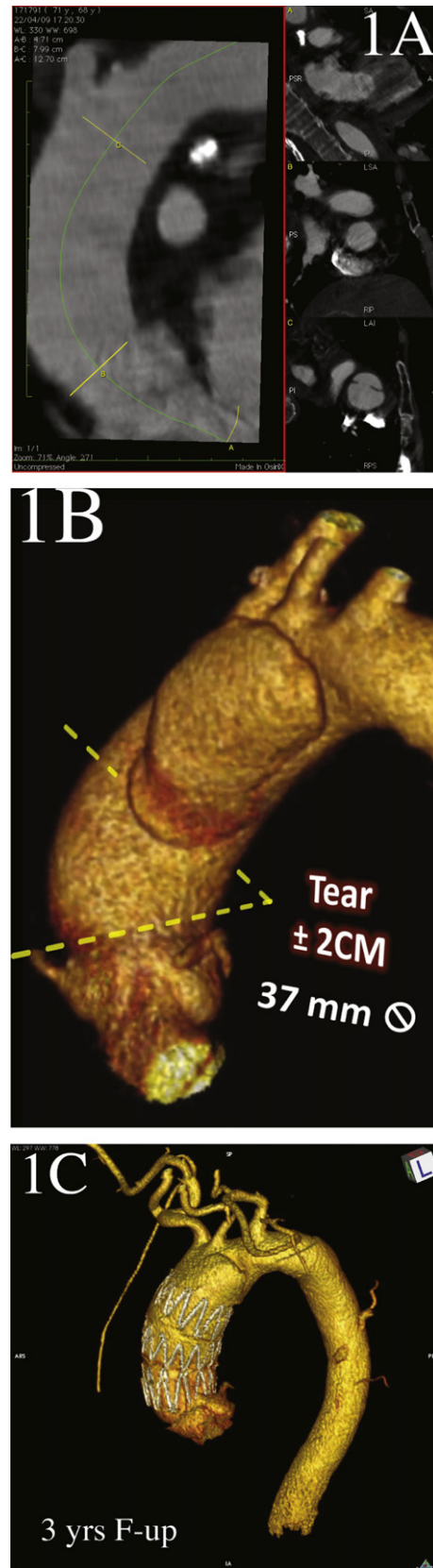


Figure 1. Limited type A dissection. (A) Center line. (B) 3D VR reconstruction. (C) 3 years Follow-up CT-scan: 3D VR reconstruction.

was positioned into the left ventricle. Under fluoroscopic guidance the graft was advanced into the ascending aorta. We used a standard Cook Zenith TX2 in one case and an off-the-shelf device for the ascending aorta (Cook, Inc., Bloomington, IN, USA) in two patients. Before deployment of the graft an angiography was performed to check for additional entry tears and extension of the dissection. Cardiac pacing (180 beats/min) was used to reach systolic blood pressure up to 40–60 mmHg to prevent dislodgement of the stent graft during deployment. Through a right common femoral vein we placed a temporary ventricular pacing wire in the apex of the right ventricle. TEE and completion angiography were used to verify the competence of the aortic valve, check the patency of the coronary arteries and supra-aortic branches and to evaluate the exclusion of the dissection.

RESULTS

Between April 2009 and June 2012, 37 patients with TAAD were submitted to the Emergency Department of our hospital, at the cardiac surgery department. Nine of them were considered at high risk for open surgery because of comorbidities and/or previous sternotomy. The anatomic characteristics of these patients were studied for an endovascular approach and four of them respected our inclusion criteria and were addressed to a stent graft position in the ascending aorta (two males: mean age 70 years; Table 1). All patients were smokers and had hypertension; one patient had atrial fibrillation. One patient had prior aortic valve repair and two patients had previous ascending aortic repair for TAAD (in one of them the ascending aortic repair was associated to the aortic valve replacement) with a residual entry tear in the ascending aorta. The patients with previous ascending aortic repair were first treated with analgesic and anti-hypertensive therapies without results. Three patients were operated in acute setting (<8 h after acute onset of symptoms), one of these because of brachiocephalic trunk symptomatic dissecting dilatation (32 mm, no neurologic signs, neck pain not responding to medical therapy) occurring 48 months after ascending aorta replacement. In one case the procedure was delayed (48 h). Mean operating time was 128 min (range 90–215 min). An LCC–RCC–RSA bypass was performed in one case. Technical success was achieved in 100% of the patients, with complete exclusion of the entry tear. Stent graft length ranged between 55 and 81 mm and diameter between 35

and 40 mm. No death was registered during follow-up (range 4–39 months, mean 15 months). One patient experienced a pulmonary oedema 2 months after the procedure, not operative related. Control CT scans demonstrated no migration of the graft. A complete false lumen thrombosis of the ascending aorta was obtained in three patients, whereas in one case the false lumen in the ascending aorta was still patent, without aortic enlargement. This patient remains asymptomatic at 9 months' follow-up.

In two patients the complete false lumen thrombosis of the descending thoracic aorta was obtained, whereas in the other two patients only a partial false lumen thrombosis was obtained (Tables 2 and 3).

DISCUSSION

With increasing aged population the incidence of TAAD is rising, especially in the elderly group.¹² In these patients open surgical repair is indicated, with graft replacement of the ascending aorta and, in the presence of aortic regurgitation, with valve resuspension or replacement. It has been reported that both preoperative clinical condition of the patient and invasive character of such procedures are associated with high mortality rates, ranging up to 60% in octogenarians.^{2–4} Medical therapy alone has a comparable or even worse outcome, and therefore less invasive treatment options, such as endovascular therapies, might be beneficial.^{1,2} Our study confirmed that, in a small selected subset of patients, stent graft placement in the ascending aorta for TAAD is feasible and may represent an effective and safe procedure.

In 2000 Dorros et al. reported the first case of TAAD treated with an endovascular technique through a trans-septal approach.¹³ Since then several authors have published their experiences, but the current literature remains sparse (Table 4). Ye et al. reported the largest series consisting of 10 patients with only midterm follow-up.¹⁴ These results seem promising if we consider the high-risk patients and their poor prognosis.

As the landing zones are located very close to the coronary and innominate arteries, stent graft placement in the ascending aorta may be performed only in selected cases. Two studies have been conducted to investigate the feasibility of stent graft placement in type A dissections.^{10,11} Moon et al. showed that in 162 patients with TAAD 32% were anatomically suitable for endovascular repair as there

Table 1. Baseline characteristics.

	Sex	Age	Co-morbidities	ASA/Euro-score	Time between symptoms and OR
Patient 1	F	69	Hypertension, Tabaco use	III/9.42%	<8 h
Patient 2	M	58	Hypertension, Tabaco use, previous ascending aorta replacement for type A dissection (2007)	III/34.93%	<8 h
Patient 3	F	78	Hypertension, diabetes, dyslipidemia, previous aortic valve replacement (2011)	III–IV/37.05%	<8 h
Patient 4	M	75	Hypertension, COPD, previous aortic valve replacement (2008), ascending aorta replacement for type A dissection (2012)	III–IV/34.38%	2 days

Table 2. Characteristics dissection and procedure.

	Diameter ascending aorta	Number of entry tears	Distance entry tear LSCA	Distance entry tear STJ	Type of stent graft	Measurements stent graft	Length of procedure (min)	Technical success	Additional procedure	In-hospital mortality	In-hospital morbidity
Patient 1	36	1	60	24	Cook TX2	40–31	90	Yes	No	No	No
Patient 2	32	1	30	45	OS Cook	38–73	215	Yes	Yes ^a	No	No
Patient 3	36	1	84	15	OS Cook	38–55	170	Yes	No	No	No
Patient 4	40	1	46	36	OS Cook	42–72	140	Yes	No	No	no

LSCA: left subclavian artery, STJ: sinotubular junction, AT: anonymous trunk, OS: off the shelf.

^a LCCA–RCCA–RSA bypass + AT embolisation.

Table 3. Follow-up.

	Length of FU (months)	Thrombosis FL ascending AO	Thrombosis FL descending AO	Ascending aortic diameter	Complications	Additional procedures	Mortality
Patient 1	39	Yes	Yes	34	No	No	No
Patient 2	15	Yes	Yes	30	No	No	No
Patient 3	9	No	Partial	36	No	No	No
Patient 4	4	Yes	Partial	34	No	No	No

was the absence of valvular involvement and appropriate length and diameter of proximal sealing zones.¹⁰ Hybrid procedures could be used to extend the applicability by combining a supra-aortic debranching procedure with endovascular stent graft placement. We performed this in one patient (Fig. 2). The use of a left-to-right carotid bypass can increase the feasibility of endovascular treatment of the ascending aorta up to 40% of all TAAD patients.¹¹

A thorough understanding of the anatomical limits of the aortic dissection and the adjacent anatomy is a prerequisite before such procedures are performed. Identification of the primary entry tear is essential for the success of stent grafting, although this may be a difficult process. The development of multi-detector-slice CT scanners and post-processing software has resulted in superior imaging with less artefacts, improving the sensitivity and specificity of this imaging modality.^{15,16} Three-dimensional reconstructions and virtual endoluminal imaging can be useful to

assess the size and location of the intimal tear and to determine the precise length and diameter of the stent graft for successful exclusion of the dissection.¹⁷ Other radiologic findings, such as pericardial effusion, aortic diameter, the diameters of true and false lumen and the status of thrombosis of the false lumen, may be helpful in planning the procedure.¹⁸

Endovascular procedures in TAAD patients harbour considerable risks. The aortic arch manipulation with guide wires and stent grafts can lead to extension of dissection or dislodgement of thrombus. To avoid such complications, in selected cases, a right carotid artery access for the stent graft can be used. This is also associated with an increased risk of stroke, so we preferred to perform all procedures from a femoral route. Aortic valve insufficiency is another important complication, which is associated with aortic dilatation due to the stent graft. This complication might be related to excessive oversizing.¹⁹ Based on this observation

Table 4. Review of literature.

First author	Year	Stentgraft	Number of patients	Acute (%)	30-day Mortality (%)	Endoleak (%)	CVA (%)	Late mortality (%)	Prev. interv	FU (m)
Dorros et al.	2000	Lacteba	1	1(100)	0(0)	0(0)	0(0)	0(0)	–	–
Kato et al.	2001	Home-made	7						0	3–42
Wang et al.	2003	COV Z-STENT	1	1(100)	0(0)	0(0)	0(0)	0(0)	–	–
Ihnken et al.	2004	GENERIC BARE, GORE	1	1(100)	0(0)	0(0)	0(0)	0(0)	0	–
Zhang et al.	2004	GIANTURCO Z	1	0(0)	0(0)	0(0)	0(0)	0(0)	0	12
Rayan et al.	2004	GORE			1(MPA)				–	–
Verhoye et al.	2006	COOK-Z	1	1(100)	0(0)	0(0)	0(0)	0(0)	–	–
Zimpfer et al.	2006	JOTEC	1	1(100)	0(0)	0(0)	0(0)	0(0)	0	0
Senay et al.	2007	GORE TAG	1	1(100)	0(0)	1(100)	0(0)	0(0)	0	0
Mussa et al.	2007	GORE TAG	1		1				1	0
Palma et al.	2008	BRAILE BIOMED	1	0(0)	0(0)	0(0)	0(0)	0(0)	–	–
Kische et al.	2008	COOK	2						–	–
Nienaber et al.	2011	VARIOUS	6						0	9–39
Ye et al.	2011	VARIOUS	10	6(60%)	1(10)	1(10)	2(20)	10	0	35.5
Metcalfe et al.	2012	Cook	1	1(100)	0(0)	0(0)	0(0)	0(0)	–	–

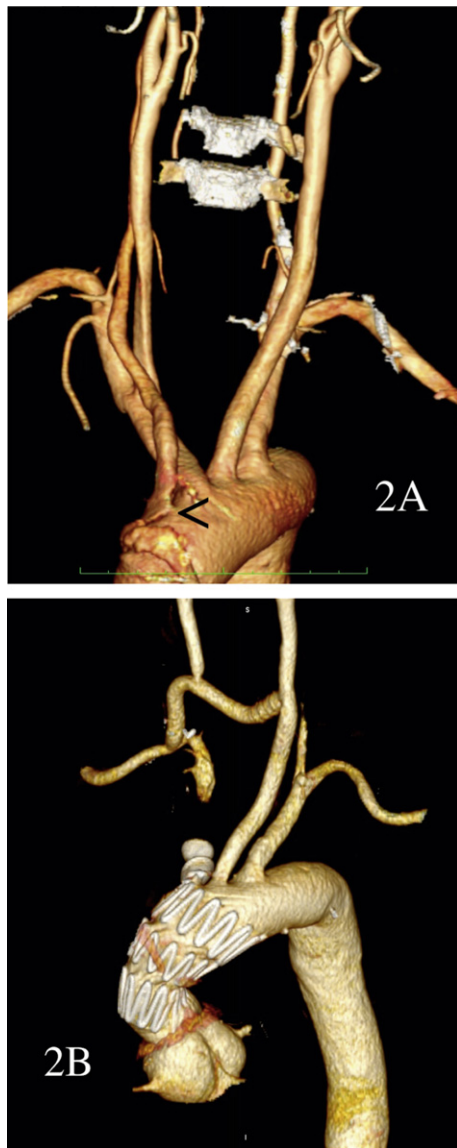

Figure 2. (A) Type A dissection after limited open repair extended to brachio-cephalic trunk and right common carotid artery: 3D VR reconstruction. (B) TEVAR in the ascending aorta + reversed LCC–RCC–RSA bypass. Plug into the brachio-cephalic trunk: 3D VR reconstruction.

we adopted a maximum oversizing of 10%. A complete TEE should be performed in all cases to assess cardiac and aortic valve function, in combination with an angiography to confirm the patency of the supra-aortic branches and coronary arteries.

Development of novel devices and techniques and increasing experience in these types of procedures are fundamental, before these techniques can be widely adopted. In our experience we used in three cases a device specifically designed from Cook for the ascending aorta, with a longer shaft (100 cm) and a short tip (2 cm) (Fig. 3). Recently Metcalfe et al. published their experience with the implementation of a stent in a TAAD patient, designed specifically for ascending aorta, consisting of a 65-mm covered component and proximal and distal bare stents.²⁰ Although the use of bare stents in aortic dissections




Figure 3. Cook off-the-shelf device for ascending.

remains highly debated, as it may induce a new dissection or a re-entry tear, the results of these developments, in combination with other studies, are eagerly awaited.^{21,22}

Our experience is limited to a small, atypical, number of patients with TAAD. Three of them had previous cardiac surgery. In these patients the natural risk of retrograde dissection, cardiac tamponade or aortic rupture was lower. A re-intervention was necessary because of the medical therapy failure, but open surgery was considered at high risk by a multidisciplinary team at our institute.

Again, previous ascending aortic replacement is another bias of this group of patients because it certainly eliminates the risk of retrograde dissection during TEVAR. However, the presence of a mechanical aortic valve made the procedure more technically demanding.

We propose endovascular treatment of the ascending aorta in a very selected number of cases and still consider open repair the gold standard.

CONCLUSION

Endovascular treatment of TAAD by placement of a stent graft in the ascending aorta is a challenging procedure due to the proximity of the aortic arch branches and coronary arteries. Our experience shows that this technique is feasible in selected patient categories, and it seems associated with

favourable results. Before this therapy can be implemented in the daily practice, further research is mandatory.

ACKNOWLEDGEMENTS

None.

CONFLICT OF INTEREST/FUNDING

None.

REFERENCES

- Hagan PG, Nienaber CA, Isselbacher EM, Bruckman D, Karavite DJ, Russman PL, et al. The International Registry of Acute Aortic Dissection (IRAD): new insights into an old disease. *J Am Med Assoc* 2000;283:897–903.
- Mehta RH, O’Gara PT, Bossone E, Nienaber CA, Myrmet T, Cooper JV, et al. Acute type A aortic dissection in the elderly: clinical characteristics, management, and outcomes in the current era. *J Am Coll Cardiol* 2002;40:685–92.
- Piccardo A, Regesta T, Pansini S, Concistre G, Dell’Aquila A, Scarano F, et al. Should octogenarians be denied access to surgery for acute type A aortic dissection? *J Cardiovasc Surg (Torino)* 2009;50:205–12.
- Trimarchi S, Eagle KA, Nienaber CA, Rampoldi V, Jonker FH, De Vincentis C, et al. Role of age in acute type A aortic dissection outcome: report from the International Registry of Acute Aortic Dissection (IRAD). *J Thorac Cardiovasc Surg* 2010;140:784–9.
- Dake MD, Miller DC, Semba CP, Mitchell RS, Walker PJ, Liddell RP, et al. Transluminal placement of endovascular stent-grafts for the treatment of descending thoracic aortic aneurysms. *N Engl J Med* 1994;331:1729–34.
- Kato N, Shimono T, Hirano T, Ishida M, Yada I, Takeda K. Transluminal placement of endovascular stent-grafts for the treatment of type A aortic dissection with an entry tear in the descending thoracic aorta. *J Vasc Surg* 2001;34:1023–8.
- Moon MC, Morales JP, Greenberg RK. The aortic arch and ascending aorta: are they within the endovascular realm? *Semin Vasc Surg* 2007;20:97–107.
- Nienaber CA, Kische S, Akin I, Liebold A, Weidtmann B, Incb H. Indications, timing and results of endovascular treatment of type A aortic dissection. *Eur J Vasc Endovasc Surg* 2011;18:187–91.
- Kolvenbach RR, Karmeli R, Pinter LS, Zhu Y, Lin F, Wassijew S, et al. Endovascular management of ascending aortic pathology. *J Vasc Surg* 2011;53:1431–7.
- Moon MC, Greenberg RK, Morales JP, Martin Z, Lu Q, Dowdall JF, et al. Computed tomography-based anatomic characterization of proximal aortic dissection with consideration for endovascular candidacy. *J Vasc Surg* 2011;53:942–9.
- Sobocinski J, O’Brien N, Maurel B, Bartoli M, Goueffic Y, Sassard T, et al. Endovascular approaches to acute aortic type A dissection: a CT-based feasibility study. *Eur J Vasc Endovasc Surg* 2011;42:442–7.
- Olsson C, Thelin S, Stahle E, Ekblom A, Granath F. Thoracic aortic aneurysm and dissection: increasing prevalence and improved outcomes reported in a nationwide population-based study of more than 14,000 cases from 1987 to 2002. *Circulation* 2006;114:2611–8.
- Dorros G, Dorros AM, Planton S, O’Hair D, Zayed M. Transseptal guidewire stabilization facilitates stent-graft deployment for persistent proximal ascending aortic dissection. *J Endovasc Ther* 2000;7:506–12.
- Ye C, Chang G, Li S, Hu Z, Yao C, Chen W, et al. Endovascular stent-graft treatment for Stanford type A aortic dissection. *Eur J Vasc Endovasc Surg* 2011;42:787–94.
- LePage MA, Quint LE, Sonnad SS, Deeb GM, Williams DM. Aortic dissection: CT features that distinguish true lumen from false lumen. *AJR Am J Roentgenol* 2001;177:207–11.
- Small JH, Dixon AK, Coulden RA, Flower CD, Housden BA. Fast CT for aortic dissection. *Br J Radiol* 1996;69:900–5.
- Hornero F, Cervera V, Estornell J, Rodriguez I, Buendia JA, Esteban JM, et al. Virtual vascular endoscopy for acute aortic dissection. *Ann Thorac Surg* 2005;80:708–10.
- Takami Y, Tajima K, Kato W, Fujii K, Hibino M, Munakata H, et al. Can we predict the site of entry tear by computed tomography in patients with acute type A aortic dissection? *Clin Cardiol* 2012;35:500–4.
- Zhang H, Li M, Jin W, Wang Z. Endoluminal and surgical treatment for the management of Stanford type A aortic dissection. *Eur J Cardiothorac Surg* 2004;26:857–9.
- Metcalfe MJ, Karthikesalingam A, Black SA, Loftus IM, Morgan R, Thompson MM, et al. The first endovascular repair of an acute type A dissection using an endograft designed for the ascending aorta. *J Vasc Surg* 2012;55:220–2.
- Williams JB, Andersen ND, Bhattacharya SD, Scheer E, Piccini JP, McCann RL, et al. Retrograde ascending aortic dissection as an early complication of thoracic endovascular aortic repair. *J Vasc Surg* 2012;55:1255–62.
- Zipfel B, Czerny M, Funovics M, Coppi G, Ferro C, Rousseau H, et al. Endovascular treatment of patients with types A and B thoracic aortic dissection using relay thoracic stent-grafts: results from the RESTORE Patient Registry. *J Endovasc Ther* 2011;18:131–43.