

# Occupational triphenyltin acetate poisoning: a case report

C Colosio, M Tomasini, S Cairoli, V Foà, C Minoia, M Marinovich, C L Galli

## Abstract

**A case of triphenyltin acetate (TPTA) poisoning is described. The patient, who had been exposed mainly to cutaneous absorption, showed acute stages of an urticarial eruption, signs of hepatic injury, slight glucose intolerance, and electroencephalographic abnormalities. Concomitant with the highest concentrations of tin in plasma and the peak of tin excretion in urine, neutrophils did not show the normal increase in actin polymerisation after stimulation with a chemotactic peptide (100 nM fMLP). The peak of urinary excretion of tin occurred between the fifth and the sixth day after poisoning; subsequently, the rate of excretion became slow, suggesting biphasic kinetics with the possibility of a cumulative trend.**

Triphenyltin acetate (TPTA) belongs to the group of organotin compounds used world wide as biocides. In Italy 500 000 Kg of organotin compounds were used in 1984.<sup>1</sup> Triphenyltin acetate is used as a molluscicide, an antifouling agent, a fungicide, and a rodent repellent.<sup>2</sup> About 25 years ago, a mixture of organotin compounds used for the treatment of boils, osteomyelitis, anthrax, and acne poisoned at least 217 people, of whom 100 died.<sup>3</sup> The most common clinical picture was characterised by impairment of the central nervous system (CNS) with interstitial oedema of the white matter.<sup>3</sup>

Cases of intoxication due to occupational exposure have also been published. The main route of absorption seems to be the respiratory tract. Some degree of cutaneous absorption, however, cannot be excluded.<sup>4-7</sup> The most common clinical findings were

headache, dizziness, photophobia, nausea, and vomiting. Sometimes temporary loss of consciousness, epileptic seizures, dermatitis, and asthenia were seen.<sup>4,5,7,8</sup> Laboratory findings included transitory hyperglycaemia, glycosuria, and an increase in activity of liver transaminases (alanine aminotransferase (ALT) and aspartate aminotransferase (AST)) that sometimes persisted weeks after poisoning.<sup>5</sup> Organotin compounds produce neurotoxicity and immunotoxicity in rats.<sup>9</sup> Trialkyltin compounds inhibit oxidative phosphorylation in mitochondria in vitro.<sup>10,11</sup> They also cause haemolysis of erythrocytes,<sup>12</sup> probably due to an interaction of erythrocyte membrane components with alkyl radicals.<sup>13</sup> They inhibit DNA synthesis and cAMP production in isolated rat thymocytes,<sup>14</sup> and impair chemotaxis and phagocytosis in rabbit neutrophils.<sup>15</sup>

Recently, an effect of organotin compounds on polymorphonuclear leucocytes (PMN) was shown. This consisted of a decrease in the amount of the polymerised form of actin in human neutrophils, with inhibition of the actin polymerisation normally detectable on stimulation of the cells with a chemotactic peptide (fMLP).<sup>16</sup>

## Case history

The patient, a man aged 36, was accidentally exposed to an unknown amount of 18.95% formulation TPTA (Brestan).

He was handling a package of the compound without gloves and spilt the pesticide powder on the exposed cutaneous area of his arms. He washed immediately but about 12 hours later experienced bilateral plantar pain and, after around 24 hours, severe genital oedema. Some hours later an erythematous eruption appeared on his trunk (see fig 1). In the past he had had similar accidents with TPTA without reporting any adverse effects on his health. Two days after the accident, the patient had general malaise, dizziness, nausea, and abdominal pain for which he was admitted to hospital.

On admission, temperature, pulse rate, and blood pressure were normal; physical examination showed slight genital oedema, urticarial eruptions on his trunk, and pronounced hepatomegaly (lower liver margin about 5 cm below the costal margin). Blood glucose concentration was 113 mg/100 ml (normal

---

Istituto di Medicina del Lavoro, Università degli Studi di Milano, 20122 Milano, Italia  
C Colosio, M Tomasini, S Cairoli, V Foà

Fondazione Clinica del Lavoro, Laboratorio Igiene Industriale, Pavia, Italia  
C Minoia

Istituto de Scienze Farmacologiche, Università degli Studi di Milano, 20100 Milano, Italia  
M Marinovich, C L Galli

---

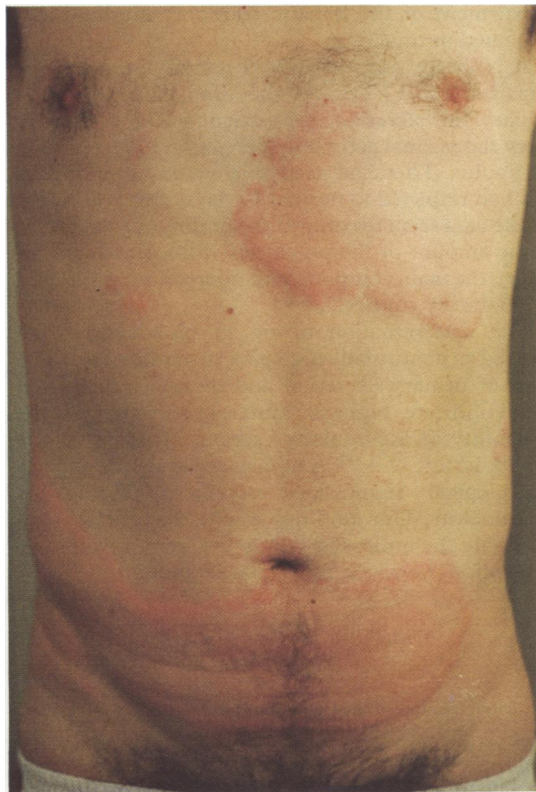

Figure 1 Urticarial eruption on the patient exposed to triphenyltin acetate.

value 60–110),  $\gamma$ -glutamyl transpeptidase ( $\gamma$ -GT) 68 IU/l, and bilirubin 1.52 mg/100 ml (normal value 0.36). Other routine laboratory findings were normal. A glucose tolerance test on the fifth day showed impairment of glucose metabolism and slight glycosuria.

The day after admission to hospital, activity of serum transaminases was high (AST 76 IU/l, ALT 198 IU/l). Some indices of inflammation were also raised (mucoproteins 165 mg/dl (normal value 55–140); C-reactive protein 67  $\mu$ g/ml (normal value 0–5)).

The rise in activity of transaminase persisted, with a progressive decrease for 18 days. When the patient was discharged 21 days after the accident, ALT (41 IU/l) and  $\gamma$ -GT (75 IU/l) activities were still slightly high.

Despite steroid treatment 8, 10, 12, and 14 days after the poisoning, the patient showed recrudescences of urticarial eruption on his trunk and arms.

Allergological investigation, performed by patch tests with entire Brestan and with each single component in its formulation, did not produce any positive results.

Ten days after the accident, an electroencephalogram (EEG) showed alterations consisting of generalised paroxysmal abnormalities in a picture of bradyrhythmia. On the 11th day serum IgE was raised (543 IU/ml (normal value < 200)). Twelve days after poisoning a hepatic echotomography showed a generalised enlargement of the liver. Examination of a liver needle biopsy specimen taken three days later showed slight and non-specific inflammatory abnormalities. A focal mononuclear lobular infiltration was found accompanied by slight steatosis that could be attributed to a daily alcohol intake of around 200 g.

The patient was discharged 21 days after the poisoning, apparently completely recovered. Somewhat high ALT and  $\gamma$ -GT activities with slight hepatomegaly persisted. During the next five months, the patient suffered from periodic urticaria on his trunk and arms. The cutaneous eruptions were attenuated by antihistamines, and reappeared when treatment was stopped. About six weeks after the poisoning he developed angioedema which persisted for several days. Four months after the poisoning, the EEG showed slight anomalies during hyperpnea.

#### Laboratory investigations

The intake of TPTA was estimated by determining the concentration of tin in blood and urine. Ten samples of blood and eight samples of urine were taken between the second and the 19th day after poisoning. One sample of blood and two samples of urine (morning and evening) were taken five months later. Analyses were performed by atomic absorption spectroscopy.<sup>17</sup> On the fourth, eighth, and 16th day circulating neutrophils were separated by the method of Boyum,<sup>18</sup> and stimulated with 100 nM fMLP. The increase in actin polymerisation was then determined using the NBD phalloidin staining method.<sup>19</sup> This test was repeated five months later. The peak of urinary tin excretion occurred between the fifth and the sixth day (96  $\mu$ g/l, fig 2) and decreased to a concentration of about 30  $\mu$ g/l by the eighth day.

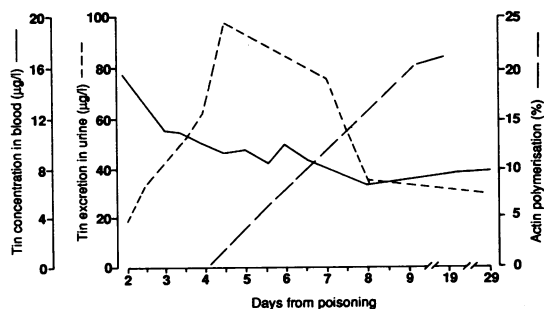


Figure 2 Time sequence of PMN actin polymerisation and tin excretion in patient exposed to triphenyltin acetate.

Subsequently, the rate of excretion decreased; one month after the poisoning a urinary concentration of 28  $\mu\text{g/l}$  was found. This was still higher than the tin concentration in the urine sample taken two days after the poisoning (18  $\mu\text{g/l}$ ).

Reference values are not available but in our experience values range from six to 30  $\mu\text{g/l}$  in non-exposed subjects. Tin disappeared rapidly from the plasma, most being lost between the second and fourth day concomitant with the increase in urinary excretion. A second, small peak in tin concentration in blood was found on the sixth day (fig 2).

On the fourth day, the PMNs did not show any increase in actin polymerisation in comparison with PMNs of healthy human subjects ( $p < 0.01$ ); on the eighth day, the PMNs had recovered somewhat, although their activity was still lower than that of healthy human subjects ( $p < 0.01$ ). Activity of PMNs was normal by 16 days after the accident (fig 2).

## Discussion

The patient showed usual signs of organotin poisoning—namely, dizziness, nausea, possible impairment of the central nervous system, and liver damage.

Our clinical findings seem to confirm results obtained in animals indicating that TPTA is less neurotoxic than other organotin compounds as the patient showed only electroencephalographic anomalies with no clinical evidence of impairment of the CNS. The bilateral plantar pain suffered 12 hours after the poisoning could be a sign of slight impairment of the peripheral nervous system.

Other organotin compounds—for example, tributyl and dibutyltin—cause cutaneous erythema due to an irritative effect<sup>8</sup>; the patient under study did not show any such effect. The severe genital oedema and the urticarial eruption with an increase in circulating IgE, which persisted in spite of steroid treatment and without exposure to TPTA, have not previously been described as associated with organotin poisoning. On the basis of the history of the patient we believe we can attribute these findings to TPTA poisoning. The lack of evidence of cutaneous sensitisation to the components of the product may be due to the presence of unknown metabolites acting as antigens; the persistence of urticarial eruptions could be interpreted as a chronic urticaria caused by the unknown antigen(s) and not depending on a mechanism belonging to the first group of Gell and Coomb's classification.

The mechanism by which the liver is damaged by organotin compounds is still not clear; some authors have postulated an impairment of the hepatic transport mechanism or the conjugation of bilirubin with glutathione, or both.<sup>5</sup> In our case the concentration of serum bile acid, measured to evaluate possible

impairment of the hepatic transport mechanism,<sup>20</sup> remained normal.

It is interesting that PMN activity seems to be impaired by TPTA. At the time of the peak of urinary tin excretion, the patient's PMNs did not show the normal actin polymerisation in response to a stimulus. They had partly recovered by eight days and had returned to normal 16 days after poisoning. These data seem to confirm the findings of a decrease in the amount of the polymerised form of actin (F-actin), the main component of microfilaments, found in laboratory studies.<sup>16</sup>

The determination of tin in blood and urine showed an abnormally high concentration of tin. The rates of urinary excretion and disappearance from blood indicate biphasic kinetics, and suggest the possibility of a cumulative action. No data on the metabolic fate of TPTA in man are available and the toxicological significance of these findings is still unclear. Our findings imply that TPTA can penetrate the unbroken skin; a degree of respiratory absorption, however, cannot be excluded.

- 1 Central Institute of Statistics (ISTAT). *Statistiche agrarie 1984*. Vol 32. Rome: ISTAT, 1988.
- 2 World Health Organisation. *Tin and organotin compounds. Environmental health criteria*. 15th ed. Geneva: WHO, 1980.
- 3 Alajovanine T, Derobert L, Thieffry S. Clinical study of 210 cases of poisoning with organic tin salts. *Rev Neurol (Paris)* 1958;98:85-96.
- 4 Guardascione V, Mazzella di Bosco M. Contributo alla conoscenza della patologia professionale da antiparassitari. Su tre casi di intossicazione acuta da fungicidi a base di trifenilacetato di stagno. *Lavoro Umano* 1967;19:307-13.
- 5 Manzo L, Richelmi P, Sabbioni E, Pietra R, Bono F, Guardia L. Poisoning by triphenyltin acetate. Report of two cases and determination of tin in blood and urine by neutron activation analysis. *Clinical Toxicology* 1981;18:1343-53.
- 6 Piscator M. Tin. In: Friberg L, Nordberg GF, Vouk VB, eds. *Handbook on the toxicology of metals*. Holland: Elsevier Biomedical Press, 1979;37:613-26.
- 7 Pollini G, Biscaldi GP, Moglia A, Pugliese F. Intossicazione sub-acuta da trifenilacetato e trifenilidrossido di stagno: considerazioni su un caso clinico. *Bollettino della Società Medico Chirurgica di Pavia*. 1980;94:9-13.
- 8 Lyle WH. Lesions of the skin in process workers caused by contact with butyltin compounds. *Br J Ind Med* 1958;15:193-6.
- 9 Snoeji NJ, Van Iersel AA, Penninks AH, Seinen W. Toxicity of triorganotin compounds: comparative in vivo studies with a series of trialkyltin compounds and triphenyltin chloride in male rats. *Toxicol Appl Pharmacol* 1985;81:274-86.
- 10 Aldridge VN, Street BW. Biochemical effects and properties of some trialkyltins. *Biochem J* 1964;91:187-297.
- 11 Matsui H, Wada O, Ushijima Y, Mizuta T. Inhibition of oxidative metabolism in rabbit polymorphonuclear leukocytes by triphenyltin chloride. *Arch Toxicol* 1983;54:227-33.
- 12 Byington KM, Yem RY, Forte LR. The hemolytic activity of some trialkyltin and triphenyltin compounds. *Toxicol Appl Pharmacol* 1974;27:230-40.
- 13 Ali AA, Upreti RK, Kidwai AM. Interaction of di- and tributyltin chloride with human erythrocyte membrane. *Toxicol Lett* 1987;38:13-8.
- 14 Shoeij NJ, Punt PM, Penninks AM, Seinen W. Effects of tri-n-butyltin chloride on energy metabolism, macromolecular synthesis, precursor uptake and cyclic AMP production in isolated rat thymocytes. *Biochim Biophys Acta* 1986;852:234-43.

- 15 Elferink JGR, Deierkauf M, Van Steveninck J. Toxicity of organotin compounds for polymorphonuclear leukocytes. The effects of phagocytosis and exocytosis. *Biochem Pharmacol* 1986;**35**:3727-32.
- 16 Marinovich M, Sanghui A, Colli S, Tremoli E, Galli CL. Cytoskeletal modifications induced by organotin compounds in human neutrophils. *Toxicology in vitro*. 1990;**4**:2.
- 17 Chamsaz N, Winefordner JD. Determination of inorganic and organotin compounds in seawater by graphite furnace. *Journal of Analytical Atomic Spectrometry* 1988;**3**:119-22.
- 18 Boyum A. Isolation of Mononuclear cells and granulocytes from human blood. *Scand J Clin Lab Invest* 1968;**97**:77-85.
- 19 Wallace PJ, Wersto RP, Packman CH, Litchman MA. Chemotactic peptide-induced changes in neutrophil actin conformation. *J Cell Biol* 1984;**99**:1060-5.
- 20 Anonymous. Serum bile acids in Hepatobiliary disease. *Lancet* 1982;**ii**:1136-8.

Accepted 23 July 1990