

## Short Report

# Germline mosaicism in Rett syndrome identified by prenatal diagnosis

Mari F, Caselli R, Russo S, Cogliati F, Ariani F, Longo I, Bruttini M, Meloni I, Pescucci C, Schurfeld K, Toti P, Tassini M, Larizza L, Hayek G, Zappella M, Renieri A. Germline mosaicism in Rett syndrome identified by prenatal diagnosis.

Clin Genet 2004: 67: 258–260. © Blackwell Munksgaard, 2004

Rett syndrome is an X-linked neurodevelopmental dominant disorder that affects almost exclusively girls. The vast majority of cases are sporadic and are caused by *de novo* mutations in the *MECP2* gene, located in Xq28. Only few familial cases have been reported: in four cases, the mother was an asymptomatic carrier and in other four cases, the germline mosaicism in the mother was postulated. Owing to the above reported cases of germline mosaicism, we decided to offer prenatal diagnosis to all expectant mothers with a Rett daughter despite the absence of the causative mutation in parents' blood. We describe here the outcome of the first nine cases of prenatal diagnosis followed by our center. In eight cases, the fetus did not carry the mutation. In one case, the female fetus did carry the same mutation of the affected sister. The couple decided to interrupt the pregnancy and to devolve fetal tissues for research purposes. Our results indicate that prenatal diagnosis should be proposed to all couples with a Rett daughter, even when the mutation is apparently *de novo*. Moreover, one positive prenatal test among the first nine cases indicates that germline mosaicism may be seriously considered for the assessment of recurrence risk during genetic counseling.

**F Mari<sup>a</sup>, R Caselli<sup>a</sup>, S Russo<sup>b</sup>,  
F Cogliati<sup>b</sup>, F Ariani<sup>a</sup>, I Longo<sup>a</sup>,  
M Bruttini<sup>a</sup>, I Meloni<sup>a</sup>, C Pescucci<sup>a</sup>,  
K Schurfeld<sup>c</sup>, P Toti<sup>c</sup>,  
M Tassini<sup>d</sup>, L Larizza<sup>b</sup>, G Hayek<sup>e</sup>,  
M Zappella<sup>e</sup> and A Renieri<sup>a</sup>**

<sup>a</sup>Medical Genetics Unit, Department of Molecular Biology, University of Siena, Siena, <sup>b</sup>Laboratory of Molecular Biology, Istituto Auxologico Italiano, Milan, <sup>c</sup>Department of Anatomy and Pathology, <sup>d</sup>Centro Universitario di Risonanza Magnetica Nucleare, University of Siena, and <sup>e</sup>Department of Child Neuropsychiatry, Azienda Ospedaliera Senese, Siena, Italy

Key words: genetic counseling – germline mosaicism – prenatal diagnosis – RTT

Corresponding author: Alessandra Renieri, MD, PhD, Associate Professor, Medical Genetics Unit, University of Siena, Policlinico Le Scotte, viale Bracci 2, 53100 Siena, Italy.  
Tel.: +39 0577 233303;  
Fax: +39 0577 233325;  
e-mail: renieri@unisi.it

Received 3 September 2004, revised and accepted for publication 16 November 2004

As soon as the gene responsible for Rett syndrome (RTT) was discovered, we started performing molecular analysis of *MECP2* gene in the RTT females who were admitted to the Child Neuropsychiatry of the University of Siena (1). We also started to collect parents' samples in order to verify whether the mutation was *de novo* or inherited. In 115 apparently sporadic cases diagnosed from 1999 till today, the mutation was not found in parents' DNA except for one case where the same *MECP2* mutation was found in both a RTT girl and her unaffected mother (unpublished data). As germline mosaicism was reported in RTT, we decided to offer prenatal diagnosis in case of a second pregnancy of the above reported couples even with a *de novo* mutation. This suggestion was clearly stated in the counseling report. During the

last 4 years, nine couples decided to have a pregnancy and accepted the suggestion to perform a prenatal diagnosis. These nine prenatal diagnoses were performed by chorionic villous sampling in five cases and by amniocentesis in the other four. In eight cases, the fetus DNA was normal and pregnancies were successfully delivered. Five girls and three boys were born and every child, aged from 6 months to 4 years, is presently healthy. In one case, we detected in the fetus the same *MECP2* mutation of the affected sister (Table 1).

### Case report

We first met the family for genetic counseling during an hospitalization of the affected daughter in the Child Neuropsychiatry, University of Siena

Table 1. Prenatal tests performed from 2000 till today

Year	<i>MECP2</i> mutation type in the affected daughter	Prenatal test	Sex of the fetus	Result	Mother's age (years)	Father's age (years)
2000	p.Y141X	Chorionic villous sampling	Female	Negative	34	40
2000	p.R453X	Amniocentesis	Female	Negative	39	45
2002	p.R306C	Amniocentesis	Male	Negative	36	39
2002	p.T158M	Chorionic villous sampling	Male	Negative	31	Unknown
2003	p.R168X	Amniocentesis	Male	Negative	37	51
2003	p.P152R	Chorionic villous sampling	Female	Negative	30	36
2003	p.R133C	Amniocentesis	Female	Negative	31	44
2003	p.R270X	Chorionic villous sampling	Female	Negative	33	39
2003	c.567insA	Chorionic villous sampling	Female	Positive	38	38

(Fig. 1a). The proband (No. 709) is the second child of non-consanguineous parents and she was 3 years old at the time of the counseling. She had a normal development in the first 6 months. Then her progress ceased. The ability to use her hands was overwhelmed by incessant hand stereotypes, and hyperventilation and groundless smiles were referred. At 3 years of age, she still had lallation and she was not able to walk. Her head circumfer-

ence was 45 cm (<3°cnt). She fulfilled the criteria for RTT (2). As a collateral finding, sarcosin, which is not normally detectable in urine and plasma, was detected in this patient in both urine (6.53–9.66 mmol/l) and plasma (0.16–0.17 mmol/l).

We offered a molecular analysis of *MECP2* gene to the family. Blood was collected from the proband and her parents after informed consent. The genomic DNA was extracted and coding exons 2–4 of *MECP2* gene were amplified and directly sequenced. In the DNA of the proband, the c.567-568insA mutation was found in heterozygous state. Either of the parents did not carry the mutation and there was no evidence of low-grade mosaicism by denaturing high performance liquid chromatography (DHPLC) analysis (Fig. 1b). The suggestion for prenatal diagnosis in case of a future pregnancy was clearly stated during the second session of genetic counseling together with the explanation of the molecular results.

One year after the genetic counseling, the parents, 38 years old each, decided to have a third pregnancy and asked for prenatal diagnosis. The couple decided to go through chorionic villous sampling at 13 weeks + 5 days of gestation. The extracted DNA was analyzed for the presence of the c.567-568insA mutation by DHPLC and direct sequencing. The DNA of the female fetus was found to have the same mutation of the RTT sister (Fig. 1b). In agreement with the couple, we decided to repeat the analysis on a second chorionic villous sampling on the sixteenth week of gestation. The result was confirmed and the couple decided to abort the fetus on the seventeenth week + 1 day of gestation. The fetus was aborted through prostaglandin induction. On the DNA extracted from the umbilical cord, we again confirmed the presence of the c.567-568insA mutation (data not shown).

The whole fetus was devolved to our institute for research purposes. We collected samples from different areas of the brain and from other organs (thymus, liver, spleen, placenta, kidneys, heart, adrenal glands, lung, esophagus, stomach, intestine, and pancreas) for tissue culture, molecular biology tests,

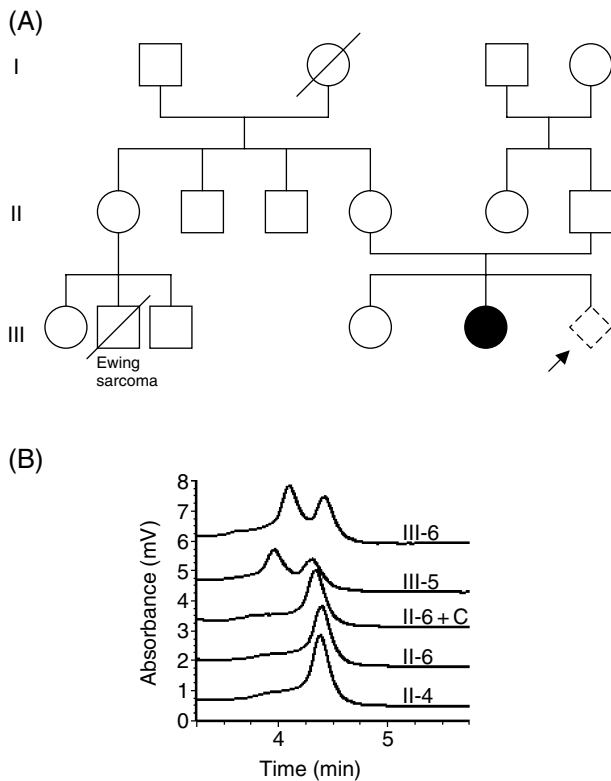


Fig. 1. (a) Pedigree of the family. (b) DHPLC analysis of the c.567-568insA mutation. The chromatograms (top to bottom) represent polymerase chain reaction products from chorionic villous sample (III-6), affected daughter (III-5), a 1:1 mixture of the father and a healthy control male (II-6 + C), father alone (II-6) and mother (II-4). The father, mother and the mixture of the father and a healthy control male show the same homoduplex peak. The chorionic villous sample and the affected daughter demonstrate a heteroduplex formation.

and histological analysis. Morphological analysis of the brain showed a normal picture. However, the detection of subtle differences in the architectural pattern should require a comparison with a fetus of the same gestational age. This control sample is difficult to obtain, as in voluntary abortion usually pregnancy is interrupted in an earlier gestational age.

## Discussion

Rett syndrome is an X-linked neurodevelopmental dominant disorder that affects almost exclusively girls. The vast majority of cases is sporadic and is caused by *de novo* mutations in *MECP2* gene. Only few familial cases, with a documented *MECP2* mutation, have been reported. For some of them, the explanation resides in the fact that the mother is an asymptomatic carrier (3–6). In other cases, four in all, germline mosaicism in the mother was postulated. Wan et al. (3) reported of a woman with motor-coordination problems and mild learning disabilities, her RTT sister, her RTT daughter, and her son who died of encephalopathy. All the four individuals carried the same *MECP2* mutation. Her parents did not carry the mutation suggesting germline mosaicism (3, 4). In 1999, Amir et al. (7) reported of two half sisters with clinical and molecular diagnosis of RTT. The mutation was not present in their mother suggesting germline mosaicism. Another identical case was reported by Villard et al. (8). Yaron et al. reported of a RTT girl and her brother with severe neonatal encephalopathy, carrying the same *MECP2* mutation. The asymptomatic mother did not carry the mutation (9).

In the four familial cases reported above, the *MECP2* mutation was maternally derived. Trappe et al. observed that in sporadic cases of RTT, the origin of the *MECP2* mutation was almost exclusively paternal (10). Yaron et al. state that we should be more careful in defining a risk of recurrence in those cases where the mutation is maternally derived (9). In order to strengthen this hypothesis, it would have been useful to establish the origin of *MECP2* mutation in our case. Unfortunately, in our family the *MECP2* mutation origin could not be derived.

So far, expression studies in human tissues have used adult RTT brain only (11). The availability of this fetal brain will allow us to study *MECP2* expression, its localization, and gene-expression profiling in a particular developmental stage. Furthermore, this material will allow us to study the possible effects of *MECP2* absence on brain structure and on neuronal morphology and plasticity.

This is the first reported case of mosaicism found after a prenatal diagnosis. The frequency of germline mosaicism in RTT is at present unknown. The

small number of cases (nine) does not allow to derive a correct percentage ( $1/9 = 11\%$ ) useful for genetic counseling. However, taking into account our experience, mosaicism should not be considered so rare. Despite the fact that the precise rate of germline mosaicism of *MECP2* mutations remains unknown, our results strongly indicate that the opportunity to perform a prenatal diagnosis should be discussed with all couples with a RTT daughter despite the apparently *de novo* mutation.

## Acknowledgements

This work was supported by Telethon grants GGP02372A and GTF02006, by the Emma and Ernesto Rulfo Foundation, by the Ministero della Salute (Progetti di Ricerca Finalizzata, D.L. 502/92-2003), by MIUR (FIRB 01) and by the University of Siena (PAR 2001 and PAR 2002) to A.R.

This work was also supported by the Ministero della Salute (Progetti di Ricerca Finalizzata NEMEC) to L.L.

## References

1. De Bona C, Zappella M, Hayek G et al. Preserved speech variant is allelic of classic Rett syndrome. *Eur J Hum Genet* 2000; 8: 325–330.
2. Trevathan E, Moser HW. Diagnostic criteria for Rett syndrome. *Ann Neurol* 1988; 23: 425–428.
3. Wan M, Lee SS, Zhang X et al. Rett syndrome and beyond: recurrent spontaneous and familial *MECP2* mutations at CpG hotspots. *Am J Hum Genet* 1999; 65: 1520–1529.
4. Schanen N, Dahle EJ, Capozzoli F et al. A new Rett syndrome family consistent with X-linked inheritance expands the X chromosome exclusion map. *Am J Hum Genet* 1997; 61 (3): 634–641.
5. Zappella M, Meloni I, Longo I et al. Preserved speech variants of the Rett syndrome: molecular and clinical analysis. *Am J Med Genet* 2001; 104 (1): 14–22.
6. Gill H, Cheadle JP, Maynard J et al. Mutation analysis in the *MECP2* gene and genetic counselling for Rett syndrome. *J Med Genet* 2003; 40: 380–384.
7. Amir RE, Van den Veyver IB, Wan M et al. Rett syndrome is caused by mutations in X-linked *MECP2*, encoding methyl-CpG-binding protein 2. *Nat Genet* 1999; 23: 185–188.
8. Villard L, Levy N, Xiang F et al. Segregation of a totally skewed pattern of X chromosome inactivation in four familial cases of Rett syndrome without *MECP2* mutation: implications for the disease. *J Med Genet* 2001; 38 (7): 435–442.
9. Yaron Y, Ben Zeev B, Shomrat R et al. *MECP2* mutation in Israel: implications for molecular analysis, genetic counseling, and prenatal diagnosis in Rett syndrome. *Hum Mutat* 2002; 20 (4): 323–324 (available from <http://www.interscience.wiley.com/humanmutation/pdf/mutation/540.pdf>).
10. Trappe R, Laccione F, Colibanschi J et al. *MECP2* mutations in sporadic cases of Rett syndrome are almost exclusively of paternal origin. *Am J Hum Genet* 2001; 68: 1093–1101.
11. Colantuoni C, Jeon O-E, Hyder K et al. Gene expression profiling in postmortem Rett syndrome brain: differential gene expression and patient classification. *Neurobiol Dis* 2001; 8: 847–865.