

# Glandular Odontogenic Cyst- An Unusual Presentation in the Maxilla

ISHITA SINGHAL<sup>1</sup>, APARNA DAVE<sup>2</sup>, MANPREET ARORA<sup>3</sup>, PULIN SALUJA<sup>4</sup>

## ABSTRACT

The Glandular Odontogenic Cyst (GOC) is thought to be a developmental cyst arising from the remnants of dental lamina. This cyst has an unpredictable and a potentially aggressive behaviour, with a worldwide prevalence of 0.17%. It occurs in patients aged 40-70 years, occurring exclusively in the anterior mandibular jaw. Here, authors presents a case of 42-year-old male patient reported to the Department of Oral Medicine and Radiology with a chief complaint of pain in the upper right back tooth region since five days. Two radiolucencies were observed in the maxillary anterior and posterior regions, as an incidental finding in the radiographic examination. Cone Beam Computed Tomography (CBCT) revealed two separate unilocular homogeneously hypodense regions with radiopaque sclerotic borders in the maxillary arch, located in the anterior and posterior regions of the maxilla, crossing the midline, which is quite rare. A final diagnosis of GOC was made based on the histopathological examination of the specimen after complete enucleation. Diagnosis of this cyst is challenging clinically and radiographically, as it can be confused with other cysts or malignancies of the jaws. Hence, diagnosis of GOC can only be based on characteristic histopathological findings.

**Keywords:** Goblet cells, Hobnail cells, Mucous cells, Pseudostratified squamous epithelium, Unilocular

## CASE REPORT

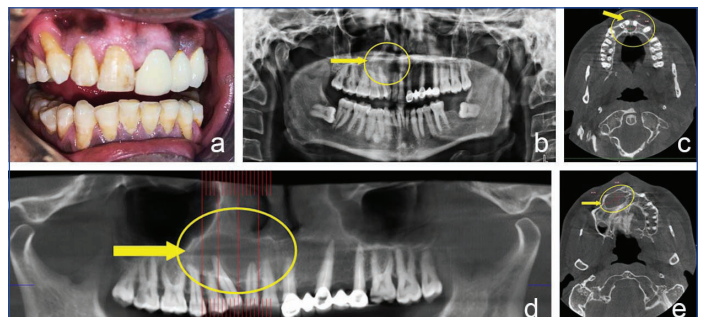
A 42-year-old male patient, reported to the Department of Oral Medicine and Radiology, with a chief complaint of dull and continuous pain in the upper right back tooth region while eating since five days.

Intraoral examination revealed tenderness on percussion in relation to 16, 17 and 18. Gingiva was oedematous and pink in colour with melanin pigmentation. Generalised gingival recession from cemento-enamel junction to cervical third of the root was evident. There was no swelling reported in the associated area and the teeth did not exhibit any mobility [Table/Fig-1a]. The patient gave a history of extraction in relation to 22, 24 and 47 three years ago, and subsequently a fixed prosthesis extending from 21 to 25 was provided. The patient also had a habit of smoking 8-10 bidis per day, for 15-20 years. There was no significant medical history. Based on the patient's history and clinical examination, a provisional diagnosis of chronic apical periodontitis in relation to 16, 17 and 18 was made.

On radiographical examination, Orthopantomogram (OPG) revealed an ill-defined radiolucency on the distal surface of the crown region of 17 and on the mesial surface of the crown region of 18, indicating proximal caries in relation to 17 and 18. There was an additional incidental finding in the OPG, which revealed a unilocular well-defined radiolucency with a radiopaque sclerotic border in the anterior maxillary region, involving the apices of 11, 12, 13 and 14 [Table/Fig-1b]. On clinical examination, the teeth showed no mobility and the percussion test was also negative. Pulp vitality test was done using Waldent Electric Pulp Vitality Tester in relation to 11, 12, and 13 which showed immediate response, indicating that the associated teeth were vital.

Cone Beam Computed Tomography (CBCT) revealed two separate unilocular homogeneously hypodense regions with radiopaque sclerotic borders in the maxillary arch: An oval shaped lesion extending from the periapical portion of 11 to 21 palatally, measuring 9.00 mm (mesiodistally)×7.05 mm (labiopalatally)×8.85 mm (superior-inferiorly) in size [Table/Fig-1c] and a large ellipsoidal shaped lesion extending from mesial aspect of 11 to 15, measuring 21.73 mm×13.29 mm×15.56 mm in size [Table/Fig-1d and e]. The lesion involved both the anterior and posterior regions in the maxilla. Based on the radiological findings, a diagnosis of odontogenic cyst was made and differential

diagnoses of odontogenic keratocyst, nasopalatine cyst and unicystic ameloblastoma were taken into consideration. Routine blood investigations were done. The patient was referred to the Department of Oral and Maxillofacial Surgery for cyst enucleation and was also referred to the Department of Conservative and Endodontics for root canal treatment, followed by post and core and fixed prosthesis in relation to 17 and restoration of 18.



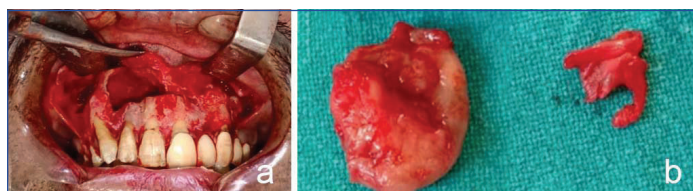
**[Table/Fig-1]:** a) Intraoral photograph with no sign of swelling; b) Orthopantomogram (OPG) revealed a unilocular well-defined radiolucency with a radiopaque sclerotic border in the right maxillary anterior region, involving the apices of 11, 12, 13 and 14; c) Cone Beam Computed Tomography image in axial plane: An oval shaped, unilocular homogeneously hypodense region extending from the periapical portion of 11 to 21 palatally, measuring 9×7.05×8.85 mm in size; d) Medium Field of View CBCT scan of maxillary arch revealing a unilocular homogeneously hypodense region extending from mesial aspect of 11 to 15; e) Cone Beam Computed Tomography image in axial plane: A large ellipsoidal shaped, unilocular homogeneously hypodense region extending from mesial aspect of 11 to 15, measuring 21.73×13.29×15.56 mm in size.

In the Department of Oral and Maxillofacial Surgery, the surgical site was painted with cipladine 5% solution to achieve asepsis and then the patient was draped. Infraorbital and nasopalatine blocks were given with Indoco Warren Lignox Lignocaine 2% with adrenaline 1:80,000 concentration. A crevicular incision with posterior releasing with Bard Parker blade (BP blade) number-15 was placed from 16 to 23 region, and then the mucoperiosteal flap of full thickness was raised till the vestibular depth. A bony window was created with the help of a round bur and the cystic lining was exposed. The cystic lesion was completely enucleated and chemical cauterization with carnoy's solution for both the cyst was performed [Table/Fig-2a].

Irrigation of the cystic cavity was done with cipladine 5% solution and then the flap was closed by interrupted suture with Ethicon vicryl

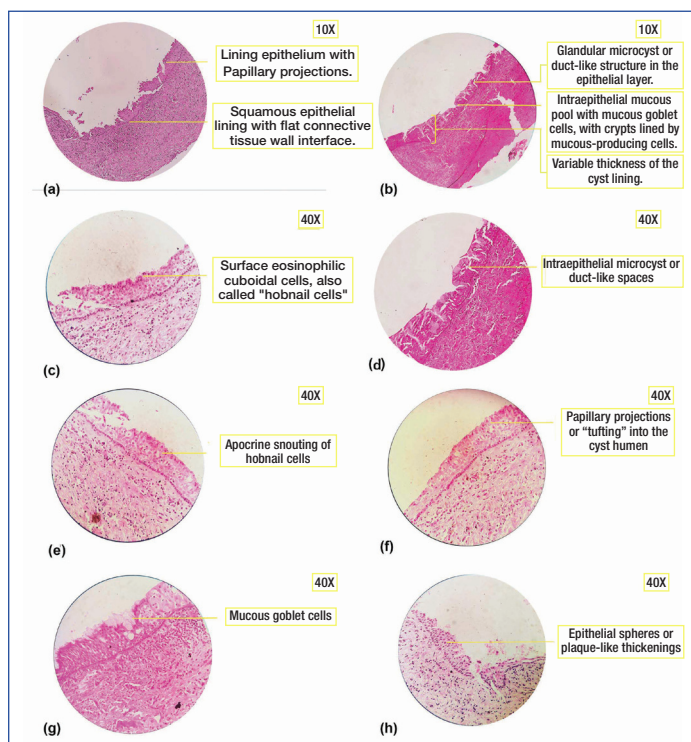
suture 3-0 polyglactin 910 SH-1 27" coated absorbable braid violet and 22 mm 1/2 circle reverse cutting needle taper point.

The excised specimen was sent to the Department of Oral Pathology for histopathological evaluation. Two soft tissue specimens were received by the Department of Oral Pathology, measuring 20 mm×15 mm from the labial side and 8 mm x 6 mm from the palatal side. Macroscopically, the submitted tissues were firm in consistency and creamish-white in colour [Table/Fig-2b].



**[Table/Fig-2]:** a) Enucleation with curettage; b) Two soft tissue specimens were received by the Department of Oral Pathology, measuring 20×15 mm from the labial side, and 8×6 mm from the palatal side; Macroscopically, they were creamish-white in colour and firm in consistency.

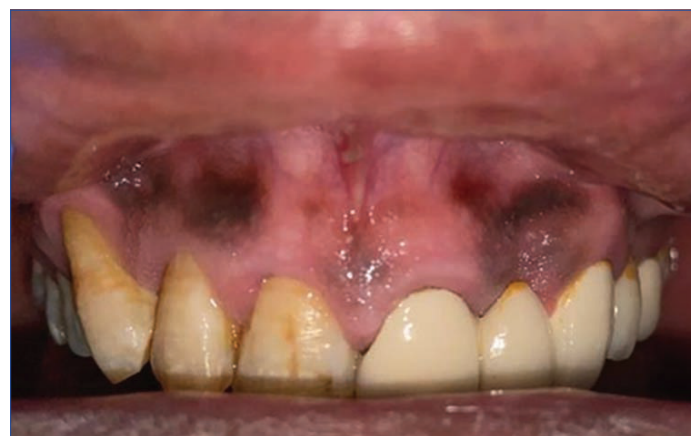Microscopic examination of Haematoxylin and Eosin (H&E) stained soft tissue specimens exhibited a cystic lining that was non keratinised stratified squamous type [Table/Fig-3a] and was of variable thickness with a flat interface connective tissue wall [Table/Fig-3b]. The superficial epithelial layer showed hobnail cells and the basal and parabasal layers showed clear vacuolated cells. The epithelial layer had papillary projections with glandular microcyst or duct-like structures throughout the epithelium [Table/Fig-3b-f]. At places, the epithelial layer exhibited ciliated pseudostratified columnar cells with intraepithelial mucous goblet cells [Table/Fig-3b,g]. At one place, plaque like thickening was evident [Table/Fig-3h]. Underlying connective tissue showed bundles of collagen fibres,



**[Table/Fig-3]:** a) Microscopic examination of H&E stained soft tissue section exhibited a cystic lining that was non keratinised stratified squamous type with flat connective tissue wall interface. The epithelial lining showed papillary projections (10 X); b) Microscopic examination of H&E stained soft tissue section exhibited a cystic lining with variable thickness. The epithelial layer was composed of glandular microcyst or duct-like structures and mucous goblet cells (10 X); c) Microscopic examination of H&E stained soft tissue section exhibited hobnail cells on the surface eosinophilic cuboidal cells (40 X); d) Microscopic examination of H&E stained soft tissue section exhibited apocrine snouting of hobnail cells in the superficial epithelial layer (40 X); e) Microscopic examination of H&E stained soft tissue section exhibited intra-epithelial microcysts or duct like spaces (40 X); f) Microscopic examination of H&E stained soft tissue section exhibited papillary projections (tuffing) into the cystic lumen (40 X); g) Microscopic examination of H&E stained soft tissue section exhibited mucous goblet cells in the epithelial layer (40 X); h) Microscopic examination of H&E stained soft tissue section exhibited plaque like thickenings in the epithelial layer (40 X).

dense inflammatory cell infiltrate, blood vessels and macrophages. Correlating clinically, radiographically and histopathologically, a final diagnosis of GOC was made.

The patient was followed-up for a year and there was no sign of recurrence [Table/Fig-4].



**[Table/Fig-4]:** The patient was followed-up for a year and there was no sign of recurrence.

## DISCUSSION

Odontogenic cysts are relatively common lesions occurring in the oral cavity, and they form a major part of the total biopsies received by any Oral Pathologist. This diversified group of lesions exhibit varying presentations in the maxilla and mandible, ranging from a small innocuous lesion to a highly aggressive and destructive lesion, which may even transform into a malignancy [1].

GOC was first documented in 1987, by Padayachee Arun and Van Wyk CW as Sialo-Odontogenic Cyst. Two cases were reported having identical clinical, radiographical and histopathological characteristics of both botryoid odontogenic cyst and central mucoepidermoid tumor. This cyst was suggested to be of salivary gland origin, as it exhibited mucous cells and pools of mucin in the epithelial lining [2]. Later Gardner DG et al., in 1988, described eight cases of this cyst in his article and renamed it as GOC, suggesting that the term sialo odontogenic cyst was used informally and so should be abandoned. The cystic lining exhibited ball-like plaques, reminiscent of those seen in the periodontal cysts and adenomatoid odontogenic cysts with pools of mucicarmine positive material within the epithelium, which suggested it to be of odontogenic origin [3].

In 2017, World Health Organisation (WHO) classified GOC under odontogenic cysts histopathologically, and described it as developmental cyst with stratified squamous epithelial lining that simulates salivary gland or glandular differentiation" [4]. There are less than 200 cases of GOC reported all over the world so far [5]. It is clinically rare and histopathologically unusual cyst with an unpredictable and potentially aggressive behaviour, with a frequency of 0.012-1.3% of all the jaw cysts [6,7]. It is common in patients aged between 40-70 years, with a male predilection [8].

Clinically, patients usually exhibit a painless, slowly growing intra-osseous lesion, involving the anterior region of the mandible, but in the literature, there are few cases reported involving the anterior region of the maxilla [9-12]. Urs AB et al., have observed expansion in relation to the cystic lesion along with thinning, erosion, or perforation of the cortical plates in some of their cases [13]. At times, the lesion can also cause nerve compression or any other secondary infections in the jaw, which can lead to severe pain [14]. Li L et al., in 2016, described the recurrence of pain in their patient due to compression of the posterior superior alveolar nerve by the lesion [7]. In the present case, the lesion was completely asymptomatic, involving both the maxillary anterior and posterior region, which is quite uncommon. Radiographically, GOC is localised intraosseously presenting as either a unilocular or a



multilocular radiolucent lesion, surrounded by radiopaque sclerotic margin [8]. At times, GOC can also cause perforation of the cortex bone along with tooth displacement and resorption [9]. It can mimic other developmental cysts like dentigerous cysts, lateral periodontal cyst or globulomaxillary cyst [15,16]. Their differentiating features are presented in [Table/Fig-5]. In this case, GOC presented as two separate unilocular lesions located in the anterior and posterior regions of the maxilla, crossing the midline which is quite rare and there is no such case reported in the scientific literature.

Glandular odontogenic cyst	Dentigerous cyst	Lateral periodontal cyst	Globulomaxillary cyst
Well-defined radiolucency, with scalloped sclerotic margins.	Well-defined radiolucency, usually associated with hyperostotic borders unless they are secondarily infected.	Cyst is seen as a round or ovoid, well-defined radiolucency with hyperostotic borders.	Cyst appears as pear-shaped or tear-shaped radiolucency. Small end of the pear is directed toward the crest of alveolar ridge.
It is a unilocular or multilocular radiolucency.	Usually, it is unilocular but sometimes it may appear multilocular.	It is a unilocular lesion.	It is a unilocular region.
It is usually found at the apex of the tooth.	Cyst may envelop the crown symmetrically, but it may expand laterally from the crown. Cyst is usually attached with the cemento-enamel junction.	It is usually found between the cervical margins and the apex of adjacent root surfaces and may or may not be in contact with root surfaces.	It develops between apex of both the vital teeth.
Mostly associated with anterior mandibular region.	Mostly associated with impacted mandibular and maxillary third molars and canines.	Mostly associated with vital mandibular canine and premolar area and is followed by the anterior region of the maxilla.	Mostly associated with maxillary lateral incisor and canine area.
Age: 30-40 years	Age: 11-30 years	Age: 22-85 years	Age: 20-40 years

[Table/Fig-5]: Radiographic differentiating features of GOC [16].

Histopathologically, GOC shows multiple features. However, often all the features are seen only at focal areas or not all the features are seen in the cyst. In addition, few of these features are known to occur in other lesions such as Botryoid-Odontogenic Cyst, Radicular Cyst, Dentigerous Cyst, or Low-Grade-Mucoepidermoid Carcinoma [17].

To avoid this confusion, Gardner DG et al., gave few microscopic parameters that were adapted from previously reported microscopic features of GOC [Table/Fig-6] [3].

The cyst is lined with stratified squamous epithelium of varying thickness, exhibiting a flat interface with the underlying connective tissue without any inflammatory infiltrate.
The superficial layer of the epithelium consists of eosinophilic cuboidal cells making the surface irregular and sometimes papillary.
Cilia may be present on the surface of eosinophilic cuboidal cells.
Pools of mucicarmine-positive material are present within the epithelium.
Mucous cells are usually prominent on the surface.
Basal cells are sometimes hyperchromatic and may be vacuolated.
Epithelial cells may be arranged into apparently spherical structures.
Irregularly shaped calcifications may be present in the connective tissue beneath the epithelium.

[Table/Fig-6]: Microscopic features given by Gardner DG et al., (1988) [3].

The features of Gardner DG et al., were later modified by Kaplan I et al., and divided the features into major and minor criteria. As a guideline, authors suggested that atleast focal presence of each of the major criteria should be mandatory, whereas minor criteria need not be present for diagnosis, but may just support it [14] [Table/Fig-7].

Major criteria	Minor criteria
Squamous epithelial lining with flat connective tissue wall interface, lacking basal palisading [Table/Fig-3a]	Lining epithelium with papillary projections [Table/Fig-3a]
Variations in thickness of epithelial lining with or without epithelial sphere or whorls or focal luminal proliferation [Table/Fig-3b]	Ciliated cells
Cuboidal eosinophilic cells or "hobnail" cells [Table/Fig-3c]	Multicystic or multiluminal architecture
Intraepithelial mucous pool with mucous goblet cells, with or without crypts lined by mucous-producing cells [Table/Fig-3b]	Clear or vacuolated cells in basal or spinous layer
Glandular microcyst or duct-like structure in the epithelial layer [Table/Fig-3b]	

[Table/Fig-7]: Microscopic features given by Kaplan I et al., (2005) [14].

Fowler CB et al., recorded ten microscopic parameters of GOC [18] [Table/Fig-8]. Authors suggested that a combination of specific microscopic features, not necessarily corresponding with their major and minor criteria, can appear to be helpful in making an accurate diagnosis of GOC. So, he proposed the presence of 7 or more microscopic parameters that were highly predictive of diagnosis of GOC, and presence of 5 or less microscopic parameters that were highly predictive of non GOC or GOC mimicker [18].

Surface eosinophilic cuboidal cells, also called "hobnail cells" [Table/Fig-3c]
Intraepithelial microcysts or duct-like spaces [Table/Fig-3e]
Apocrine snouting of hobnail cells [Table/Fig-3d]
Clear or vacuolated cells
Variable thickness of the cyst lining [Table/Fig-3b]
Papillary projections or "tufting" into the cyst lumen [Table/Fig-3a,f]
Mucous goblet cells [Table/Fig-3g]
Epithelial spheres or plaque-like thickenings [Table/Fig-3h]
Cilia on the surface of eosinophilic cuboidal cells
Multiple compartments

[Table/Fig-8]: Microscopic features given by Fowler CB et al., (2011) [18].

In the present case, on histopathological evaluation, the haematoxylin and eosin slide revealed non keratinised stratified squamous type epithelium of varying thickness. The superficial epithelial layer showed hobnail cells and the basal and parabasal layers showed clear vacuolated cells. The epithelial layer had papillary projections with glandular microcyst or duct-like structures throughout the epithelium. At places, the epithelial layer exhibited ciliated pseudostratified columnar cells with intraepithelial mucous goblet cells. At one place, plaque like thickening was evident. These features led to the diagnosis of GOC.

Treatment is generally influenced by the size of lesion, involvement of the teeth, cortical bone perforation, history of recurrence and proximity to vital anatomic structures. The preferred choice of treatment involves enucleation or curettage, and to avoid recurrence 1.0 to 1.5 cm margins and some overlying mucosa is resected from the jaw [19]. The GOC has been associated with high recurrence rate of 21-55%, because of its multilocular nature, tendency of thin epithelium to separate from underlying connective tissue capsule thus making removal difficult at the time of surgery and because of conservative treatment of the lesion [16]. Follow-up should be continued for atleast six months to three years by clinical examination and radiographic examination, to avoid recurrence of this cyst [19].

## CONCLUSION(S)

Glandular Odontogenic Cyst (GOC) being a rare and a unique lesion, exhibits many variations clinically and radiographically. Hence, it can create a problem in diagnosis, as it mimics many other odontogenic cysts. A proper histopathological evaluation and its correlation with the clinical findings is necessary. Since, the lesion is aggressive and is

associated with high recurrence rate, it further more emphasises the need of correct diagnosis of this rare entity. It has been suggested to follow-up these cases for a period of one year.

## REFERENCES

- [1] Gul S, Shah AA, Bashir S, Bashir S. Different treatment modalities for OKC of jaws. *Int J Res Health Allied Sci.* 2020;6(3):118-20.
- [2] Padayachee A, Van Wyk CW. Two cystic lesions with features of both the botryoid odontogenic cyst and the central mucoepidermoid tumour: Sialo-odontogenic cyst? *J Oral Pathol.* 1987;16(10):499-504.
- [3] Gardner DG, Kessler HP, Morency R, Schaffner DL. The glandular odontogenic cyst: An apparent entity. *J Oral Pathol.* 1988;17(8):359-66.
- [4] El-Naggar, Adel K, John KC, Chan, Grandis J, Rubin, Takashi Takata, and Pieter J. Slootweg. *WHO Classification of Head and Neck Tumours.* 2017. Print.
- [5] Kadam VD, Changule GR, Choudhary SH, Gade LP. Glandular odontogenic cyst in a young Indian female: A rare case report with review of literature. *J Indian Acad Oral Med Radiol.* 2020;32(3):300.
- [6] Chandolia, Betina & Bajpai, Manas & Arora, Manika. (2017). Glandular Odontogenic Cyst. *J Coll Physicians Surg Pak.* 2017;27(3):S23-25.
- [7] Li L, Singh P, Ping J, Li X. Glandular odontogenic cyst of posterior maxilla: A rare entity. *Int J Case Rep Imag.* 2016;7(4):254-60.
- [8] Yanduri S, Deepa KK, Kumar BV, Suma S, Madhura MG, Vakade CD. Glandular odontogenic cyst: Analysis of clinicopathological features of five cases. *Indian Journal of Oral Health and Research.* 2017;3(1):40.
- [9] Olawuyi AB, Effiom OA, Ogundana O, Odukoya O. Glandular odontogenic cyst of the maxilla in a Nigerian: Case report and review of literature. *Port Harcourt Med J.* 2017;11:103-06.
- [10] Jafarian AH, Rahpeyma A, Khajehahmadi S. Recurrent glandular odontogenic cyst of maxilla-a case report. *Iran J Pathol.* 2015;10(2):160.
- [11] Rao JB, Kumar KJ, Kumar BP. Glandular odontogenic cyst involving the posterior part of maxillary sinus, a rare entity. *J Maxillofac Oral Surg.* 2010;9(1):72-75.
- [12] Ogura I, Tsuchimochi M, Ono J, Kanri Y, Okada Y, Fujii K, et al. Glandular odontogenic cyst: a report of four cases. *Oral Science International.* 2017;14(2):43-49.
- [13] Urs AB, Kumar P, Augustine J, Malhotra R. Glandular odontogenic cyst: Series of five cases. *J Oral Maxillofac Pathol.* 2017;21(2):239.
- [14] Kaplan I, Gal G, Anavi Y, Manor R, Calderon S. Glandular odontogenic cyst: Treatment and recurrence. *J Oral Maxillofac Surg.* 2005;63(4):435-41.
- [15] Shah M, Kale H, Ranginwala A, Patel G. Glandular odontogenic cyst: A rare entity. *J Oral Maxillofac Pathol.* 2014;18(1):89.
- [16] Ferreira JC, Vêncio EF, de Sá RT, Gasperini G. Glandular odontogenic cyst in dentigerous relationship: An uncommon case report. *Case Rep Dent.* 2019;2019:8647158.
- [17] Shah AA, Sangle A, Bussari S, Koshy AV. Glandular odontogenic cyst: A diagnostic dilemma. *Indian J Dent.* 2016;7(1):38.
- [18] Fowler CB, Brannon RB, Kessler HP, Castle JT, Kahn MA. Glandular odontogenic cyst: analysis of 46 cases with special emphasis on microscopic criteria for diagnosis. *Head Neck Pathol.* 2011;5(4):364-75.
- [19] Marx RE, Stern D. *Oral and maxillofacial pathology: A rationale for diagnosis and treatment.* Hanover Park: Quintessence Publishing Company; 2012.

### PARTICULARS OF CONTRIBUTORS:

1. Postgraduate Student, Department of Oral Pathology and Microbiology and Forensic Odontology, SGT Dental College Hospital and Research Institute, Gurugram, Haryana, India.
2. Professor and Head, Department of Oral Pathology and Microbiology and Forensic Odontology, SGT Dental College Hospital and Research Institute, Gurugram, Haryana, India.
3. Professor, Department of Oral Pathology and Microbiology and Forensic Odontology, SGT Dental College Hospital and Research Institute, Gurugram, Haryana, India.
4. Reader, Department of Oral Pathology and Microbiology and Forensic Odontology, SGT Dental College Hospital and Research Institute, Gurugram, Haryana, India.

### NAME, ADDRESS, E-MAIL ID OF THE CORRESPONDING AUTHOR:

Dr. Aparna Dave,  
Professor and Head, Department of Oral Pathology and Microbiology and Forensic Odontology, SGT Dental College, Hospital and Research Institute, Gurugram, Haryana, India.  
E-mail: [aparna.dave@sgtuniversity.org](mailto:aparna.dave@sgtuniversity.org)

### PLAGIARISM CHECKING METHODS: [Lain H et al.](#)

- Plagiarism X-checker: Jun 16, 2021
- Manual Googling: Sep 20, 2021
- iThenticate Software: Sep 30, 2021 (16%)

### ETYMOLOGY: Author Origin

### AUTHOR DECLARATION:

- Financial or Other Competing Interests: None
- Was informed consent obtained from the subjects involved in the study? Yes
- For any images presented appropriate consent has been obtained from the subjects. Yes

Date of Submission: **Jun 11, 2021**

Date of Peer Review: **Aug 16, 2021**

Date of Acceptance: **Sep 24, 2021**

Date of Publishing: **Oct 01, 2021**