



Case Report

Desensitization of olipudase alfa-induced anaphylaxis in a child with chronic neurovisceral acid sphingomyelinase deficiency

Laura Fiori^a, Veronica Maria Tagi^{a,b}, Chiara Montanari^{a,b}, Mirko Gambino^a,
Veronica Carlevatti^c, Carmela Zizzo^d, Enza D'Auria^a, Dario Dilillo^a, Elvira Verduci^{a,e,*},
Gianvincenzo Zuccotti^{a,b}

^a Department of Pediatrics, Buzzi Children's Hospital, Milan, Italy

^b Department of Biomedical and Clinical Science, University of Milan, Milan, Italy

^c Hospital Pharmacy Department, ASST Fatebenefratelli-Sacco, Vittore Buzzi Children's Hospital, Milan, Italy

^d Institute for Biomedical Research and Innovation (IRIB) National Research Council (CNR), Palermo, Italy

^e Department of Health Sciences, University of Milan, Milan, Italy

ARTICLE INFO

Keywords:

ASMD
Acid sphingomyelinase
Olipudase alfa
Anaphylaxis
Desensitization
Enzyme replacement therapy

ABSTRACT

Olipudase alfa is indicated for the non-central nervous system manifestations of Acid sphingomyelinase deficiency (ASMD). Anaphylaxis is a very rare and life-threatening adverse reaction described for this drug. Here, we report the case of a 2-year-old boy affected by chronic neurovisceral ASMD who experienced signs of hypersensitivity reactions to olipudase alfa since the administered dose of 1 mg/kg during dose escalation and a proper anaphylactic reaction during the second administration of the target therapeutic dose of 3 mg/kg. The treatment was stopped for 15 weeks and then a 7-step desensitization protocol with the infused dose of 0.03 mg/kg was applied. Subsequent gradual dose escalation was resumed, successfully reaching the dose of 0.3 mg/kg. Moreover, biochemical, and radiological disease indexes, which were increased during treatment discontinuation, have gradually improved since the restart of treatment. However, at the second administration of the dose of 0.6 mg/kg, the patient experienced another adverse drug reaction with facial urticarial rash and bronchospasm, requiring the administration of adrenaline, methylprednisolone, and inhaled salbutamol. This case report highlights the need to customize the olipudase alfa desensitization protocol according to individual tolerance and raises the issue of achieving the established therapeutic target in the most sensitive children.

Synopsis: We report a case of anaphylaxis to olipudase alfa in a child affected by chronic neurovisceral Acid sphingomyelinase deficiency (ASMD) and describe a 7-step desensitization procedure. This procedure, with the total administered dose of 0.03 mg/kg, followed by gradual dose escalation, allowed to reach the dose of 0.3 mg/kg without adverse reactions; however, at the second administration of the dose of 0.6 mg/kg our patient presented another adverse reaction suggesting the need of a different desensitization strategy.

1. Introduction

Acid sphingomyelinase deficiency (ASMD) is a rare lysosomal storage disorder (LSD) resulting from bi-allelic mutations in SMPD1 gene, leading to progressive accumulation of sphingomyelin in different organs. [1] The estimated global prevalence is about 1:100,000–1,000,000. [2]

On the basis of its phenotype and natural history, ASMD is classified into infantile neurovisceral (ASMD A), chronic neurovisceral (ASMD A/B or intermediate ASMD) and chronic visceral (ASMD B).

Infantile neurovisceral ASMD presents with severe visceral and neurological involvement presenting within the first 6–10 months of life with progressive psychomotor deterioration, culminating in death usually by the age of 3 years. Chronic visceral ASMD manifests with a protracted, multi-systemic, oligosymptomatic course, with no or minimal neurological impairment. Its natural history encompasses a broad spectrum of manifestations and severity. Survival typically extends well into adulthood, and in some instances, approaches normalcy. Patients may experience prolonged periods of stability spanning years. Patients with chronic neurovisceral ASMD have visceral manifestations similar to

* Corresponding author at: Department of Pediatrics, Buzzi Children's Hospital, Milan, Italy.

E-mail address: elvira.verduci@unimi.it (E. Verduci).

<https://doi.org/10.1016/j.ymgmr.2024.101120>

Received 25 October 2023; Received in revised form 30 January 2024; Accepted 8 July 2024

Available online 17 July 2024

2214-4269/© 2024 The Authors. Published by Elsevier Inc. This is an open access article under the CC BY-NC license (<http://creativecommons.org/licenses/by-nc/4.0/>).

chronic visceral ASMD but with an earlier onset, sometimes accompanied by mild neurological symptoms [3]. Non-treated patients survive beyond early childhood, extending sometimes into adulthood. [2]

ASMD non-neurological symptoms include hepatosplenomegaly, liver dysfunction leading to fibrosis, interstitial lung disease, thrombocytopenia, and coagulation defects, dyslipidaemia, osteopenia, growth failure and delayed puberty. [4,5]

In the past, ASMD management was restricted to supportive care, with a very low life expectancy and poor life quality. [6,7]. Disease natural history has been modified by the introduction of olipudase alfa, a recombinant human acid sphingomyelinase that hydrolyses sphingomyelin. Like other enzyme replacement therapies (ERTs), olipudase alfa does not cross the blood–brain barrier. In summer 2022 the U.S. Food and Drug Administration approved olipudase alfa for the treatment of non-central nervous system (CNS) manifestations in chronic neurovisceral and chronic visceral ASMD.

Clinical trials demonstrated olipudase alfa efficacy with significant and comprehensive improvements in disease pathology and in clinically relevant endpoints. [7]

Experimental studies also demonstrated a good tolerability of olipudase alfa in pediatric patients [7–10]. The most reported treatment-related adverse reactions (ARs) are mild to moderate, being pyrexia, headache, urticaria, and vomiting the most common. These ARs have already been described during the infusion of other ERTs. [11] A recent systematic review describes the ERTs related hypersensitivity reactions (HR) in LSDs and the desensitization strategies applied. [11] Out of 52 patients with HR, 32 (61%) experienced anaphylaxis (3–5 HR grade according to the World Allergy Organization Anaphylaxis Guidance 2020). [12]

2. Case report

A 15-month-old child came to our Emergency Department for acute febrile pneumonia associated with hepatosplenomegaly. The child did not present any neurological sign. Infectious and lymphoproliferative diseases were excluded. In the suspect of a LSD, specific investigations were carried out: Chitotriosidase was 10× normal value (nv), plasma Lysosphingomyelin-509 was 4.3 ng/mL (nv < 0.9) and Sphingomyelinase enzyme activity, assessed by spectrophotometry with a wavelength of 410 nm, was 0.10 nmol/h/mg (nv 0.50–3.50). Genetic analysis revealed a homozygous c.1177 T > G mutation in exon 3 of the SMPD1 gene, also known as W391G, confirming the diagnosis of chronic neurovisceral ASMD (Fig. 1). Therefore, after obtaining informed parental consent, ERT for compassionate use was introduced at the age of 22 months.

The first infusion at a dose of 0.03 mg/kg was administered by increasing doses infusions every two weeks with clinical, biochemical and instrumental follow-up [13].

Transaminases, evaluated 24 h before and 48 h after each infusion,

were always normal.

Infusions were well tolerated until the 7th one, at a dose of 1 mg/kg. Before the end of the infusion the patient presented with erythematous neck skin rash, slight tremors at lower limbs, vomiting and hyperpyrexia with normal vital parameters (VPs). ERT was interrupted, and intravenous (IV) hydrocortisone and oral paracetamol were administered with the resolution of symptoms. Anti-olipudase alfa antibodies resulted in the absence of specific IgE (sIgE), but high IgG titre (1:12800).

During the 11th and 12th administrations, at the same dose, the patient presented respectively with a slight eyelid edema and fine tremors at lower limbs and a mild temperature rise (38.5°) with vomiting 30 min after the end of the infusion. VPs were normal and the episodes resolved spontaneously within a few minutes. The patient suffered from vomiting and diarrhea during the following days: similar symptoms were reported in his parents, suggesting an infectious cause.

During the 12th administration, at 1 mg/kg, pre-post infusion plasma complement proteins showed a decrease in C3 from 1.06 to 0.84 g/L (nv 0.9–1.8) and C4 from 0.42 to 0.13 g/L (nv 0.1–0.4).

An allergy counselling concluded for a class III allergic reaction according to Gell and Coombs classification, recommending premedication with betamethasone 0.1 mg/kg before the subsequent infusions.

At the 13th administration, still at the dose of 1 mg/kg, with premedication, no ARs occurred. Pre- and post-infusion exams were performed, confirming the increase in circulating immune complexes (Ic) from 12 to 95 RU/mL (nv < 20) and the reduction of C3 (from 1.08 to 0.98 g/L); and C4 (from 0.44 to 0.18 g/L).

Fourteenth to 19th infusions, with premedication and increasing olipudase dose from 1.5 to 3 mg/kg, were well tolerated, successfully reaching the target dose of 3 mg/kg at 31 months of age.

During the 10 months of ERT, dried blood spot specific biomarkers showed a dramatic decrease: Chitotriosidase from 62 to 20 µmol/h/L (nv 8–121 µmol/h/L); lyso-sphingomyelin (Lyso-SPM) from 175.3 to 77.8 ng/mL (nv 0–70 ng/mL) (Fig. 2).

Both liver and spleen volumes, estimated by magnetic resonance (MR) every 3 months during ERT, decreased: liver from 887 to 811 cm³ and spleen from 380 to 304 cm³ after 7 months (Fig. 3). Echocardiographic evaluations were consistently normal. No respiratory complications or pulmonary infections occurred. TO chest computer tomography (CT) showed initial thickening of interlobular septa with possible interstitial disease and follow-up thoracic ultrasounds described B lines. Normal growth and psychomotor development (evaluated with CFCS-GMFCs-GMFM-Mini MACS scales) were recorded.

At the 20th administration (second infusion at the dose of 3 mg/kg), with oral premedication (betamethasone 0.2 mg/kg and paracetamol), one hour after the start of the infusion, the patient presented with face, limbs, and trunk pruritic urticarial eruption. The infusion was discontinued, betamethasone 0.2/mg/kg and cetirizine were administered orally. After 30 min, an episode of vomiting associated with hypotension (blood pressure 86/44 mmHg) and bradycardia (heart rate 60 bpm)

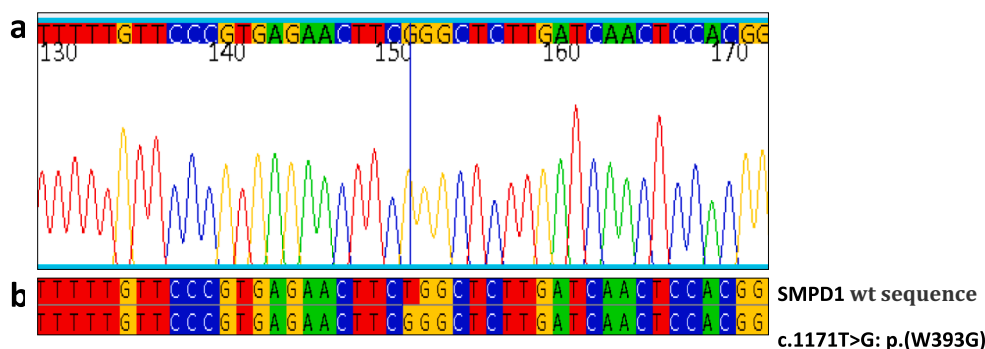
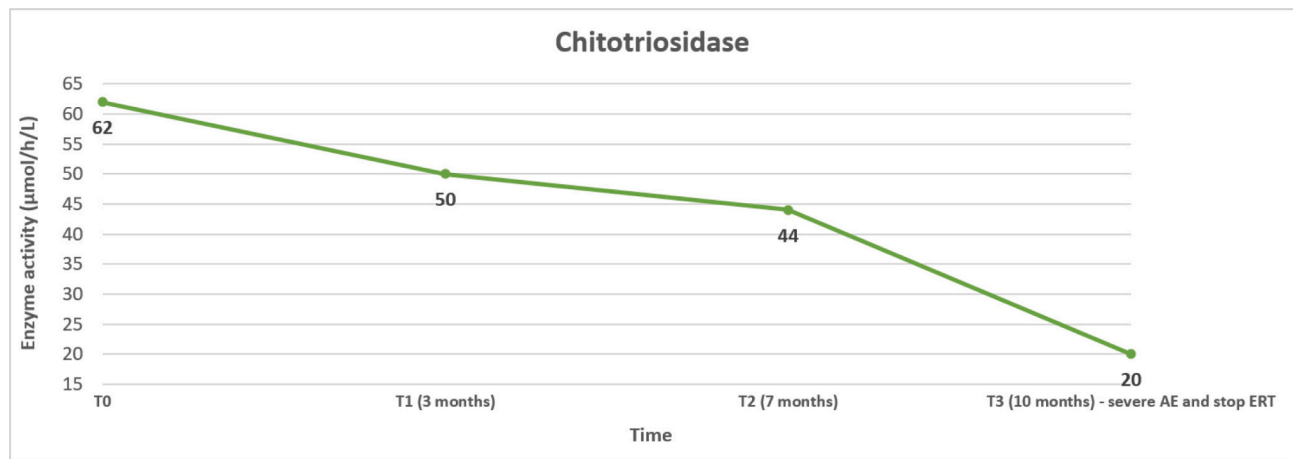


Fig. 1. Index case mutation c.1171 T > G. (a) Portion of the electropherogram of the SMPD1 exon 3 in index case, homozygous c.1171 T > G is indicated by the blue line. (b) Portion of sequence of SMPD1 exon 3 in patient aligned with the corresponding sequence of a healthy control (wt).

A



B

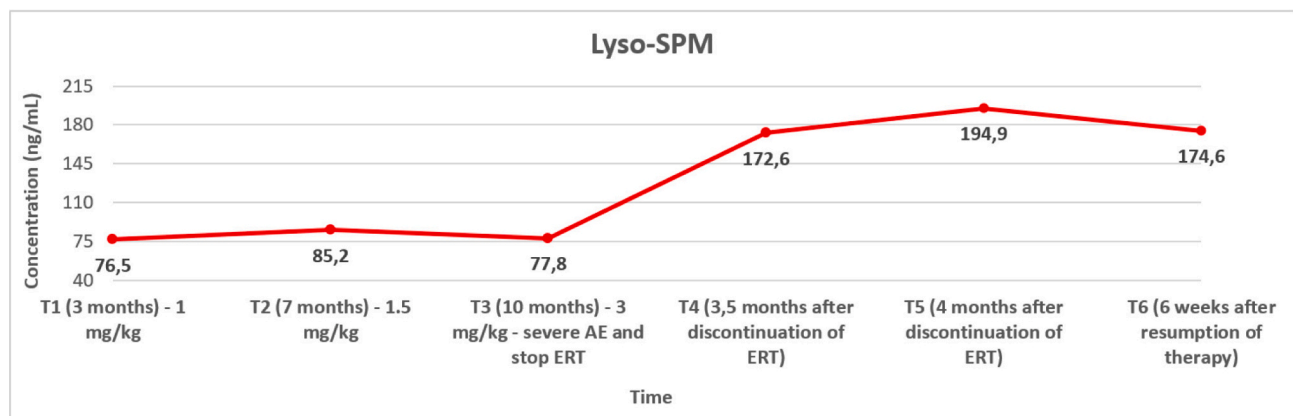


Fig. 2. Chitotriosidase (A) and Lyso-SPM (B) trend during ERT (Chitotriosidase: normal values 8–121 $\mu\text{mol/h/L}$; Lyso-SPM: normal values 0–70 ng/mL).

occurred. Intramuscular adrenaline 0.01 mg/kg was administered with the resolution of symptoms. The patient experienced a grade 5 HR. [12] Post-therapy blood exams showed normal serum tryptase (obtained 3 h after the event), normal circulating IgC but positive anti-olipudase IgE (8.34 kUA/L) with positive IgG (titre >1:3200).

ERT infusion was therefore interrupted, pending the development of a specific desensitization protocol.

After discontinuation of therapy, Lyso-SPM values increased to 172.6 and 194.9 ng/mL , respectively, 3.5 and 4 months after drug discontinuation (Fig. 1B). Furthermore, liver and spleen volume were increased (Fig. 2).

A Sanofi desensitization guideline (available upon request to Sanofi) which was not otherwise utilized or tested in clinical practice, was made available to our team. This guideline represents suggestions only and describes a desensitization procedure, to be tailored to the specific patient, that can be considered to rechallenge patients who have experienced a severe allergic reaction during treatment with olipudase alfa and/or were found to be positive for specific anti-olipudase IgE.

The desensitization procedure was performed using a serial dilution scheme to a final drug dilution of 1:10,000.

Premedication with IV methylprednisolone (2 mg/kg/day) and oral cetirizine (0.25 mg/kg/day) was started 18 h before the infusion.

The drug was administered using a syringe pump and IV infusion line equipped with a polyethersulfone 0,2 μm filter, after priming the line at

1 ml/min for 30 min to saturate it.

The dose escalation was restarted from the lowest dose, as recommended in the Sanofi Guideline referenced above.

A 7-step desensitization was performed using the 4 different olipudase alfa concentrations obtained, with a progressive increase in the infusion rate (Table 1).

A total amount of 0.4 mg (0.03 mg/kg) of olipudase alfa was administered in approximately 3 h and 26 min in Pediatric Intensive Care Unit. No ARs were observed during and after the infusion.

After desensitization, the patient has continued bi-weekly ERT infusion, always preceded by premedication. Methylprednisolone was substituted by oral prednisone at the third infusion. The dose escalation was resumed from dose of 0.1 mg/kg, according to the Sanofi guideline referenced above. The infusion time was doubled at each first administration of a higher dose to further reduce the risk of HR, as suggested by the protocol.

All the infusions were well tolerated up to the first dose of 0.6 mg/kg administered at half the infusion speed despite a positive molecular COVID test in the child, who presented asymptomatic. Stature growth had improved from a 10°-25° to 25°-50° percentile since the resumption of treatment, weight growth was stable within the 3°-15° percentile. Lyso-SPM tested on dry blood spot decreased after 6 weeks of treatment resumption (Fig. 1B).

Two weeks later, after the end of the second infusion at the dose of

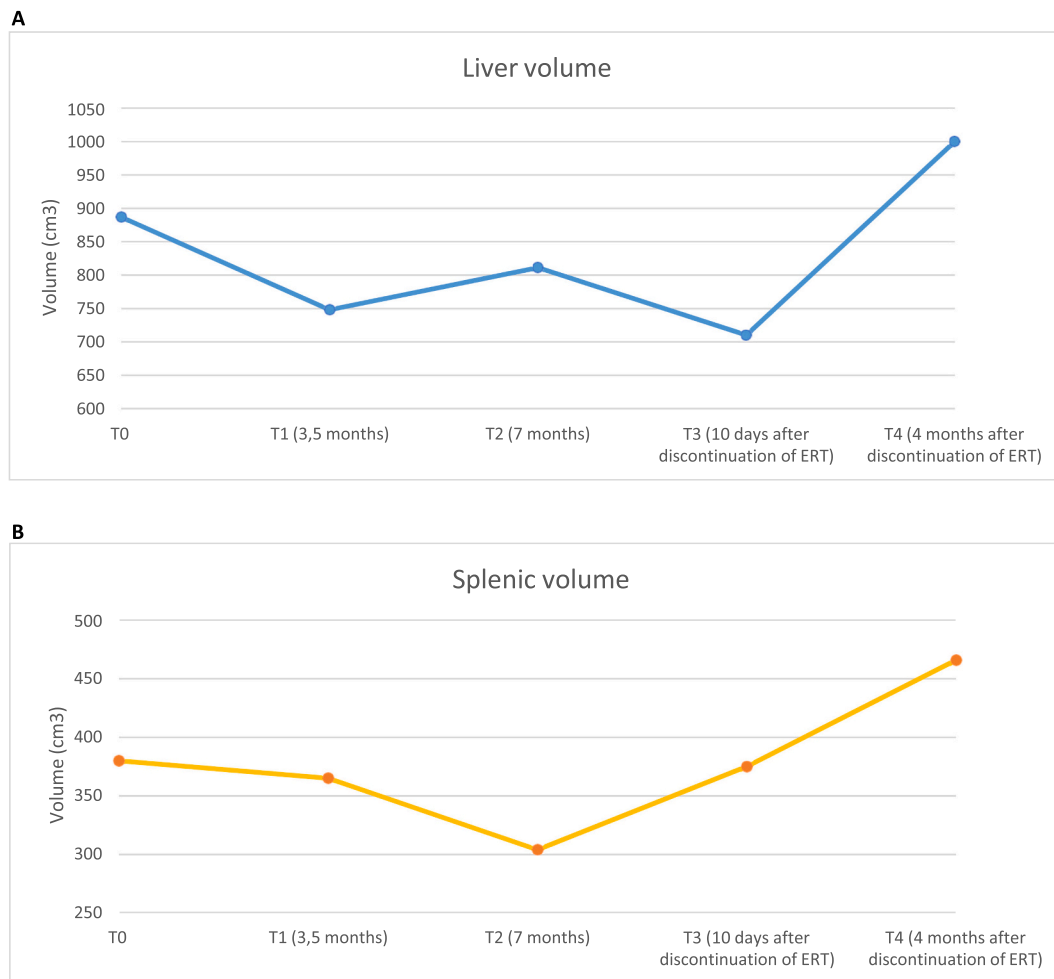


Fig. 3. Liver (A) and splenic (B) volume trend during and after discontinuation of ERT.

Table 1

Intravenous desensitization protocol of olipudase alfa according to Sanofi, adapted to our patient's weight (13 kg). [13].

Step	Bag	Concentration	Infusion rate	Duration	Infused dose
1	A	0.1 µg/ml	0.1 ml/min	30 min	0.3 µg
2	A	0.1 µg/ml	0.3 ml/min	30 min	0.9 µg
3	B	1 µg/ml	0.1 ml/min	30 min	3 µg
4	B	1 µg/ml	0.3 ml/min	30 min	9 µg
5	C	10 µg/ml	0.1 ml/min	30 min	30 µg
6	C	10 µg/ml	0.3 ml/min	30 min	90 µg
7	D	100 µg/ml	0.1 ml/min	26 min	260 µg

0.6 mg/kg, the child experienced facial urticarial rash, cough and respiratory distress with diffuse inspiratory wheezing. Oxygen saturation was 94%, heart rate 150 bpm. Blood pressure was normal. The patient experienced a grade 3 HR. [12] Methylprednisolone and inhaled salbutamol were administered. After 15 min, due to the persistence of respiratory symptoms, intramuscular adrenaline 0.01 mg/kg was administered with a rapid improvement of symptoms.

Blood samples were collected within 1–3 h. Complement activation product C3a was positive, while mast cell activation tryptase was normal (2.7 µg/L, nv2.2–13.2). Olipudase alfa-specific IgG and IgE levels were evaluated 72 h later and both were high (sIgE 6.05 kUA/L; IgG antibody titre >3200).

After this second severe adverse reaction, ERT infusion was discontinued for two months. Subsequently, a new personalized desensitization protocol has been introduced and is currently ongoing.

3. Discussion

Although it is a rare complication, reports of HR to ERTs are increasing due to their always more frequent therapeutic use in LSDs. [11]

Homozygote patients with the same mutation of our child have a wide variety of residual enzymatic activity and of neurological presentations, ranging from subclinical retinal involvement to severe ataxia, cognitive deficits and psychiatric disorders. [14]

To the extent of our knowledge, this is the first case of anaphylaxis in a patient with this mutation.

Most ARs can be counteracted by reducing the rate of infusion and by premedication. [11,15–18] Desensitization protocols are usually reserved to patients in whom these measures fail or when the initial reaction is a life-threatening event. It has been suggested that patients with negative skin test are more likely to resolve their ARs just increasing the infusion time, unlike those with a positive skin test [16]; however, cases of scarce tolerance to prolonged infusion time have been reported even in patients with negative skin test. [19] Furthermore, skin tests for recombinant enzymes are neither standardized nor validated, therefore their sensitivity could be low. [11]

The rationale of a drug desensitization is to modify the patient's immune response to a vital irreplaceable drug inducing at least a temporary tolerance to it. Desensitization protocols should be personalized to reach the best tolerance, although this is not always possible, even with premedication. [20] In some patients the addition of leukotriene receptor antagonists in premedication was useful in avoiding further HR after desensitization. [15]

Data on desensitization in the pediatric LSD population are sparse.

Desensitization to alglucosidase alfa in 7 children with Pompe disease has been described [21–25] showing that high sustained antibody titres have a negative impact on clinical outcomes [26] but that an immune tolerance induction concurrent with ERT improves clinical outcome. [27]

Graganiello et al. (2019) [23] adopted a premedication with tranexamic acid, cetirizine, ranitidine and deflazacort from 72 h before the infusion to improve tolerance in the desensitization of two young patients with infantile-onset Pompe disease treated with alglucosidase alfa. Tranexamic acid was added to the premedication because it might reduce complement activation and the risk of developing angioedema.

Anaphylaxis and other immediate HR to laronidase used in non-neurological manifestations [28] of Mucopolysaccharidosis I patients are rare. [29] In these patients, desensitization protocols have been proved safe and efficient to avoid treatment discontinuation [30,31], however not always long-term tolerance is maintained. [32] Therefore, subcutaneous allergen immunotherapy-like desensitization has been suggested in addition to rapid desensitization to obtain sustained tolerance. [33] Moreover, the application of the desensitization protocol proposed by Castells et al. for chemotherapy drugs (2008) [34], including the administration of diphenhydramine, ranitidine, montelukast, acetaminophen and methylprednisolone during the infusion to block different allergy pathways, adapted for laronidase has been demonstrated to be safe and effective. [35]

In Gaucher disease treatment, ARs to imiglucerase are mild and infrequent and regressed by reducing the infusion rate. [36] Sanofi desensitization protocols are available also for patients affected by Gaucher disease who experience a severe HR to ERT. [37] In this protocol, pre-medication is not recommended since corticosteroids are not effective in mitigating IgE mediated anaphylactic reactions, and antihistamines may mask the early signs or ARs symptoms. [38] Few cases of successful desensitization to imiglucerase in Gaucher disease have been reported in literature. [36,38–41]

Anaphylaxis is a rare AR in treated ASMD patients. One case of anaphylaxis in a 16-month-old patient during infusion at the dose of 0.6 mg/kg has been described in literature. [8] Olipudase alfa was restarted after 14 weeks of suspension at a dose of 0.3 mg/kg at a 1:100,000 dilution. Afterwards, a gradual dose escalation was resumed, although the patient continued to experience mild ARs at higher drug doses which required discontinuation of the drug administration. [8]

We report the first application of a desensitization protocol according to Sanofi guidelines referenced above in a patient affected by chronic neurovisceral ASMD. The desensitization procedure was not successful in obtaining a long-term tolerance.

In our patient the high specific IgE level poses for a type I hypersensitivity reaction. However, recent studies have demonstrated that ARs to olipudase alpha are more likely due to a cytokine production and inflammatory response to the release of ceramide than to a proper allergic reaction to the drug. [42] In our patient both mechanisms, together with complement system activation with consequent immune-complex mediated reactions, may have contributed to the non-satisfactory response to this desensitization protocol. A further reduction of infusion rate with higher dilution might be helpful.

Considering the good clinical response in the first 6 months of treatment (dose escalation up to 1 mg/kg) with the reduction of disease biomarkers and splenic and liver volume, together with the improvement of height, we conclude that in our patient a lower ERT dose than the target one can be effective, as describe in literature. [8] This evidence may support the need for both a personalized dose escalation and a target dose, especially in patients who experience a severe AR.

Among patients on compassionate use, until now ARs described are more frequent and more severe in the children than in adult. [8] Mechanisms underlying ARs in ASMD patients on ERT seem to be multiple, depending both on the immune-allergic response of the patient and on the ceramide release.

Considering our patient immune-allergic pattern and his excellent clinical and biochemical response to the treatment but with HR, a new desensitization protocol must be defined.

Author contributions

LF, CM, MG and VC were involved in the clinical care of the patient. LF, VMT, DD, EV, ED, CZ and GZ drafted and reviewed the manuscript, MG, VMT and CZ drafted all figures and tables. All authors critically revised and approved the final version of the manuscript.

Informed consent

All procedures followed were in accordance with the ethical standards of the responsible committee on human experimentation and with the Helsinki Declaration of 1975, as revised in 2000. The patients' parents gave their informed consent for the publication of this case report.

Animal rights

This article does not contain any studies with animal subjects performed by any of the authors.

CRediT authorship contribution statement

Laura Fiori: Conceptualization, Supervision, Writing – original draft, Writing – review & editing. **Veronica Maria Tagi:** Conceptualization, Supervision, Writing – original draft, Writing – review & editing. **Chiara Montanari:** Supervision, Writing – original draft. **Mirko Gambino:** Conceptualization, Writing – original draft. **Veronica Carlevatti:** Supervision, Writing – original draft. **Carmela Zizzo:** Supervision, Writing – review & editing. **Enza D'Auria:** Supervision, Writing – original draft. **Dario Dilillo:** Conceptualization, Supervision. **Elvira Verduci:** Conceptualization, Supervision. **Gianvincenzo Zuccotti:** Conceptualization, Supervision.

Declaration of competing interest

The authors declare no conflict of interest.

Data availability

The datasets generated during the current study are available from the corresponding author on reasonable request.

Acknowledgments

We are grateful to Sanofi for supplying the Olipudase Alfa sensitization guideline and to Sanofi employees for their constant availability and valuable support to our clinical practice.

We thank Fondazione Romeo and Enrica Invernizzi for extraordinary support.

Our deepest gratitude goes to the patient's family for their support of this publication.

References

- [1] Y.W. Pan, M.C. Tsai, C.Y. Yang, W.H. Yu, B. Wang, Y.J. Yang, Y.Y. Chou, Enzyme replacement therapy for children with acid sphingomyelinase deficiency in the real world: a single center experience in Taiwan, *Mol. Genet. Metab. Rep.* 34 (2023) 100957, <https://doi.org/10.1016/j.ygm.2023.100957>.
- [2] T. Geberhiwot, M. Wasserstein, S. Wanninayake, S.C. Bolton, A. Dardis, A. Lehman, et al., Consensus clinical management guidelines for acid sphingomyelinase deficiency (Niemann-pick disease types A, B and A/B), *Orphanet J. Rare Dis.* 18 (1) (2023) 85, <https://doi.org/10.1186/s13023-023-02686-6>.
- [3] D. Cassiman, S. Packman, B. Bembi, H.B. Turkia, M. Al-Sayed, M. Schiff, J. Imrie, P. Mabe, T. Takahashi, K.E. Mengel, R. Giugliani, G.F. Cox, Cause of death in patients with chronic visceral and chronic neurovisceral acid sphingomyelinase

- deficiency (Niemann-Pick disease type B and B variant): literature review and report of new cases, *Mol. Genet. Metab.* 118 (3) (2016 Jul) 206–213, <https://doi.org/10.1016/j.ymgme.2016.05.001>. Epub 2016 May 11. Erratum in: *Mol Genet Metab.* 2018 Dec;125(4):360.
- [4] E.H. Schuchman, M.P. Wasserstein, Types a and B Niemann-pick disease, *Best Pract. Res. Clin. Endocrinol. Metab.* 29 (2) (2015) 237–247, <https://doi.org/10.1016/j.beem.2014.10.002>.
- [5] M.P. Wasserstein, R.J. Desnick, E.H. Schuchman, S. Hossain, S. Wallenstein, C. Lamm, M.M. McGovern, The natural history of type B Niemann-pick disease: results from a 10-year longitudinal study, *Pediatrics* 114 (6) (2004) e672–e677, <https://doi.org/10.1542/peds.2004-0887>.
- [6] M.M. McGovern, N. Lipka, E. Bagiella, E.H. Schuchman, R.J. Desnick, M. P. Wasserstein, Morbidity and mortality in type B Niemann-pick disease, *Genet. Med.* 15 (8) (2013) 618–623, <https://doi.org/10.1038/gim.2013.4>.
- [7] M. Wasserstein, R. Lachmann, C. Hollak, L. Arash-Kaps, A. Barbato, R.C. Gallagher, et al., A randomized, placebo-controlled clinical trial evaluating olipudase alfa enzyme replacement therapy for chronic acid sphingomyelinase deficiency (ASMD) in adults: one-year results, *Genet. Med.* 24 (7) (2022) 1425–1436, <https://doi.org/10.1016/j.gim.2022.03.021>.
- [8] G.A. Diaz, S.A. Jones, M. Scarpa, K.E. Mengel, R. Giugliani, N. Guffon, et al., One-year results of a clinical trial of olipudase alfa enzyme replacement therapy in pediatric patients with acid sphingomyelinase deficiency, *Genet. Med.* 24 (10) (2022) 2209.
- [9] M.P. Wasserstein, G.A. Diaz, R.H. Lachmann, M.H. Jouvin, I. Nandy, A.J. Ji, A. C. Puga, Olipudase alfa for treatment of acid sphingomyelinase deficiency (ASMD): safety and efficacy in adults treated for 30 months, *J. Inher. Metab. Dis.* 41 (5) (2018) 829–838, <https://doi.org/10.1007/s10545-017-0123-6>.
- [10] G.A. Diaz, R. Giugliani, N. Guffon, S.A. Jones, E. Mengel, M. Scarpa, et al., Long-term safety and clinical outcomes of olipudase alfa enzyme replacement therapy in pediatric patients with acid sphingomyelinase deficiency: two-year results, *Orphanet J. Rare Dis.* 17 (1) (2022) 437, <https://doi.org/10.1186/s13023-022-02587-0>. Erratum in: *Orphanet J Rare Dis.* 2023;18(1):55.
- [11] F. Spataro, P. Carlucci, T. Loverre, L. Macchia, D. Di Bona, Hypersensitivity reaction during enzyme replacement therapy in lysosomal storage disorders. A systematic review of desensitization strategies, *Pediatr. Allergy Immunol.* 34 (6) (2023) e13981, <https://doi.org/10.1111/pai.13981>.
- [12] V. Cardona, L.J. Ansotegui, M. Ebisawa, Y. El-Gamal, M. Fernandez Rivas, S. Fineman, M. Geller, A. Gonzalez-Estrada, P.A. Greenberger, M. Sanchez Borges, G. Senna, A. Sheikh, L.K. Tanno, B.Y. Thong, P.J. Turner, M. Worm, World allergy organization anaphylaxis guidance 2020, *World Allergy Organ J.* 13 (10) (2020) 100472, <https://doi.org/10.1016/j.waojou.2020.100472>.
- [13] Sanofi., *Practical Guide to Administration and Monitoring of Olipudase Alfa MAT-GLB-2004278 v1.0*, Feb 2021.
- [14] V. Mihaylova, J. Hantke, I. Sinigerska, S. Cherninkova, M. Raicheva, S. Bouwer, et al., Highly variable neural involvement in sphingomyelinase-deficient Niemann-pick disease caused by an ancestral gypsy mutation, *Brain* 130 (Pt 4) (2007) 1050–1061, <https://doi.org/10.1093/brain/awm026>.
- [15] I. Turgay Yagmur, O. Unal Uzun, A. KucukcongarYavas, I. Kulhas Celik, M. Toyran, M. Gunduz, et al., Management of hypersensitivity reactions to enzyme replacement therapy in children with lysosomal storage diseases, *Ann. Allergy Asthma Immunol.* 125 (4) (2020) 460–467.
- [16] C.S. Aranda, L.F. Ensina, I.C. Nunes, M.C. Mallozi, C. Mendes, A.M. Martins, D. Solé, Diagnosis and management of infusion-related hypersensitivity reactions to enzyme replacement therapy for lysosomal diseases: the role of desensitization, *J Allergy Clin Immunol Pract* 4 (2) (2016) 354–356, <https://doi.org/10.1016/j.jaip.2015.11.012>.
- [17] K.H. Kim, C. Decker, B.K. Burton, Successful management of difficult infusion-associated reactions in a young patient with mucopolysaccharidosis type VI receiving recombinant human arylsulfatase B (galsulfase [Naglazyme]), *Pediatrics* 121 (3) (2008) e714ee717.
- [18] B.K. Burton, D.A. Whiteman, H.O.S. Investigators, Incidence and timing of infusion-related reactions in patients with mucopolysaccharidosis type II (hunter syndrome) on idursulfase therapy in the real-world setting: a perspective from the hunter outcome survey (HOS), *Mol. Genet. Metab.* 103 (2) (2011), 113e120.
- [19] M.F. Huffaker, A.Y. Liu, G.M. Enns, S. Vijay, A.J. Amor, N.F. Adkinson Jr., Case series of sebelipase alfa hypersensitivity reactions and successful sebelipase alfa rapid desensitization, *JIMD Rep.* 49 (1) (2019) 30e36.
- [20] R.G. Breslow, J. Caiado, M.C. Castells, Acetylsalicylic acid and montelukast block mast cell mediator-related symptoms during rapid desensitization, *Ann. Allergy Asthma Immunol.* 102 (2) (2009), 155e160.
- [21] M. Capanoglu, E. Dibek Misirlioglu, D. Azkur, E. Vezir, H. Guvenir, M. Gunduz, et al., IgE-mediated hypersensitivity and desensitisation with recombinant enzymes in Pompe disease and type I and type VI Mucopolysaccharidosis, *Int. Arch. Allergy Immunol.* 169 (3) (2016) 198–202, <https://doi.org/10.1159/000446154>.
- [22] A.H. El-Gharbawy, J. Mackey, S. DeArmedy, G. Westby, S.G. Grinnell, P. Malovrh, et al., An individually, modified approach to desensitize infants and young children with Pompe disease, and significant reactions to alglucosidase alfa infusions, *Mol. Genet. Metab.* 104 (1–2) (2011) 118–122, <https://doi.org/10.1016/j.ymgme.2011.07.004>.
- [23] V. Graganiello, S. Fecarotta, A. Pecoraro, A. Tarallo, A. Catzola, G. Spadaro, et al., Desensitization of two young patients with infantile-onset Pompe disease and severe reactions to alglucosidase alfa, *Neurol. Sci.* 40 (7) (2019) 1453–1455, <https://doi.org/10.1007/s10072-019-03744-3>.
- [24] I.H. Karagol, A. Bakirtas, O. Yilmaz, E. Topal, A. Kucukcongar, F.S. Ezgu, et al., Desensitisation of the youngest patient with Pompe disease in response to alglucosidase alfa, *Allergol Immunopathol (Madr)* 42 (4) (2014) 372–375, <https://doi.org/10.1016/j.aller.2013.02.012>.
- [25] J. Baruteau, A. Broomfield, V. Crook, N. Finnegan, K. Harvey, D. Burke, et al., Successful desensitisation in a patient with CRIM-positive infantile-onset Pompe disease, *JIMD Rep.* 12 (2014) 99–102, https://doi.org/10.1007/8904_2013_250.
- [26] S.G. Banugaria, S.N. Prater, Y.K. Ng, J.A. Kobori, R.S. Finkel, R.L. Ladda, et al., The impact of antibodies on clinical outcomes in diseases treated with therapeutic protein: lessons learned from infantile Pompe disease, *Genet. Med.* 13 (8) (2011) 729–736, <https://doi.org/10.1097/GIM.0b013e3182174703>.
- [27] P.S. Kishnani, P.I. Dickson, L. Muldowney, J.J. Lee, A. Rosenberg, R. Abichandani, et al., Immune response to enzyme replacement therapies in lysosomal storage diseases and the role of immune tolerance induction, *Mol. Genet. Metab.* 117 (2) (2016) 66–83, <https://doi.org/10.1016/j.ymgme.2015.11.001>.
- [28] Genzyme Canada, *Aldurazyme® (Laronidase) Product Monograph*, 2014.
- [29] I. Yilmaz, A.S. Caglar, F. Kardas, Z. Karaca, S. Yenigun, N. Tutar, Successful desensitization in a patient with hypersensitivity reaction to laronidase. Late breaking poster session LB TPS, *Allergy* 72 (2017) 758–823.
- [30] S. Bilgiceltan, Ö. Keskin, M. Keskin, B. Öztürkhisim, E. Küçükosmanolu, M. Karaolan, M.Y. Ozkars, Well tolerated enzyme replacement therapy after successful desensitization in a pediatric patient with mucopolysaccharidosis type 1 and history of anaphylaxis, *Allergy Europ. J. Allergy Clin. Immunol.* 70 (344–345) (2015). SUPPL. 101.
- [31] C. Aranda, L.F. Ensina, D. Sole, A.M. Martins, Hypersensitivity reactions to enzyme replacement therapy for lysosomal diseases in Brazil: outcomes and safety of 1,140 rapid desensitizations, *Mol. Genet. Metab.* 120 (1–2) (2017) S22–S23.
- [32] J.R. Cernadas, K. Brockow, A. Romano, W. Aberer, M.J. Torres, A. Bircher, et al., European network of drug allergy and the EAACI interest group on drug hypersensitivity. General considerations on rapid desensitization for drug hypersensitivity - a consensus statement, *Allergy* 65 (2010) 1357–1366.
- [33] F. Spataro, F. Viggiani, D.G. Macchia, V. Rollo, A. Tummolo, P. Suppressa, et al., Novel approach to idursulfase and laronidase desensitization in type 2 and type 1 S mucopolysaccharidosis (MPS), *Orphanet J. Rare Dis.* 17 (1) (2022) 402.
- [34] M.C. Castells, N.M. Tennant, D.E. Sloane, F.I. Hsu, N.A. Barrett, D.I. Hong, et al., Hypersensitivity reactions to chemotherapy: outcomes and safety of rapid desensitization in 413 cases, *J. Allergy Clin. Immunol.* 122 (3) (2008) 574–580.
- [35] L.F. Ensina, C.S. Aranda, A.E. de Lacerda, I. Camelo-Nunes, D. Sole, A.M. Martins, M. Castells, Laronidase hypersensitivity and desensitization in type I mucopolysaccharidosis: a case report, *Pediatr. Allergy Immunol.* 25 (5) (2014) 498–499, <https://doi.org/10.1111/pai.12209>.
- [36] K. Foster, S. Kim, A. Peters, Successful imiglucerase desensitization in a patient with severe arthralgia and myalgia, *Ann. Allergy Asthma Immunol.* 129 (5) (2022) S93, <https://doi.org/10.1016/j.ana.2022.08.763>.
- [37] Sanofi, *Guideline to Re-Challenge Administration of Cerezyme (Imiglucerase for Injection)*, November 2022.
- [38] O. Tsilochristou, N.A. Gkavogiannakis, E.N. Ioannidou, M. Makris, Successful rapid desensitization to imiglucerase in an adult patient with Gaucher disease and documented IgE-mediated hypersensitivity, *J Allergy Clin Immunol Pract* 3 (4) (2015) 624–626.
- [39] D. Erdogdu, A. Gelincik, B. Canbaz, B. Colakoglu, S. Büyükoztürk, R. Tanakol, Successful desensitization to imiglucerase of an adult patient diagnosed with type I Gaucher disease, *Int. Arch. Allergy Immunol.* 160 (2) (2013) 215–217.
- [40] D.G. Peroni, L. Pescollenderg, G.L. Piacentini, W. Cassar, A.L. Boner, Effective desensitization to imiglucerase in a patient with type I Gaucher disease, *J. Pediatr.* 155 (6) (2009) 940–941.
- [41] A.A. Roppelt, D.V. Yukhacheva, P.E. Dyakonov, I.G. Hamin, I.S. Movsisyn, I. S. Goar, et al., Rapid desensitization therapy with imiglucerase in a patient with an anaphylactic reaction to it against the background of Gaucher disease, *Pediatrics* 101 (2) (2022) 121–127, <https://doi.org/10.24110/0031-403X-2022-101-2-121-127>.
- [42] W. Mauhin, R. Borie, F. Dalbics, C. Douillard, N. Guffon, C. Lavigne, et al., Acid sphingomyelinase deficiency: sharing experience of disease monitoring and severity in France, *J. Clin. Med.* 11 (4) (2022) 920.