

# Procto-Glyvenol<sup>®</sup> accelerates the natural healing process of wounds: a pre-clinical study

M. MALINVERNO<sup>1</sup>, E. CALLEGARI<sup>1</sup>, L. PIRONA<sup>1</sup>, I. PELLERANI<sup>1</sup>, B. BELMONTE<sup>2</sup>, C. TRIPODO<sup>2</sup>, P. ANGELICO<sup>1</sup>, S. BIONDI<sup>1</sup>

<sup>1</sup>Preclinical Group, R&D and Medical Affairs, Recordati S.p.A., Milan, Italy

<sup>2</sup>Department of Health Sciences, Tumor Immunology Unit, University of Palermo School of Medicine, Palermo, Italy

**Abstract. – OBJECTIVE:** Hemorrhoids are a common anorectal disease that causes pain, itching, and burning. The prevalence of hemorrhoids is estimated to be as high as 36% in the general population, with approximately 50% of individuals experiencing symptomatic hemorrhoids at least once in their life. Middle age, obesity, and pregnancy are risk factors. The combination of tribenoside and lidocaine (Procto-Glyvenol<sup>®</sup>, Recordati) has been used for decades to treat low-grade hemorrhoids, and its efficacy and safety are well supported by clinical experience. Tribenoside has been shown to have an anti-inflammatory effect, ameliorate the local microcirculation and vascular tone, and promote the healing of basement membrane. However, the molecular mechanism behind its wound-healing properties is still unclear.

**MATERIALS AND METHODS:** Human dermal fibroblasts were used to test the effect of tribenoside on cell proliferation, cell migration, and production of reactive oxygen species *in vitro*. Full-thickness excisional wound model in rats was used to test the wound-healing properties of Procto-Glyvenol<sup>®</sup> *in vivo*.

**RESULTS:** Tribenoside has been found to increase the migration rate of fibroblasts *in vitro* and to improve the wound healing process by promoting re-epithelialization in rats. Furthermore, novel antioxidant activity of tribenoside has been reported, which may represent a further mechanism of action in wound healing.

**CONCLUSIONS:** Procto-Glyvenol<sup>®</sup> improves the natural healing process of wounds by stimulating cell migration and protecting against the toxic effects of reactive oxygen species. Therefore, it may represent a first-line treatment for hemorrhoids, which are a significant medical and socioeconomic problem that can deteriorate the quality of life.

*Key Words:*

Hemorrhoids, Tribenoside, Wound healing, Procto-Glyvenol<sup>®</sup>, Animal model.

## Introduction

Hemorrhoids are one of the most common anorectal diseases, characterized by symptomatic enlargement and abnormal downward displacement of the anal cushions causing venous dilatation<sup>1,2</sup>. They can occur either inside the rectum (known as internal hemorrhoids) or outside the anus (known as external hemorrhoids). External hemorrhoids usually cause subjective symptoms which include pain, itching and burning, while internal hemorrhoids are associated to more objective symptoms, such as prolapse or rectal bleeding. The exact etiology of hemorrhoids is unknown; however, it is now widely accepted<sup>1,3</sup> that hemorrhoids develop when the supporting tissues of the anal cushions disintegrate or deteriorate. The prevalence of hemorrhoids is estimated to be as high as 36% in the general population, with approximately 50% of individuals who will experience symptomatic hemorrhoids at least once in their life<sup>4,5</sup>. Middle age (45-65 years), obesity, and pregnancy are considered risk factors. Up to 85% of women experience hemorrhoids during the third trimester of pregnancy, and in 25-35% of cases, the condition persists<sup>6,7</sup>. Due to their high prevalence and the severe discomfort that they cause, hemorrhoids represent a significant medical and socioeconomic problem.

The severity of hemorrhoids is classified into four clinical grades according to the Goligher classification. Low-grade disease, which represents the wide majority (>90%) of cases, is usually managed with the local application of topical preparations containing anti-inflammatory drugs, including steroids<sup>8,9</sup>. However, due to the risk of systemic adsorption, steroids are associated with the potential onset of adverse events. This limits their application over the middle-term period or in particularly sensitive patients such as

the elderly, pregnant or breastfeeding women and athletes<sup>10,11</sup>. Alternatively, the combination of tribenoside and lidocaine (Procto-Glyvenol<sup>®</sup>, Recordati, Italy) has been used for decades to treat hemorrhoids, with broad clinical experience supporting its efficacy and safety, even in pregnant and breastfeeding women<sup>12,13</sup>. Lidocaine is a widely used local anesthetic that provides rapid relief of subjective symptoms, such as pain and itching, perceived as the worst discomfort by patients. Tribenoside has been shown<sup>14</sup> to have an anti-inflammatory effect, ameliorate the local microcirculation and vascular tone and promote the healing of the basement membrane, thereby improving the objective symptoms of hemorrhoids such as prolapse or rectal bleeding. Moreover, unlike steroids or nonsteroidal anti-inflammatory drugs (NSAIDs), the anti-inflammatory activity of tribenoside is not associated with adverse effects on the gastrointestinal or immune system<sup>15</sup>. In controlled clinical studies in literature, the combination of tribenoside and lidocaine has been shown to be superior to the single components in the treatment of hemorrhoids, as it can improve both subjective and objective symptoms at the same time. Additionally, Procto-Glyvenol<sup>®</sup> has been demonstrated<sup>13</sup> to be at least equally effective and sometimes even superior to standard care based on steroids in providing fast relief of the subjective symptoms. Although the efficacy of tribenoside as a treatment for hemorrhoids has been widely described in clinical practice, there is still a lack of preclinical studies investigating the molecular mechanism behind its wound-healing properties. To address this gap, this study utilized *in vitro* settings and an animal model of wound healing to show that tribenoside improves wound healing by stimulating cell migration and protecting against the toxic effects of reactive oxygen species.

## Materials and Methods

### Materials

The following materials have been used: neutral buffered 10% formalin (cat. 9713) from Avantor (VWR International srl, Milan, Italy); Eukitt mounting medium (cat. 03989), eosin Y alcoholic solution (cat. HT110116), Mayer's hematoxylin solution (cat. MHS32), Masson's trichrome stain kit (cat. HT15) and transforming growth factor beta (TGF- $\beta$ ) (cat. H8541) were from Sigma-Aldrich (Merk Life Science srl, Milan, Italy). Histolemon (cat. 454911) was from Carlo Erba (Cornaredo,

Milan, Italy). The 10 mm diameter biopsy punch was purchased from Betued on Amazon (www.amazon.it). Procto-Glyvenol<sup>®</sup> was produced by Recordati Spa, Milan, Italy. Fibroblast Basal Medium (FBM) (cat. CC-3131) and Fibroblast Growth Medium (FGM-2) SingleQuots (cat. CC-4126) media were from Lonza Biosciences (Hayward, CA, USA). Dulbecco's Phosphate Buffered Saline (cat. ECB4004L) and trypsin-EDTA (cat. ECB3052D) were from Euroclone (Pero, Milan, Italy). CellTiter-Glo Luminescent Cell Viability Assay (cat. G7571) was from Promega (Milan, Italy). DCFDA/H2DCFDA-Cellular ROS Assay Kit (cat.113851) was from Abcam (Cambridge, UK).

### Cell Cultures

Human dermal fibroblasts (HDF, Lonza Bioscience) derived from normal adult foreskin were maintained in FBM Basal medium supplemented with FGM-2 SingleQuots (2% fetal bovine serum, insulin, hFGF- $\beta$  and gentamycin/amphotericin-B) in a 95% air, 5% CO<sub>2</sub> and humidified atmosphere at 37°C.

### Cell Viability Assay

Cell viability was assessed using the CellTiter-Glo Luminescent Viability Assay KIT (Promega, Madison, WI, USA). HDF cells, at 80% confluence, were washed with PBS, trypsinized and then seeded in 96-well plates at the density of 5,000 cells per well in complete medium. After 24 hours, the cells were treated with increasing concentrations of tribenoside or vehicle (0.1% DMSO) in basal medium. After 24 hours of incubation with tribenoside, an equal volume of CellTiter-Glo reagent to the volume of cell culture medium present in each well was added, and the plate was incubated for 10 minutes to stabilize the luminescent signal. The luminescence was then measured using the FlexStation<sup>®</sup> 3 Multi-Mode Microplate Reader (Molecular Devices, San Jose, CA, USA).

Relative cell viability was calculated as follows: cell viability at the given concentration/cell viability of control  $\times$  100. Each experiment was performed in triplicate.

### Measurement of ROS

Intracellular levels of reactive oxygen species (ROS) were measured using 2',7'-dichlorofluorescein diacetate (DCFDA) present in the DCFDA/H2DCFDA-Cellular ROS Assay Kit (Abcam). HDF cells were washed with PBS, trypsinized and seeded in 96-well plates at a density of 25,000 cells per well in a complete medium. After 24

hours at 37°C to allow attachment, the cells were washed with PBS, and 20 µM of DCFDA solution was added to each well. The plate was incubated with DCFDA solution for 45 minutes at 37°C in the dark, and then the fluorogenic dye was removed. The plate was treated with an increasing concentration of tribenoside for 4 hours, and then the intensity of the resulting fluorescence was measured using the FlexStation® 3 Multi-Mode Microplate Reader (Molecular Devices). Each experiment was performed in triplicate.

### ***In-Vitro Wound Healing Assay***

6.5 x 10<sup>4</sup> cells were seeded in 48-well plates. Once they reached full confluence, a circular wound was created using a vacuum tube. A p10 pipette tip was overlaid to a p200 pipette tip attached to the vacuum tube and perpendicularly positioned above each well's center. A circular layer of cells was aspirated with gentle and brief contact. After washing with PBS, a basal medium containing 1% FBS with or without treatment was added, and the cells were incubated for 48 hours. TGF-β at 5 ng/ml was used as a positive control. Each wound area was acquired at the beginning and at the indicated time points (24 hours and 48 hours) with a camera (Moticam Pro285B) connected to the microscope (Eurotek, 4× objective) and the wound area was quantified using ImageJ software. Wound closure was calculated as follows:  $\text{Wound Area Closure} = (\text{Area } t_0 - \text{Area } t_{24-48}) / \text{Area } t_0 \times 100$ .

### ***Animals***

All the procedures with animals were performed in agreement with the Institutional Animal Care and Use Committee (IACUC) of Istituto di Ricerche Farmacologiche Mario Negri IRC-CS (IRFMN), in compliance with the guidelines established in the Principles of Laboratory Animal Care (Directive 86/609/EEC) and as approved by the Italian Ministry of Health with the authorization number 315/2022-PR. The animals were housed at the IRFMN animal facility under standard conditions and fed with a regular chow diet and water ad libitum. Sixteen male CD rats (200-225 g) from Charles River (Calco, Italy) were used.

### ***In-Vivo Wound Healing Experiment***

The day before the experiment, the animals were shaved on the back, randomized, and assigned to either the Control or Procto-Glyvenol® group (n=8). After shaving, animals were housed in individual cages during the entire period of the exper-

iment to avoid skin lesions from fighting, which may interfere with wound repair. On the day of the experiment, the animals were deeply anesthetized with isoflurane (5% induction, 3% maintenance), weighted, and two full-thickness excision wounds were made on the dorsal skin of each rat with a 10 mm diameter biopsy punch. After surgery, the wounds were immediately photographed. Animals received the treatment twice daily, morning and afternoon, starting immediately after surgery and until day 13. The two wounds of each animal were treated with the same medication, which was applied with a small spatula to cover the wound completely. After the application of medication, the wounds were left open without dressing. Animals in the control group did not receive any treatment. On days 7 and 10, the animals were anesthetized, weighted, shaved, and photographed. At the end of the experiment, on day 14, the animals were sacrificed, weighed, shaved, and photographed. Skin biopsies were taken around the original wounds using the same punch and were processed for histological analysis.

### ***Sample Processing and Histological Analysis***

Skin biopsies collected after sacrifice were fixed in neutral-buffered 10% formalin overnight at 4°C, dehydrated in 70% ethanol and processed by a Diapath automatic processor as follows. Tissues were dehydrated through 70% (60 minutes), two changes of 95% (90 minutes each), and three changes of 99% (60 minutes each) ethanol, cleared through three changes of xylene (90 minutes each), and finally immersed in three changes of paraffin, 1 hour each. Samples were embedded in a paraffin block and stored at room temperature until ready for sectioning. 4 µm-thick sections were cut with a Histocore Multicut Microtome (Leica, Wetzlar, Germany) and colored with either Hematoxylin & Eosin or Masson's trichrome stain, following standard protocols.

All images were acquired using a Leica DM750 microscope featured with a Leica ICC 50 W camera and a 4× objective and then analyzed by a blinded operator with the Fiji ImageJ software<sup>16</sup>. A scoring system optimized and validated by van de Vyver et al<sup>17</sup> was used for histological analysis. The following parameters have been evaluated on H&E-stained images of the left wound of each animal. The percentage of re-epithelization was used as a measure of wound closure. It was determined as described in [Supplementary Figure 1a](#) and calculated as follows: re-epithelization % = [(distance of minor axis between origi-

nal wound edges – distance of axis in the open area) / distance of minor axis between original wound edges] x 100. Then, a numerical score was assigned to all pictures to define if the re-epithelization process was “complete” (score 2: re-epithelization %  $\geq 95$ ), “partial” (score 1:  $0 < \text{re-epithelization \%} < 95$ ), and “none” (score 0: re-epithelization % = 0). Only in samples with a complete re-epithelization (score 2) the epidermal thickness index (ETI) was evaluated as an indicator of epithelial maturation in the wounded area. Five measurements of the epidermal thickness in the uninjured skin and in the wounded area were made as shown in **Supplementary Figure 1b, c**, and the ETI was calculated as follows:  $\text{ETI} = (\text{average thickness of epidermis in wound area} / \text{average thickness of epidermis in uninjured skin}) \times 100$ . A numerical score has then been assigned to define if the tissue has returned to its uninjured state (score 2:  $95\% \leq \text{ETI} \leq 105\%$ ), if the tissue is hypertrophic (score 1:  $\text{ETI} > 105\%$ ), or if the skin is in hypoplasia (score 0:  $\text{ETI} < 95\%$ ).

For the histopathological analysis, slides were analyzed under Zeiss Axio Scope A1 optical microscope (Zeiss, Germany), and microphotographs were collected using an Axiocam 503 Color digital camera with the ZEN2 imaging software (Zeiss, Oberkochen, Germany). A semi-quantitative scoring system was applied, including the following variables: ulceration, epidermal inflammation, dermal inflammation, vascular proliferation and distortion, fibroblast proliferation, and fibrosis. All the variables were morphologically evaluated and scored according to the degree of severity: 0 absent, 1 mild, 2 moderate, 3 severe. For each sample, the seven scores were then summed up to the total score.

### **Quantitative Assessment of Wound Closure**

The size of each animal's two open wounds was determined on days 0, 7, 10, and 14.

For each wound, the open area was manually traced by a blind operator after image calibration using the FIJI ImageJ software (NIH, <https://imagej.net/software/fiji>). The relative wound area (A) was calculated as follows:  $A = \text{wound area at the time point analyzed (days 0, 7, 10, or 14)} / \text{wound area on day 0}$ .

### **Statistical Analysis**

Statistical analysis was performed using GraphPad Prism 9 (La Jolla, CA, USA). The

unpaired Student's *t*-test was applied to compare two groups, while the one-way ANOVA was applied for multiple comparisons, followed by Dunnett's post hoc test. The statistical test for each plot is specified in the corresponding legend. The significance level was  $\leq 0.05$ .

## **Results**

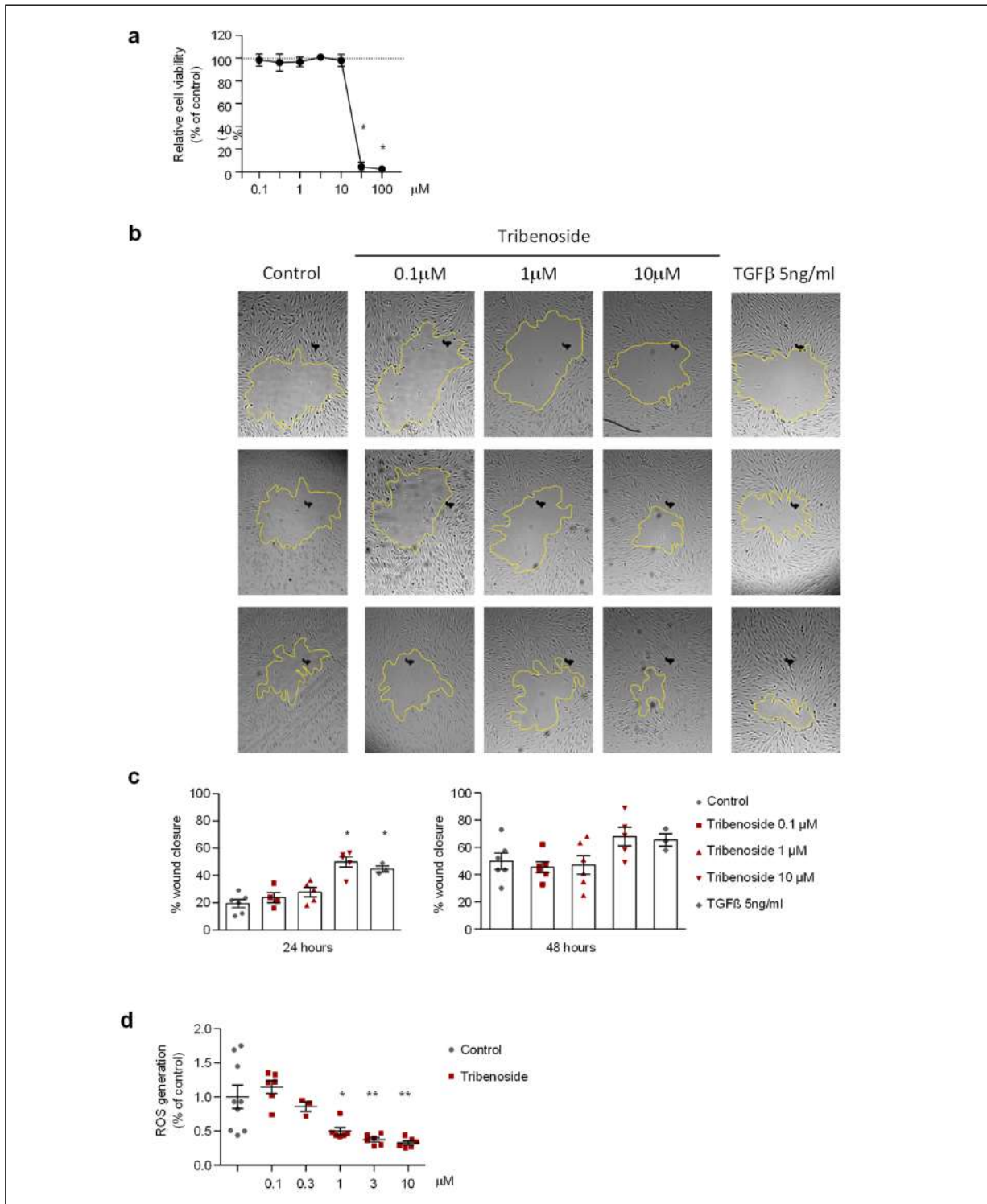
### **Tribenoside Promotes Wound Healing in Human Dermal Fibroblasts In-Vitro**

The process of wound healing is supported by two complementary events: cell proliferation and cell migration. To assess the effect of tribenoside on cell proliferation, human dermal fibroblasts (HDF) were treated with increasing concentrations of tribenoside (0.1-100  $\mu\text{M}$ ) for 24 hours. Tribenoside did not induce any significant change in cell viability at concentrations up to 10  $\mu\text{M}$ , but it was found to be toxic at higher concentrations (Figure 1a). This on/off toxicity of tribenoside above 10  $\mu\text{M}$  has been previously described<sup>18</sup>. The efficacy of tribenoside in stimulating cell migration was then investigated in a classical *in vitro* wound healing assay. HDF grown in monolayer were mechanically wounded and the closure of the wound area was monitored over time using light microscopy in the presence of increasing concentrations of tribenoside (0.1  $\mu\text{M}$ , 1  $\mu\text{M}$  and 10  $\mu\text{M}$ ). TGF- $\beta$  at 5 ng/ml was used as a positive control due to its ability to stimulate wound repair<sup>19</sup>. As shown in Figure 1b-c, tribenoside accelerated wound healing compared to the vehicle, and its effect was concentration-dependent. Specifically, a statistically significant increase in wound area closure was observed after 24 hours of incubation with 10  $\mu\text{M}$  tribenoside (50%), compared to the control (19%). This increase was similar to that of the positive control TGF- $\beta$  (45%) (Figure 1c). After 48 hours of incubation, a tendency was observed with 10  $\mu\text{M}$  tribenoside, although not significant.

Collectively, these data demonstrate that tribenoside improves wound healing in HDF by promoting cell migration rather than cell proliferation.

### **Tribenoside Inhibits ROS Production In Vitro**

Reactive oxygen species are crucial regulators of the wound healing process as they are required for defending against invading pathogens<sup>20</sup>. However, sustained excessive production of ROS can lead to oxidative stress, which has detrimental effects on wound healing<sup>21</sup>. The antioxidant acti-



**Figure 1.** Tribenoside promotes *in-vitro* wound healing in human dermal fibroblasts. **a**, Quantification of cell viability after incubation with tribenoside, expressed as % of cell viability of vehicle-treated control. Data are means  $\pm$  SE;  $p < 0.0001$  among groups (one-way ANOVA);  $*p < 0.001$  vs. Control (Dunnett's post hoc test). **b-c**, HDF were mechanically scratched and treated with tribenoside at the indicated concentrations. **b**, Representative pictures for each treatment at several time points. Magnification 4x. **c**, The closure of the wound area was analyzed 24 and 48 hours after treatment and compared with the control group. Data are means  $\pm$  SE;  $p < 0.0001$  among groups (one-way ANOVA);  $*p < 0.01$  vs. Control (Dunnett's post hoc test). **d**, HDF cells were incubated with tribenoside (0.1-10  $\mu$ M) and the level of ROS was measured. All data were normalized on the control group and expressed as means  $\pm$  SE;  $p < 0.0001$  among groups (one-way ANOVA);  $*p < 0.05$ ,  $**p < 0.01$  vs. Control (Dunnett's post hoc test).

vity of tribenoside was assessed by measuring the intracellular levels of ROS in human dermal fibroblasts. Tribenoside reduced intracellular levels of ROS in a dose-dependent manner, with statistical significance being achieved at 1 mM (Figure 1d).

### ***Procto-Glyvenol® Accelerates Wound Closure In Vivo***

The efficacy of Procto-Glyvenol® in accelerating wound healing was tested *in vivo* in a rat model of full-thickness skin wounds. Following surgery, animals either received local application of Procto-Glyvenol twice a day for two weeks or no treatment. Pictures of wounds were taken on day 0 (just after surgery), day 7, day 10 and day 14 (after sacrifice) (Figure 2a). On day 0, the mean wound area was comparable between the two groups (Figure 2b-c) and in line with the theoretical value (0.79 cm<sup>2</sup>, Figure 2c). From day 7 onwards, the Procto-Glyvenol® group showed a smaller wound area than the control group. The difference was statistically significant on days 10 and 14 (Figure 2b-f). There was no significant difference in animal weight between the two groups (Figure 2d), suggesting the absence of major signs of suffering.

The stage of the re-epithelialization process was then evaluated by histological analysis of skin biopsies taken from the wound area after sacrifice. The re-epithelialization process occurs through the migration of keratinocytes from the edge toward the center of the wound area to form a new epidermis. The Procto-Glyvenol® group showed a significantly higher re-epithelialization percentage than the control group (97.50±1.44 vs. 77.49±8.37) (Figure 3b). Additionally, twice as many animals in the Procto-Glyvenol® group achieved complete re-epithelialization compared to the control group (6 out of 8 vs. 3 out of 8, respectively) (Figure 3c). As an indicator of epithelial maturation during the wound healing process, the epidermal thickness was evaluated in those samples that showed complete re-epithelialization only. The epidermis was 2- to 3-fold thicker in the wound area than in uninjured skin, with no statistically significant difference between the Procto-Glyvenol® and the control groups (Figure 3d, e). This indicates that the remodeling phase of wound healing had not been completed yet under either condition.

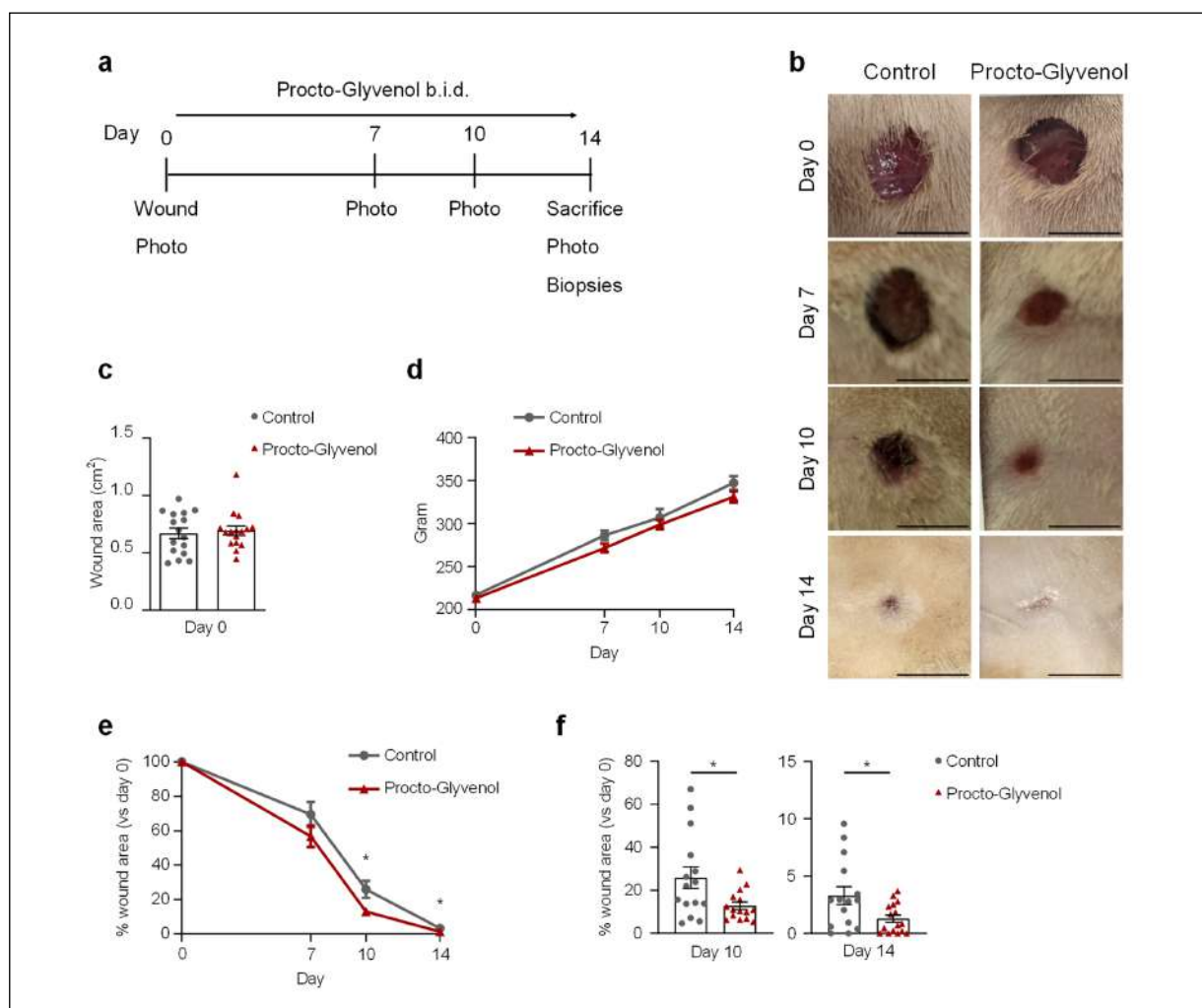
### ***Procto-Glyvenol Does Not Have Any Toxic Effect on the Maturation of Tissue***

Histopathological parameters, including ulceration, epidermal and dermal inflammation,

vascular proliferation and distortion, fibroblast proliferation and fibrosis, were then evaluated by analyzing Hematoxylin and Eosin-stained sections (Figure 4a). Skin biopsies of the control and Procto-Glyvenol® groups showed substantially comparable characteristics, despite a certain degree of heterogeneity among samples of the same group. The epidermis was substantially regular and devoid of major alterations, with only one sample of the control group displaying severe ulceration (Figure 4b). The granulation tissue in the two groups exhibited comparable characteristics, with infiltration of inflammatory cells, particularly granulocytes, the proliferation of small blood vessels with normal morphology, and mild to severe proliferation of fibroblasts associated with fibrosis. The histological evaluation was scored based on the severity of each parameter, with a score ranging from 0 (absent) to 3 (severe). The scores of each parameter were then summed up to yield a final score for each sample. The final score confirmed that the wounds treated with Procto-Glyvenol® were comparable to those of the control group in terms of tissue remodeling and maturation (Figure 4c). Therefore, the histopathological analysis demonstrated that Procto-Glyvenol® does not interfere with the natural process of tissue remodeling and does not have a toxic effect on the tissue. Overall, these data suggest that Procto-Glyvenol® is an effective treatment for improving the rate of wound healing through stimulation of the re-epithelialization process.

## **Discussion**

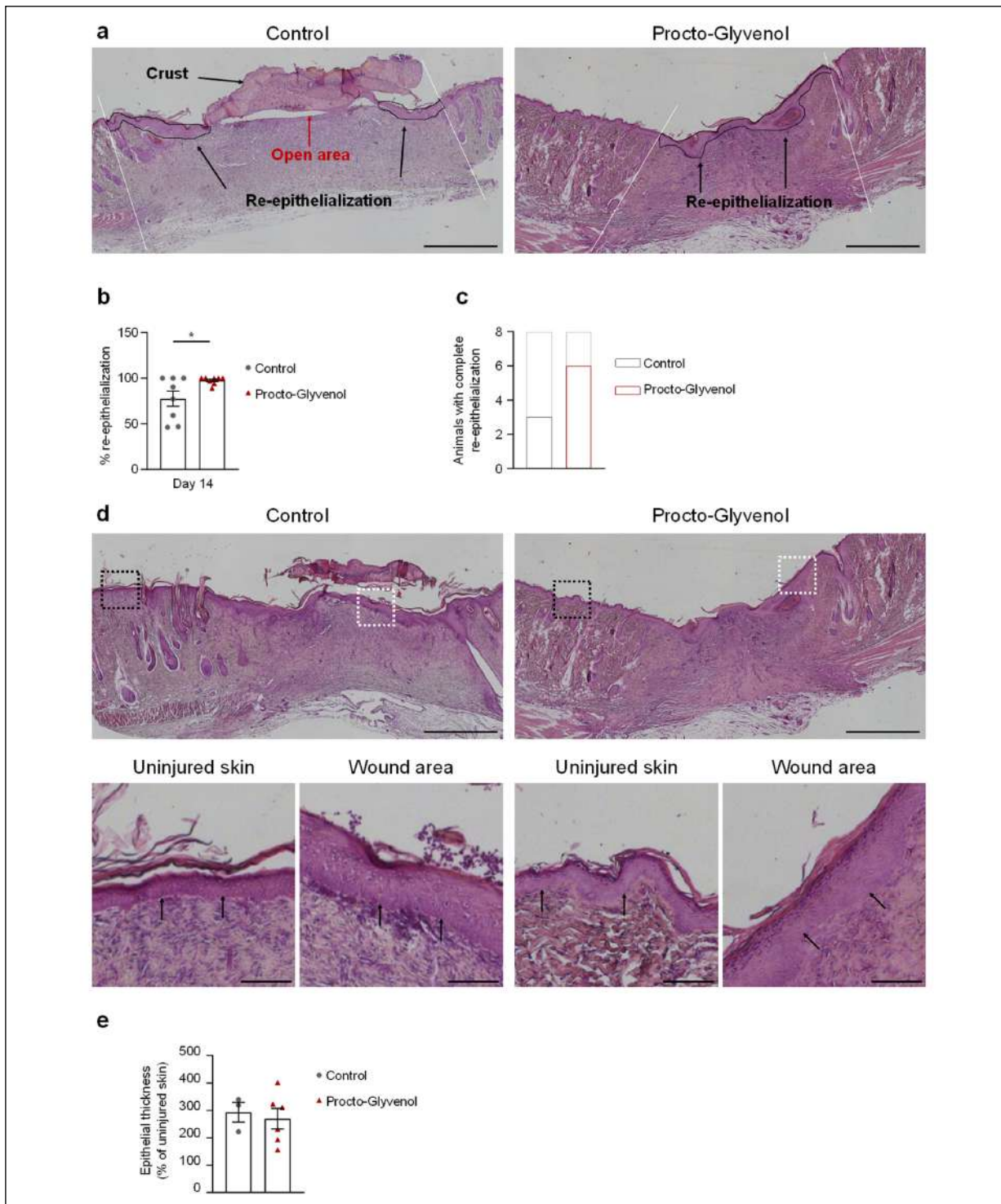
Procto-Glyvenol®, the association tribenoside + lidocaine, has been used for decades for the clinical management of hemorrhoids, particularly in patients who do not tolerate corticosteroids well, like pregnant and breastfeeding women, athletes, and the elderly. The positive effect of Procto-Glyvenol® on wound healing has been widely reported in clinical practice<sup>13,14</sup>. However, the mechanism of action through which tribenoside enhances wound healing was still unclear. Previous studies<sup>15,22</sup> showed that oral administration of tribenoside promotes wound healing in rats by increasing the formation of granulation tissue. Using both *in vitro* and *in vivo* models, the present study confirmed that tribenoside promotes the natural healing process of wounds even when applied topically. Specifically, in wound healing experiments *in vitro*,



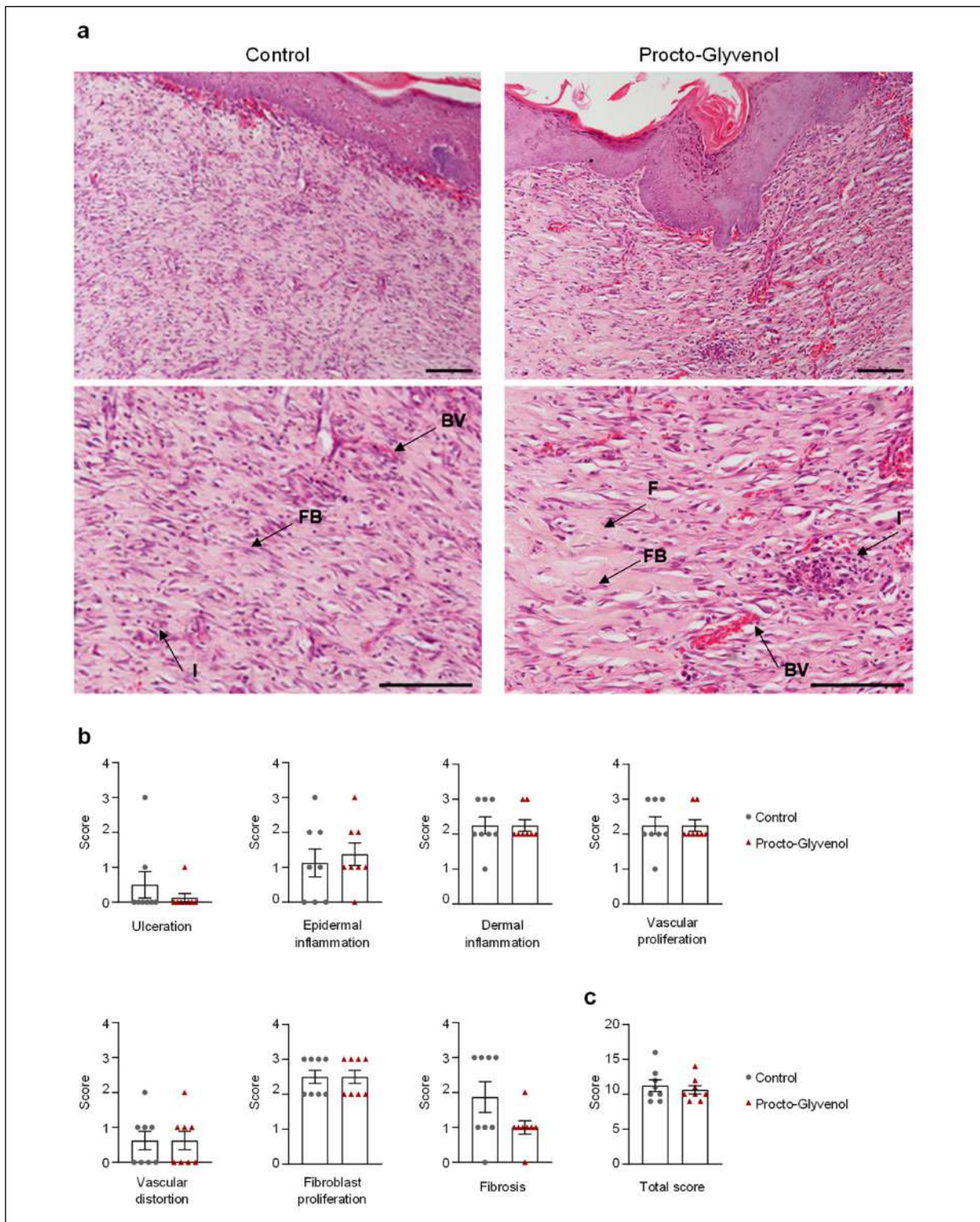
**Figure 2.** Procto-Glyvenol® accelerates wound closure *in vivo*. **a**, Experimental scheme. Procto-Glyvenol® was administered twice a day until day 13; photos were taken on days 0, 7, 10 and 14 after sacrifice. **b**, Representative photographs of skin wounds from control and treated rats taken on days 0, 7, 10 and 14; scale bar: 1 cm. **c**, Quantification of wound area after surgery on day 0, expressed in cm<sup>2</sup>. Data are mean  $\pm$  SE;  $p > 0.05$  (Student's *t*-test); each dot represents a wound. **d**, Plot showing the weight of the rats during the experiment, expressed in grams. Data are means  $\pm$  SE. **e**, Quantification of wound area at different time points, expressed as percentage of the area on day 0. Data are means  $\pm$  SE;  $p < 0.0001$  over time,  $p < 0.02$  between treatments (two-way ANOVA),  $*p < 0.05$  Procto-Glyvenol® vs. Control (Student's *t*-test);  $n = 8$  wounds per group. **f**, Quantification of wound area on day 10 and day 14, expressed as percentage of the area on day 0. Data are means  $\pm$  SE;  $*p < 0.05$  (Student's *t*-test); each dot represents a wound.

tribenoside induced human fibroblasts to migrate and close the wound, with no apparent effect on the proliferation rate. This was paralleled by faster wound healing after topical application of Procto-Glyvenol® to skin wounds in rats. Procto-Glyvenol® stimulated natural tissue regeneration compared to control by improving the re-epithelialization process. Re-epithelialization is sustained by the migration of keratinocytes from the border to the center of the wound. On the other hand, there was no difference in the underlying granulation tissue in terms of inflammatory infiltrate, extracellular matrix depo-

sition, and vascular and fibroblast proliferation. These data suggest that tribenoside promotes the wound-healing process by increasing cell migration while not affecting the natural process of tissue maturation and remodeling or causing any toxic effect on the tissue. The *in vivo* data also suggest that tribenoside acts preferentially on keratinocytes. However, at the stage at which the histological analysis was performed (14 days after wounding), the healing process was advanced, and the granulation tissue, which is composed mostly of fibroblasts, blood vessels and inflammatory cells, had already formed



**Figure 3.** Procto-Glyvenol<sup>®</sup> improves re-epithelialization process. **a**, Representative H&E-stained histological sections showing the re-epithelialization process in Control and Procto-Glyvenol<sup>®</sup> treated wounds; magnification 4x; scale bar: 1 mm. White lines delimit wound edges; black arrows point to the re-epithelialization area; red arrows point to the open area of the wound. **b**, Quantification of the percentage of re-epithelialization on day 14. Data are mean  $\pm$  SE; \* $p < 0.05$  (Student's *t*-test); each dot represents a wound. **c**, Plot showing the ratio of animals with complete re-epithelialization process for each group. Data are expressed as the number of animals with complete re-epithelialization on the total number of animals analyzed (8).  $p > 0.05$  (Fisher's test). **d**, Representative H&E-stained histological sections showing hyperplasia of newly formed epithelium in wound area (white boxes), compared to uninjured skin (black boxes); magnification 4x; scale bar: 1 mm upper panels, 100  $\mu$ m lower panels. Arrows point to epithelium. **e**, Quantification of the thickness of the newly formed epithelium, expressed as a percentage of the thickness of uninjured skin. Data are means  $\pm$  SE;  $p > 0.05$  (Student's *t*-test); each dot represents a wound.



**Figure 4.** Procto-Glyvenol® has no effect on the maturation of granulation tissue. **a**, Representative H&E-stained sections showing the epithelium and the granulation tissue in the wound area; magnification 10x; scale bar: 100 µm. FB: fibroblast; F: fibrosis; BW: blood vessel; I: inflammation. **b**, Histopathological analysis and semi-quantitative scoring for the following parameters: ulceration, epidermal inflammation, dermal inflammation, vascular proliferation, vascular distortion, fibroblast proliferation and fibrosis. The score was assigned based on severity as follows: 0 absent; 1 mild; 2 moderate; 3 severe. Data are means ± SE;  $p > 0.05$  (Student's *t*-test); each dot represents a wound. **c**, Total score is the sum of the score of the seven parameters analyzed. Data are means ± SE;  $p > 0.05$  (Student's *t*-test); each dot represents a wound.

completely. Therefore, the increased proliferation of fibroblasts observed in the *in vitro* experiment was not confirmed *in vivo*. An earlier time point of analysis might have revealed a difference in proliferation between treated and control groups.

The *in vitro* data also suggest that tribenoside has antioxidant activity, as it decreases the production of ROS under basal conditions. Although ROS acts as a first-line defense against invading pathogens, excessive production of ROS leads to oxidative stress, which is a cause of impaired wound healing in many pathological conditions. Therefore, the use of antioxidant agents to treat non-healing wounds has been proposed<sup>23-25</sup>.

The antioxidant activity of tribenoside is a novel insight into its mechanism of action that further supports the clinical findings, although it requires further investigation in *in vivo* models. The combination of tissue regeneration and antioxidant activity, linked to the anesthetic activity of lidocaine, accounts for the improvement of signs and symptoms observed in clinical settings and makes Procto-Glyvenol® the drug of choice for the treatment of low-grade hemorrhoids.

### Limitations

The major limitation of the study is that the histological analysis of wound samples was performed at a one-time point only and could not describe tissue changes over time. Specifically, conducting an analysis at an earlier time point (i.e., 1 week) could have confirmed the increased fibroblast migration observed *in vitro*. Conversely, an analysis at a later time point could have described differences in events that occur later in the healing process, such as epithelium remodeling and tissue maturation.

### Conclusions

Hemorrhoids represent a significant medical and socioeconomic problem because of their high prevalence and the severe discomfort that they cause. The pathogenesis of hemorrhoids is complex and includes abnormal venous dilatation, severe inflammation, and wounds. Using *in vitro* and *in vivo* approaches, this study investigated the mechanisms underlying Procto-Glyvenol® activity. Procto-Glyvenol® accelerated the natural process of tissue regeneration and was shown to possess antioxidant activity, helping to reduce the oxidative stress that might cause impaired wound healing.

In conclusion, based on these findings, the benefit of Procto-Glyvenol® in treating hemorrhoids could be due to an accelerated wound healing process obtained by increased cell migration and reduced oxidative stress.

---

### Acknowledgments

The authors would like to acknowledge Dr. Federica Pisati from the Tumour and Microenvironment Histopathology Unit, FIRC Institute of Molecular Oncology (IFOM), Milan, for the excellent technical work. Editorial assistance was provided by Aashni Shah and Valentina Attanasio (Polistudium SRL, Milan, Italy) and was supported by Recordati S.p.a.

---

### Funding

The study has been conducted with the funds of Recordati S.p.a.

---

### Conflict of Interest

Matteo Malinverno, Elisa Callegari, Lorenza Pirona, Isabella Pellerani, Patrizia Angelico, and Stefano Biondi are employees of Recordati S.p.a.

---

### Authors' Contributions

SB and PA conceived the study; MM and IP performed the *in vivo* experiments and analyzed the data; EC and LP performed the *in vitro* experiments and analyzed the data; BB and CT performed histopathological evaluation; MM wrote the manuscript, which was revised by all the authors.

---

### Informed Consent

Not applicable.

---

### Ethics Approval

Ethical approval has been granted by the Italian Ministry of Health with the authorization number 315/2022-PR.

---

### Data Availability

All data generated or analyzed during this study are included in this published article.

### References

- 1) Lohsiriwat V. Hemorrhoids: from basic pathophysiology to clinical management. *World J Gastroenterol* 2012; 18: 2009-2017.
- 2) Ratto C, Orefice R, Tiso D, Martinisi GB, Pietroletti R. Management of hemorrhoidal disease: new generation of oral and topical treatments. *Eur Rev Med Pharmacol Sci* 2020; 24: 9645-9649.

- 3) Thomson WH. The nature of haemorrhoids. *Br J Surg* 1975; 62: 542-552.
- 4) Ganz RA. The evaluation and treatment of hemorrhoids: a guide for the gastroenterologist. *Clin Gastroenterol Hepatol* 2013; 11: 593-603.
- 5) Johanson JF, Sonnenberg A. The prevalence of hemorrhoids and chronic constipation. An epidemiologic study. *Gastroenterology* 1990; 98: 380-386.
- 6) Quijano CE, Abalos E. Conservative management of symptomatic and/or complicated haemorrhoids in pregnancy and the puerperium. *Cochrane Database Syst Rev* 2005; 2005: CD004077.
- 7) Abramowitz L, Sobhani I, Benifla JL, Vuagnat A, Darai E, Mignon M, Madelenat P. Anal fissure and thrombosed external hemorrhoids before and after delivery. *Dis Colon Rectum* 2002; 45: 650-655.
- 8) Riss S, Weiser FA, Schwameis K, Riss T, Mittelböck M, Steiner G, Stift A. The prevalence of hemorrhoids in adults. *Int J Colorectal Dis* 2012; 27: 215-220.
- 9) Kaidar-Person O, Person B, Wexner SD. Hemorrhoidal disease: A comprehensive review. *J Am Coll Surg* 2007; 204: 102-117.
- 10) Hall JF. Modern management of hemorrhoidal disease. *Gastroenterol Clin North Am* 2013; 42: 759-772.
- 11) Altomare DF, Giannini I. Pharmacological treatment of hemorrhoids: a narrative review. *Expert Opin Pharmacother* 2013; 14: 2343-2349.
- 12) Kestřánek J. Hemorrhoid management in women: the role of tribenoside + lidocaine. *Drugs Context* 2019; 8: 212602.
- 13) Lorenc Z, Gokce O. Tribenoside and lidocaine in the local treatment of hemorrhoids: an overview of clinical evidence. *Eur Rev Med Pharmacol Sci* 2016; 20: 2742-2751.
- 14) Faikoglu G, Saygisever-Faikoglu K, Ozcan FO. Tribenoside–lidocaine combination in wound healing of hemorrhoids: a review of literature. *Pharm Pharmacol Int J* 2021; 9: 236-240.
- 15) Jaques R. The pharmacological activity of tribenoside. *Pharmacology* 1977; 15: 445-460.
- 16) Schindelin J, Arganda-Carreras I, Frise E, Kaynig V, Longair M, Pietzsch T, Preibisch S, Rueden C, Saalfeld S, Schmid B, Tinevez JY, White DJ, Hartenstein V, Eliceiri K, Tomancak P, Cardona A. Fiji: an open-source platform for biological-image analysis. *Nat Methods* 2012; 9: 676-682.
- 17) van de Vyver M, Boodhoo K, Frazier T, Hamel K, Kopcewicz M, Levi B, Maartens M, Machcinska S, Nunez J, Pagani C, Rogers E, Walendzik K, Wisniewska J, Gawronska-Kozak B, Gimble JM. Histology scoring system for murine cutaneous wounds. *Stem Cells Dev* 2021; 30: 1141-1152.
- 18) Kikkawa Y, Takaki S, Matsuda Y, Okabe K, Taniguchi M, Oomachi K, Samejima T, Katagiri F, Hozumi K, Nomizu M. The influence of Tribenoside on expression and deposition of epidermal laminins in HaCaT cells. *Biol Pharm Bull* 2010; 33: 307-310.
- 19) Amento EP, Beck LS. TGF-beta and wound healing. *Ciba Found Symp* 1991; 157: 115-123.
- 20) Schäfer M, Werner S. Oxidative stress in normal and impaired wound repair. *Pharmacol Res* 2008; 58: 165-171.
- 21) Dunnill C, Patton T, Brennan J, Barrett J, Dryden M, Cooke J, Leaper D, Georgopoulos NT. Reactive oxygen species (ROS) and wound healing: the functional role of ROS and emerging ROS-modulating technologies for augmentation of the healing process. *Int Wound J* 2017; 14: 89-96.
- 22) Wilhelmi G. Einfluss von oral verabreichtem Tribenosid auf die Wundheilung an der normalen Rattenhaut [Effect of orally administered tribenoside on wound healing in the normal rat skin]. *Arzneimittelforschung* 1974; 24: 934-937.
- 23) Ozdemir A, Topçu A, Mercantepe T, Arpa M, Mataracı Karakaş S, Ozdemir A, Tümkaya L, Mercantepe F. The effects of dexmedetomidine on early acute kidney injury in severely burned rats. *Eur Rev Med Pharmacol Sci* 2023; 27: 1311-1321.
- 24) Şimşek Sezer EN. In vitro investigation of cytotoxic, antioxidant, apoptosis-inducing, and wound healing properties of endemic *Centaurea fenzi* Reichardt extracts. *Eur Rev Med Pharmacol Sci* 2022; 26: 1462-1474.
- 25) Younis NS, El Semaary NA, Mohamed ME. Silver nanoparticles green synthesis via cyanobacterium *Phormidium* sp.: characterization, wound healing, antioxidant, antibacterial, and anti-inflammatory activities. *Eur Rev Med Pharmacol Sci* 2021; 25: 3083-3096.