



## ORIGINAL ARTICLE

# Clinical, histological, immunohistochemical, and biomolecular analysis of hyaluronic acid in early wound healing of human gingival tissues: A randomized, split-mouth trial

Andrea Pilloni<sup>1</sup> | Lorenzo Marini<sup>1</sup> | Nicoletta Gagliano<sup>2</sup> |  
Elena Canciani<sup>3</sup> | Claudia Dellavia<sup>2</sup> | Laura Brigida Cornaghi<sup>2</sup> |  
Ezio Costa<sup>4</sup> | Mariana A. Rojas<sup>1</sup>

<sup>1</sup>Section of Periodontics, Department of Oral and Maxillofacial Sciences, Sapienza University of Rome, Rome, Italy

<sup>2</sup>Department of Biomedical, Surgical and Dental Sciences, Università degli Studi di Milano, Milan, Italy

<sup>3</sup>Department of Biomedical Sciences for Health, Università degli Studi di Milano, Milan, Italy

<sup>4</sup>Private Practice, Verona, Italy

## Correspondence

Mariana A. Rojas, Section of Periodontics, Department of Oral and Maxillofacial Sciences, Sapienza University of Rome, 6 Caserta Street, Rome 00161, Italy.  
Email: [marianaandrea.rojas@uniroma1.it](mailto:marianaandrea.rojas@uniroma1.it)

## Abstract

**Background:** Hyaluronic acid (HA) exerts a fundamental role in tissue repair. In vitro and animal studies demonstrated its ability to enhance wound healing. Nevertheless, in vivo human studies evaluating mechanisms involved in oral soft tissue repair are lacking. The aim of this study was to evaluate the in vivo effect of HA on early wound healing of human gingival (G) tissues.

**Methods:** In the present randomized, split-mouth, double-blind, clinical trial, G biopsies were obtained in eight patients 24 h post-surgery after HA application (HA group) and compared with those obtained from the same patients without HA application (no treatment; NT group). Clinical response was evaluated through the Early Wound Healing Score (EHS). Microvascular density (MVD), collagen content and cellular proliferation were evaluated through sirius red and Masson trichrome staining, and Ki-67 immunohistochemistry, respectively. To assess collagen turnover, MMP-1, MMP-2, MMP-9, TGF- $\beta$ 1 protein levels and *LOX*, *MMPI*, *TIMPI*, *TGFBI* gene expression were analyzed by western blot and real time polymerase chain reaction.

**Results:** Twenty-four hours after surgery, the EHS was significantly higher in the HA group. MVD, collagen content, and cell proliferation were not affected. *LOX* mRNA, MMP-1 protein, and *TIMPI* gene expression were significantly upregulated in the HA compared to the NT group.

**Conclusions:** The additional use of 0.8% HA gel does not modify new blood vessel growth in the early phase of gingival wound healing. Concerning the secondary outcomes, HA seems to enhance extracellular matrix remodeling and

This is an open access article under the terms of the [Creative Commons Attribution-NonCommercial-NoDerivs](https://creativecommons.org/licenses/by-nc-nd/4.0/) License, which permits use and distribution in any medium, provided the original work is properly cited, the use is non-commercial and no modifications or adaptations are made.

© 2023 The Authors. *Journal of Periodontology* published by Wiley Periodicals LLC on behalf of American Academy of Periodontology.



collagen maturation, which could drive early wound healing of G tissues to improve clinical parameters.

#### KEYWORDS

cell biology, collagen turnover, fibroblast(s), gene expression, gingiva, oral mucosa, wound healing

## 1 | INTRODUCTION

Hyaluronic acid (HA) is a major endogenous component of the extracellular matrix (ECM) in almost all tissues. It is an hygroscopic and viscoelastic biomolecule with an essential role in maintaining the integrity of tissues.<sup>1</sup> HA is active through the entire process of wound healing,<sup>2</sup> which is characterized by a sequence of regulated phases (hemostasis, inflammation, granulation tissue formation, and tissue remodeling) that require new collagen matrix deposition and efficient vascularization.<sup>3</sup>

In oral wound repair, fibroblasts are responsible for the production of most ECM components.<sup>4</sup> HA induces fibroblast proliferation and new vessel formation.<sup>5</sup> In periodontal wound healing, HA seems to promote the inflammatory response by stimulating the synthesis of hyaluronan by endothelial cells (ECs).<sup>6</sup>

In vitro and animal studies have demonstrated the ability of HA to enhance the healing process<sup>7–9</sup> and, due to its beneficial effects,<sup>10</sup> it has been extensively used in the periodontal field.<sup>11–14</sup>

Asparuhova et al. demonstrated that HA enhances the proliferation of human oral fibroblasts in vitro. However, in vitro experiments present limitations, since during the postsurgical period, hyaluronidase could degrade HA to lower the molecular weight (MW), exerting additional or opposing effects on wound repair.<sup>15</sup>

Although all of the above-mentioned studies demonstrated the potential beneficial effects of HA, the specific in vivo cellular mechanisms involved remain unclear.

Recently, Canciani et al.,<sup>16</sup> in an in vivo study on human gingival biopsies collected 10 days after surgery, observed a higher microvascular density (MVD) after HA treatment.

However, it is important to highlight that the cellular response begins early after injury. In fact, previous studies demonstrated that the main transcriptional changes occur in the first 12 to 24 h.<sup>17–19</sup> This was also confirmed by our previous human studies.<sup>20,21</sup> From a clinical point of view, healing during the first postoperative days is crucial for wound stability maintenance and, therefore, for successful treatment outcome.<sup>22</sup>

Thus, the elucidation of the mechanisms related to cellular activation and gene expression modulation in the

early phases of oral wound repair after HA treatment could allow a strategic use of HA in the wound care environment.

Therefore, the main aim of the present study was to evaluate the in vivo effect of HA in the early phases following surgical wounding through histological, immunohistochemical, and biomolecular analyses of human buccal attached gingival (G) biopsies obtained 24 h after injury.

The second aim was to evaluate the clinical response at 24 h and 1 week after injury.

## 2 | MATERIALS AND METHODS

### 2.1 | Study design and ethics statements

The present study was designed as a randomized, split-mouth, double-blind clinical trial performed according to current standards of clinical research (CONSORT guidelines) (<http://www.consort-statement.org>).

The CONSORT diagram is presented in Figure S1 in the online *Journal of Periodontology*.

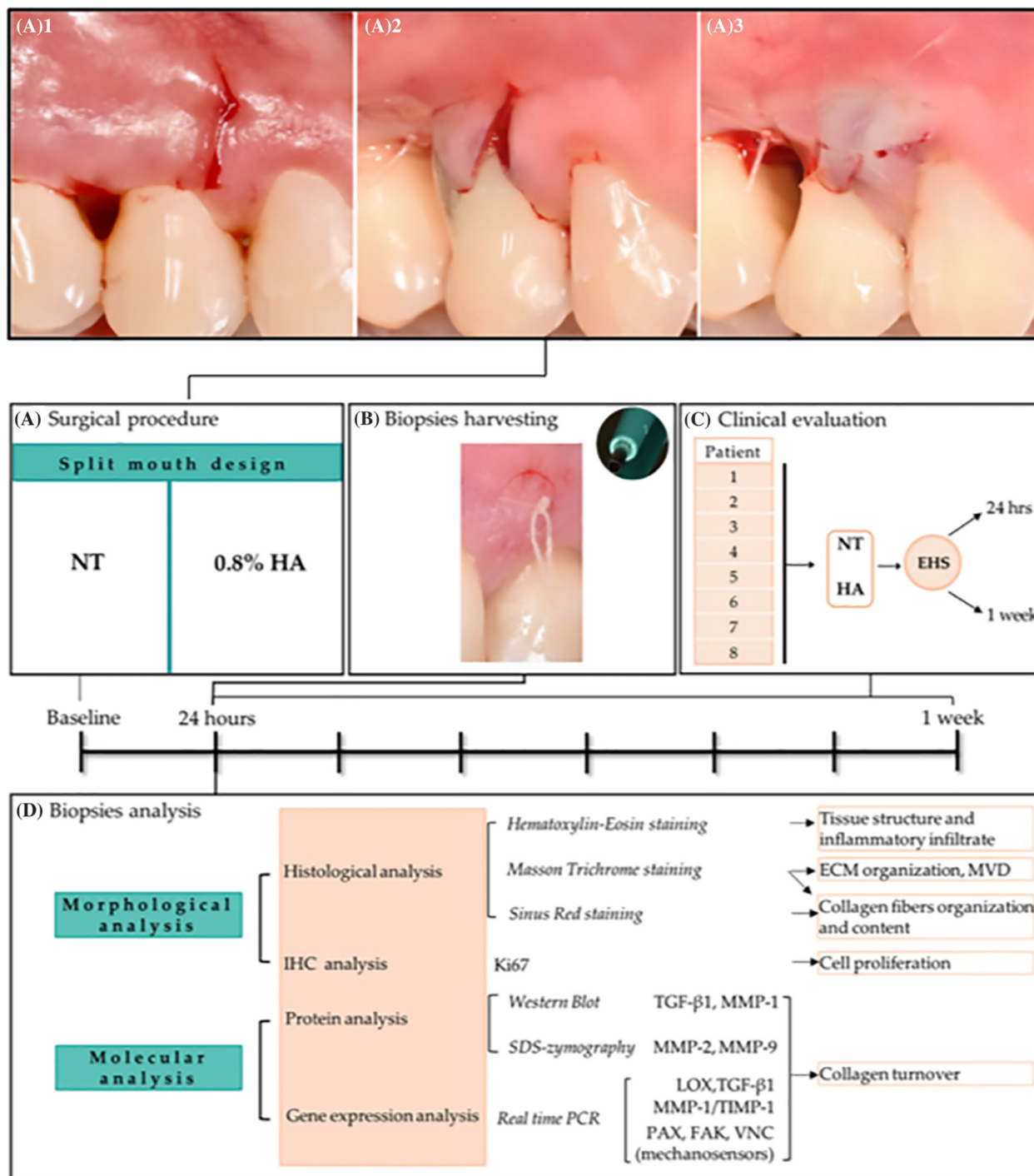
The study protocol (ClinicalTrials.gov- NCT04865952) was approved by the Sapienza University of Rome Ethics Committee (Ref.5315-Prot.0640/2020). Each participant signed an informed consent statement in accordance with the Declaration of Helsinki (1975, revised in 2013).

The trial was conducted at the Section of Periodontics of the Department of Oral and Maxillo-Facial Sciences of Sapienza, University of Rome, between April and July 2021.

The experimental design is presented in Figure 1.

### 2.2 | Patient selection

The inclusion criteria were as follows: (1) males and females between 18 to 50 years of age, (2) after nonsurgical periodontal therapy reevaluation, molar teeth of the first and third sextants exhibiting residual periodontal pockets (probing pocket depth  $\geq$  5mm) requiring surgical treatment by means of open flap debridement; (3) periodontally



**FIGURE 1** Outline of the experimental design. (A) Eight patients undergoing two surgical procedures were treated with a split-mouth design and assigned to either 0.8% hyaluronic acid (HA) application (HA group) or no treatment (NT group). Callout panel: (A)1—vertical releasing incision (VRI); (A)2—HA placed at the end of the surgical procedure, at the level of the VRI; (A)3—HA placed over the closed VRI. (B) Buccal attached gingival (G) biopsies were harvested 24 h after surgery from eight patients. (C) Clinical evaluation was performed at 24 h and 1 week after surgery by means of the Early Wound Healing Score (EHS) in the NT and HA groups. (D) Each G biopsy was divided into three parts, for histological-immunohistochemical (IHC) analysis, for protein analysis, and for gene expression analysis, in order to carry out both morphological and molecular analyses. For the histological-IHC analysis, tissue structure and inflammatory infiltrate, extracellular matrix (ECM) organization and microvascular density (MVD), and collagen fiber organization/content were evaluated through hematoxylin-eosin, Masson trichrome and Sirius Red staining, respectively, while cellular proliferation was evaluated by immunohistochemical detection of Ki-67. For the molecular analysis, collagen turnover was evaluated through MMP-1, MMP-2, MMP-9, and TGF- $\beta$ 1 protein analysis by Western blot and SDS-zymography, and lysyl oxidase (LOX), MMP1, TIMP1, and TGFBI gene expression by real time polymerase chain reaction. Gene expression of key proteins playing a role as mechanosensors (PAX, FAK, VNC) were also assessed.



healthy status (full-mouth plaque score and full-mouth bleeding score <15%).

The following conditions served as exclusion criteria: (1) systemic diseases; (2) history of poor wound healing; (3) pregnant or lactating; (4) smoking; (5) medications affecting periodontal status (e.g., phenytoin, calcium channel blockers and cyclosporine); (6) therapy with anticoagulants, corticosteroids, or any drug interfering with the healing process during the previous 6 months.

### 2.3 | Surgical procedures and biopsy collection

All surgical procedures were performed by the same experienced operator (AP).

After local anesthesia, buccal and palatal intracrevicular incisions were made keeping the mesiodistal extension from the distal aspect of the upper second molar to the mesial aspect of the upper second premolar. On the buccal side, a vertical releasing incision (VRI) was performed mesial to the second premolar to improve surgical access. The VRI was always kept within the attached gingiva. The full thickness mucoperiosteal flaps were elevated, limiting the apical reflection to 1 to 2 mm beyond the mucogingival junction. No periosteal incisions were made. The defects were debrided with mini curettes and ultrasonic instruments and the roots were planed. During the instrumentation the flaps were carefully protected with periosteal elevators and frequently irrigated with sterile saline.

Prior to applying external interrupted mattress sutures at the interdental sites for flap repositioning at the presurgical level, surgical sites were randomized (by tossing a coin) to either receive HA application (HA group) or have no treatment (NT group).

For the HA group, 0.2 ml of 0.8% high MW HA gel\* was placed at the level of the VRI. Then, in both groups, primary closure of the VRI was made using interrupted sutures (polyglycolic acid-PGA, 6-0 monofilament).† Finally, in the HA group, 0.2 ml of gel was applied topically on the closed VRI with a gentle massage for 2 min.<sup>23</sup> HA application was performed using a syringe with local drug delivery tips (Figure 1A).

No postoperative chlorhexidine mouth rinse was prescribed during the first 24 h after surgery.<sup>24</sup>

At 24 h, G biopsies were harvested at the level of the VRIs with a biopsy punch of 2.0 mm diameter, replicat-

ing our previous studies.<sup>20,21,24</sup> The biopsy areas healed by secondary intention and sutures were removed at 1 week.

### 2.4 | Clinical analysis

A blinded examiner (LM) evaluated the clinical response at the level of the VRIs 24 h after surgery (before harvesting the biopsies) and after 1 week (before suture removal), using the Early Wound Healing Score (EHS).<sup>25,26</sup>

The examiner underwent a calibration session on five VRIs not included in the present investigation. He was asked to evaluate the EHS at 1 day from the surgical procedure on two occasions 120 min apart. Calibration was not considered acceptable if the intraclass correlation coefficient was <0.81.

The EHS was recently introduced to assess wound healing by primary intention in periodontal soft tissues. This score is based on the evaluation of clinical signs of re-epithelialization (0, 3, or 6 points), hemostasis (0, 1, or 2 points) and inflammation (0, 1, or 2 points). The sum of these three parameters is calculated as the EHS, which ranges between 0 to 10 points (worst to ideal wound healing).

### 2.5 | Morphological analysis

Two blinded experienced examiners (NG and EC) performed the morphological analysis.

To minimize human-related biases, each stained slide after digitalization was blindly analyzed by the two expert morphologists: the first expert (NG) validated all the results and the second expert (EC) blindly and randomly reviewed 10% of the score.<sup>27</sup>

Each G biopsy was divided into three parts: histological, gene expression, and protein analysis. G biopsies were fixed in 10% neutral buffered formalin and processed for paraffin embedding. Sections of 4 μm thickness were cut using a Leica microtome, routinely dewaxed, rehydrated, and processed for histological staining, histochemistry, and immunohistochemistry. All of the slides were acquired using a high resolution scanner (NanoZoomer S60)‡ and the digital slides were managed and evaluated using NDP.view2 image-dedicated software.‡ Sections were analyzed to study morphological features, MVD, ECM organization, collagen content, and cellular proliferation.

\* Gengigel® Prof syringes, Ricerfarma, Milan, Italy

† Ethicon, Johnson & Johnson, Somerville, NJ, USA

‡ Bio Optica, Milan



Tissue structure and presence of inflammatory infiltrate were evaluated on hematoxylin and eosin-stained sections.

### 2.5.1 | Masson trichrome staining

Masson trichrome with aniline staining was performed following the manufacturer's protocol,<sup>\*</sup> and the sections were used to analyze ECM organization and to calculate the MVD. The staining highlights nuclei in black, cytoplasm in red, erythrocytes in yellow, and collagen fibers in blue. Microvessels were evaluated by a stereology-based method on the slides scanned with an Aperio Scan Scope System CS2.<sup>†</sup> A customized digital counting grid was employed to evaluate the MVD of each tissue slide through histomorphometric analysis. The intersection points of the grid that fell on the vessels were manually counted, and the ratio between test points and total points of the grid that fell on the overall connective tissue was calculated and expressed as a percentage value.<sup>28</sup>

### 2.5.2 | Sirius red staining

Sirius red staining<sup>‡</sup> was performed to stain and analyze interstitial fibrillary collagen organization and content.<sup>28</sup> Slides were deparaffinized and immersed for 30 min in saturated aqueous picric acid containing 0.1% sirius red F3BA<sup>§</sup> and were observed under polarized light<sup>¶</sup> in order to distinguish the newly deposited collagen, describe collagen maturation, and evaluate collagen fiber arrangement.

### 2.5.3 | Immunohistochemistry

The Ki-67 protein is a cell proliferation marker expressed during all active phases of the cell cycle (G1, S, G2, and mitosis), but absent from resting cells (G0).

Ki-67 expression in gingival lining epithelium was analyzed by immunohistochemistry using an anti-Ki-67 (clone B56) and a secondary HRP-conjugated antibody.<sup>#</sup> The evaluation of Ki-67 positive cells was quantified by Image J software on the slides scanned with an Aperio Scan Scope System. The number of Ki-67 immunoreactive cells was

expressed as a percentage relative to the total area of the epithelium considered.

## 2.6 | Molecular analysis of collagen turnover pathways

An experienced examiner (NG) performed the molecular analysis.

### 2.6.1 | Gene expression analysis

Gene expression analysis was performed on gingival homogenates ( $n = 8$  NT + HA per patient). Total RNA was isolated using Tri-Reagent and 1  $\mu$ g of total RNA was reverse-transcribed in 20  $\mu$ l final volume of reaction mix.<sup>||</sup> mRNA levels for collagen turnover-related genes lysyl oxidase (*LOX*), matrix metalloproteinase 1 (*MMP1*), tissue inhibitor of matrix metalloproteinase 1 (*TIMP1*), and *TGFBI* were assessed by real time PCR. mRNA levels for PAX, FAK and VNC, acting as mechanosensors, were also assessed.

Glyceraldehyde 3-phosphate dehydrogenase (*GAPDH*) was used as a housekeeping gene.<sup>29</sup> Each sample was analyzed in triplicate in a Bioer LineGene 9600 thermal cycler<sup>\*\*</sup> and gene expression levels relative to that of *GAPDH* were calculated using the  $\Delta$ CT method.

### 2.6.2 | Western blot analysis

For western blot analysis, gingival fragments ( $n = 6$  NT + HA per patient) were homogenized in Tris-HCl 50 mM pH 7.6, 150 mM NaCl, 1% Triton X-100, 5 mM EDTA, 1% Sodium Dodecyl Sulfate (SDS), and centrifuged at 14,000  $\times$  g for 10 min at 4°C to remove cell debris. For analysis, samples (40  $\mu$ g of total proteins) were diluted in SDS-sample buffer, loaded on 10% SDS-polyacrylamide gel, as previously described.<sup>30</sup> After blocking, membranes were incubated with the mouse anti-MMP1 (1:2000) (Millipore) o.n. at 4°C and anti-mouse horseradish peroxidase (HRP)-conjugated secondary antibody (1:20000 in Tris Buffered Saline with Tween -TBST). To confirm equal loading, membranes were re-probed by monoclonal antibody to actin (1:7500 in TBST). Immunoreactive bands were revealed by the Amplified Opti-4CN substrate (Bio Rad) and quantified by densitometric scanning (UVIBand, Eppendorf).

\* Hamamatsu, Japan

† Leica Biosystem, Milan, Italy

‡ Sigma Aldrich, Italy

§ Nikon Eclipse 80i, Japan

¶ Sigma, Milan, Italy

# Mach 4 Universal HRP-polymer, Biocare Medical, USA

|| Biorad, Segrate, Milan, Italy

\*\* Bioer, Hangzhou, China



**TABLE 1** Demographic parameters of the study population and clinical wound healing response 24 h and 1 week after injury in the HA and NT groups

Demographic data			EHS			
Patient	Age	Sex	24 h		1 week	
			NT	HA	NT	HA
1	47	M	7 (R3, H2, I2)	10 (R6, H2, I2)	9 (R6, H2, I1)	10 (R6, H2, I2)
2	41	M	6 (R3, H2, I1)	10 (R6, H2, I2)	9 (R6, H2, I1)	10 (R6, H2, I2)
3	21	F	6 (R3, H1, I2)	7 (R3, H2, I2)	7 (R3, H2, I2)	9 (R6, H2, I1)
4	28	F	10 (R6, H2, I2)	10 (R6, H2, I2)	10 (R6, H2, I2)	10 (R6, H2, I2)
5	26	F	5 (R3, H1, I1)	10 (R6, H2, I2)	7 (R3, H2, I2)	10 (R6, H2, I2)
6	35	F	7 (R3, H2, I2)	9 (R6, H2, I1)	9 (R6, H2, I1)	10 (R6, H2, I2)
7	39	M	7 (R3, H2, I2)	9 (R6, H2, I1)	9 (R6, H2, I1)	10 (R6, H2, I2)
8	45	M	7 (R3, H2, I2)	9 (R6, H2, I1)	7 (R3, H2, I2)	10 (R6, H2, I2)
Mean ± SD	35.3 ± 9.4					
Range	21–47					
Median (IQR)		7 (1)	9.5 (1)	9 (2)	10 (0)	

Abbreviations: EHS, Early Wound Healing Score; H, clinical signs of hemostasis; HA, hyaluronic acid; I, clinical signs of inflammation; IQR, interquartile range; NT, no treatment; R, clinical signs of re-epithelialization; SD, standard deviation.

### 2.6.3 | SDS-zymography

Gingival homogenates (10 µg of total proteins) were run under nonreducing conditions on 10% polyacrylamide gel (SDS-PAGE) co-polymerized with 1 mg/ml of type I gelatin at 4°C as previously described.<sup>30</sup>

## 2.7 | Outcome measures

The primary outcome was the change in MVD. Secondary outcomes were changes in (1) collagen content and cell proliferation; (2) MMP-1, MMP-2, MMP-9, TGF-β1, PAX, FAK, and VNC protein expression; (3) *LOX*, *MMPI*, *TIMPI*, *TGFBI*, *PAX*, *FAK*, and *VNC* gene expression; (4) clinical response (EHS).

All the outcomes were assessed at 24 h, while the clinical response was also evaluated after 1 week.

## 2.8 | Sample size

Sample size calculation was performed using  $\alpha = 0.05$  and the power of sample  $(1 - \beta) = 95\%$ .

Considering the absence of previous studies providing data on the in vivo effect of HA in G early wound healing, the sample size was calculated based on data from a study of Canullo et al.,<sup>31</sup> in which the MVD average was from 8% to 12% with a standard deviation of 3%. Therefore, the population of the study was calculated to be  $n > 7.35$ .<sup>28,31</sup> Considering a dropout of 15%, eight patients were required.

## 2.9 | Statistical analysis

Data were expressed as mean ± standard deviation (SD). HA and NT group histology, viability, molecular and proteomic data were analyzed by GraphPad Prism v 9.0 software using the nonparametric Wilcoxon test or paired samples.

For continuous variables (EHS score), median and the interquartile range (IQR) were calculated, and the nonparametric Mann-Whitney *U* test was used for statistical analysis.

Values of  $P < 0.05$  were considered statistically significant.

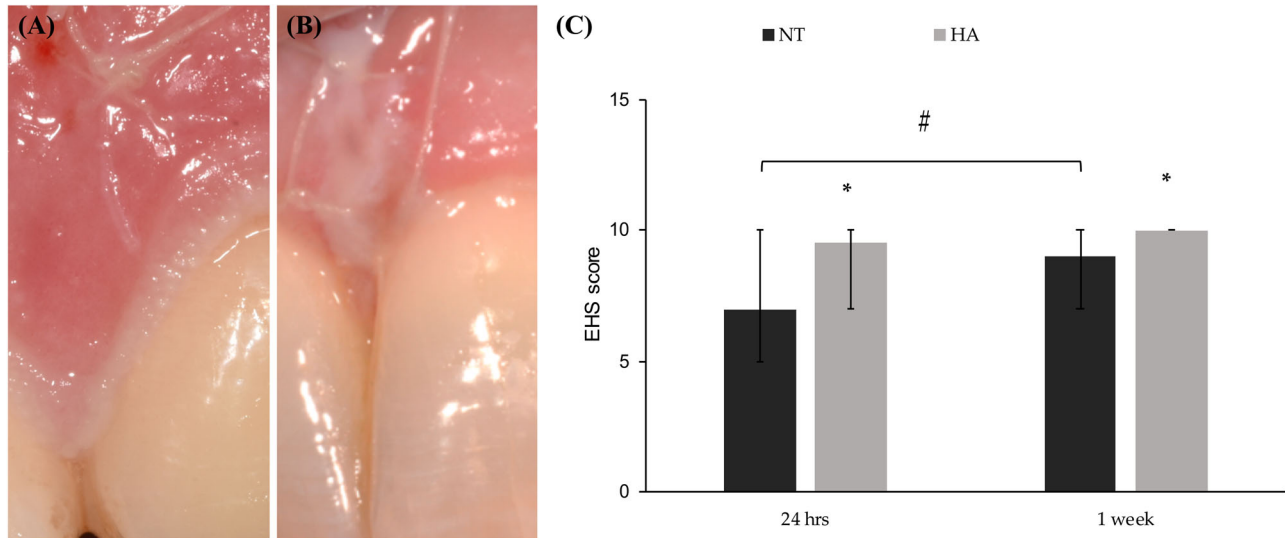
## 3 | RESULTS

### 3.1 | Study population

Eight subjects were included (four females and four males; 35 years ± 9.4, Table 1).

### 3.2 | Clinical response

No complications occurred in any of the patients. At 24 h, the median EHS values for the HA and NT groups were 9.5 (IQR: 1) and 7 (IQR: 1), respectively. At 1 week, the values observed were 10 (IQR: 0) for the HA, and 9 (IQR: 2) for the NT group. Significant differences between groups were found at both time periods evaluated ( $P < 0.05$ ). The EHS value in the HA group showed no significant difference



**FIGURE 2** (A,B) Clinical photographs of patient 5 showing wound healing of gingival tissue 24 h after surgery at the (A) hyaluronic acid (HA)-treated site (Early Wound Healing Score [EHS] = 10) and at the (B) no treatment (NT) site (EHS = 5). (C) Differential clinical wound healing response between NT and HA groups at 24 h and 1 week after surgery evaluated through assessment with the EHS. The median values of the EHS were reported. Error bars represent interquartile range (IQR). \* $p < 0.05$  (NT vs. HA); # $p < 0.05$  (24 h vs. 1 week)

between 24 h and 1 week, while in the NT group this difference was statistically significant ( $P < 0.05$ , Figure 2A–C, Table 1).

### 3.3 | Cell proliferation and histological analysis

Immunohistochemistry analysis of Ki-67 expression in gingival epithelial cells showed a similar cell proliferation in both groups (Figure 3A,B). Histological analysis revealed that gingival structure was not affected by HA treatment. No signs of inflammatory infiltration were evident (Figure 3F).

### 3.4 | Microvascular distribution (MVD)

MVD showed similar results in both experimental groups. MVD was  $15.56\% \pm 3.64$  in the NT group compared with  $14.94\% \pm 6.32$  in the HA group ( $P > 0.05$ , Figure 3C,D).

### 3.5 | Collagen content and turnover pathways

In both groups, light microscopy analysis of Masson Trichrome-stained sections revealed similar ECM organization and collagen content (Figure 3C). Sinus red-stained sections showed dense bundles of collagen fibers extend-

ing in all directions, with the typical organization of dense irregular gingival connective tissue (Figure 3E). Moreover, in polarized light observation in both groups, the staining was dark orange-red, consistent with the presence of mature collagen fibers, while newly deposited collagen was not detected.

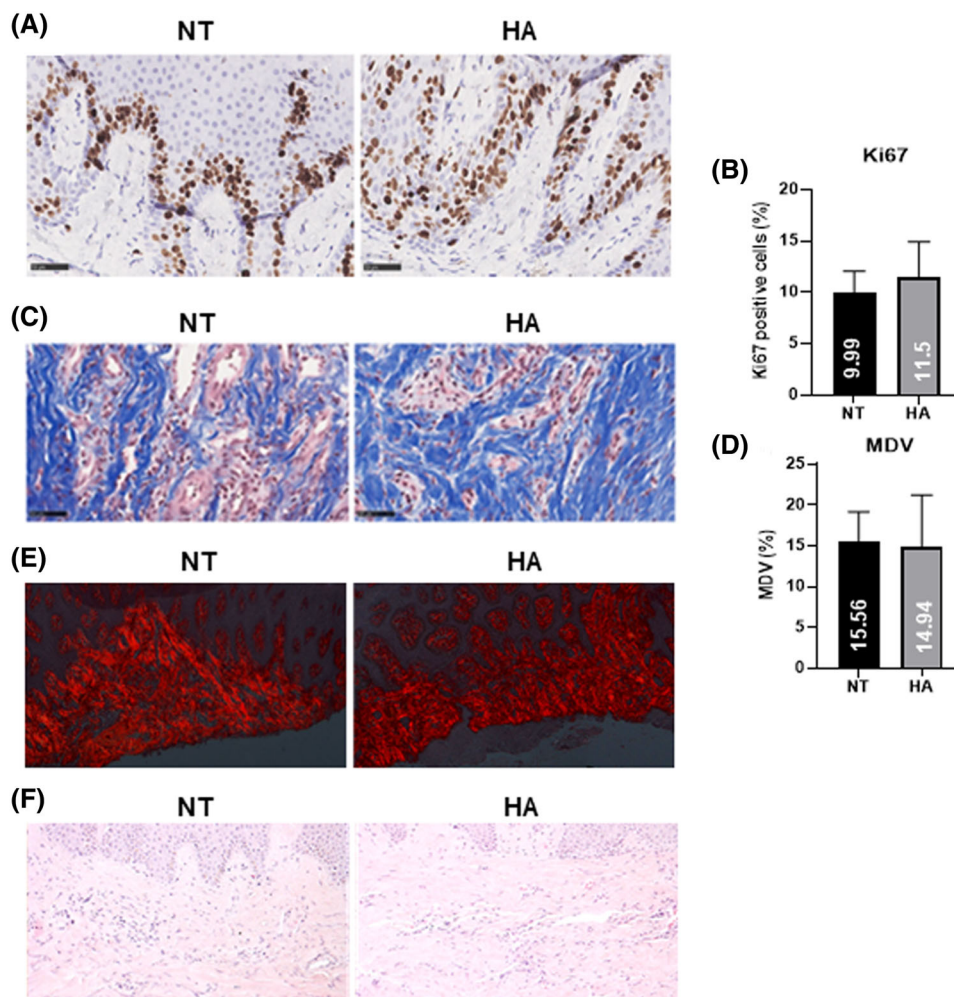
Gene expression analysis showed that LOX mRNA levels were significantly upregulated in the HA group ( $P < 0.05$ , Figure 4A).

Collagen degradation pathways were also investigated. MMP1 gene expression was not significantly affected (Figure 4B). By contrast, western blot analysis of MMP-1 revealed a significant increase in HA compared to NT sites ( $P < 0.05$ , Figure 4C,D). Also, TIMP1 gene expression was significantly induced by HA administration ( $P < 0.05$ , Figure 4E).

SDS-zymography showed that MMP-2 and MMP-9 expression was not affected by HA treatment (Figure 5A–D).

Since collagen turnover pathways can be modulated by TGF- $\beta$ 1, TGF- $\beta$ 1 mRNA levels were also investigated, showing similar results in both groups (Figure 6A). TGF- $\beta$ 1 activation showed a similar pattern. In fact, the ratio between the expression of the 25 kDa active dimer relative to the 44–53 kDa latent inactive protein expression results were similar in the NT and HA-treated samples (Figure 6B).

The expression of FAK, PAX, and VCN, codifying for proteins acting as mechanosensors, was unaffected by HA treatment (Figures 6C–E)



**FIGURE 3** (A) Representative photomicrographs of sections of gingival biopsies taken at hyaluronic acid (HA)-treated and no treated (NT) sites, stained with anti-Ki-67 antibodies. Scale bar 50  $\mu\text{m}$ . (B) Bar graph showing the percentage of Ki-67 immunopositive cells in the NT and HA groups. Data are means  $\pm$  standard deviations. (C) Representative photomicrographs of sections of NT and HA gingival biopsies stained with Masson trichrome showing dense bundles of collagen fibers in multiple directions for both groups, without evident differences in extracellular matrix components and microvascular distribution. Scale bar 50  $\mu\text{m}$ . (D) Bar graph showing the percentage of microvascular density (MVD) values in the NT and HA groups. Data are means  $\pm$  standard deviations. (E) Representative photomicrographs of sections of gingival biopsies stained with Sirius Red observed by polarized light microscope showing a similar content of collagen fibers in NT and HA-treated gingiva. No newly deposited collagen was evident. Scale bar 50  $\mu\text{m}$ . (F) Representative photomicrographs of hematoxylin and eosin-stained sections revealing the absence of inflammatory infiltration and the preserved structure of gingival tissue.

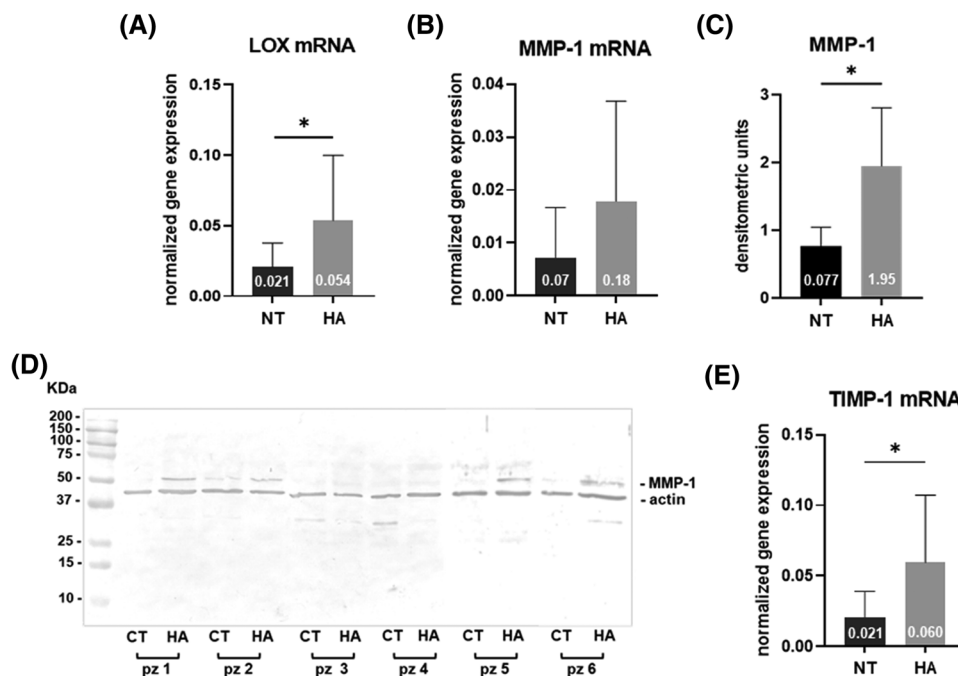
## 4 | DISCUSSION

Gingival tissue-derived cells play an important role in oral wound healing.<sup>32</sup> Proper soft tissue repair after surgical procedures is an essential issue for clinical success.<sup>33</sup> The use of biologically active agents that influence cell behavior is of significant interest. In the present study, we investigated whether HA was able to favor gingival wound repair, using a high MW<sup>34</sup> 0.8% HA gel, due to its specific indications and the available literature demonstrating its ability to improve the wound healing.<sup>1,2,5–9</sup>

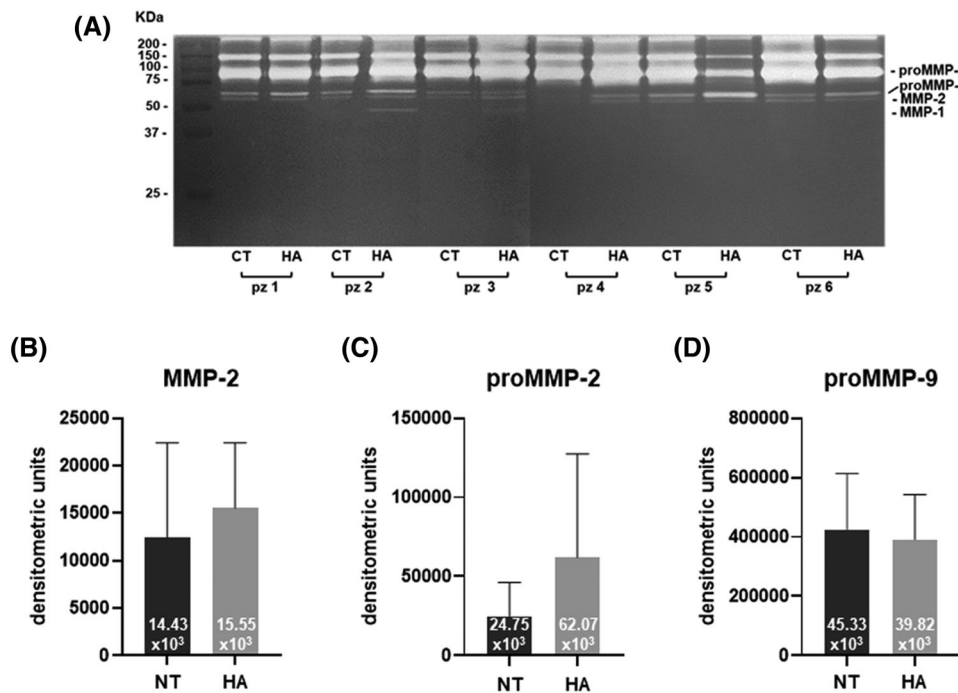
The clinical response was assessed by the EHS score.<sup>25</sup> This score has been demonstrated to provide a system for reproducible repeated ratings for the early healing assessment of periodontal soft tissues, showing a high intra-examiner (0.826–0.915) and inter-examiner reliability correlation coefficient (0.828).<sup>26</sup>

The HA group showed significantly higher median EHS values when compared to the NT group in both evaluated periods. However, at 1 week, this result should be considered with caution as the difference between the groups was too small, and might not be clinically relevant. This

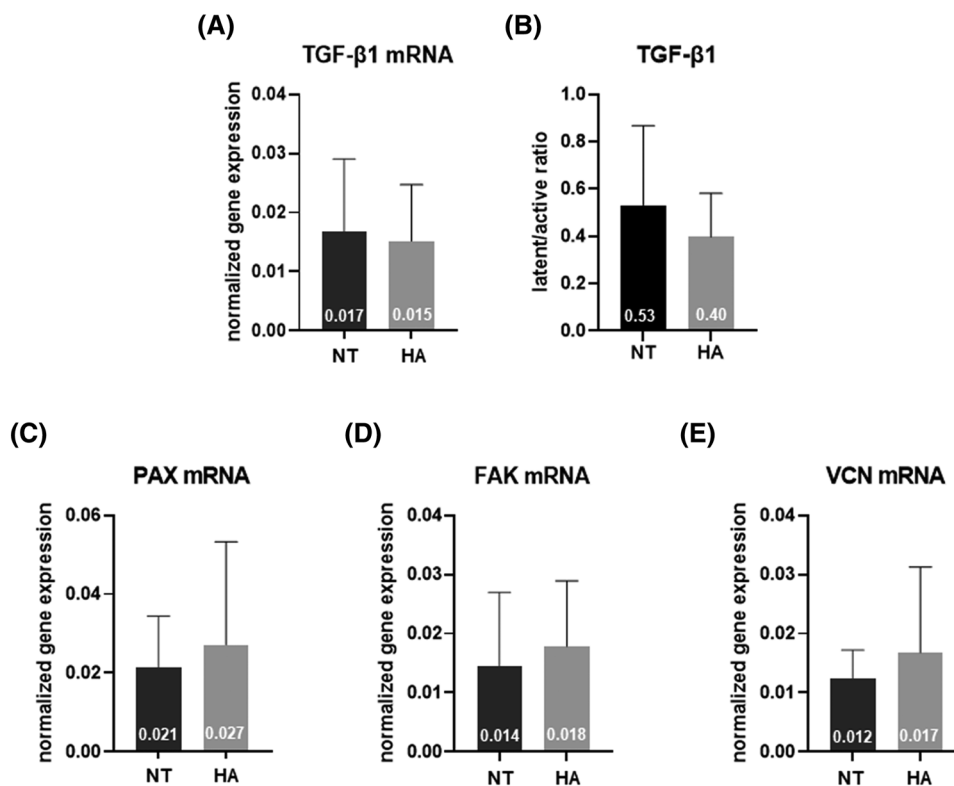




**FIGURE 4** Gene expression analysis results for hyaluronic acid (HA)-treated and no treatment (NT) groups. Bar graph data were normalized on actin protein levels and show means  $\pm$  standard deviations. **(A)** Lysyl oxidase (LOX) mRNA expression levels. **(B)** Matrix metalloproteinase 1 (MMP-1) mRNA expression levels. **(C)** MMP-1 protein levels after densitometric analysis. **(D)** Representative western blots showing MMP-1 immunoreactive bands in gingival homogenates of NT and HA groups. **(E)** TIMP-1 mRNA expression levels.



**FIGURE 5** **(A)** Representative SDS-zymogram showing activity levels of matrix metalloproteinases (MMPs; specifically, proMMP-9, proMMP-2, MMP-2 and MMP-1) in gingival homogenates of hyaluronic acid (HA)-treated and no treated (NT) sites. **(B-D)** MMP protein levels after densitometric scanning of lytic bands, showing means  $\pm$  standard deviations of the NT and HA groups for **(B)** MMP-2, **(C)** proMMP-2, and **(D)** proMMP-9



**FIGURE 6** (A,B) Means and standard deviations for the hyaluronic acid (HA)-treated and no treatment (NT) groups of (A) TGF- $\beta$ 1 mRNA levels and (B) TGF- $\beta$ 1 activation expressed as the ratio between the active homodimer and the latent form. (C-E) Means and standard deviations for the HA and NT groups of the gene expression of mechanosensors (C) PAX, (D) FAK, and (E) VCN.

confirms that in order to best highlight subtle differences in healing, it is necessary to select very early time intervals for evaluation.

Interestingly, clinical response in the HA group at 24 h was similar to NT at 1 week, and this could allow us to hypothesize that HA might accelerate the clinical wound healing response.<sup>10,35</sup>

The role of HA in enhancing angiogenesis has been reported.<sup>5</sup> An in vitro study reports that HA is involved in stimulating angiogenesis by acting on HA receptors present in ECs.<sup>36</sup>

In a previous histological study,<sup>10</sup> a statistically significant percentage of newly formed blood vessels in human oral wounds was detected 10 days after HA treatment.

Considering the literature and our previous data, in the current research we defined MVD as the primary outcome aiming to investigate the influence of HA in the early phases of G tissue repair. However, in our results, no changes in MVD after HA treatment were observed. The differences in the HA composition and in the biopsy collection time might be possible reasons explaining this.<sup>10</sup> Moreover, although new blood vessel growth is a key element in the proliferative phase of wound healing,<sup>37</sup> this might not be strictly necessary in the early period.<sup>22</sup>

Morphological analyses revealed that tissue structure, inflammatory infiltrate, cell proliferation, ECM and collagen fiber organization were not affected by HA. However, a recent in vitro study<sup>15</sup> reported an increase of human oral fibroblast proliferation after HA treatment. The effect of HA on cell proliferation in vitro is related to its MW and concentration, and the method of delivery of HA to the cell culture.<sup>15</sup>

A recent human study<sup>38</sup> evaluated the effect of topical treatment with phenytoin in experimental palatal wounds. As in our study, after 24 h, the authors reported no histological differences between groups. This could support the hypothesis about the importance of performing a deeper analysis to detect changes in the healing process at a very early period, such as gene and protein expression assessment.

Collagen fibril stabilization is influenced by the maturation of newly synthesized collagen. LOX is a secreted copper-containing amine, involved in collagen and elastin cross-linking. It has been shown that LOX upregulation in the inflammatory phase accelerates the healing process.<sup>39</sup> Moreover, it was previously reported that mRNA-level analysis of enzymes responsible for collagen cross-linking is predictive of the susceptibility of newly synthesized collagen to undergo maturation.<sup>40</sup> The significant



upregulation of *LOX* gene expression induced by HA is consistent with the hypothesis that collagen maturation enhanced by LOX is an early response after injury to favor collagen maturation and gingival repair. This hypothesis is supported by the observation that the extent of cross-link density significantly increases during the early ECM remodeling phase, as described for skin and liver.<sup>41</sup>

Interestingly, HA was also demonstrated to be effective in improving the efficiency of tropoelastin recruitment and desmosine-mediated cross-linking by enhancing endogenous lysyl production of LOX.<sup>42</sup>

The suggestion that collagen maturation plays a major role in the early response induced by HA during gingival repair is supported by the results related to collagen degradation. Collagen breakdown is driven by MMP-1, which cleaves the intact collagen triple helix, allowing further degradation by other proteases such as MMP-2 and MMP-9. MMPs are finely regulated not only at the transcriptional but also at the post-translational level by TIMPs.<sup>43</sup> MMP and TIMP interactions play a key role in the ECM remodeling process.<sup>43</sup>

While *MMPI* gene expression was not significantly affected by HA, our results show that MMP-1 protein levels were strongly induced in HA-treated gingiva, suggesting an increased collagen degradation. These results are consistent with our previous *in vivo* study, showing MMP-1 increase in oral fibroblasts after HA treatment.<sup>21</sup>

However, TIMP1 mRNA levels were also significantly induced by HA. The increase of MMP-1 protein levels is paralleled by the concomitant TIMP1 upregulation. As a consequence, although the collagen turnover is stimulated, collagen content is not modified.

In this study, we considered *TIMP1* gene expression in relation to MMP-1 protein levels since TIMPs do not undergo post-transcriptional modifications.<sup>44</sup> Therefore, TIMP1 mRNA levels can be used to predict their ability to inhibit MMP-1.

These findings suggest that HA-induced TIMP1 upregulation, balancing interstitial collagen degradation, could represent an important mechanism to restore tissue homeostasis and to avoid the deleterious consequences for the wound healing process of excessive amounts of MMPs acting for a long time on healing tissue.<sup>43</sup>

The results are not consistent with a recent study evaluating the effect of enamel matrix derivative (EMD) on excisional palatal mucosa wounds. The authors reported stable TIMP-1 and reduced MMP-9 in the EMD group, while clinical differences were not observed at any time point. Nevertheless, an early evaluation was not performed, thus EMD benefits in early inflammatory stages cannot be elucidated.<sup>45</sup>

TGF- $\beta$ 1 is a pro-fibrotic factor involved in collagen turnover regulation and fibrogenesis. It increases

LOX expression, contributing to collagen stabilization.<sup>46</sup> According to a previous *in vitro* study,<sup>15</sup> our results showed no differences in *TGFBI* gene expression. Moreover, the analysis at the protein level suggests that HA did not trigger an increased TGF- $\beta$ 1 activation. Our data show that LOX upregulation is not paralleled by TGF- $\beta$ 1 upregulation. Since TGF- $\beta$ 1 is an activator of LOX,<sup>47</sup> we can hypothesize an alternative mechanism leading to HA-induced LOX upregulation.

Cell-ECM interactions act as important effectors in the modulation of cell activities, by involving reciprocal forces translated into intracellular signals by mechanotransduction mechanisms.<sup>46</sup> Indeed, it was previously reported that LOX mechanoregulation leads to different control of LOX expression by low- and high-level mechanical forces exerted by different ECM stiffness, therefore influencing ECM stabilization.<sup>48</sup> Accordingly, since HA could behave as a mechanical stimulus acting on cells, we can hypothesize that in our experimental setting *LOX* gene expression can be triggered by an HA-induced mechanical stimulation. Although we did not find an upregulation of genes codifying for some protein part of the adhesion plaque, this hypothesis is not inconsistent: that HA can favor cell-ECM adhesion and integrin clustering and, therefore, cell-ECM protein cross-talk, leading to activation of signaling mechanisms able to modify cellular responses, including LOX upregulation.

This finding, together with the results related to TIMPs/MMPs balance and LOX expression, suggests that HA favors the expression of genes related to an improved healing response. Accordingly, we can hypothesize that LOX upregulation could be induced by a different and TGF- $\beta$ 1-independent activation pathway.

The maintenance of cell functions and homeostasis *in vivo* requires the integration of biological and mechanical signals. Fibroblasts sense and respond to mechanical forces that can influence ECM remodelling.<sup>49</sup>

A recent *in vitro* study<sup>16</sup> reported that HA downregulates PAX and VNC mRNA levels in human gingival fibroblasts. Our results showed that FAK, PAX and VNC mRNA levels are not influenced by HA treatment, suggesting that the events triggered by HA in the early healing are not dependent on mechanotransduction mechanisms.

Undoubtedly, this study presents some limitations. Since our aim was to investigate the early events triggered by HA in gingival tissue during healing, morphological and molecular evaluations were performed using a single postsurgical time point.

A second limitation could be that LOX analysis was performed only at the gene expression level. However, as previously reported, it represents a reliable approach to analyze collagen maturation related to gingival repair.



On the other hand, the randomization method used was by a simple coin toss, while more appropriate methods are needed, especially in small clinical trials.<sup>50</sup>

Nonetheless, this is the first human study evaluating in vivo the effect of HA in the early stage of oral surgical wound repair. Surgical wounds present particular conditions that are not present in a monolayer cell culture and could produce relevant changes in the oral tissue response.

Further studies should focus on extending the follow-up period, in order to understand the role of HA in the different phases of oral wound repair, allowing the development of new therapies to enhance oral wound healing. Furthermore, it would be of interest to evaluate the effect of HA in subjects with systemic conditions that impair wound healing, such as diabetic or smoking patients.

## 5 | CONCLUSIONS

The present study showed that the additional use of 0.8% HA gel in periodontal surgery does not modify new blood vessel growth in the early phase of gingival wound healing.

Nevertheless, regarding secondary outcomes, HA application resulted in an enhancement of ECM remodeling and collagen maturation, that could act as key drivers of the early wound healing of G tissues to improve clinical parameters.

## AUTHOR CONTRIBUTIONS

Conceptualization: Andrea Pilloni, Lorenzo Marini, Mariana A. Rojas. Data acquisition: Elena Canciani, Claudia Dellavia, Nicoletta Gagliano, Laura B. Cornaghi. Data curation: Elena Canciani, Nicoletta Gagliano. Investigation: Andrea Pilloni, Lorenzo Marini, Elena Canciani, Nicoletta Gagliano, Mariana A. Rojas. Methodology: Andrea Pilloni, Lorenzo Marini, Mariana A. Rojas. Project Administration: Andrea Pilloni, Mariana A. Rojas. Supervision: Andrea Pilloni. Writing—original draft: Andrea Pilloni, Lorenzo Marini, Mariana A. Rojas. Writing—review and editing: Andrea Pilloni, Lorenzo Marini, Elena Canciani, Nicoletta Gagliano, Claudia Dellavia, Ezio Costa, Mariana A. Rojas. All authors critically revised the manuscript, gave their final approval, and agree to be accountable for all aspects of the work.

## ACKNOWLEDGMENTS

No external funding, apart from the support of the authors' institutions, was available for this study.

## CONFLICTS OF INTEREST

The authors declare that there are no conflicts of interest in this study.

## DATA AVAILABILITY STATEMENT

Supporting data of this study are available from the corresponding author upon request.

## ORCID

Andrea Pilloni  <https://orcid.org/0000-0002-6268-1863>


Lorenzo Marini  <https://orcid.org/0000-0001-6662-2644>

Nicoletta Gagliano  <https://orcid.org/0000-0002-3393-3144>

Elena Canciani  <https://orcid.org/0000-0002-6987-6794>

Claudia Dellavia  <https://orcid.org/0000-0001-5145-3606>

Laura Brigida Cornaghi  <https://orcid.org/0000-0002-6871-5059>

Mariana A. Rojas  <https://orcid.org/0000-0002-8712-0958>

## REFERENCES

- Dahiya P, Kamal R. Hyaluronic acid: a boon in periodontal therapy. *N Am J Med Sci.* 2013;5(5):309-315. <https://doi.org/10.4103/1947-2714.112473>
- Aya KL, Stern R. Hyaluronan in wound healing: rediscovering a major player. *Wound Repair Regen.* 2014;22(5):579-593. <https://doi.org/10.1111/wrr.12214>
- Hämmerle CH, Giannobile WV; Working Group 1 of the European Workshop on Periodontology. Biology of soft tissue wound healing and regeneration—consensus report of Group 1 of the 10th European Workshop on Periodontology. *J Clin Periodontol.* 2014;41(Suppl 15):S1-S5. <https://doi.org/10.1111/jcpe.12221>
- Chiquet M, Katsaros C, Klefsas D. Multiple functions of gingival and mucoperiosteal fibroblasts in oral wound healing and repair. *Periodontol 2000.* 2015;68(1):21-40. <https://doi.org/10.1111/prd.12076>
- Prosdociami M, Bevilacqua C. Exogenous hyaluronic acid and wound healing: an updated vision. *Panminerva Med.* 2012;54(2):129-135.
- Larjava H, Heino J, Kähäri VM, Krusius T, Vuorio E. Characterization of one phenotype of human periodontal granulation-tissue fibroblasts. *J Dent Res.* 1989;68(1):20-25. <https://doi.org/10.1177/00220345890680010301>
- West DC, Hampson IN, Arnold F, Kumar S. Angiogenesis induced by degradation products of hyaluronic acid. *Science.* 1985;228(4705):1324-1326. <https://doi.org/10.1126/science.2408340>
- Pilloni A, Bernard GW. The effect of hyaluronan on mouse intramembranous osteogenesis in vitro. *Cell Tissue Res.* 1998;294(2):323-333. <https://doi.org/10.1007/s004410051182>
- Fujioka-Kobayashi M, Müller HD, Mueller A, et al. In vitro effects of hyaluronic acid on human periodontal ligament cells. *BMC Oral Health.* 2017;17(1):44. <https://doi.org/10.1186/s12903-017-0341-1>
- Casale M, Moffa A, Vella P, et al. Hyaluronic acid: Perspectives in dentistry. A systematic review. *Int J Immunopathol Pharmacol.* 2016;29(4):572-582. <https://doi.org/10.1177/0394632016652906>
- Pilloni A, Schmidlin PR, Sahrman P, Sculean A, Rojas MA. Effectiveness of adjunctive hyaluronic acid application in coronally advanced flap in Miller class I single gingival recession



- sites: a randomized controlled clinical trial [published correction appears in *Clin Oral Investig*. 2018 Nov;22(8):2961-2962]. *Clin Oral Investig*. 2019;23(3):1133-1141. <https://doi.org/10.1007/s00784-018-2537-4>
12. Pilloni A, Nardo F, Rojas MA. Surgical treatment of a cemental tear-associated bony defect using hyaluronic acid and a resorbable collagen membrane: A 2-year follow-up. *Clin Adv Periodontics*. 2019;9(2):64-69. <https://doi.org/10.1002/cap.10053>
  13. Shirakata Y, Imafuji T, Nakamura T, et al. Periodontal wound healing/regeneration of two-wall intrabony defects following reconstructive surgery with cross-linked hyaluronic acid-gel with or without a collagen matrix: a preclinical study in dogs. *Quintessence Int*. 2021;0(0):308-316. <https://doi.org/10.3290/j.qi.b937003>
  14. Pilloni A, Rojas MA, Marini L, et al. Healing of intrabony defects following regenerative surgery by means of single-flap approach in conjunction with either hyaluronic acid or an enamel matrix derivative: a 24-month randomized controlled clinical trial. *Clin Oral Investig*. 2021;25(8):5095-5107. <https://doi.org/10.1007/s00784-021-03822-x>
  15. Asparuhova MB, Kiryak D, Eliezer M, Mihov D, Sculean A. Activity of two hyaluronan preparations on primary human oral fibroblasts. *J Periodontal Res*. 2019;54(1):33-45. <https://doi.org/10.1111/jre.12602>
  16. Canciani E, Sirello R, Pellegrini G, et al. Effects of Vitamin and amino acid-enriched hyaluronic acid gel on the healing of oral mucosa: in vivo and in vitro study. *Medicina (Kaunas)*. 2021;57(3):285. Published 2021 Mar 18. <https://doi.org/10.3390/medicina57030285>
  17. Chen L, Arbieva ZH, Guo S, Marucha PT, Mustoe TA, DiPietro LA. Positional differences in the wound transcriptome of skin and oral mucosa. *BMC Genomics*. 2010;11:471. Published 2010 Aug 12. <https://doi.org/10.1186/1471-2164-11-471>
  18. Simões A, Chen L, Chen Z, et al. Differential microRNA profile underlies the divergent healing responses in skin and oral mucosal wounds. *Sci Rep*. 2019;9(1):7160. Published 2019 May 9. <https://doi.org/10.1038/s41598-019-43682-w>
  19. Iglesias-Bartolome R, Uchiyama A, Molinolo AA, et al. Transcriptional signature primes human oral mucosa for rapid wound healing. *Sci Transl Med*. 2018;10(451):eaap8798. <https://doi.org/10.1126/scitranslmed.aap8798>
  20. Vescarelli E, Pilloni A, Dominici F, et al. Autophagy activation is required for myofibroblast differentiation during healing of oral mucosa. *J Clin Periodontol*. 2017;44(10):1039-1050. <https://doi.org/10.1111/jcpe.12767>
  21. Rojas MA, Ceccarelli S, Gerini G, et al. Gene expression profiles of oral soft tissue-derived fibroblast from healing wounds: correlation with clinical outcome, autophagy activation and fibrotic markers expression. *J Clin Periodontol*. 2021;48(5):705-720. <https://doi.org/10.1111/jcpe.13439>
  22. Polimeni G, Xiropaidis AV, Wikesjö UM. Biology and principles of periodontal wound healing/regeneration. *Periodontol 2000*. 2006;41:30-47. <https://doi.org/10.1111/j.1600-0757.2006.00157.x>
  23. Galli F, Zuffetti F, Capelli M, et al. Hyaluronic acid to improve healing of surgical incisions in the oral cavity: a pilot multi-centre placebo-controlled randomised clinical trial. *Eur J Oral Implantol*. 2008;1(3):199-206.
  24. Pilloni A, Ceccarelli S, Bosco D, et al. Effect of chlorhexidine digluconate in early wound healing of human gingival tissues. a histological, immunohistochemical and biomolecular analysis. *Antibiotics (Basel)*. 2021;10(10):1192. <https://doi.org/10.3390/antibiotics10101192>
  25. Marini L, Rojas MA, Sahrman P, Aghazada R, Pilloni A. Early wound healing score: a system to evaluate the early healing of periodontal soft tissue wounds. *J Periodontal Implant Sci*. 2018;48(5):274-283. <https://doi.org/10.5051/jpis.2018.48.5.274>
  26. Marini L, Sahrman P, Rojas MA, et al. Early Wound Healing Score (EHS): an Intra- and Inter-Examiner Reliability Study. *Dent J (Basel)*. 2019;7(3):86. <https://doi.org/10.3390/dj7030086>
  27. Fusco N, Rocco EG, Del Conte C, et al. HER2 in gastric cancer: a digital image analysis in pre-neoplastic, primary and metastatic lesions. *Mod Pathol*. 2013;26(6):816-824. <https://doi.org/10.1038/modpathol.2012.228>
  28. Canciani E, Gagliano N, Paino F, et al. Polyblend nanofibers to regenerate gingival tissue: a preliminary in vitro study. *Frontiers in Materials*. 2021;8:670010.
  29. Francetti L, Dellavia C, Corbella S, et al. Morphological and molecular characterization of human gingival tissue overlying multiple oral exostoses. *Case Rep Dent*. 2019;2019:3231759. <https://doi.org/10.1155/2019/3231759>
  30. Bianchi F, Sommariva M, Cornaghi LB, et al. Mechanical cues, E-Cadherin Expression and Cell "Sociality" are crucial crossroads in determining pancreatic ductal adenocarcinoma cells behavior. *Cells*. 2022;11(8):1318. Published 2022 Apr 13. <https://doi.org/10.3390/cells11081318>
  31. Canullo L, Pellegrini G, Allievi C, Trombelli L, Annibali S, Dellavia C. Soft tissues around long-term platform switching implant restorations: a histological human evaluation. Preliminary results. *J Clin Periodontol*. 2011;38(1):86-94. <https://doi.org/10.1111/j.1600-051X.2010.01641.x>
  32. Smith PC, Martínez C, Martínez J, McCulloch CA. Role of fibroblast populations in periodontal wound healing and tissue remodeling. *Front Physiol*. 2019;10:270. Published 2019 Apr 24. <https://doi.org/10.3389/fphys.2019.00270>
  33. Rojas MA, Marini L, Pilloni A, Sahrman P. Early wound healing outcomes after regenerative periodontal surgery with enamel matrix derivatives or guided tissue regeneration: a systematic review. *BMC Oral Health*. 2019;19(1):76. [10.1186/s12903-019-0766-9](https://doi.org/10.1186/s12903-019-0766-9)
  34. Kawano Y, Patrúlea V, Sublet E, et al. Wound healing promotion by hyaluronic acid: effect of molecular weight on gene expression and in vivo wound closure. *Pharmaceuticals (Basel)*. 2021;14(4):301. Published 2021 Mar 28. <https://doi.org/10.3390/ph14040301>
  35. Romeo U, Libotte F, Palaia G, et al. Oral soft tissue wound healing after laser surgery with or without a pool of amino acids and sodium hyaluronate: a randomized clinical study. *Photomed Laser Surg*. 2014;32(1):10-16. <https://doi.org/10.1089/pho.2013.3509>
  36. Gao F, Yang CX, Mo W, Liu YW, He YQ. Hyaluronan oligosaccharides are potential stimulators to angiogenesis via RHAMM mediated signal pathway in wound healing. *Clin Invest Med*. 2008;31(3):E106-16. [10.25011/cim.v31i3.3467](https://doi.org/10.25011/cim.v31i3.3467)
  37. DiPietro LA. Angiogenesis and wound repair: when enough is enough. *J Leukoc Biol*. 2016;100(5):979-984. <https://doi.org/10.1189/jlb.4MR0316-102R>



38. Doshi A, McAuley JW, Tatakis DN. Topical phenytoin effects on palatal wound healing. *J Periodontol*. 2021;92(3):409-418. <https://doi.org/10.1002/JPER.20-0340>
39. Schrementi ME, Ferreira AM, Zender C, DiPietro LA. Site-specific production of TGF-beta in oral mucosal and cutaneous wounds. *Wound Repair Regen*. 2008;16(1):80-86. <https://doi.org/10.1111/j.1524-475X.2007.00320.x>
40. van der Slot AJ, Zuurmond AM, van den Bogaerd AJ, et al. Increased formation of pyridinoline cross-links due to higher telopeptide lysyl hydroxylase levels is a general fibrotic phenomenon. *Matrix Biol*. 2004;23(4):251-257. <https://doi.org/10.1016/j.matbio.2004.06.001>
41. Ricard-Blum S, Bresson-Hadni S, Vuitton DA, Ville G, Grimaud JA. Hydroxypyridinium collagen cross-links in human liver fibrosis: study of alveolar echinococcosis. *Hepatology*. 1992;15(4):599-602. <https://doi.org/10.1002/hep.1840150408>
42. Kothapalli CR, Gacchina CE, Ramamurthi A. Utility of hyaluronan oligomers and transforming growth factor-beta1 factors for elastic matrix regeneration by aneurysmal rat aortic smooth muscle cells. *Tissue Eng Part A*. 2009;15(11):3247-3260. <https://doi.org/10.1089/ten.tea.2008.0593>
43. Brew K, Dinakarandian D, Nagase H. Tissue inhibitors of metalloproteinases: evolution, structure and function. *Biochim Biophys Acta*. 2000;1477(1-2):267-283. [https://doi.org/10.1016/s0167-4838\(99\)00279-4](https://doi.org/10.1016/s0167-4838(99)00279-4)
44. Sternlicht MD, Werb Z. How matrix metalloproteinases regulate cell behavior. *Annu Rev Cell Dev Biol*. 2001;17:463-516. <https://doi.org/10.1146/annurev.cellbio.17.1.463>
45. Miguel MMV, Mathias-Santamaria IF, Rossato A, et al. Enamel matrix derivative effects on palatal mucosa wound healing: Randomized clinical trial. *J Periodontol Res*. 2021;56(6):1213-1222. <https://doi.org/10.1111/jre.12934>
46. Cai L, Xiong X, Kong X, Xie J. The role of the lysyl oxidases in tissue repair and remodeling: a concise review. *Tissue Eng Regen Med*. 2017;14(1):15-30. <https://doi.org/10.1007/s13770-016-0007-0>
47. Handorf AM, Zhou Y, Halanski MA, Li WJ. Tissue stiffness dictates development, homeostasis, and disease progression. *Organogenesis*. 2015;11(1):1-15. <https://doi.org/10.1080/15476278.2015.1019687>
48. Chen YJ, Jeng JH, Chang HH, Huang MY, Tsai FF, Yao CC. Differential regulation of collagen, lysyl oxidase and MMP-2 in human periodontal ligament cells by low- and high-level mechanical stretching. *J Periodontol Res*. 2013;48(4):466-474. <https://doi.org/10.1111/jre.12028>
49. Martino F, Perestrelo AR, Vinarský V, Pagliari S, Forte G. Cellular mechanotransduction: from tension to function. *Front Physiol*. 2018;9:824. <https://doi.org/10.3389/fphys.2018.00824>
50. Kang M, Ragan BG, Park JH. Issues in outcomes research: an overview of randomization techniques for clinical trials. *J Athl Train*. 2008;43(2):215-221. <https://doi.org/10.4085/1062-6050-43.2.215>

## SUPPORTING INFORMATION

Additional supporting information can be found online in the Supporting Information section at the end of this article.

**How to cite this article:** Pilloni A, Marini L, Gagliano N, Canciani E, et al. Clinical, histological, immunohistochemical, and biomolecular analysis of hyaluronic acid in early wound healing of human gingival tissues: A randomized, split-mouth trial. *J Periodontol*. 2023;1-14. <https://doi.org/10.1002/JPER.22-0338>