

Suture Anchors Fixation in MPFL Reconstruction using a Bioactive Synthetic Ligament

Massimo Berruto¹ Paolo Ferrua¹ Daniele Tradati¹ Francesco Uboldi¹ Eva Usellini¹
Bruno Michele Marelli²

¹SSD Chirurgia Articolare del Ginocchio, Istituto Ortopedico Gaetano Pini, Milan, Italy

²Dipartimento di Ortotraumatologia Generale e Chirurgie Ortopediche Specialistiche, Istituto Ortopedico Gaetano Pini, Milan, Italy

Address for correspondence Daniele Tradati, MD, SSD Chirurgia Articolare del Ginocchio, Istituto Ortopedico Gaetano Pini, Piazza A. Cardinal Ferrari 1, Milan, Italy (e-mail: itadart@hotmail.com).

Joints 2017;5:188–190.

Abstract

Medial patellofemoral ligament (MPFL) reconstruction has a key role in patellofemoral instability surgery. Many surgical techniques have been described so far using different types of grafts (autologous, heterologous, or synthetic) and fixation techniques. The hereby described technique for MPFL reconstruction relies on the use of a biosynthetic graft (LARS Arc Sur Tille, France). Fixation is obtained by means of suture anchors on the patellar side and a resorbable interference screw on the femoral side locating the insertion point according to Schottle et al. An early passive range of motion (ROM) recovery is fundamental to reduce the risk of postoperative stiffness; a partial weight bearing with crutches is allowed until 6 weeks after the surgery. In our experience, the use of a biosynthetic graft and suture anchors provides stable fixation, minimizing donor site morbidity and reducing the risk of patellar fracture associated with transosseous tunnels. This technique represents a reliable and reproducible alternative for MPFL reconstruction, thereby minimizing the risk of possible complications.

Keywords

- ▶ medial patellofemoral ligament
- ▶ suture anchors
- ▶ biosynthetic ligament
- ▶ patellofemoral instability

Introduction

Medial patellofemoral ligament (MPFL) has been recognized as the most important passive stabilizer of the patellofemoral joint. Dejour et al¹ described three major anatomic factors of patellofemoral instability: trochlear dysplasia, excessive tibial tuberosity–trochlear groove (TT–TG) distance, and abnormal patellar height. Surgical correction of these predisposing factors is the key to success in restoring joint stability along with MPFL reconstruction, first described by Ellera Gomes in 1992.² So far, many surgical techniques have been described using different types of graft (autografts, allografts, or synthetic grafts) and several fixation techniques, particularly on the patellar side. Use of biosynthetic graft has been described as a valid alternative to autografts in the presence of hyperlaxity³ or in revision surgery.⁴ The use of suture anchors on the patella is considered a reliable system to obtain stable fixation, thus reducing the risk of patellar fracture associated with transosseous tunnels.⁵

Surgical Technique

A 2.5-cm longitudinal skin incision is performed on the proximal medial border of the patella deep to the second parapatellar layer, taking care not to violate the underlying synovial membrane. The medial border of the patella is exposed, and a sulcus is prepared on the bony surface for placing the suture anchors and the graft. Two all-suture anchors (JuggerKnot, 1.4 mm; Zimmer Biomet, Warsaw, Indiana, United States) are inserted slightly convergent, parallel to the anterior cortex, on the superior two-thirds of the patella leaving a bony bridge of 1 cm between them (▶ Fig. 1). After testing the pullout resistance, the #1 Max braided sutures (Zimmer Biomet) are used to fix the 1.5 cm central portion of the biosynthetic graft (LARS R6 × 400; LARS, Arc Sur Tille, France) using double-row Krackow stitches until reaching stable fixation on the patellar side and leaving two symmetric free ends (▶ Fig. 2).

After performing a 2-cm skin incision between medial epicondyle and adductor tubercle, the femoral insertion point

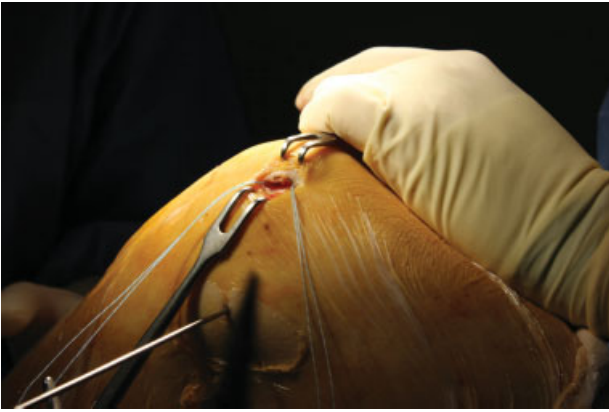

Fig. 1 Preparation of the osseous surface on the medial side of the patella.

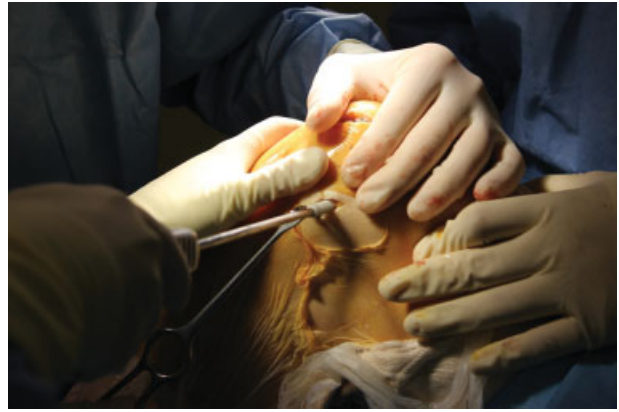

Fig. 3 Fixation of the graft on the femoral side using a biodegradable interference screw.

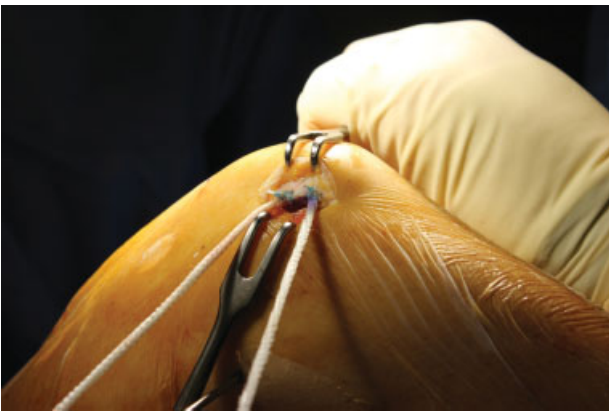


Fig. 2 Fixation of the graft to the patella using #1 Max braided sutures.

is identified according to Schottle et al⁶ under fluoroscopic guide, and an eyelet-provided guidewire is drilled through the distal femur. The graft is then passed through the second layer of medial parapatellar retinaculum. A femoral half tunnel is made using a 7-mm cannulated drill to a depth of 40 mm. The length of the graft is measured and the exceeding portion is removed. The two free ends (35-mm in length) are sutured together by Krackow stitches using absorbable sutures. The graft is passed through the femoral tunnel using the eyelet of the previously positioned guidewire. The free ends of the traction sutures are tensioned from the lateral side of the knee, allowing to check patellar medial to lateral mobility and to assess graft tension all through the ROM and after several cycles of flexion–extension. Femoral fixation is then performed at 60 degrees of knee flexion using a 7 × 25-mm biocomposite interference screw (BIORCI-HA; Smith & Nephew, Mansfield, Massachusetts, United States; ► **Fig. 3**).

Postoperative Treatment

Partial weight bearing with crutches, passive ROM recovery, and quadriceps strengthening isometric exercises are allowed from the first postoperative day. Also, the passive flexion recovery is performed by continuous passive motion with increasing ROM values. After removal of skin suture, the

patient is encouraged to perform hydrokinesitherapy, and swimming is allowed after the first month. After 6 weeks, the patient is allowed to full weight bearing if quadriceps strength has been recovered. Pivoting sport activities are allowed 6 months after surgery.

Discussion

Suture anchors fixation for MPFL has been described by Song et al.⁵ The use of these devices allows obtaining stable fixation with a reproducible, easy, and less invasive technique if compared with traditional transosseous tunnels. Also, avoiding tunnels minimizes the risk of patellar fracture in small size knees and leaves an intact patellar bone stock for eventual revision surgery. The only remarkable disadvantage is cost, which is by far superior to bone tunnels but is comparable to other devices, such as suspension button, biodegradable screws, and metallic anchors.

The use of synthetic ligament has been reported by some authors with good results comparable to autologous hamstring grafts, which are still recognized as the gold standard in MPFL reconstruction.^{3,7}

The use of synthetic ligament has several theoretical advantages. First, lesser morbidity is related to sparing of hamstring tendons, which can be preserved for future ligament or MPFL revision surgery. Second, the high mechanical properties of the synthetic graft are also useful in case of revision surgery or patients affected by generalized ligament laxity that could negatively affect resistance to traction and stiffness of autologous tissues.⁴

Some concerns about the use of synthetic grafts are related to mechanical and biological issues. On considering the higher stiffness of the biosynthetic graft when compared with autologous hamstrings, it is important to check the tension of the implant all through the procedure to avoid medial overconstraining of the patella. Surely, synovialization of synthetic ligaments that can cause graft failure, as reported in the case of intra-articular reconstruction (i.e., anterior cruciate ligament reconstruction),⁸ has not been demonstrated in extra-articular settings such as MPFL reconstruction.

Nonetheless, this is the first description of MPFL reconstruction with biosynthetic ligament and patellar fixation with suture anchors. Further studies are needed to confirm the effectiveness of this technique and its long-term efficacy in restoring patellofemoral instability.

References

- 1 Dejour H, Walch G, Nove-Josserand L, Guier C. Factors of patellar instability: an anatomic radiographic study. *Knee Surg Sports Traumatol Arthrosc* 1994;2(01):19–26
- 2 Ellera Gomes JL. Medial patellofemoral ligament reconstruction for recurrent dislocation of the patella: a preliminary report. *Arthroscopy* 1992;8(03):335–340
- 3 Berruto M, Ferrua P, Uboldi F, et al. Medial patellofemoral ligament reconstruction with bioactive synthetic ligament is an option. A 3-year follow-up study. *Knee Surg Sports Traumatol Arthrosc* 2014;22(10):2419–2425
- 4 Berruto M, Parente A, Ferrua P, Pasqualotto S, Uboldi F, Usellini E. Revision surgery in permanent patellar dislocation in DiGeorge Syndrome. *Case Rep Orthop* 2015;2015. Doi: 10.1155/2015/752736
- 5 Song SY, Kim IS, Chang HG, Shin JH, Kim HJ, Seo YJ. Anatomic medial patellofemoral ligament reconstruction using patellar suture anchor fixation for recurrent patellar instability. *Knee Surg Sports Traumatol Arthrosc* 2014;22(10):2431–2437
- 6 Schöttle PB, Schmeling A, Rosenstiel N, Weiler A. Radiographic landmarks for femoral tunnel placement in medial patellofemoral ligament reconstruction. *Am J Sports Med* 2007;35(05):801–804
- 7 Khemka A, Lord SJ, Doyle Z, Bosley B, Al Muderis M. Minimally invasive medial patellofemoral ligament reconstruction for patellar instability using an artificial ligament: a two year follow-up. *Knee* 2016;23(02):261–266
- 8 Legnani C, Ventura A, Terzaghi C, Borgo E, Albisetti W. Anterior cruciate ligament reconstruction with synthetic grafts. A review of literature. *Int Orthop* 2010;34(04):465–471